

CASE REPORT

Acute Pericarditis Mimicking Unstable Angina Pectoris

Ryan Enast Intan^{1*}, Tan Nicko Octora², Firas Farisi Alkaff³, Dimas Rio Balti⁴

¹Faculty of Medicine Universitas Airlangga, Surabaya, Indonesia

²Faculty of Medicine Universitas Airlangga, Surabaya Indonesia – Dr. R. Koesma General Hospital

³Department of Pharmacology, Faculty of Medicine Universitas Airlangga, Surabaya, Indonesia

⁴Department of Cardiology and Vascular Medicine, Dr. R. Koesma General Hospital

ARTICLE INFO

Article history:

Received 28 July 2019

Received in revised form 10 October 2019

Accepted 18 October 2019

Available online 31 October 2019

Keywords:

Acute Pericarditis,
Pericardial Effusion,
NSAID,
Transthoracic Echocardiography,
Unstable Angina Pectoris.

ABSTRACT

Pericarditis is a common disorder that might present in various settings, including primary-care and emergency department. However, the clinical features in some cases did not match with the written theory, which could lead to a misdiagnosis. We reported a 46-year-old man presented to the emergency room with progressive tightness chest pain, epigastric pain, nausea, and vomiting in the past 2 days. Based on the clinical, electrocardiograph (ECG), and laboratory evaluation, the patient was diagnosed with unstable angina pectoris (UAP) and treated accordingly but did not showed an improvement. Clinical re-examination and echocardiography evaluation showed a pathognomonic finding of pericarditis feature. Combination therapy of colchicine and ibuprofen was given for 3 weeks. One-month follow-up evaluation showed normal ECG and echocardiography result without any remainder symptoms. Acute pericarditis does not always show typical finding. Therefore, clinician must always aware with other differential diagnosis of chest pain and ECG variation of acute pericarditis.

*) Corresponding author:

ryan_intan_92@yahoo.co.id

Introduction

Pericarditis, an inflammation of the pericardium, is a common disorder that might present in various settings, including primary-care and emergency department. It is a part of the pericardial syndrome along with cardiac tamponade. However, patients with pericarditis could also presented with cardiac tamponade as its complication. In this type of patients, the outcome is worse with high mortality rate.¹ The exact incidence and prevalence is difficult to measure, but it is diagnosed in 5% of patients admitted to the emergency department for non-acute myocardial-infarction chest pain.² The clinical presentation of pericarditis remains classic, pain in the chest that has all the characteristic of ischemic pain, including the radiation routes.³ Pathognomonic electrocardiograph (ECG) finding in pericarditis in the literature was diffuse ST-T segment elevation (typically concave) and/or PR-segment depression.⁴ In clinical practice, by combining clinical examination, ECG, and echocardiography, the diagnosis of acute pericarditis should be easily made.⁵ However, like any other diseases, there are some cases that did not matched with the literature. In this report, we present a case of acute pericarditis with unusual presentation that was misdiagnosed with Unstable Angina Pectoris (UAP).

Case report

A 46-year-old man presented to the emergency room with

progressive tightness chest pain, epigastric pain, nausea, and vomiting in the past 2 days. He had been diagnosed with hypertension since several years ago but did not comply to routine check-up. On physical examination, his vital sign was as follow: blood pressure of 230/130 mmHg, heart rate of 96x/minute, respiratory rate of 24x/minute, and axillary temperature of 36.6°C. Electrocardiograph (ECG) showed normal sinus rhythm with large ventricle hypertrophy (LVH) (Figure 1a). Hematologic evaluation of complete blood count, CKMB marker, erythrocyte sedimentation rate, and C-reactive protein was within the normal limit, while LDL-C was increased (168 mg/dl). Chest x-ray showed cardiomegaly with CTR of 56.5% (Figure 2). Based on the findings, he was diagnosed with unstable angina pectoris (UAP) and hypertensive emergency. He was transferred to the Intensive Cardiac Care Unit where he received several oral medications (nifedipine SR 30 mg once daily, candesartan 16 mg once daily, farsorbid 5 mg twice daily, bisoprolol 5 mg once daily, and atorvastatin 40 mg once daily) and intravenous medications (fondaparinux 2.5 mg once daily, ranitidine 50mg twice daily, and ondansetron 8mg once daily). The next morning his chest pain persist, with additional symptoms of fever with axillar temperature of 38°C and palpitation with heart rate of 140x/minutes. ECG evaluation showed sinus tachycardia without no other abnormalities (Figure 1b). Oral 500mg paracetamol



and 10 mg bisoprolol were given but no improvement was found. Thyroid function (TSH, Free T4, and T3) was analyzed but also showed normal result. During physical re-examination, pericardial friction was hardly heard. Following the findings on the examination, TTE was performed and pericardial effusion was found, with normokinetic and normal LV systolic function, with concentric LVH (Figure 3a). Based on the additional findings, the patient was diagnosed with acute pericarditis. We checked genexpert TB test for the possibility of tuberculosis as the cause, but the result was negative. After that, fondaparinux and farsorbid were stopped, while oral 2mg colchicine as

loading dose followed with 1mg colchicine once daily and 600 mg ibuprofen thrice daily added to the therapy. The patient's symptoms resolved well with the given treatment, and the ECG return to baseline after 3 days of treatment (Figure 1c). He was then discharge from hospital and the oral medication was continued for 2 weeks. One-month follow-up evaluation showed normal sinus rhythm and LVH on ECG and resolution of pericardial effusion on TTE without any remainder symptoms (Figure 3b).

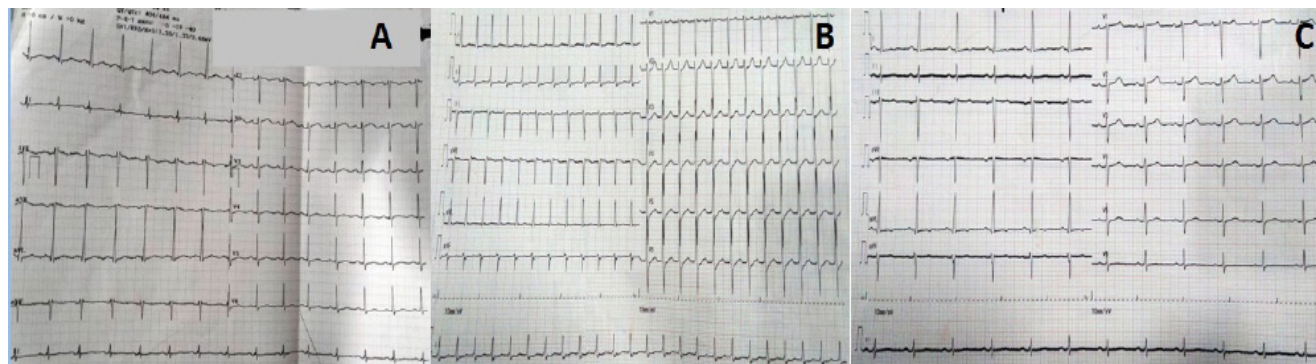


Figure 1. Electrocardiograph (ECG) evaluation result: a) on admission, showed normal sinus rhythm with left ventricle hypertrophy (LVH); b) on second day, showed sinus tachycardia with heart rate of 140x/min; c) On fifth day, after received colchicine and ibuprofen treatment, showed normal sinus rhythm and LVH.

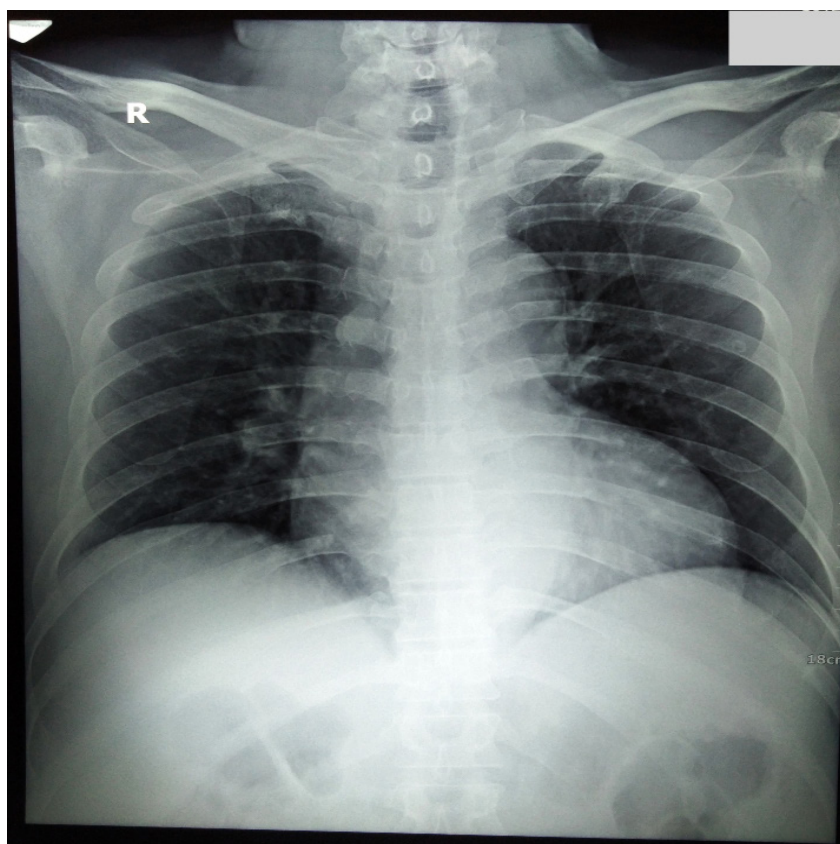


Figure 2. Thorax X-ray AP view showed normal lung findings and cardiomegaly with CTR 56.5%.

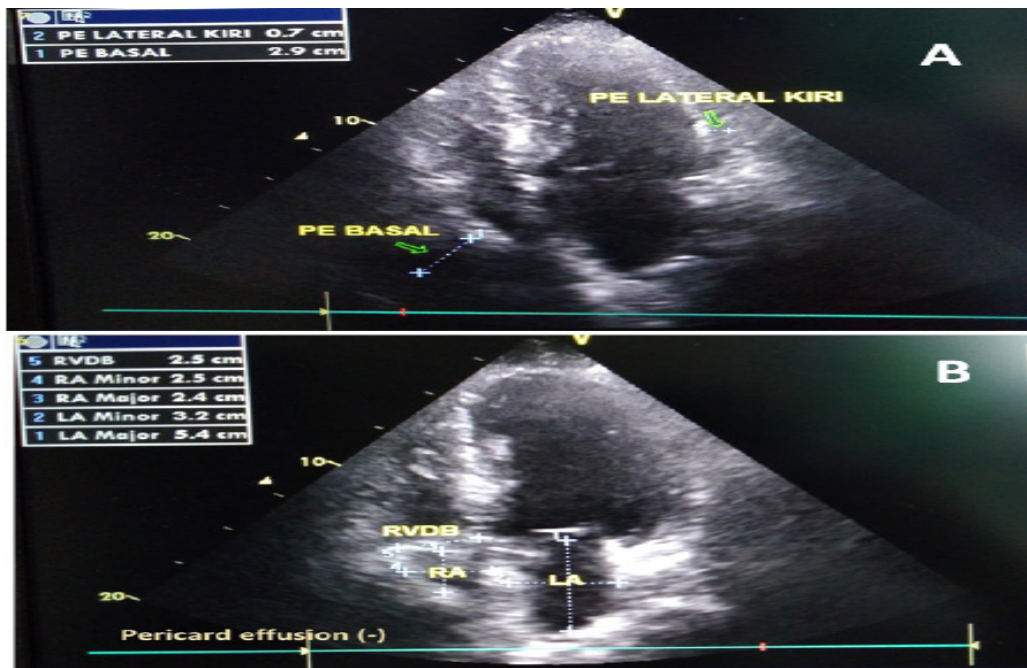


Figure 3. Transthoracic echocardiography evaluation results: a) on second day, showed massive pericardial effusion at basal (2.9 cm) and minimal pericardial effusion at lateral, with normokinetic and systolic function of LV (EF 59%);b). on thirtieth day, showed complete resolution of the pericardial effusion.

Table 1. Commonly used anti-inflammatory therapy for acute pericarditis in adults.⁸

Drugs	Dosage	Treatment duration	Tapering (every 1-2 weeks)*
Aspirin	500-1000 mg every 6-8 hours	Initial episode: 1-2 weeks	Decrease the total daily dose by 250–500 mg
Ibuprofen	600 mg every 8 hours		Decrease the total daily dose by 200–400 mg
Indomethacin	25-50 mg every 8 hours	Recurrence: Up to several months	Decrease the total daily dose by 25 mg
Naproxen	500-1000 mg daily every 12 hours		Decrease the total daily dose by 125–250 mg
Colchicine (for combination therapy with other anti-inflammatory drugs)	0.5 mg once daily (<70 kg) 0.5 mg twice daily (>70 kg)	Initial episode: 3 months Recurrence episode: 6 months	

Table 2. Predictor of poor prognostic outcome.⁸

No	Major	Minor
1.	Fever (>38oC)	Myopericarditis
2.	Subacute onset	Immunodepression
3.	Severe pericardial effusion (>20mm on echocardiography)	Trauma
4.	Cardiac tamponade	Oral anticoagulant therapy
5	No response to aspirin or NSAID after at least 1 week of therapy	

Discussion

To this date, no gold standard for diagnosis criteria for acute pericarditis has been established. Basic diagnostic evaluation for patients with pericarditis are physical auscultation, ECG, TTE, markers of inflammation, myocardial lesion, and chest X-ray. Additional diagnostic test depends on the etiology of the disease.⁵ It is suggested that at least two of the following four criteria should be present: 1) Typical chest pain, 2) Detection of a pericardial rub on auscultation, 3) suggestive ECG changes (widespread ST-elevation or PR depression), and 4) Pericardial effusion (new or worsening).⁶

In this case, the patient fulfilled two criteria, which were pericardial rub and pericardial effusion. At first, we mistakenly diagnosed the patient with UAP because of the chest pain symptom and non-specific finding from the ECG evaluation. Patient with acute pericarditis usually presents with progressive and severe chest pain that is sharp and pleuritic (supine position or inspiration makes the pain worsen). The pain might radiate to the neck, arms, or left shoulder, making the differentiation from myocardial ischemia difficult. The only difference is that the pain in pericarditis can be referred to trapezius muscle ridge.²

ECG changes in pericarditis evolve through four phases, which are: diffuse ST-segment elevation and PR-segment depression (stage I); normalization of the ST and PR segments (stage II); widespread T-wave inversions (stage III); and normalization of the T waves (stage IV).⁷ In this case, we argue that there are no specific findings from the ECG because it has already in the stage IV, considering that the patient came to the hospital 2 days after the symptoms arose.

The most common etiology of acute pericarditis is assumed to be idiopathic because the demand of diagnostic tests to confirm etiology has been relatively low.⁶ For known causes, it can be classified into infectious or non-infectious causes, where more than 2 out of 3 cases are because of infectious causes. In developed countries, the most common infection causes is viruses, while in developing countries the most common infection causes is tuberculosis.⁵ In our case, we had excluded the possibility of tuberculosis infection from chest x-ray and gene expert evaluation. The patient also had no history of malignancy or autoimmune disease, therefore we assumed that the cause of the pericarditis is either virus or idiopathic.

According to the latest treatment guidelines, NSAID are the cornerstone therapy for pericardial disease. However, the selection of specific NSAID is based on physician preference, patient's previous history, and comorbidities of the patient. The commonly used NSAID is aspirin, ibuprofen, indomethacin, or naproxen.⁸ Corticosteroid, on the other hand, is not recommended to be given as therapy because it is an independent risk factor for recurrence.⁹ In addition to NSAID, colchicine could be given as combination therapy. Trial study for the use of colchicine for acute pericarditis concluded that colchicine plus conventional therapy led to a clinically important and statistically significant benefit over conventional treatment by decreasing the recurrence rate at 18 months in patients with a first episode of acute pericarditis. Moreover, it also significantly reduces the symptoms at 72 hours.⁹ However, when given as monotherapy, colchicine generally

fails.⁸ It is suggested that colchicine is best combined with ibuprofen because ibuprofen has the advantage of increasing coronary flow and has relatively few adverse effects.³ List of commonly used anti-inflammatory therapy along with the dosage and the treatment duration can be seen in table 1.

The risk of recurrence or complication (i.e. cardiac tamponades and constructive pericarditis) in patients with acute pericarditis are based on the presence of several clinical features as poor prognostic predictors. The predictors were divided into major and minor predictor as seen in table 2. In our patient, neither major nor minor predictors were existed.

Conclusion

Acute pericarditis does not always show typical finding, especially in symptoms and ECG feature, and it also can mimic other diagnosis such as AUP. Clinician must always aware with other differential diagnosis of chest pain and ECG variation of acute pericarditis. TTE is a simple but important diagnostic tool to evaluate pericardial effusion as one of the diagnosis criteria for acute pericarditis.

Conflict of Interest

The author stated there is no conflict of interest

References

1. Cornily JC, Pennec PY, Castellant P, et al. Cardiac tamponade in medical patients: a 10-year follow-up survey. *Cardiology*. 2008;111(3):197-201.
2. Troughton RW, Asher CR, Klein AL. Pericarditis. *The Lancet*. 2004;363(9410):717-27.
3. Spodick DH. Acute pericarditis: current concepts and practice. *JAMA*. 2003;289(9):1150-3.
4. Masek KP, Levis JT. ECG diagnosis: acute pericarditis. *Perm J*. 2013;17(4):e146.
5. Imazio M, Spodick DH, Brucato A, Trincherio R, Markel G, Adler Y. Diagnostic issues in the clinical management of pericarditis. *Int J Clin Pract*. 2010;64(10):1384-92.
6. Khandaker MH, Espinosa RE, Nishimura RA, et al. Pericardial disease: diagnosis and management. *Mayo Clin Proc*. 2010;85(6):572-93.
7. Lange RA, Hillis LD. Clinical practice. Acute pericarditis. *N Engl J Med*. 2004;351(21):2195-202.
8. Adler Y, Charron P, Imazio M, et al. 2015 ESC Guidelines for the diagnosis and management of pericardial diseases: The Task Force for the Diagnosis and Management of Pericardial Diseases of the European Society of Cardiology (ESC) Endorsed by: The European Association for Cardio-Thoracic Surgery (EACTS). *European Heart Journal*. 2015;36(42):2921-64.
9. Imazio M, Bobbio M, Cecchi E, et al. Colchicine in addition to conventional therapy for acute pericarditis: results of the COLchicine for acute PERicarditis (COPE) trial. *Circulation*. 2005;112(13):2012-6.