

CASE REPORT

Diagnostic Challenge of Peritoneal Tuberculosis in Woman with Ascites

Nenci Siagian¹, Muhammad Vitanata Arfijanto^{2*}

¹Department of Internal Medicine, Faculty of Medicine Universitas Airlangga, Surabaya, Indonesia - Dr. Soetomo General Hospital Surabaya, Indonesia

²Division of Tropic and Infection, Department of Internal Medicine, Faculty of Medicine Universitas Airlangga, Surabaya, Indonesia - Dr. Soetomo General Hospital Surabaya, Indonesia

ARTICLE INFO

Article history:

Received 13 May 2020

Received in revised form 28 May 2020

Accepted 04 June 2020

Available online 30 June 2020

Keywords:

Peritoneal tuberculosis,
Ascites,
Adenosin deaminase.

*) Corresponding author:

maftuchah-r@fk.unair.ac.id

ABSTRACT

Tuberculosis (TB) is a major health global issue including extrapulmonary tuberculosis (EPTB). The one of manifestation of EPTB is peritoneal TB that constitutes 2% from all cases of pulmonary TB around the world. The diagnosis of peritoneal TB is quite challenging because many cases have symptom that similar to other diseases and those often necessary need further specific examinations such as PCR, culture and radiologic examination. We reported a case report of peritoneal tuberculosis in woman with ascites.

Introduction

Peritoneal TB is a peritoneum or visceral inflammation which is caused by *Mycobacterium tuberculosis*.¹ Most of Peritoneal TB results from pulmonary TB that can happen at any point after primary infection or occurs years or decades later because of the alteration of responsible immune response mechanism.¹ World Health Organization (WHO) estimates shows that globally there are 8.6 million incident cases of TB which is 80% are in 22 countries, extrapulmonary tuberculosis (EPTB) constitutes about 15 to 20 % of all cases of TB and more than 50 % of all cases of TB in HIV-positive patients.² Peritoneal tuberculosis constitutes 2% of all cases of pulmonary TB and 59.8% of all cases of abdominal TB.¹ Peritoneal TB is more common in woman than man, 1.5: 1, 3rd and 4th decade.¹

Peritoneal TB infection grows slowly and has non specific symptoms so that delay diagnosis and increase the morbidity and mortality.¹ Most of peritoneal TB do not have direct lung involvement and are more likely to have negative sputum smear results.² Ascites is one of common symptom of peritoneal TB that mimic to other disease such as cirrhosis hepatitis, autoimmune disease and malignancy.^{1,3,4} So that the diagnosis largely depends on more specific examination.² Therefore, we reported a case report of woman with ascites and other clinical signs of chronic disease and malignancy.

Case report

A 46-year old female presented with chief complain of swollen

abdomen since a month ago. She also complained about intermittent pain at the abdomen. In the last 2 months, she felt tired and weakness easily. It became worst since she couldn't eat because of nausea and vomit since a week ago. She also got fever since a month ago. There is no complain about the loss weight, chronic cough, night sweating. She said there is no problem with urinate, bowel habit and menstruation. She has no history of pulmonary TB, diabetes melitus, hypertension, liver and kidney disease before. Physical examination showed that her condition was weak, with blood pressure 100/60 mmHg, pulse 104 beats per minute, respiratory rate 24 times per minute, axillary temperature 37.7°C, weighed approximately 50 kgs, and her consciousness level was alert. Head and neck examination revealed the presence of anemic conjunctiva. Shifting dullness was positive in abdominal examination and pain VAS score was 1-2 on abdominal palpation. Based on history taking and physical examination, we did further laboratory (Table 1) and imaging examination. The results showed low haemoglobin (6.9 g/dL) with hypochromic and microcytic appearance, low albumin level (2.3 g/dL), negative hepatitis B and C marker, normal urine analysis and chest x-ray (figure1). Based on those data we planned to examine ascitic fluid and tumor marker. The patient was given PRC and albumin transfusion and symptomatic agent to reduce the complains.

On day 3, patient had severe vomiting and could not eat



and drink. From physical examination we found worsen abdominal swelling with meteorism and the pain scale increased. We decided to do decompression with nasogastric tube and lavement to reduce the intraabdominal pressure. The abdomen x-ray examination showed there is no signs of bowel obstruction (figure 2). The ascitic fluid analysis showed low serum ascites albumin gradient (SAAG), low total protein, low glucosa, high LDH dan mononuclear cell dominant without malignant cell. The tumor marker showed high Ca-125 level and normal CEA. Based on those datas we assesed the patient with suspect peritoneal TB so we planned to check adenosin deaminase (ADA) test from ascitic fluid and abdominal CT scan to confirm the diagnosis.

On day 5, the complain of vomiting became regressed and she could eat porridge. From physical examination the pain scale decreased. The result of ADA test was high (51.4 U/L ,with cut off 30 U/L) and abdominal CT scan showed lobulated fluid, extraluminal at abdominal and pelvic cavum, thickening bowel wall with contrast enhancement (figure 3). Based on those findings we diagnosed the patient with peritoneal TB. The patient was given first category of anti TB drug based on her weight for 9-12 months (2HRZE/10HR) and discharged 2 days later. The sign and symptoms revealed after six months of treatment.

Table 1. Laboratory Examination Result

Variable	On Admission	Day 3	Day 6
Blood			
Haemoglobin	6.9 g/dL	10.6 g/dL	
WBC	3790 / μ L	4800/ μ L	
Platelet	352000/ μ L	289000 / μ L	
Neutrophil	76.7 %	77.8%	
Lymphocyte	7.7%	7.5 %	
Erythrocyte Sedimentation Rate	60mm/h		
Blood glucose	128 mg/dL		
SGOT	46.0 U/L		
SGPT	25.0 U/L		
Ureum	11.0 mg/dL	35.0 mg/dL	17 mg/dL
Serum Creatinin	0,85 mg/dL	1.2 mg/dL	0.9 mg/dL
Albumin	2.3 g/dL	2.7 g/dL	
Sodium	133 mmol/L	139 mmol/L	
Potassium	3.7 mmol/L	4.5 mmol/L	
Chloride	97 mmol/L	100 mmol/L	
HbsAg	Non reactive		
Anti HCV	Non reactive		
Ascitic Fluid Analysis			
WBC-BF	0.22x103/ μ L		
RBC-BF	0.002x103 / μ L		
Total Protein	5.1 g/dL		
Glucose	75mg/dL		
LDH	263 μ L		
MN %	86.5%		
PMN%	13.5%		
Urine analysis			
Blood	Negative		
Leucocyte	++		
Nitrit	Negative		
Protein	Negative		
Glucose	Negative		
Ca-125		143.3 U/mL	
Cytology		Mononuclear cell dominant without malignant cell	
ADA test		51.4 U/L	

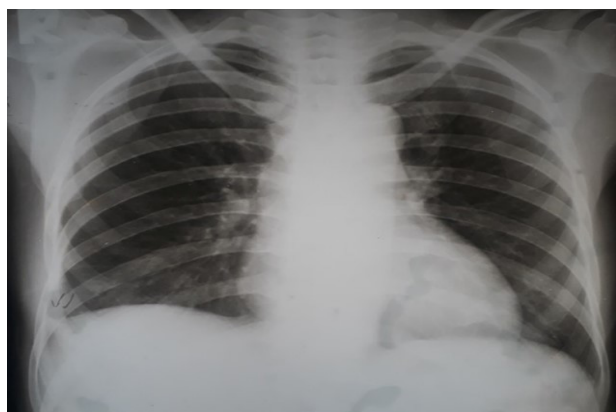


Figure 1. Chest x-ray of patient showed no sign of pulmonary tuberculosis

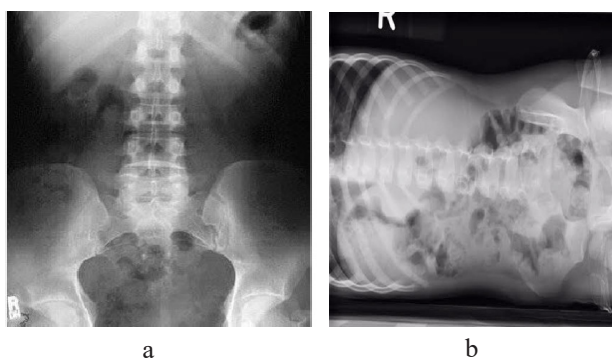


Figure 2. Abdominal x-ray: a.) supine and b.) left lateral decubitus showed no sign of bowel obstruction

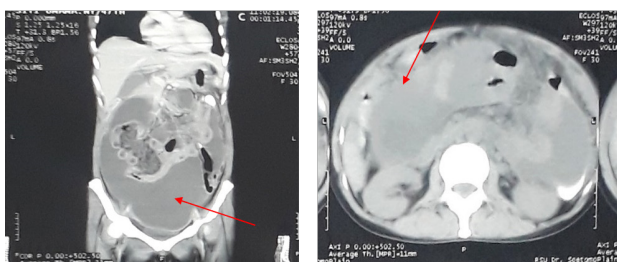


Figure 3. Abdominal CT scan showed extraluminal and loculated free fluid intensity, with contrast enhancement at abdomen cavity and pelvic cavity (arrow)

Discussion

Peritoneal TB is one of kind of abdominal TB that affect the parietal or visceral peritoneum.¹ Peritoneal TB results from the hematogenous and lymphatic spread of primary infection of *M. tuberculosis* bacilli.² Although this can happen at any point after primary infection, it most commonly occurs years or decades later, because the reactivation of latent focus of TB at peritoneum. That's why patients with peritoneal TB do not have direct lung involvement.² There are two conditions of peritoneal TB, acute and chronic.⁴ The acute condition shows acute abdomen signs and symptoms with or without ascites.⁴ The chronic condition has 3 types: (1) Wet type; patient comes with ascites, anorexia and weight loss (2) Encysted (loculated) type; patient comes with abdominal swelling at certain location (3) Fibrous type; patient comes with sign and symptom of ileus due to bowel attachment (chest board phenomenon).⁴ Abdominal swelling (65-100%), abdominal

pain (36-93%),^{4,5} anaemia (48-68%) and ascites on physical examination (51-100%)⁵ are common clinical presentation of peritoneal TB and can be found in other diseases such as malignancy, autoimmune and cirrhosis hepatis.^{1,3,4} On day 3, the patient had severe vomit likely because of the gastric outlet impairment due to ascites. But we have to always consider about ileus obstruction as a complication which could be happen anytime in this case.

Analysis and citology of ascitic fluid are very helpful to distinguish the type of ascites. The SAAG value less than 1.1 g/dL showed that the ascitic is non cirrhotic ascites. The glukosa ascites serum ratio less than 0.96 and total protein more than 2.5 g/dL may refer to tuberculosis infection. However those values have low sensitivity for diagnosis of peritoneal TB.^{1,4,6} The gold standard of peritoneal TB diagnosis is *M. tuberculosis* found in suspected specimen which is ascitic fluid.^{1,7} The studies reported that the sensitivity of zeihl neissen stain is 0-3%, the sensitivity of PCR examination is less than 5% and the sensitivity culture of *M. tuberculosis* is 35-50%.^{8,9} But the studies reported that ADA test has sensitivity and spesificity over than 90% (cut off 30-45U/L).¹⁰ ADA value is increased in tuberculous ascitic fluid because of the stimulation of T cells by the mycobacterial antigens. ADA activity in the peritoneal fluid has been proved to be a simple and reliable method for early diagnosis of tuberculous peritonitis.¹⁰ The tumor marker Ca-125 can be higher than normal in peritoneal TB so that Ca-125 can be used for treatment evaluation.¹¹

Ultrasonography (USG) is a routine examination for non cirrotic ascites but sometimes the result is less representative.¹² Abdominal CT scan has high diagnostic value for peritoneal TB such as loculated fluid in abdomen cavum (70-90%) or thickening peritoneal wall and contrast enhancement (70%).¹³ Laparoscopy is an invasive procedure and increase the risk of perforation however it performed in peritoneal TB with bowel adhesion that can lead to intestinal obstruction.¹⁴

The guideline of therapy of peritoneal TB in Indonesia is based on Ministry of Health regulator (PERMENKES) number 67 2016.¹⁵ Peritoneal TB is treated with anti tuberculosis drug first category for 9-12 months. The regimen consists of Rifampin 10mg/kg, Isoniazid 5mg/kg, Pyrazinamide 15mg/kgBB and Ethambutol 15mg/kg for 2 months and continue with Rifampicin 10mg/kgBB 3x/week and Isoniazide 5 mg/KgBB 3x/week for 7-10 months.¹⁵ The surgery procedure is needed for peritoneal TB with symptom of bowel obstruction, perforation and peritonitis. Surgery sometimes conducted if conservative treatment is failed.¹⁴ The prognosis of peritoneal TB is good as long as the patient gets adequate anti tuberculosis drug.¹

Conclusion

The diagnosis of extrapulmonary TB is still quite challenging in most of cases such as peritoneal TB. Peritoneal TB may shows ascites that similar to other disease like cirrosis hepatic or malignancy. It needs more spesific examination which is taken from suspicious location to find the *M. tuberculosis* to confirm the diagnosis. However in peritoneal TB, ADA test has higher sensitivity and specifity than zeihl neissen staining, GeneXpert and culture. The conservative therapy with anti tuberculosis drug is the main therapy for peritoneal TB.

However surgery procedure will be need if there is sign of acute abdomen due to bowel obstruction.

Conflict of Interest

The author stated there is no conflict of interest

References

1. Zain HL. Tuberkulosis Peritoneal. In: Buku Ajar Ilmu Penyakit Dalam Fakultas Kedokteran Universitas Indonesia. 2015
2. Purohit M, Mustafa T. Laboratory diagnosis of extra-pulmonary tuberculosis (EPTB) in resource-constrained setting: State of the art, challenges and the need. *J Clin Diagnostic Res.* 2015
3. Raviglione CM. Mycobacterial Diseases. in: Fauci AS, Braunwald E, Isselbacher KJ, Wilson JD, Martin JB, Kasper DL, et al., editors. *Harrison's Principles of Internal Medicine.* 19th ed. New York: McGraw-Hill;2015
4. Karanikas M, Porpodis K, Zarogoulidis P, Mitrakas A, Touzopoulos P, Lyratzopoulos N, et al. Tuberculosis in the Peritoneum: Not too Rare After All. *Case Report Gastroenterology.* 2012
5. Rathi P, Gambhire P. Abdominal Tuberculosis. *J Assoc Physicians India.* 2016
6. Tsao GG. Ascites. In: *Sherlock's Disease of the Liver and Biliary System.* 13th ed, Oxford: John Wiley&Sons Ltd; 2017
7. Chaudhuri A. Recent changes in technical and operational guidelines for tuberculosis control programme in India - 2016: A paradigm shift in tuberculosis control. *J Assoc Chest Physicians.* 2017
8. Mehta PK, Raj A, Singh N, Khuller GK. Diagnosis of extrapulmonary tuberculosis by PCR. *FEMS Immunol Med Microbiol.* 2012
9. Tewari M, Sahoo SP, Shukla HS. Abdominal Tuberculosis. In: *Tuberculosis,* 2nd ed, India. Jaypee Brothers Medical Publisher (p) Ltd; 2009
10. Lakkana Boonyagars SK. Use of Adenosine Deaminase for the Diagnosis of Tuberculosis: A Review. *J INFECT DIS ANTIMICROB AGENTS.* 2010;
11. Mas MR, Comert B, Saglamkaya U, Yamanel L, Kuzhan O, Ateskan U, et al. CA-125; a new marker for diagnosis and follow-up of patients with tuberculous peritonitis. *Dig Liver Dis.* 2000
12. Rosado E, Penha D, Paixao P. Abdominal Tuberculosis - Imaging Findings. *European Society of Radiology. ECR journal.* 2013;
13. Rocha EL da, Pedrassa BC, Bormann RL, Kierszenbaum ML, Torres LR, D'Ippolito G. Abdominal tuberculosis: a radiological review with emphasis on computed tomography and magnetic resonance imaging findings. *Radiol Bras.* 2015
14. Wyers SG, Matthews JB. Surgical Peritonitis and Other Diseases of the Peritoneum, Mesentery, Omentum, and Diaphragm. In: *Sleisenger and Fordtran's Gastrointestinal and Liver Disease.* 2010
15. Peraturan Menteri Kesehatan (PERMENKES) Republik Indonesia Nomor 67. 2016.