

ORIGINAL ARTICLE

Distribution Genotype High Risk (HR) And Low Risk (LR) Human Papillomavirus (HPV) at Condyloma Acuminata

Gondo Mastutik^{1*}, Alphania Rahniayu^{1,2}, Dwi Murtiastutik^{3,4}, Afria Arista³, Trisniartami Setyaningrum^{3,4}, Nabihah Missaoui^{5,6}, Suhartono Taat Putra¹

¹Department of Anatomy Pathology, Faculty of Medicine, Universitas Airlangga, Surabaya, Indonesia

²Department of Clinical Pathology, Faculty of Medicine, Universitas Airlangga, Surabaya, Indonesia - Dr. Soetomo General Academic Hospital Surabaya, Indonesia

³Departement of Dermatology and Venereology, Faculty of Medicine, Universitas Airlangga, Surabaya, Indonesia

⁴Departement of Dermatology and Venereology, Dr. Soetomo General Academic Hospital, Surabaya, Indonesia

⁵Assistant Professor in Cellular Biology, Kairouan University, Sciences and Technologies Faculty, Sidi Bouzid, Tunisia

⁶Researcher, Research Unit UR14ES17, Medicine Faculty, Sousse, University of Sousse, Tunisia

ARTICLE INFO

Article history:

Received 04 April 2021

Received in revised form 15 June 2021

Accepted 20 June 2021

Available online 30 June 2021

Keywords:

Condyloma acuminata,
HPV,
High Risk HPV,
Focus dysplasia,
Koilocytosis,
Sexually transmitted disease.

*) Corresponding author:

gondomastutik@fk.unair.ac.id

ABSTRACT

Introduction: Condyloma acuminata that is also known as genital warts are one of the most common sexually transmitted that caused by infection of Human papillomavirus (HPV). Persistent infection of Low Risk (LR) or High risk (HR) HPV is a risk factor for progress into benign or malignant cancer. The objective is to analyze distribution of genotype LR-HPV and HR-HPV at condyloma acuminata in anogenital region.

Methods: A cross sectional study using were 36 lesions from men and women of condyloma acuminata patients. All subject signed the informed consent and ethic obtained from our institution, number 382/Panke.KKE/V/2016. The specimen was used to histopathological examination and to identified 40 genotypes of HPV using a reverse line blot assay.

Results: The All patients were diagnosed as condyloma acuminata, some with focus dysplasia and koilocytosis. All patients were positive for HPV, including LR-HPV were HPV 6, 11, 42, 54, 61, 81,87,89 and HR-HPV were HPV 18, 26, 45, 51, 52, 66, 67, 68B, 69, 82. The single infection of LR-HPV was 44.4%, multiple infection LR/LR-HPV was 13,9% and the multiple infection of LR/HR-HPV was 41.7%. The LR-HPV infected 70,6% and HR-HPV infected 29,4%.

Conclusion: LR-HPV is the major infection of condyloma acuminata, in single infection or multiple infection with HR-HPV. The most common infections were HPV 11, followed by HPV 6, HPV 18, HPV 51, and HPV 82. The determination of genotype of HPV can be used to predict the malignant transformation.

Introduction

Condyloma acuminata that is also known as genital warts are one of the most common sexually transmitted diseases in the world.^{1,2} In United States, there were 500,000 to one million new cases diagnosed.² In Valencian community, Spain, it was estimated 612 cases of genital warts with overall incidence rate was 75.8 per 100,000 people per year.³ In the world base on systematic review study showed that the overall incidence of condyloma acuminata was 160-289 per 100,000 people per year. The new cases incidence of condyloma acuminata in males is 103-168 per 100,000

persons and in females is 76-191 per 100,000 persons. Incidence recurrent is 110 per 100.000 persons.⁴ The incidence new cases of condyloma acuminata in Bali, Indonesia during period 2015-2017 was 260 of 4743 persons (5.47%)⁵ and in Surabaya, Indonesia during 2009-2011 was 259 per 2,960 persons (8.7 %) and 2012-2014 was 318 per 3,674 persons (8.7%).⁶

Condyloma acuminata are usually found in warm and moist mucosal regions, that is characterized of skin in the region of anal and genital.^{1,4} It appears as flat lesion, dome-shaped, keratotic, pedunculated, or cauliflower shaped, which are single or cluster lesion.^{1,7} These are



accompanied by anogenital pruritus, burning, itching, vaginal discharge and bleeding. These lesions are visible on the peri genital and perianal region, including the penis, scrotum, vulva, pubic, perineal, perianal areas, crural folds.^{1,4,7}

The most common causes of condyloma acuminata is an infection by Human papillomavirus (HPV).⁸ There are more than 100 genotypes of HPV. Based on the ability to cause malignancy of HPV, the International Agency for Research on Cancer (IARC) have classified into high-risk (HR) (HPV 16, 18, 31, 33, 35, 39, 45, 51, 52, 56, 58, and 59), possibly HR (HPV 26, 30, 34, 53, 66, 67, 68, 69, 70, 73, 82, 85, 97), and probably low-risk (LR) (HPV 6, 11).^{9, 10} The LR-HPV such as HPV types 6, 11, 40, 42, 43, 44, 54, 61, 70, 72, and 81 are associated with causes of condyloma acuminata and un-oncogenic,¹¹⁻¹³ but study in China in 2013 showed that HR-HPV (HPV16, 52, 58, 56, 18, 66, 33) and LR-HPV (HPV 6, 11, and 43) caused condyloma acuminata.¹⁴ A prospective study to follow up 3,033 men with HPV infection during 12 months showed that infection with HPV 6 and HPV 11 developed to be condyloma acuminata and HPV 16 was to be penile intraepithelial neoplasia as precursor of penile cancer.¹⁵ A retrospective study was also showed that invasive penile cancer associated with infection of HR-HPV.¹⁶ These cases indicated that LR-HPV was co-infection with HR-HPV or single infection with HR-HPV that may lead to progression on malignancy on anogenital.

Approximately 30-40 percent of cases of condyloma acuminata will undergo spontaneous regression within in the first month of infection and some will be persistent infection.^{1,2,7} Persistent LR-HPV infection is a risk factor for epithelial lesions that manifest as benign hyperplasia, whereas HR-HPV infection increases the risk of developing premalignant lesions and is associated with cervical cancer in women.¹ The objective of this study is to analyze distribution of the genotype HR-HPV and LR at condyloma acuminata in anogenital region. This study identified 40 genotypes of HPV, including HR-HPV and LR from condyloma acuminata lesions in men and women using a reverse line blot assay.

Methods

This study was a cross sectional study conducted at Out clinic Patient of Department Dermatology and Venereology, Dr. Soetomo General Academic Hospital, Surabaya, Indonesia during period January-December 2017. The specimens were taken from patient after they sign the informed consent. Those who were not willing to participate in this study were excluded. This study was approved by the Medical Ethic Research from Dr. Soetomo General Academic Hospital Surabaya, number 382/Panke.KKE/V/2016.

The inclusion criteria of sample were all of patients diagnosed with condyloma acuminata using visual inspection by Dermatologist and willing to participate in this study by sign the informed consent. The exclusion criteria of patients were women in menstruation period or pregnant and cervicitis, women or men in infection HPV and AIDS.

There were 36 specimens of the biopsy tissues taken from lesion patient who diagnosed as condyloma acuminata. The specimen was separated become

two sections; one section is for tissues processing in block paraffin as procedure for making histopathology diagnose. The histopathology diagnosed of condyloma acuminata performed by Expert Pathologist. The other section is for genotyping HPV.

The genotyping of HPV was performed by Polymerase Chain Reaction (PCR) and followed by reverse line blot assay. DNA virus was extracted from specimen of condyloma acuminata by using QIAamp DNA Mini Kit (Qiagen) and genotyping of HPV was using Ampliquality HPV type express v 3.0 (AB Analitica) according to the manufacture's protocol that identified 40 genotypes of HPV.

Results

Histopathology Diagnose

The results of histopathology diagnose showed that all patients were diagnosed as condyloma acuminata. Some specimens showed condyloma acuminata with focus dysplasia and koilocytosis which specific for HPV infected cells (Figure 1)

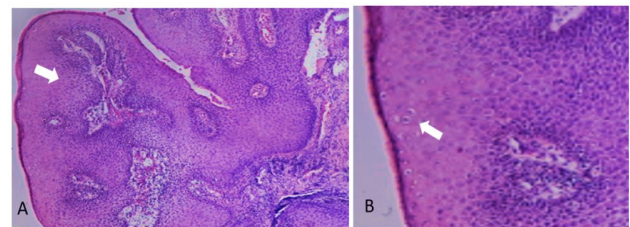


Figure 1. Histopathology of condyloma acuminata in anogenital with hematoxylin eosin (HE) staining. Arrow indicated the focus dysplasia (in figure A) and koilocytosis (in figure B)

Distribution Genotype of LR-HPV and HR-HPV at the condyloma acuminata patients

A total of 36 the condyloma acuminata patients participated in this study, including 15/36 (41.67%) for male and 21 (58.33%) for female, aged 18-64 years old. In 15 males, showed that 6/36 (16.67 %) were positive infected by multiple type HR-HPV/LR and 9/36 (25%) were positive infected by single and multiple infection LR-HPV/LR. In female, 8/36 (22.22%) were positive infected by multiple type HR-HPV/LR and 13 (36.11%) were positive infected by single and multiple infection LR-HPV/LR. The most patients of aged was 15-24 years old that were 7/36 (19.44%) positive infected by HR-HPV and 10/36 (27.79%) by LR-HPV (Table 1).

Table 1. Characteristic of the condyloma acuminata patients

Characteristic	N (%)
Sex	
Male	15 (41.67)
Female	21 (58.33)
Age	
15-24 years	17 (47.22)
25-34 years	6 (16.67)
35-44 years	8 (22.22)

45-54 years	4 (11.11)
55-64 years	1 (2.78)
Duration presence of each warts	
< 1 month	5 (13.89)
1-3 month	23 (63.89)
4-6 month	6 (16.67)
>6 month	2 (5.56)
Type lesion	
Solitary	2 (5.56)
Multiple	34 (94.44)
History of previous lesions	
First time lesions	29 (80.56)
Recurrence lesions	7 (19.44)
Location of lesions	
Penis	7 (19.44)
Anus	6 (16.67)
Penis and Anus	2 (5.56)
Labia (Majora and Minora)	15 (41.67)
Vulva	3 (8.33)
Introitus Vagina	2 (5.56)
Perineum	1 (2.78)

The genotype of HPV was HR-HPV and LR-HPV, in single infection of LR-HPV, multiple infection of LR/LR-HPV, or multiple infection of LR/HR-HPV. The genotypes of LR-HPV in this study were HPV 6, 11, 42, 54, 61, 81,87,89 and HR-HPV were HPV 18, 26, 45, 51, 52, 66, 67, 68B, 69, 82. The single infection of LR-HPV was 44.4%, multiple infection of LR/LR-HPV was 13,9% and the multiple infection of LR/HR-HPV is 41.7% (Table 2).

Table 2. Single and multiple infection of HPV in the condyloma acuminata patients

Genotype HPV	Type HR or LR	N (%)
Single infection		16 (44.4)
HPV 6	LR	4 (11.1)
HPV 11	LR	12 (33.3)
Multiple infection LR/LR-HPV		5 (13.9)
HPV 6, 11	LR/LR	2 (5.5)
HPV 6, 61	LR/LR	1 (2.8)
HPV 6,81,87,89	LR/LR/LR/LR	1 (2.8)
HPV 11,87	LR/LR	1 (2.8)
Multiple infection LR/HR-HPV		15 (41.7)
HPV 6, 11,18,51,82	LR/LR/HR/HR/HR	1 (2.8)
HPV 6, 42,51,61	LR/LR/HR/LR	1 (2.8)
HPV 11, 18	LR/HR	2 (5.5)
HPV 11,18,45	LR/HR/HR	1 (2.8)
HPV 11, 26	LR/HR	1 (2.8)

HPV 11, 51	LR/HR	1 (2.8)
HPV 11, 51, 82	LR/HR/HR	1 (2.8)
HPV 11, 52, 54	LR/HR/LR	1 (2.8)
HPV 11, 52,69,90	LR/HR/HR/LR	1 (2.8)
HPV 11, 66	LR/HR	1 (2.8)
HPV 11, 67	LR/HR	1 (2.8)
HPV 11, 68B	LR/HR	1 (2.8)
HPV 11, 82	LR/HR	2 (5.5)

The frequency of HPV 11 infected 28 per 68 times (41.18%), HPV 6 infected 11 per 68 times (16.18%), and HPV 18, 51 and 82 respectively infected 4 per 68 times (5.88%). The frequency of LR-HPV infected in 48/68 (70,6%) and HR-HPV infected in 20/68 (29,4%). The most common LR-HPV were HPV 11 and HPV 6, and HR-HPV were HPV 18, HPV 51, and HPV 82 (Table 3).

Table 3. The most often of HPV genotype found at the condyloma acuminata patients

Genotype HPV	N (%)
HPV 11	28 (41.18)
HPV 6	11 (16.18)
HPV 18	4 (5.88)
HPV 51	4 (5.88)
HPV 82	4 (5.88)
HPV 52	2 (2.94)
HPV 61	2 (2.94)
HPV 87	2 (2.94)
Other type (HPV 26, 42, 45, 66, 67, 81, 54, 68B, 69, 89, 90)	11 (16.18)

Discussion

Condyloma acuminata or anogenital warts are single or multiple lesions, soft or raised masses that appears as smooth, verrucous or lobulated, with flat, dome-shaped, cauliflower shaped, or pedunculated, filiform, fungating, plaque-like in anogenital regions.^{2,17} Histopathology features can be observed by hematoxylin-eosin (HE) that showed papillomatosis, hyperkeratosis, parakeratosis, hypergranulosis, and koilocyte, as well as some showed focus dysplasia. The papillary dermis presented dilated capillaries.^{17,18,19} These microscopic appearances were also seen on the HE slides in this study, where several slides showed papillomatosis, hyperkeratosis, with focus dysplasia and koilocytosis.

The age of people with condyloma acuminata in this study peaked at the age of 15-24 years, namely 47.2% and those were under 35 years of 23/36 (63.9%). This was in accordance with others studies showed that condyloma acuminata patients usually occurred at the sexually active age, namely 15-24 years.^{2, 20} The highest prevalence of condyloma acuminata was around the age of 20-30 years, in female or male patients.^{4, 21}

We found that there were 6 patients who showed histopathological results of condyloma acuminata with focus dysplasia. The presentation of dysplasia base on the histopathological finding was associated with

increased infection of HPV 16 and HPV 18, while the rounded papillomatosis, hypergranulosis, and dilated vessels were associated with HPV 6 and HPV 11.¹⁹ The ages of these patients were 20, 22, 26, 42, and 44 years old and infected with HR-HPV and LR-HPV were each 3 patients. Patients diagnosed as condyloma acuminata with a focus on dysplasia and infected by HR-HPV should be monitored to determine the progression of the disease to malignancy.

This study identified 40 genotypes of HPV. There were HPV type 6, 11, 16, 18, 26, 31, 33,35, 39, 40, 42, 43, 44, 45, 51, 52, 53, 54, 55, 56, 58, 59,61, 62, 64, 66, 67, 68a, 68b, 69, 70, 71, 72, 73, 81, 82, 83,84, 87, 89, and 90. Identification HPV genotype is very important to predict the progression of the diseases, to be benign lesion or malignant lesion in anogenital region. In addition, it can also provide a more complete management of the patient. Without knowing these types of HPV genotypes, the management of condyloma acuminata in patients is limited to removing the lesions.

From 36 specimen condyloma acuminata, including male and female, we found all of specimens was positive for HPV. There were a group of LR-HPV including HPV 6, 11, 42, 54, 61, 81,87, 89 and a group of HR-HPV including HPV 18, 26, 45, 51, 52, 66, 67, 68B, 69, 82. Other study showed that form 879 patients with genital warts, including 512 men and 367 women, showed LR-HPV were HPV6, 11, 42, 43 and 81 and HR-HPV were HPV16, 18, 31, 33, 35, 39, 45, 51, 52, 53, 56, 58, 59, 66, 68, 73, 82 and 85).²²

Condyloma acuminata is a benign tumor that the most often to be caused by infection of LR-HPV and some is co-infection with HR-HPV. The single infection of LR-HPV in this study was 16/36 (44.4%), multiple infection of LR-HPV and LR-HPV was 5/36 (13.9%) and the multiple infection of LR-HPV and HR-HPV was 15/36 (41.7%). This study was in accordance with other study. Single infection in condyloma acuminata patients in Peking China showed that there was 1.453/3.288 (44.19%) of LR-HPV and HR-HPV was 945/3.288 (28.74%), multiple infection of HR-HPV/LR was 890/3.288 (27.07%).¹⁴

LR-HPV infection in the anogenital area was associated with benign tumors and HR-HPV infection was associated with a risk of malignancy. LR-HPV (HPV 6,11) were related to condyloma acuminata.¹³ A prospective study to follow up 3.033 men with HPV infection during 12 months showed that infection with HPV 6 and HPV 11 developed to be condyloma acuminata.¹⁵ The HR-HPV (HPV 16, and HPV 18), were the most related with cervical cancer and precancer lesions in women such as cervical, vaginal, and vulvar intraepithelial neoplasias and high-grade squamous intraepithelial lesions.¹⁹ In addition, HR-HPV was considered as causes of squamous cell carcinomas and associated precursor lesions in men as penile intraepithelial neoplasia, Bowenoid papulosis, Erythroplasia of Queyrat),¹⁹ as well as related with invasive penile carcinomas.¹³ Follow up infection HPV 16 in male was to be penile intraepithelial neoplasia as precursor of penile cancer.¹⁵ Other study was also reported that condyloma acuminata was associated

with the risk of cancer in anogenital. A cohort study involving 10,971 patients (1,685 men and 9,286 women) in Swedish population concluded that condyloma acuminata was strongly associated with increasing the risk of cancer in anogenital, such as vulva, penis, and anus.²³

The most dominant infection in the condyloma acuminata was infection of HPV 6 and 11. Condyloma acuminatum or venereal/genital warts referred to benign proliferative epidermal or mucosal lesions attributed mostly to HPV type 6 or 11, but co-infections with HR-HPV types are frequent.¹⁷ In this study, the most common LR-HPV in condyloma acuminata was HPV 11 (41.18%), HPV6 (16.18%) and HR-HPV was HPV 18 (5.88%), 51 (5.88%) and 82 (5.88%). Other study showed that the most common LR-HPV and HR-HPV in condyloma acuminata were in French LR-HPV was 6 (69%) and 11 (16%), followed by HR-HPV were 16 (9%), 51 (8%), 52 (7%), 66 (6%) 53 (5%), 31 (3%), and 18 (3%).²⁰ In Peking, China showed that LR-HPV were HPV 6 (16.98%), 11 (11.09%) and 43 (6.75%), and HR-HPV were 16, 52, 58, 56, 18, 66 and 33, and the incidence ratios were 6.31%, 5.06%, 4.04%, 2.60%, 2.41%, 2.40% and 2.28% in condyloma acuminata.¹⁴ In Xi'an China HPV LR was HPV6 (24.9%), HPV11 (17.9%), HPV52 (9.9%) and HR-HPV was HPV16 (7.3%).²² The estimated prevalence of HPV 6 and HPV 11 DNA in the US male population were 2.9%.²⁴ The common HR-HPV in men with condyloma acuminata was HPV 16 and followed by HPV 18.²⁵ Our previous study showed that the most common HPV infected in men with condyloma acuminata was LR-HPV were HPV 6, HPV 11 and HR-HPV were HPV 18, 51, 52, 82 26 and in cervical precancerous lesion and squamous cell carcinoma were is HPV 16 (62.68%), then followed by HPV 18 (20.9%), HPV 45 (5.97%), 52 (5.97%), and 67 (4.48%).²⁷

However, condyloma acuminata is usually caused by LR-HPV infection, this finding demonstrated that LR-HPV co-infection with HR-HPV. HR-HPV such as HPV 16, HPV 18, HPV 45, HPV 52, and 67 was HPV have been founded in cervical cancer and precancerous lesion.²⁷ Several other studies have also shown that HPV 16, as well as LR-HPV (HPV 6 and 11) were also found in penile intraepithelial neoplasia.⁸ HPV 16 and HPV 18 were founded on vulval and vaginal cancer cell.²⁸ Persistent infection of HR-HPV is a risk factor for progression of cell transformation into malignant cells. The determination of genotype HPV, including HR-HPV can be used to predict the malignant transformation of condyloma acuminata into invasive cancer in the anogenital area and also to establish a preventive program by vaccination.

Conclusion

This finding demonstrated that LR-HPV is the major infection of condyloma acuminata, in single infection or multiple infection with HR-HPV. The most common infections were HPV 11, followed by HPV 6, HPV 18, HPV 51, and HPV 82. The determination of HR-HPV can be used to predict the malignant transformation of condyloma acuminata into invasive cancer in the

anogenital area and to establish a preventive program by vaccination.

Acknowledgement

We would like to thank to the Government of the Republic of Indonesia, the Ministry of Research, Technology, and Higher Education, in particular the Faculty of Medicine, Airlangga University for financial support and all of the patients who are willing to participate in this study.

Conflict of Interest

The author stated there is no conflict of interest

References

- Santegoets LA, van Baars R, Terlou A, et al. Different DNA damage and cell cycle checkpoint control in low- and high-risk human papillomavirus infections of the vulva. *Int J Cancer*. 2012; 130: 2874-85.
- Yanofsky VR, Patel RV, Goldenberg G. Genital warts: a comprehensive review. *J Clin Aesthet Dermatol*. 2012; 5: 25-36.
- Navarro-Illana E, López-Lacort M, Navarro-Illana P, et al. Effectiveness of HPV vaccines against genital warts in women from Valencia, Spain. *Vaccine*. 2017; 35: 3342-6.
- Patel H, Wagner M, Singhal P, et al. Systematic review of the incidence and prevalence of genital warts. *BMC Infect Dis*. 2013; 13: 39-53.
- Puspawati NMD, Sissy, Gotama D. A retrospective study of condyloma acuminata profile in outpatient clinic of dermatovenereology Sanglah General Hospital Denpasar, Bali-Indonesia period 2015-2017. *Bali Dermatology and Venereology Journal*. 2018; 1: 1 3.
- Oktaviyanti RN, Barakbah J. Profil Pasien Kondiloma Akuminata (The Profile of Condyloma Acuminata) Berkala Ilmu Kesehatan Kulit dan Kelamin-Periodical of Dermatology and Venereology. 2018; 30: 240-7.
- Wiley DJ, Douglas J, Beutner K, et al. External Genital Warts: Diagnosis, Treatment, and Prevention. *Clinical Infectious Diseases*. 2002; 35: S210-24.
- Ingles DJ, Campbell CMP, Messina JA, et al. Human papillomavirus virus (HPV) genotype- and age-specific analyses of external genital lesions among men in the HPV Infection in Men (HIM) Study. *J Infect Dis*. 2015; 211: 1060-7.
- Bouvard V, Baan R, Straif K, Grosse Y, Secretan B, El Ghissassi F, Benbrahim-Tallaa L, Guha N, Freeman C, Galichet L, Cogliano V; WHO International Agency for Research on Cancer Monograph Working Group. A review of human carcinogens--Part B: biological agents. *Lancet Oncol*. 2009; 10: 321-2
- Arbyn M, Tommasino M, Depuydt C, et al. Are 20 human papillomavirus types causing cervical cancer?. *J Pathol*, 2014; 234: 431-5
- Braaten KP, Laufer MR. HPV related disease, and the HPV vaccine. *Rev Obstet Gynecol* 2008; 1: 2-10.
- Xicotencatl LG, Torres TP, Gonzalez CL, et al. Molecular diagnosis of human papillomavirus in the development of cervical cancer. *Salud Publica Mex*. 2009; 51: S479-88.
- Szymonowicz KA, Chen J. Biological and clinical aspects of HPV-related cancers. *Cancer Biol Med*. 2020; 15: 864-78.
- Lu LH, Yu J, Zhang YH, et al. HPV Infection and Distribution of HPV Genotypes on Patients with Condyloma Acuminatum, *Journal of Reproduction and Contraception*. 2014. 25: 26-31.
- Sudenga SL, Ingles DJ, Campbell CMP, et al. Genital Human Papillomavirus Infection Progression to External Genital Lesions: The HIM Study. *Eur Urol*. 2016; 69: 166-73.
- Nielson CM, Harris RB, Dunne EF, et al. Risk factors for anogenital human papillomavirus infection in men. *J Infect Dis*. 2007; 196: 1137-45
- Léonard B, Kridelka F, Delbecq K, et al. A clinical and pathological overview of vulvar condyloma acuminatum, intraepithelial neoplasia, and squamous cell carcinoma. *Biomed Res Int*. 2014; 2014: 480573.
- Veasey JV, Framil VM, Nadal SR, et al. Genital warts: comparing clinical findings to dermatoscopic aspects, in vivo reflectance confocal features and histopathologic exam. *An Bras Dermatol*. 2014; 89: 137-40.
- Vyas NS, Campbell CMP, Mathew R, et al. Role of histological findings and pathologic diagnosis for detection of human papillomavirus infection in men. *J Med Virol*. 2015; 87: 777-87.
- Aubin F, Prétet JL, Jacquard AC, et al. Human papillomavirus genotype distribution in external acuminata condylomata: a Large French National Study (EDiTH IV). *Clin Infect Dis*. 2008; 47: 610-5.
- Dareng EO, Adebamowo SN, Famooto A, et al. Prevalence and incidence of genital warts and cervical Human Papillomavirus infections in Nigerian women. *BMC Infect Dis*. 2019; 19: 27.
- Zhu C, Wang Y, Mao W, et al. Prevalence and distribution of HPV types in genital warts in Xi'an, China: a prospective study. *BMJ Open*. 2019; 9: e023897.
- Nordenvall C, Chang ET, Adami HO, et al. Cancer risk among patients with condylomata acuminata. *Int J Cancer*. 2006; 119: 888-93.
- Daugherty M and Byler T. Genital Wart and Human Papillomavirus Prevalence in Men in the United States From Penile Swabs: Results From National Health and Nutrition Examination Surveys. *Sexually Transmitted Diseases*. 2018; 45: 412-16.
- Iorga L, Dragos RM, Cristina CD, et al. Penile carcinoma and HPV infection (Review). *Exp Ther Med*. 2020; 20: 91-96.
- Murtiastutikn D, Mastutik G, Rahniayu A, et al. The Genotype of Human Papilloma Virus of Male Patients with Anogenital Warts. *Folia Medica Indonesiana*. 2019; 55: 100-6.
- Mastutik G, Alia A, Rahniayu A, et al. Genotype Human Papillomavirus in Cervical Precancerous Lesion and Squamous Cell Carcinoma at Dr Soetomo Hospital Surabaya. *African Journal of Infectious Diseases*. 2018; 12(S): 7-12.
- Ngamkham J, Boonmark K, Phansri T. Detection and Type-Distribution of Human Papillomavirus in Vulva and Vaginal Abnormal Cytology Lesions and Cancer Tissues from Thai Women. *Asian Pac J Cancer Prev*. 2016; 17: 1129-34.