

## CASE REPORT

# Diagnostic and Management Problems of a Patient with Severe Life-Threatening Acute Hypocalcemia: A Case Report

Arvin Wiranata Lianto<sup>1\*</sup>, Birgita Maria Ratu Rosari Bas<sup>1</sup>, Robert Dwitama Adiwinoto<sup>2</sup>, Libriansyah<sup>2</sup>

<sup>1</sup>Dr. Ramelan Naval Hospital, Surabaya, Indonesia

<sup>2</sup>Division of Endocrinology, Diabetes, and Metabolism, Department of Internal Medicine, Dr. Ramelan Naval Hospital, Surabaya, Indonesia

## ARTICLE INFO

### Article history:

Received 5 February 2022

Received in revised form 14 March 2022

Accepted 15 April 2022

Available online 28 April 2022

### Keywords:

Hypocalcemia,

Tetany,

Vitamin D deficiency,

Phenytoin

\*) Corresponding author:

arvinwiranatalianto@gmail.com

## ABSTRACT

Hypocalcemia is a common electrolyte disorder. Acute hypocalcemia is a life-threatening condition that needs prompt evaluation and management. We present a case of a 54-year-old woman presented to emergency room with muscle spasm and involuntary movement. Upon physical examination, the patient was disoriented and the Trousseau's sign was bilaterally positive when the cuff was inflated. Blood test revealed severe hypocalcemia with albumin-corrected serum total calcium levels 1.77 mg/dL. Following extensive diagnostic workups, there were no alternative explanations other than vitamin D deficiency. Despite aggressive intravenous (IV) calcium correction and high-dose vitamin D supplementation the calcium levels gradually decreased and neurological symptoms relapsed. The use of phenytoin to treat neurological symptoms decreased calcium levels further. The patient was eventually discharged with oral calcium and calcitriol supplementation with minimal symptoms. This case highlights the importance of thorough diagnostic workups and judicious use of anticonvulsant drugs in hypocalcemia for optimal treatment outcome.

## Introduction

Hypocalcemia is a common electrolyte disorder, but the diagnosis requires a high clinical suspicion index by the clinician. The clinical manifestations of hypocalcemia are variable, as the low serum calcium levels may impair any organ function. Acute, new onset hypocalcemia may represent a life-threatening situation requiring immediate intervention, while chronic reduction in serum calcium levels is sometimes asymptomatic or slightly symptomatic.<sup>1</sup> It is usually defined as corrected serum total calcium levels < 8.5 mg/dL, taking serum albumin levels into account. Disorders causing hypocalcemia can be divided into parathyroid hormone (PTH) and non-PTH mediated. Several organs (kidneys, liver, skeleton, gut) and vitamin D metabolism play a major role in non-PTH mediated cases.<sup>2,3</sup>

In all cases, the evaluation of the causes by diagnostic workup and management of hypocalcemia are essential and need to be addressed simultaneously. The goal of treatment is to replenish serum calcium to the normal range, to resolve or minimize symptoms.<sup>4</sup> When the etiology of hypocalcemia is known, management of the underlying disorder is important for optimal therapy. Vitamin D deficiency should be corrected

with vitamin D supplementation. In practice, vitamin D deficiency is defined as serum 25-hydroxyvitamin D (25(OH)D) concentrations <10 ng/mL, while vitamin D insufficiency is defined as serum 25(OH)D concentrations 11 – 20 ng/mL.<sup>5</sup> Currently, 25(OH)D levels below 20 ng/mL, with resultant consistent elevation of PTH are considered indicative of vitamin D deficiency.<sup>6</sup> Vitamin D deficiency or insufficiency may result from inadequate sunlight exposure, malabsorption, and certain medications that impair vitamin D metabolism.<sup>2,7,8</sup>

Here we report the case of a patient with new-onset severe acute hypocalcemia associated with vitamin D deficiency who developed treatment-resistant hypocalcemia during the course of hospitalization. We also described our diagnostic approach and clinical management.

## Case Report

A 52-year-old female with no medical history was admitted to the emergency department after a road traffic accident. She was the driver of a motorcycle involved in an intersection collision with another motorcycle. Physical examination showed the patient was alert with Glasgow coma score (GCS) score 15, pulse 100 beats per minute, respiratory rate



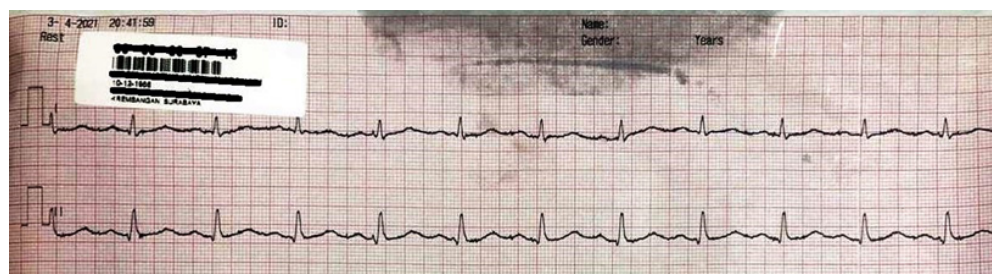
22 times per minute, axillary temperature 36.5°C, weighed approximately 65 kgs. With a visual analogue scale (VAS) of 6, she experienced significant discomfort across her left flank. The initial management was in line with the Advanced Trauma Life Support (ATLS) protocol.

Gross hematuria was detected when the urethral catheter was placed. Furthermore, no further injuries were discovered during the tertiary survey. Microscopic hematuria was discovered with moderately increased.

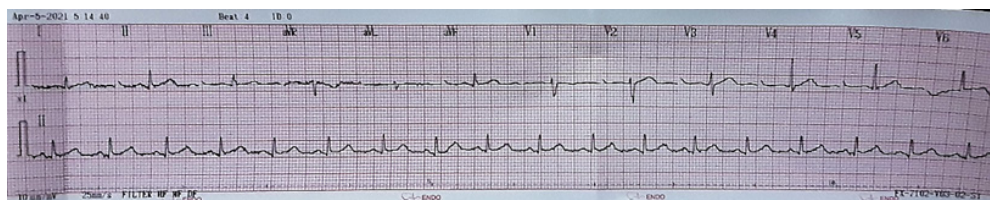
The following days, the patient underwent several diagnostic workups to investigate the etiology of hypocalcemia. Serum intact PTH levels was ordered and revealed high-normal levels (57.8 pg/mL). Serum magnesium (Mg) was within normal limit (2.2 mg/dL). Thyroid function test was also within normal limit. A contrast-enhanced computed tomography (CT) scan of abdomen was obtained to exclude acute abdominal events. Skeletal survey did not reveal any lesions. Neck ultrasonography was performed with normal results. 24 hours urinary calcium excretion was normal. Serum 25(OH)

D levels was decreased (13.9 ng/mL), indicating vitamin D insufficiency status. The diagnostic findings and normal range were described in table 1.

Over the following days, total serum calcium levels gradually decreased, despite aggressive IV calcium correction and high-dose vitamin D supplementation (10,000 IU oral calcitriol daily). Meanwhile, the neurologic symptoms relapsed as the patient complained about bothersome twitching in the lower legs. In light of these findings, phenytoin regimen was initiated (100 mg IV phenytoin diluted in normal saline, 3 times daily) upon consultation with neurology. However, calcium and 25(OH)D levels did not substantially increase to normal range levels, therefore phenytoin was stopped. The progression of mineral metabolism parameter was presented in table 2. The patient was eventually discharged after 3 weeks of admission with a prescription for oral calcium lactate 1,500 mg daily in divided dose and oral calcitriol 10,000 IU daily with improvement neurologic symptoms.



(A)



(B)

Figure 1. Electrocardiogram showed markedly prolonged QT interval at admission (A) and improvement after calcium replenishment (B)

**Table 1. Laboratory results and normal range for tested parameters**

Parameter	Result	Normal range
Calcium	0.90 mg/dL	8.60-10.30 mg/dL
Albumin	2.91 g/dL	3.40-5.40 g/dL
Phosphate	3.10 mg/dL	3.00-4.50 mg/dL
Serum creatinine	0.80 mg/dL	0.60-1.30 mg/dL
AST	42 U/L	0-35 U/L
ALT	25 U/L	0-37 U/L
Intact PTH	57.80 pg/mL	15-65 pg/mL
Magnesium	2.20 mg/dL	1.90-2.50 mg/dL
TSHs	5.35 $\mu$ IU/mL	0.35-5.10 $\mu$ IU/mL
T4	7.04 ng/mL	5.13-14.06 ng/mL
T3	0.63 $\mu$ g/dL	0.84-2.02 $\mu$ g/dL
24-h urinary calcium	101.30 mg	100-250 mg
25(OH)D	13.90 ng/mL	30-80 ng/mL

Table 2. Mineral metabolism parameters upon admission and after treatment

Parameter	At admission	24-hour of treatment	1st week of treatment	2nd week of treatment	3rd week – discharged
Calcium (mg/dL)	0.90	8.90	6.60-8.40	8.10	8.70-7.90
25(OH)D (ng/mL)	-	-	13.90	-	-
Intact PTH (pg/mL)	-	-	57.80	21.80	-

## Discussion

Because of the variable clinical manifestations of hypocalcemia, the clinician must have a high clinical suspicion index to make the diagnosis. The characteristic neurologic manifestation of hypocalcemia is tetany, a condition caused by increases in peripheral neuromuscular irritability.<sup>9</sup> Tetany symptoms can range from mild to severe (perioral numbness, paresthesias in the hands and feet, muscle cramps) (carpopedal spasm, laryngospasm, and focal or generalized seizures, which must be distinguished from the generalized tonic muscle contractions that occur in severe tetany). Other patients experience less specific symptoms such as fatigue, hyperirritability, anxiety, and depression, and some patients, even those with severe hypocalcemia, do not experience neuromuscular symptoms. Tetany is defined electromyographically as a series of repetitive, high-frequency discharges following a single stimulus. The most important pathophysiologic effect of hypocalcemia is probably hyperexcitability of peripheral neurons, but hyperexcitability occurs at all levels of the nervous system, including motor endplates, spinal reflexes, and the central nervous system. Low ionized calcium levels in the extracellular fluid increase the permeability of neuronal membranes to sodium ion, causing a progressive depolarization, which increases the possibility of action potentials.<sup>10</sup> Our patient presented to the emergency room with difficulty of swallowing solid and liquid food because of pharyngeal muscle spasm. Although the patient already complained of twitching and involuntary movements, the Trousseau's sign elicited when the blood pressure cuff applied prompted the evaluation of calcium levels.<sup>11</sup>

The investigation of the underlying disorder by diagnostic workups is important for achieving optimal outcome in hypocalcemic patients. According to Pepe et al., investigation of hypocalcemia should begin with thorough evaluation of medical, familial, pharmacological history to exclude any drug inducing hypocalcemia and genetic syndromes causing hypocalcemia.<sup>2</sup> No obvious past illness or any significant medications (diuretics, anticonvulsants) recorded from medical history. A contrast-enhanced abdominal CT scan also excluded acute pancreatitis as the cause of acute hypocalcemia in our patient.<sup>12</sup> Therefore, the investigation proceeded to laboratory workups.<sup>13</sup> The first order of investigation in evaluating hypocalcemia was: renal function test, serum magnesium, phosphate, and intact PTH levels. Our patient renal function test, serum magnesium, and phosphate levels were normal. The intact PTH levels, however, was in the upper-normal range (57.8 pg/mL) this might be a response to the severe drop in serum calcium levels.

The final step in investigating hypocalcemia is to

measure serum 25(OH)D levels.<sup>2</sup> Our patient serum 25(OH)D levels was 13.9 ng/mL, indicating vitamin D insufficiency. However, serum 25(OH)D levels below 20 ng/mL, with resultant consistent elevation of PTH as seen in this present case might be considered as vitamin D deficiency.<sup>6</sup> The possibility of vitamin D deficiency in this patient was also supported by the lower normal levels (101.3 mg) of 24-hour urine calcium excretion finding. Vitamin D deficiency may result from inadequate sunlight exposure, malabsorption, and certain medications that impair vitamin D metabolism. Normal skeletal survey from bone radiograph excluded skeletal disorders (osteomalacia).<sup>14</sup> While we had not fully investigated the probability of vitamin D malabsorption in this present case we strongly suspected malabsorption as the underlying disorder of vitamin D deficiency. Nevertheless, treatment should be initiated irrespective of the cause, according to the algorithm (figure 2) in the management of the adult with vitamin D deficiency.<sup>15</sup>

Calcium supplementation with the goal to replenish serum calcium to the normal range is important in the acute setting. Intravenous calcium solutions are hyperosmolar and should be administered through a large central vein, whenever possible. One gram of calcium gluconate contains 93 mg of elemental calcium, therefore 100-300 mg of elemental calcium (1-3 g calcium gluconate) in 100 mL dextrose over 10 min infusion followed by continuous infusion of 0.5-1.5 mg of elemental calcium/kg per hour is a rational approach.<sup>2</sup> Due to the presence of vitamin D deficiency, a supplementation with oral calcitriol 2000 IU daily is recommended for serum 25(OH)D levels 12-20 ng/mL along with calcium replenishment.<sup>6</sup> We give our patient a larger dose supplementation with oral calcitriol 10.000 IU daily in divided dose because of the possibility of malabsorption. Some medications such as phenytoin, phenobarbital, and rifampicin can induce hepatic p450 enzymes and accelerate metabolism of vitamin D.<sup>15</sup> Considering some of the aforementioned drugs might be used in practice to treat the neurological manifestations of hypocalcemia, judicious use of anticonvulsants is essential in managing hypocalcemic patient.<sup>12</sup> The calcium levels in this patient decreased when phenytoin regimen (IV loading and oral dose) was given to treat the neurological symptoms might be due to increased catabolism of vitamin D. Therapy with standard anticonvulsants is ineffective and may even exacerbate these seizures (by an anti-vitamin D effect). Because of that, the best treatment for patient with acute severe hypocalcemia is intravenous calcium solutions and continued with oral calcitriol until the symptoms have cleared.

---

**Conclusion**

Hypocalcemia might present with various clinical manifestations. The presence of tetany should raise the awareness of a physician for prompt calcium levels evaluation. Whenever available, serum 25(OH)D levels should be obtained in the case of acute hypocalcemia. Antiepileptic drugs should be used with caution in treating the neurological symptoms of hypocalcemia associated with vitamin D deficiency, as it may increase catabolism of vitamin D. Therapy with standard anticonvulsants is ineffective and may even exacerbate these seizures (by an anti-vitamin D effect). Because of that, the best treatment for patient with acute severe hypocalcemia is intravenous calcium solutions and continued with oral calcitriol until the symptoms have cleared.

---

**Acknowledgment**

We would like to thank the patient for her consent to this case report publication.

---

**Conflict of Interest**

The author stated there is no conflict of interest.

---

**References**

1. Schafer AL, Shoback DM. Hypocalcemia: diagnosis and treatment. [Updated 2016 Jan 3]. Endotext [Internet] South Dartmouth MDText com, Inc.
2. Pepe J, Colangelo L, Biamonte F, et al. Diagnosis and management of hypocalcemia. *Endocrine* 2020; 1–11.
3. Goltzman D, Rosen CJ, Mulder JE. Treatment of hypocalcemia. UpToDate, Waltham, MA.
4. Christensen RS, Ryan JL. Chapter 16 - Hypocalcemia. In: McDermott MTBT-ES (Fifth E (ed). Philadelphia: Mosby, 2009, pp. 148–153.
5. Thacher TD, Clarke BL. Vitamin D insufficiency. *Mayo Clin Proc* 2011; 86: 50–60.
6. Khan QJ, Fabian CJ. How I treat vitamin D deficiency. *J Oncol Pract* 2010; 6: 97–101.
7. Qari FA. Practical Approach for the Prevention and Management of Vitamin D Deficiency in Adult Patients. *Saudi J Intern Med* 2013; 3: 9–15.
8. Kennel KA, Drake MT, Hurley DL. Vitamin D deficiency in adults: when to test and how to treat. In: *Mayo Clinic Proceedings*. Elsevier, 2010, pp. 752–758.
9. Williams A, Liddle D, Abraham V. Tetany: A diagnostic dilemma. *J Anaesthesiol Clin Pharmacol* 2011; 27: 393.
10. Hall JE. Guyton and Hall Textbook of Medical Physiology, Jordanian Edition E-Book. Elsevier, 2016.
11. Manni A, Quarde A. *Endocrine Pathophysiology*. Springer, 2020.
12. Chhabra P, Rana SS, Sharma V, et al. Hypocalcemic tetany: a simple bedside marker of poor outcome in acute pancreatitis. *Ann Gastroenterol Q Publ Hell Soc Gastroenterol* 2016; 29: 214.
13. Singer FR. Hypocalcemia. In: Kleerekoper M, Siris ES, McClung M (eds) *The Bone and Mineral Manual*. Elsevier, 2005, pp. 161–163.
14. Infante M, Corradini D, Romano M, et al. Life-Threatening Hypocalcemia in A Patient with highly suspected osteomalacia: A Case Report. *AACE Clin Case Reports* 2018; 4: 174–178.
15. Inkster B. *Adult Vitamin D Guidelines*. Edinburgh Cent Endocrinol Diabetes.