

### *A Case of Tinea Incognito: A Misuses of Steroid*

**Diah Mira Indramaya, Abdul Karim, Zahruddin Ahmad**

*Department of Dermatology and Venereology Faculty of Medicine Universitas Airlangga/Dr. Soetomo General Academic Hospital Surabaya-Indonesia*

#### **ABSTRACT**

**Background:** Tinea incognito (TI) is a dermatophytic infection which has lost its typical clinical appearance because of improper use of steroids. Topical steroids in Indonesia are often used without prescription. The misuses of steroids has led to the emergence of TI. Clinical diagnosis of TI is still a challenge even by dermatologists, thus lead to a delay treatment. **Purpose:** To report a case of TI in child. **Case:** A 10-year-old girl presented with itchy ill defined erythematous patches on the face. The patch had appeared since 2 months before. The patient had already got topical and systemic corticosteroid but there were no improvement. Physical examination showed multiple papules on ill defined scaly erythematous patches on facial region. Potassium hydroxide examination revealed arthroconidia and septate hyphae, while from culture isolation *Microsporum gypseum* were identified. Diagnosis of TI was successfully made and the patient was treated with griseofulvin two times 125 mg per day orally for four weeks. The patient showed good result. **Discussion:** TI lesions usually lose their classic annular appearance thus the disease is likely to be confused with other diseases. It is important for dermatologist to consider fungal infection as differential diagnosis of prolong erythematous scaly lesions unresponsive to steroids or calcineurin inhibitors, and encourage of laboratory tests for mycological evaluation. **Conclusion:** Discontinuance of steroid and administration antifungal therapy promoted lesions improvement clinically and mycologically. It is important to regulate the topical steroid distribution and to educate primary care doctors about superficial dermatophytosis to reduce the increasing case of TI.

**Key words:** Tinea incognito, steroid, *Microsporum gypseum*.

#### **ABSTRAK**

**Latar belakang:** Tinea incognito (TI) adalah infeksi dermatofitik yang telah kehilangan tampilan klinis khasnya karena penggunaan steroid yang tidak tepat. Steroid topikal di Indonesia sering digunakan tanpa resep dokter. Penyalahgunaan steroid ini telah menyebabkan munculnya TI. Diagnosis klinis TI seringkali sulit dilakukan bahkan oleh dokter kulit, sehingga menyebabkan keterlambatan pengobatan. **Tujuan:** Melaporkan kasus TI pada anak. **Kasus:** Seorang anak perempuan berusia 10 tahun mengeluhkan bercak kemerahan gatal dengan batas tidak jelas di wajahnya. Keluhan bercak muncul sejak 2 bulan sebelumnya, dan sudah mendapatkan steroid topikal dan sistemik tetapi tidak ada perbaikan. Pemeriksaan fisik menunjukkan beberapa papula di atas makula eritematosa batas tidak jelas disertai skuama pada daerah wajah. Pemeriksaan kalium hidroksida (KOH) menunjukkan arthrokonidia dan hifa berseptata, sedangkan isolasi kultur berhasil diidentifikasi *Microsporum gypseum*. Diagnosis TI berhasil ditegakkan dan pasien diobati dengan griseofulvin oral dua kali 125 mg per hari selama empat minggu. Pasien menunjukkan perbaikan klinis yang baik. **Pembahasan:** Lesi TI biasanya kehilangan penampakan annular klasiknya, sehingga mungkin menjadi keliru dengan dengan penyakit-penyakit lainnya. Dokter kulit harus mempertimbangkan infeksi jamur sebagai diagnosis banding pada lesi kulit berupa makula eritematosa berskuama yang lama tidak responsif terhadap steroid atau inhibitor kalsineurin. **Simpulan:** Penghentian steroid dan pemberian terapi anti jamur memberikan kesembuhan secara klinis dan mikologis. Pengaturan sistem penjualan steroid topikal dan pendidikan dokter di layanan primer tentang penampakan klinis dermatofitosis superfisial sangat penting untuk mengurangi peningkatan kasus TI.

**Kata kunci:** Tinea incognito, steroid, *Microsporum gypseum*.

Alamat korespondensi: Diah Mira Indramaya, Departemen/Staf Medik Fungsional Kesehatan Kulit dan Kelamin Fakultas Kedokteran Universitas Airlangga, Rumah Sakit Umum Daerah Dr. Soetomo, Jl. Mayjen Prof. Dr. Moestopo No. 6-8 Surabaya 60131, Indonesia. Telepon: +628563030044, email: idiahmira@yahoo.com

---

#### **INTRODUCTION**

Tinea incognito (TI) is a dermatophytosis that have lost their usual clinical appearance because of the misuse of steroids or calcineurin inhibitors.<sup>1</sup>

Lesions usually lose their classic annular appearance.<sup>2</sup> TI presents as irregular, poorly defined, erythematous desquamative plaques.<sup>1</sup> Thus the disease is likely to be confused with other diseases like eczema, seborrheic

dermatitis, intertriginous psoriasis, pustular psoriasis and rosacea according to their localizations.<sup>2</sup>

The clinical diagnosis of TI sometimes difficult even for dermatologist. Topical steroids are often used without prescription in Indonesia. The increasing misuses of these drugs has led to the emergence of TI. Treatment delay of TI leads to associated morbidity not only for the patient but also for others who contact with the patient.<sup>1</sup> We report a case of TI in child that got mistreatment with steroids resulted in exacerbation and spread of the disease.

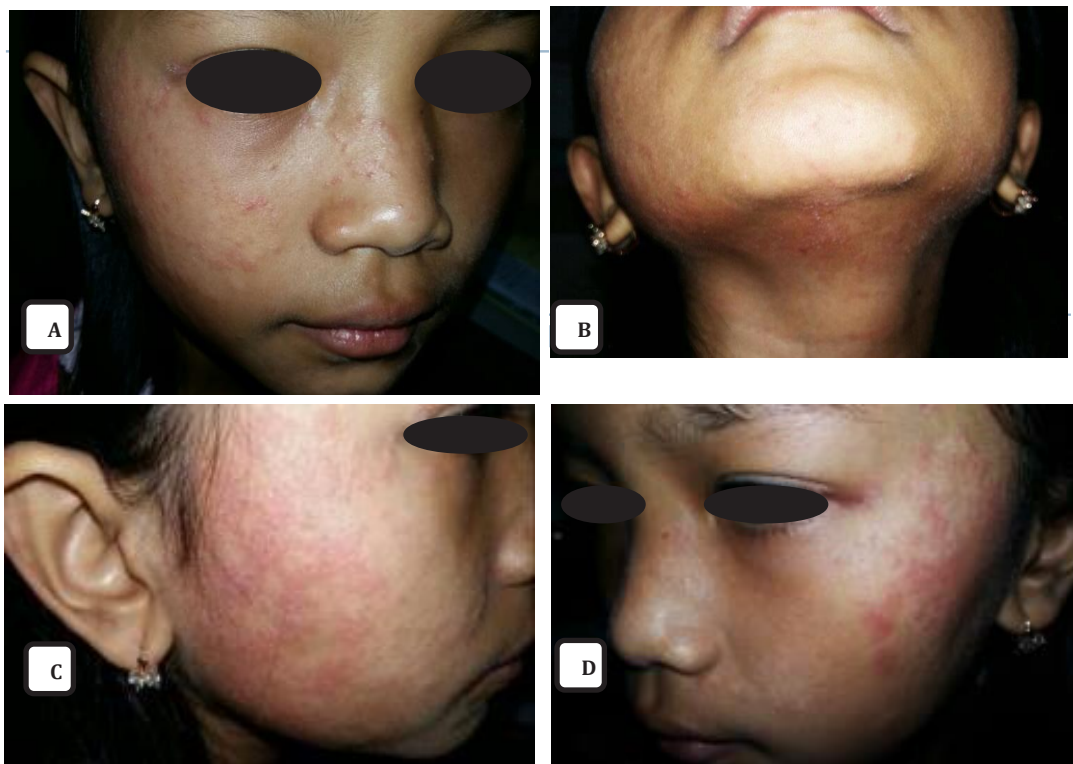### CASE REPORT

A 10 year old girl was presented to our outpatient clinic with itchy papular redness patches on her face. The small redness had appeared 2 months prior to examination. One week later she went to doctor and was given topical betamethasone for two

week. The lesions initially improved but then it persisted and gradually become wider. The mother took her to see a dermatologist and who gave oral metilprednisolone and topical mometasone for one week, but there were no improvement. The patient was finally referred to Dr. Soetomo hospital with a diagnosis of seborrheic dermatitis .

The patient was otherwise healthy and had unremarkable medical history. She has no history of applying traditional medication nor having food or drug allergy. History of atopy, asthma, and rhinitis was also denied. Family history of similar disease was denied and she did not have any pet.

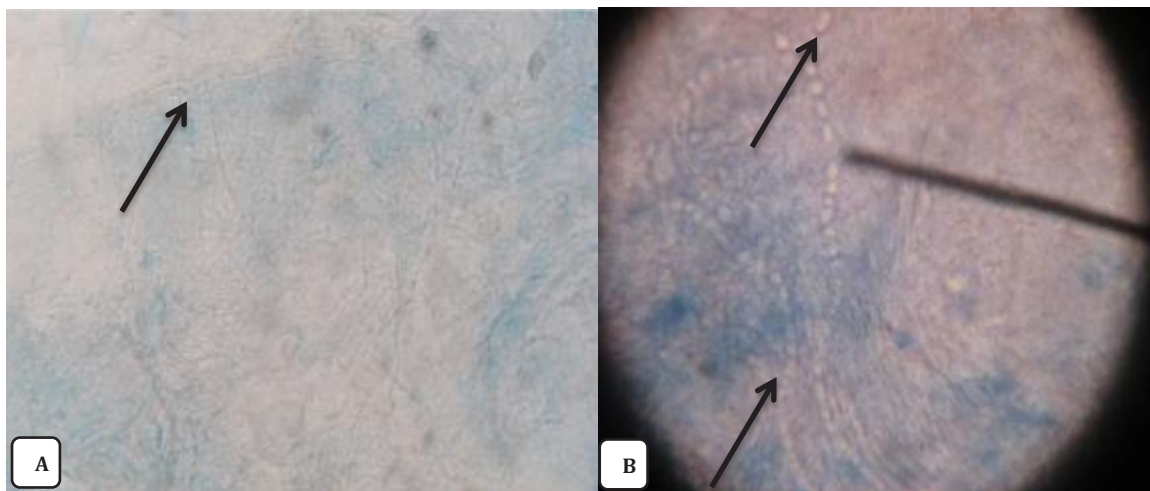
Physical examination revealed lesions on regio facialis and neck. The lesions were ill defined papular scaly erythematous patches. There were no erosion, pustule, and nor crust.



**Figure 1.** Before treatment: picture A, B on regio facialis and neck: there were erythematous macule, unsharply margined with multiple papule, covered by thin scale. Picture C, D on cheek area: there were erythematous macule/ plaque and multiple papule, covered by thin scale. Clinically, these lesions have a less raised margin and are less scaly than common dermatophytosis.

The potassium hydroxide (KOH) microscopic examination revealed arthroconidia and septate hyphae (figure 2). Fungal culture isolation was revealed macroscopic appearance of the colony as flat and granular with tan to buff pigment (figure 3). Microscopically, it was composed by septa hyphae, macroconidia are seen in enormous number, symmetric, relatively thin walled with no more than six

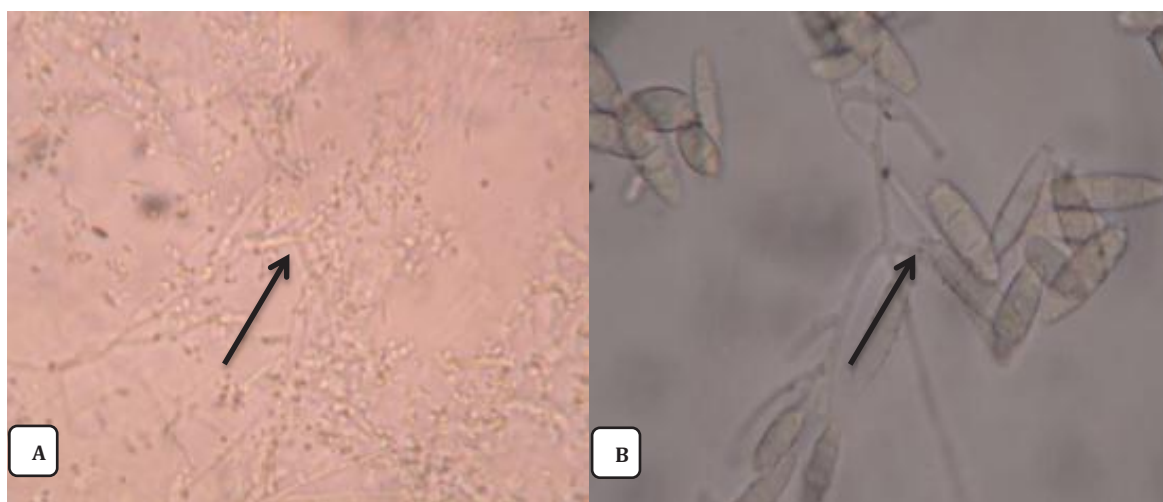
compartments, without knob (figure 4). These findings were consistent with a diagnosis of a dermatophyte infection caused by *Microsporum gypseum* (*M. gypseum*). Diagnosis of Tinea incognito was made, topical steroid was discontinued and the patient was treated with Griseofulvin 125 mg twice a day orally for four weeks and the result was good.



**Figure 2.** KOH microscopic examination: (A) showed arthroconidia and septa hyphae (on arrow) (Objective 10x) (B) Long narrow septae and branching hyphae (on arrow) (Objective 40x)



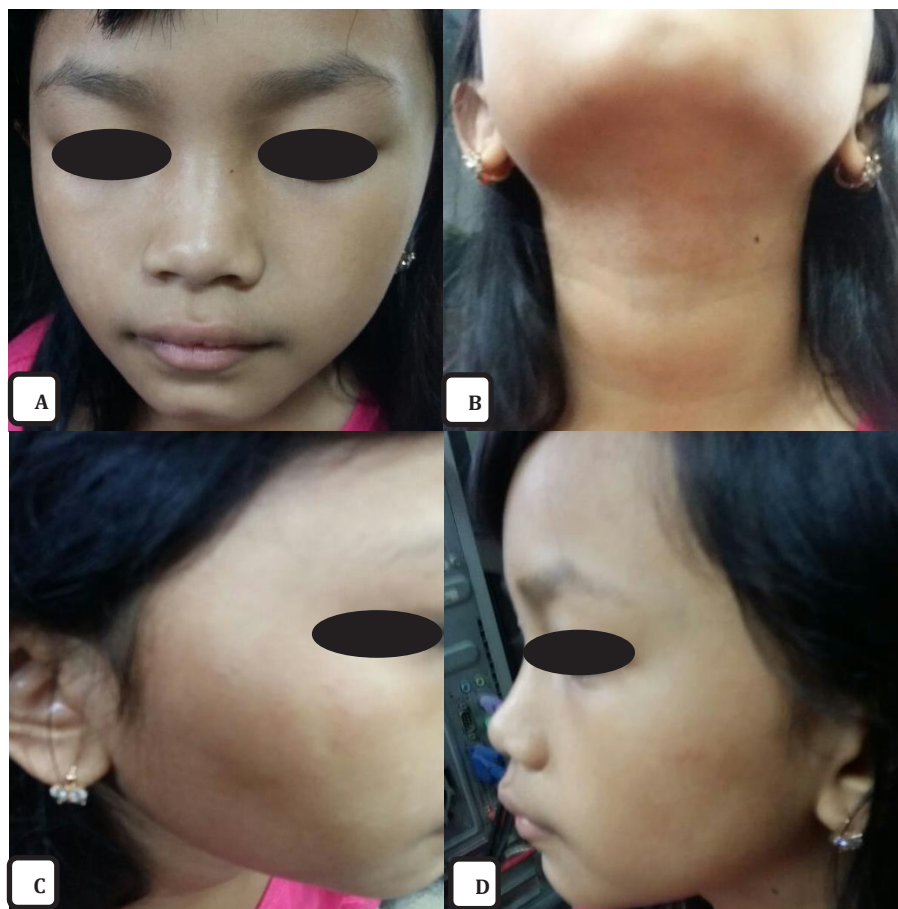**Figure 3.** Macroscopic appearance of the colonie of *M. gypseum* in culture media, there were flat and granular with tan to buff pigment appearance.



**Figure 4.** Microscopic feature of the culture result: (A) Septa hyphae and macroconidia (Objective 40x) (B) *M. gypseum* showing ellipsoidal, multicelled macroconidia without knob, only 4 cells.

**Table 1.** Clinically and mycologically progression

	July 4 <sup>th</sup> (day 1)	July 19 <sup>th</sup> (day 15)	August 2 <sup>nd</sup> (day 30)
<b>SUBJECTIVE</b>			
Itchy sensation	+++	+	-
<b>OBJECTIVE</b>			
Erythematous macule	+++	+	-
Multiple papule	++	-	-
Thin scale	++	-	-
Hypopigmented macule	-	+	+
<b>Microscopic examination (KOH)</b>			
Hyphae	+	-	-
<b>THERAPY</b>			
Griseofulvin 250 mg/day (2x1tab)	+	+	-



**Figure 5.** After Treatment: (A,B,C, and D): Good progress of the lesion 4 weeks after treatment, there were post inflammatory hypopigmented macule (KOH examination was negative)

**DISCUSSION**

Tinea incognito (TI ) was first described in 1968.<sup>3</sup> The term is used to describe a tinea infection incorrectly diagnosed and treated by the application of topical or systemic corticosteroid which has resulted in reducing the extend of inflammation and scaling.<sup>3</sup> The typical dermatophyte infection usually present as annular lesions with erythematous scaly border and

central clearing.<sup>4</sup> But dermatophytic infection may be confused with other skin disorders.<sup>2,4</sup>

In this case the patient’s prior tinea faciei had been misdiagnosed as other dermatoses and had been treated with topical betamethasone. The lesions initially improved but then it persisted and gradually extended in area. It has been suggested that the use of immunosupressant decrease the fungus induced local

inflammation, and this may allow the fungus to grow slowly with less erythema or scaling causing a modification of the typical manifestation of tinea.<sup>4</sup>

The atypical clinical features of TI were again misdiagnosed by dermatologist and she was given topical and systemic steroid. This mistreatment resulted in exacerbation and spread of the disease. Then the dermatologist referred the patient to Dr Soetomo hospital. Kim et al on his 9-year multicenter survey of Tinea incognito in Korea found that over half of the patients were either treated by non dermatologist (48%) or self treated (15,5%) and surprisingly 40% of the patients were treated by dermatologist.<sup>4</sup>

Tinea incognito lesions usually lose their classic annular appearance thus the disease is likely to be confused with different diseases like eczema, seborrheic dermatitis, intertriginous psoriasis, pustular psoriasis, and rosacea according to their localizations.<sup>2</sup> It also can mimic pityriasis rosea, impetigo, folliculitis, and lupus erythematosus.<sup>1</sup> It is important for dermatologists to consider fungal infection as differential diagnosis of skin disorders if they found long lasting erythematous scaly skin lesions unresponsive to steroids or calcineurin inhibitors and consider to perform laboratory tests for mycological evaluation.<sup>4</sup>

In our patient, the direct microscopic examination was done and revealed arthroconidia and septate hyphae. The fungal culture produced flat and granular with buff pigment colonies which then proved to be *Microsporum gypseum* (*M. gypseum*). Septate hyphae with abundant 4-6 celled macroconidia was produced. Macroconidia are thin-walled, fusiform, symmetrical, and have rounded ends. Microconidia are also present but not support the diagnosis.<sup>5,6</sup> *M. gypseum* is a geophilic saprophyte with worldwide distribution found particularly in humus-rich soils. It is a rare agent of dermatophyte infection, with low contagious potential. Infection may be transmitted from animal, or affected humans but principally from soil.<sup>5</sup> Studies by Romano in Italy and Kim in Korea found the most common agent of TI was *Trichophyton rubrum* (*T. rubrum*).<sup>4,7</sup> In 2000, Romano reported TI due to *M. gypseum* in three children in Italy and Yu et al reported a case of TI due to *M. gypseum* in China 10 years after.<sup>5,8</sup>

The diagnosis of TI in our patient was made based on history of long-lasting scaly facial skin lesion unresponsive to steroid, and the result of mycological examination. Jacob et al stated that although localized tinea corporis responds well to topical therapy but TI should be treated with oral antifungal agents. Terbinafine and the azoles such as

itraconazole and fluconazole, accumulate in the stratum corneum and are preferred over griseofulvin.<sup>9,10</sup> We gave our patient griseofulvin other than terbinafine, itraconazole or fluconazole because the drug of choice for dermatophytosis according to our clinical guideline is griseofulvin. The patient was successfully treated with griseofulvin twice 125 mg perday orally for four weeks.

The prognosis in this patient is good because the correct mycological examination and culture to obtain a correct diagnosis. This is the responsibility of the dermatologist to be aware of and apply the elemental laboratory techniques needed for the correct diagnosis of this case. Immediate cessation of all topical steroid use and implementation of specific antifungal treatment should be performed.<sup>2,9</sup> The recurrences rate is very rare as long as we educate the patients carefully to not reinstitute use of topical steroids on their own.<sup>7</sup>

The increasing incidence of TI cases was reported by Kim in Korea, and Ansar in Iran, was thought to be associated with easy access to topical steroids by the patients and with lack of understanding of tinea by non dermatologist. There should be policy changes to limit over the counter (OTC) access of steroids to patients. This would limit inappropriate tinea treatment by patients. Education regarding skin diseases including fungal infections could be provided by dermatologic associations to reduce the number of TI cases caused by non dermatologist.<sup>3,4</sup> This situation also found in Indonesia. Two other cases of TI was reported in our department last year. To reduce the increasing case of TI it is important to regulate the corticosteroid topical sales system so that this medicine can only be obtained by patients with prescription, and to inform the non-dermatologist clinicians that superficial dermatophytosis can mimic other dermatoses.

## REFERENCES

1. Boz JD, Crespo, Ruiz FR, Troya MD. Tinea incognito in children: 54 cases. *Mycoses* 2009; 54:254-8
2. Turk BG, Taskin B, Karaca N, Sezgin AO, Aytimur D. Clinical and mycological analysis of twenty-one cases of Tinea incognito in the Aegean region of Turkey: A retrospective study; *Acta dermatovenerol croat* 2013; 21(0):93-8
3. Ansar A, Farshchian M, Nazeri H, Ghisian SA. Clinico-epidemiological and mycological aspect of Tinea Incognito in Iran: A 16 year study. *Med Mycol. J* 2011;52: 25-32

4. Kim WJ, Kim TW, Mun JH, Song M, Kim HS, Ko HC, Kim BS. Tinea incognito in Korea and its risk factor: nine-year multicenter survey. *J Korean Med Sci* 2013; 28: 145-51
5. Romano C, Asta F, Massai L. Tinea incognito due to *Microsporum gypseum* in three children. *Pediatric dermatology* 2000; 17:41-4
6. Schieke SM, Garg A. Superficial fungal infection. In: Goldsmith AI, Katz S, Gilchrist A, Paller A, Leffell D, Wolff K, editors. *Fitzpatrick's Dermatology in general medicine*. 8<sup>th</sup> ed. New York: Mc Grawhill; 2012. p. 2277-97.
7. Romano C, Maritati E, Gianni C. Tinea incognito in Italy: a 15-year survey. *Mycoses* 2006; 49: 383-7
8. Yu C, Zhou J, Liu J. Tinea incognito due to *Microsporum gypseum*. *Journal of Biomedical Research* 2010;24(1):81-3
9. Jacobs JA, Kolbach DN, Vermeulen AHM, Smeets MHM, NeumanHAM. Tinea incognito due to *Trichophyton rubrum* after local steroid therapy. *Clinical infectious diseases* 2001;33e :142-4
10. Arenas R, Coutino GM, Vera L, Welsh O. Tinea incognito. *Clinics in dermatology* 2010;28:137-9