



## Clinical and Cure Profile of Tinea Capitis Patients

Farah Ayu Noviannisa<sup>1</sup>, Linda Astari<sup>2</sup> , Lindawati Alimsardjono<sup>3</sup>

<sup>1</sup>Medical Program, Faculty of Medicine, Universitas Airlangga, Surabaya, Indonesia

<sup>2</sup>Departement of Dermatology and Venereology, Faculty of Medicine, Universitas Airlangga/Dr. Soetomo General Academic Hospital Surabaya, Indonesia

<sup>3</sup>Departement of Microbiology, Faculty of Medicine, Universitas Airlangga/Dr. Soetomo General Academic Hospital Surabaya, Indonesia

### ABSTRACT

**Background:** Tinea capitis (TC) is a superficial mycoses infection of hair follicles and hair shaft caused by dermatophytes of the genus *Trichophyton* and *Microsporum*. Tinea capitis can cause hair loss and scales with varying degrees of inflammatory response. The incidence varies depending on geographical location and factors that affect the incidence rate. It is important to know the incidence also the clinical and cure profile of tinea capitis to provide benefits in the prevention, diagnosis, and treatment. **Purpose:** To evaluate the clinical and cure profile of TC patients at the Dermatology and Venereology Outpatient Clinic of Dr. Soetomo General Academic Hospital Surabaya from January 2019 to January 2020. **Methods:** A retrospective descriptive study based on medical records with a total sampling technique. **Result:** Of the 10 TC patients, who were the research subjects, TC predominantly affected males and at 5–11 years age group. The highest risk factor was a history of contact with cats. Scales were the most common clinical feature. *Microsporum canis* was the most common causative species, ectothrix arthrospores was revealed during the direct microscopic examination, Wood lamp's fluorescence was mostly yellow-green, and cigarette-shaped hair was the most common dermoscopic finding. Eighty percent of subjects were diagnosed with gray patch type. Griseofulvin was the most common oral treatment. Of the 10 patients, 8 were successfully followed up and had clinical and mycological improvement, while the other 2 patients were lost to follow-up. **Conclusion:** The diagnosis of TC was established based on the patient's history, clinical examination, and supporting examination. Monitoring therapy was carried out by evaluating the patients clinically and mycologically.

**Keywords:** dermatophytosis, tinea capitis, evaluation of therapy, fungal disease, tropical diseases.

Correspondence: Linda Astari, Department of Dermatology and Venereology, Faculty of Medicine, Universitas Airlangga/Dr. Soetomo General Academic Hospital, Jl. Mayjen. Prof. Dr. Moestopo No. 162 Surabaya 60285, Indonesia. Phone: +628976021227, e-mail: [linda-a@fk.unair.ac.id](mailto:linda-a@fk.unair.ac.id).

| Article info |

Submitted: 07-01-2022, Accepted: 12-01-2022, Published: 31-07-2022

This is an open access article under the CC BY-NC-SA license <https://creativecommons.org/licenses/by-nc-sa/4.0/>

### BACKGROUND

Dermatophytosis is a superficial fungal infection caused by dermatophyte fungi that can attack keratin-containing tissues such as the stratum corneum, epidermis, hair, and nails. Tinea capitis is a dermatophytosis that can infect the hair follicles and hair shaft, head hair, eyebrows, and eyelashes, caused by dermatophytes of the genera *Trichophyton* and *Microsporum*. Tinea capitis is most commonly observed in children between 3 and 14 years of age.<sup>1</sup> The present prevalence of tinea capitis is still high, especially in developing countries. This is due to poor personal hygiene, overcrowding, or low

socioeconomic standards.<sup>2</sup> In general, tinea capitis can cause hair loss and scaly lesions with varying degrees of inflammatory response. In some cases, the clinical signs may appear non-specific or resemble other diseases, making it difficult to establish a diagnosis. However, it has several characteristic clinical patterns.<sup>1</sup> The main clinical types of tinea capitis are the non-inflammatory type, namely gray patches and black dots, and the inflammatory type, which consists of favus and kerion.<sup>3</sup>

The incidence of tinea capitis varies worldwide depending on geographical location and factors that affect the incidence rate. A retrospective study

conducted at Prof. Dr. R. D. Kandou Manado Center Hospital from January to December 2012 revealed 6 cases of tinea capitis or 9.23% of the total 65 cases of dermatophytosis.<sup>4</sup> Furthermore, a retrospective study involving 466 dermatophytosis patients at the Mycology Division of the Dermatology and Venereology Outpatient Clinic of Dr. Soetomo General Academic Hospital Surabaya for the period 2014–2016 reported that the majority of dermatophytosis cases were tinea corporis (56.1%), followed by tinea cruris (34.3%) and tinea capitis (6.4%).<sup>5</sup>

Tinea capitis requires systemic and topical treatment. Options for antifungal are griseofulvin, terbinafine, itraconazole, and fluconazole. Also, the common options for topical therapy are 2% ketoconazole shampoo, 1% or 2.5% selenium sulfide, 2.5% povidone-iodine antiseptic, and zinc pyrithione 1% or 2%.

The data above suggests that tinea capitis incidence is relatively minor compared to other dermatophytoses. However, in developing countries, such as Indonesia, the cases of TC is still frequently found. Therefore, it is imperative to examine the incidence, clinical, and cure profile of TC cases for better prevention, diagnosis, treatment, and education of patients.

## METHODS

This was a retrospective study using secondary data obtained from medical records. The study population was tinea capitis patients treated at the Dermatology and Venereology Outpatient Clinic Dr. Soetomo General Academic Hospital Surabaya and met the inclusion criteria from January 2019 to January 2020. The study variables were age, sex, education level, duration of illness, risk factors, clinical features, supporting examination, diagnosis, therapy, and monitoring of the therapy. The materials and instruments of this research were medical records of tinea capitis patients at the Dermatology and Venereology Outpatient Clinic of Dr. Soetomo General Academic Hospital Surabaya.

This research was conducted at the Mycology Division of the Dermatology and Venereology Outpatient Clinic Dr. Soetomo General Academic Hospital Surabaya from September 2020 to November 2021. This research has been reviewed by the Ethics Committee at Hospital Ethics Committee of Dr. Soetomo General Academic Hospital Surabaya No.070/1196 301.4.2/Litb/XI/2020.

## RESULT

Three hundred and three new patients with dermatophytosis (3.3%), 10 were patients diagnosed

with tinea capitis. They were treated at the Mycology Division of the Dermatology and Venereology Outpatient Clinic of Dr. Soetomo General Academic Hospital Surabaya between January 2019 and January 2020.

Tinea capitis was the most observed in males (60% or 6 patients) than females (40% or 4 patients), and the highest age group was 5–11 years (6 patients), followed by 0–5 years (3 patients) and 12–16 years (1 patient). In terms of education, most patients were only primary education graduates (6 patients). The anamnesis shows that most patients seek treatment in less than 4 weeks (7 patients) and the remaining seek treatment in 4–8 weeks (3 patients).

The most frequent risk factor for tinea capitis patients was a history of contact with pets. Figure 1 shows that several patients had more than one risk factor. Table 1 shows the distribution of clinical features among patients. Squama was the most prevalent clinical feature, followed by local alopecia and hypopigmented macules. Other clinical features observed were hair loss, erythematous macule, broken hair, papules, hyperkeratotic plaque, hyperpigmentation, grayish macule, and crust.

Supporting examinations that the patients underwent were fungal culture, potassium hydroxide (KOH) 10–20%, Wood's lamp, and dermoscopy. Fungal culture, the gold standard for tinea capitis diagnostic, was performed on all patients, and all results were positive. The most common dermatophyte identified was *Microsporum canis* followed by *Microsporum audouinii*.

On Wood's lamp examination, it was found that seventy percent (7 patients) had positive results with the highest fluorescence found was yellowish-green, followed by greenish, purplish, bluish-green, 2 patients had negative results, and 1 patient had no data. The KOH 10–20% examination results showed 60% (6 patients) positive and 40% (4 patients) negative. The findings of KOH 10–20% were ectothrix (3 patients), arthroconidia (1 patient), and ectothrix plus hyphae (1 patient). Additionally, the supportive examination with dermoscopy was performed on 5 patients (50%), and all results were positive. Cigarette-shaped hair was the most common finding, followed by morse hair, comma hair, and corkscrew hair.

The diagnosis of tinea capitis is divided into the non-inflammatory type (gray patch and black dot) and the inflammatory type (kerion and favus). Eight patients (80%) were diagnosed with gray patch type tinea capitis, and 2 patients (20%) were diagnosed with kerion type tinea capitis. All patients received griseofulvin as systemic therapy, and the most widely

administered topical therapy was ketoconazole scalp solution 2%.

Table 2 shows the results of clinical examination and supporting examinations after oral and topical therapy during the previous visit to evaluate the therapy. 80% of patients attended the follow-up visit, and their clinical examination results showed an improvement. The KOH 10–20% data showed that 3 patients (30%) experienced improvement. From Wood's lamp examination, 3 patients still had positive results, which means no improvement. As for dermoscopy, the results showed that 1 patient had improved. 50% of patients (5 patients) attended the third visit, and all of them presented with improvements in clinical features. The KOH 10–20%

result showed that 30% of patients (3 patients) had negative results. On Wood's lamp examination, 10% of patients (1 patient) had negative results. Also, 10% of patients (1 patient) experience improvement based on the result of the dermoscopy examination. 20% of patients (2 patients) attended the fourth visit, and all of them experienced improvements in clinical features, KOH 10–20%, and dermoscopy. Also, on Wood's lamp examination, only 1 patient had improvement. Only 1 patient attended the fifth visit, and the patient showed improvement in clinical features and supporting examination. Based on medical records, the fungal culture was only performed at the first visit. Therefore, there was no fungal culture data for the subsequent visit.

Risk Factors

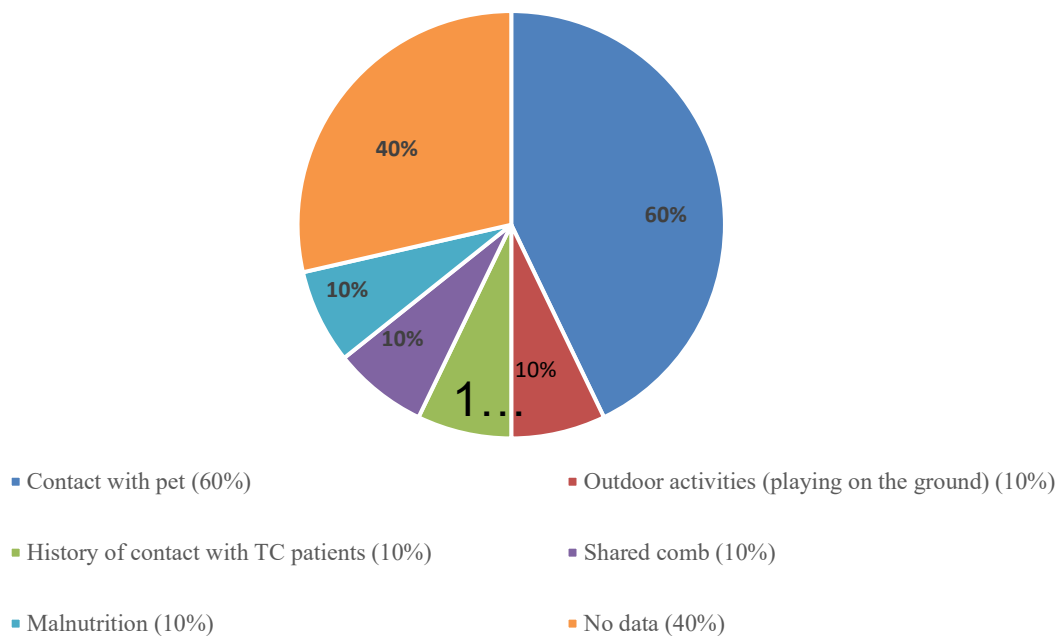


Figure 1. Risk factors of the study subjects at Dr. Soetomo General Hospital in January 2019 – January 2020.

Table 1. Clinical features of study subjects at Dr. Soetomo General Hospital in January 2019 – January 2020

No.	Clinical feature	n (%)
1.	Scales	9 (90)
2.	Local alopecia	6 (60)
3.	Erythematous macule	4 (40)
4.	Hair loss	4 (40)
5.	Hypopigmented macule	4 (40)
6.	Broken hair	2 (20)
7.	Papule	2 (20)
8.	Hyperkeratotic plaque	1 (10)
9.	Crust	1 (10)
10.	Hyperpigmentation	1 (10)
11.	Gray macule	1 (10)

**Table 2.** Monitoring therapy of the study subjects

Subject	Duration of therapy	Improvement category					Description
		Clinical feature	KOH 10–20%	Wood's Lamp	Dermoscopy	Fungal Culture	
1	8 weeks	Yes	Yes	Yes	Yes	No data	Clinical and mycological improvement
2	2 weeks	Yes	No data	No data	No data	No data	Clinical improvement
3	2 weeks	-	-	-	-	-	Loss to follow up
4	2 weeks	-	-	-	-	-	Loss to follow up
5	4 weeks	Yes	No	No data	No data	No data	Clinical improvement
6	6 weeks	Yes	Yes	No	No data	No data	Clinical and mycological improvement
7	6 weeks	Yes	Yes	No	No	No data	Clinical and mycological improvement
8	8 weeks	Yes	Yes	Yes	Yes	No data	Clinical and mycological improvement
9	6 weeks	Yes	Yes	Yes	No data	No data	Clinical and mycological improvement
10	4 weeks	Yes	Yes	No	No data	No data	Clinical and mycological improvement

KOH = potassium hydroxide

## DISCUSSION

The prevalence of tinea capitis patients at the Dermatology and Venereology Outpatient Clinic of Dr. Soetomo General Academic Hospital Surabaya was 3.3% from January 2019 to January 2020. A previous study at Dr. Soetomo General Academic Hospital Surabaya that the prevalence of tinea capitis cases was 0.31%–1.55% from 2001 to 2006.<sup>6</sup> Furthermore, from 2011 to 2013, there were 22 tinea capitis patients (3.5%) out of 624 dermatophytoses patients.<sup>7</sup> Additional data at the Dermatmycology Division of the Dr. Cipto Mangunkusumo National Central Public Hospital Jakarta showed 0.53% cases of tinea capitis within 6 years.<sup>8</sup>

Tinea capitis was more prevalent in males than females. The result is supported by a previous study conducted in Egypt in 2021. The study showed that tinea capitis was most common in males (86%) than females (14%).<sup>9</sup> Such higher prevalence in male patients, apart from prepubertal factors such as fungistatic fatty acid levels, is most likely also caused by hormonal factors and low levels of progesterone, which causes inhibition of steroid-mediated dermatophyte growth.<sup>10</sup>

The most prevalent age group was 5–11 years. The result of this study is similar to the previous study in Medan. The study found that tinea capitis cases at the Dermatology and Venereology Polyclinic, Dr. Pirngadi General Hospital Medan from 2014 to 2017

were most prevalent in the age group of 5–11 years (27.8%).<sup>11</sup> This may be due to children's poor hygiene and the absence of saturated fatty acids, which provides a natural protective mechanism against dermatophytosis.<sup>12</sup> Very rare cases of tinea capitis in adults can be caused by the fungistatic characteristic of long-chain fatty acids in post-pubertal sebum, maturation of hair follicles, and the immune system after adulthood which can protect the body against fungal invasion.<sup>13</sup> Most tinea capitis are observed in patients with a lower level of education. In this study, there were no data on the educational level of the patient's parents. However, a study conducted in India showed a relationship between the education level of parents and the proportion of tinea capitis in the population. The study found that tinea capitis was more common in children whose parents have primary school education or no education.<sup>14</sup>

Most tinea capitis patients seek treatment when they feel pain in the first 4 weeks after infection or are characterized by the appearance of symptoms. The incubation period for tinea capitis is approximately several weeks.<sup>15</sup> In addition, the patients immediately check themselves after symptoms or clinical changes in their bodies appear, suggesting that they care about their wellbeing.

Figure 1 shows that the risk factors for tinea capitis may vary, including a history of contact with pets, contact with tinea capitis patients, outdoor

activities (playing on the ground), comb sharing, and malnutrition. Many predisposing factors in the onset of tinea capitis infection include contact with animals, living in a crowded environment, sharing beds, towels, and combs, intrafamily history of tinea capitis, and low social standards.<sup>16</sup>

The most common clinical feature was squama. In addition, other clinical features were found in the form of local alopecia, hair loss, hypopigmented macule, erythematous macule, broken hair, grayish macule, hyperkeratotic plaque, hyperpigmentation, crust, and papule. These results are similar to the study conducted in Dr. Soetomo General Academic Hospital Surabaya in 2014–2016. The study stated that the physical examination data confirmed that squama (85.7%) was the most common efflorescence. Other clinical features include erythematous macule, hypopigmentation, papule, hyperpigmentation, erosion, grayish macule, pustule, nodule, and crust.<sup>17</sup>

Fungal culture, the gold standard for dermatophytosis diagnostics, was performed on all patients, and all results showed positive. *Microsporum canis* was the most common causative species identified. A retrospective study conducted in Campania reported similar results, where 143 cases of tinea capitis in a group of patients younger than 18 years were also caused by *Microsporum canis* (64.1%).<sup>18</sup> In gray patch tinea capitis, the most common isolated organism was *M. canis* followed by *T. rubrum* and *T. mentagrophytes*.<sup>19</sup>

The KOH data shows that ectothrix arthrospores was the most common finding. Meanwhile, a study conducted in North India reported that the positivity rate of the KOH was 71%, and the endothrix pattern (63.38%) was the most common.<sup>20</sup>

Seventy percent of Wood's lamp examination results was positive. Positive fluorescence on Wood's lamp examination can be found in *Microsporum canis*, *Microsporum audouinii*, *Microsporum distortum*, *Microsporum ferrugineum*, and occasionally *Trichophyton schoenleinii*. The Wood's lamp examination will mainly show positive results in ectothrix dermatophytes.<sup>21</sup> It also supports that 30% of tinea capitis patients who underwent KOH 10%–20% examination showed positive results of ectothrix spores. Also, the causative species identified from fungal culture examination of tinea capitis patients at Dr. Soetomo General Academy Hospital Surabaya from January 2019 to January 2020 were *Microsporum canis* and *Microsporum audouinii*.

Dermoscopy was performed in 50% of cases. The examination results showed that cigarette-shaped hair (40%) was mainly found, followed by morse hair, corkscrew hair, and comma hair (20%). Those

dermoscopic findings in tinea capitis resulted from the fungal invasion of the hair shaft. A publication on morse hair as a dermoscopic sign for tinea capitis reported that five cases with tinea capitis in their study were cultured positive for *Microsporum canis*.<sup>22</sup>

The gray patch type was the most diagnosed type of tinea capitis. The clinical feature of the non-inflammatory type is characterized by scaly, seborrheic (dandruff) scalp, and hair loss. The gray patch presentation is *Microsporum ectothrix* infection with uneven circular alopecia with scales. Kerion type tinea capitis is characterized by one or more tender and inflamed alopecia nodules covered with pustules.<sup>23</sup>

Treatment of tinea capitis requires systemic antifungal therapy because topical antifungals alone are not sufficient to penetrate the hair shaft to eradicate infection.<sup>24</sup> All patients received griseofulvin as the systemic therapy. Griseofulvin is available in micro size tablets of 125, 250, and 500 mg with a recommended dose of 15–20 mg/kgBw/day for children with a duration of therapy of 6–12 weeks, while the dose for adults is 500–1000 mg/day for 4–8 weeks. Some literature shows that griseofulvin is more effective against *Microsporum* species. Topical antifungal therapy is used as adjuvant therapy for systemic antifungals, and it can help reduce spore transmission. Combination therapy with topical and oral antifungals can increase the cure rate.<sup>25</sup> The majority of patients received ketoconazole scalp solution 2% as adjuvant therapy.

Therapy monitoring was done by evaluating the patient clinically and mycologically to determine the effectiveness of the prescribed therapy. Before the patient is declared cured and the treatment stops, a complete recovery must be confirmed, consisting of clinical and mycological cures. Table 2 shows that out of 10 tinea capitis patients, 8 patients attended the follow-up check and 2 patients did not attend the follow-up or loss to follow-up. After receiving 2 weeks of griseofulvin, patients came back, and they mainly experienced clinical and mycological improvement on each visit. In this study, no patient was compliant until the therapy's end and was declared cured.

A study conducted at Dr. Soetomo General Academy Hospital Surabaya in 2014–2016 stated that education for follow-up was given to all patients, but only 27 of 42 patients (64.3%) returned for follow-up.<sup>5</sup> In addition, research conducted at Dr. Cipto Mangunkusumo Center National Hospital Jakarta reported that from 20 patients, 15 patients (65.22%) experienced improvement. Still, only 5 patients (21.74%) were successfully followed up until the end of therapy and declared cured. Such non-adherence can be caused by the lack of education provided by medical

practitioners, the patient's low understanding of the importance of follow-up, and proximity to the hospital.<sup>8</sup>

The study results showed that tinea capitis was more prevalent in male children. The diagnosis was made based on anamnesis, physical examination, and supporting examination. The most common diagnosis of tinea capitis was gray patch type (80%). Griseofulvin and ketoconazole scalp solution 2% were the most given treatment. Eight out of 10 patients were successfully evaluated with clinical and mycological improvement, and 2 patients were loss to follow-up. The therapy given was generally in accordance with the Clinical Practice Guidelines applicable at Dr. Soetomo General Academy Hospital Surabaya, with a reasonably high cure rate and good therapeutic effectiveness.

## REFERENCES

- Fuller LC, Barton RC, Mohd Mustapa MF, Proudfoot LE, Punjabi SP, Higgins EM, Punjabi S. British association of dermatologists' guidelines for the management of tinea capitis 2014. *Br J. Dermatol* 2014; 171(3): 454-463.
- Ginter-Hanselmayer G, Weger W, Ilkit M, Smolle J. Epidemiology of tinea capitis in Europe: current state and changing patterns. *Mycoses* 2007; 50: 6-13.
- Craddock LN, Schieke SM. Superficial fungal infections. In: Kang S, Amagai M, Bruckner AL, Enk AH, Margolis DJ, McMichael AJ, et al., editors. *Fitzpatrick's Dermatology*. 9th Edition. New York: McGraw-Hill Education 2019, p. 2925-51.
- Bertus NVP, Pandaleke HE, Kapantow GM. Profil dermatofitosis di Poliklinik Kulit dan Kelamin RSUP Prof. Dr. RD Kandou Manado Periode Januari-Desember 2012. *e-Clinic* 2015; 3(2): 2-5.
- Venitarani SA, Handayani S, Ervianti E. Profile of patients with tinea kapitis. *Dermatol Reports* 2019; 11(S1): p.8042.
- Suyoso S. Tinea kapitis pada bayi dan anak. In: *Kelompok Studi Dermatologi Anak. Penyakit papuloeritroskuamosa dan dermatomikosis superfisial pada bayi dan anak*. Semarang: Badan Penerbit Universitas Diponegoro 2008. p.49-88.
- Putri AI, Astari L. Profil dan evaluasi pasien dermatofitosis. *Berkala Ilmu Kesehatan Kulit dan Kelamin* 2017; 29(2): 135-141.
- Sari AB, Widaty S, Bramono K, Miranda E, & Ganjardani M. Tinea kapitis di Poliklinik Kulit dan Kelamin RSUPN Dr.Cipto Mangunkusumo Jakarta periode tahun 2005-2010. *Departemen Ilmu Kesehatan Kulit dan Kelamin, FK Universitas Indonesia, RSUPN Dr. Cipto Mangunkusumo Jakarta* 2012:113-117.
- Tawfik K, Mohammed R, Shaltout A. Identification of dermatophytes isolated from tinea capitis patients and their in vitro susceptibility to terbinafine. *AIMJ* 2021; 2(5): 45-49.
- Emele F, Oyeka C. Tinea capitis among primary school children in Anambra state of Nigeria. *Mycoses* 2008; 51(6): 536-41.
- Rizkina N, Lingga FDP. Profil tinea kapitis di Poliklinik Kulit dan Kelamin RSUD Dr. Pirngadi Kota Medan Periode 2014 - 2017. *J. Ilm. Simantek* 2020; 4(4): 9-15.
- Hibstu DT, Kebede DL. Epidemiology of tinea capitis and associated factors among school age children in Hawassa Zuria District, Southern Ethiopia, 2016. *J Bacteriol & Parasitol* 2017; 8: 1-5.
- Cervetti O, Albini P, Arese V, Ibba F, Novarino M, Panzone M. Tinea capitis in adults. *Adv Microbiol* 2014; 4: 12-14.
- Attal RO, Deotale V, Yadav A. Tinea capitis among primary school children: a clinicomycological study in A rural hospital in central India. *Int J Cur Res Rev* 2017; 9(23): 25.
- John AM, Schwartz RA, Janniger CK. The kerion: an angry tinea capitis. *Int J Dermatol* 2018; 57(1): 3-9.
- Bassyouni RH, El-Sherbiny NA, Abd El Raheem TA, Mohammed BH. Changing in the epidemiology of tinea capitis among school children in Egypt. *Annals of Dermatology* 2017; 29(1): 13-19.
- Venitarani SA, Handayani S, & Ervianti E. Profile of patients with tinea kapitis. *Dermatol Reports* 2019; 11(S1): 8042.
- Calabrò G, Patalano A, Fiammenghi E, Chinese C. Tinea capitis in Campania, Italy: a 9-year retrospective study. *G Ital Dermatol Venereol* 2015; 150(4): 363-7.
- Aldayel M, Bukhari I. Pattern of tinea capitis in a hospital based clinic in Al Khobar, Saudi Arabia. *Indian J Dermatol* 2004; 49(2): 66-68.
- Dr Kanishtha Sharma. Clinicomycological profile of tinea capitis from a tertiary care hospital in North India. *IOSR Journal of Dental and Medical Sciences (IOSR-JDMS)* 2018; 17(8): 70-73.
- Bennassar A, Grimalt R. Management of tinea capitis in childhood. *Clin Cosmet Investig Dermatol* 2010; 3: 89.