



The Profiles of Infantile Hemangiomas Patients

Arie Hidayati¹, Nanda Earlia¹ , Ninda Sari², Vella¹, Mimi Maulida¹, Cynthia Wahyu Asrizal³

¹Department of Dermatology and Venereology, Faculty of Medicine Universitas Syiah Kuala/dr. Zainoel Abidin General Hospital, Banda Aceh, Indonesia

²NCB Skin Clinic

³Physiology Department, Faculty of Medicine Universitas Syiah Kuala, Banda Aceh, Indonesia

ABSTRACT

Background: Infantile hemangiomas (IH) are the most prevalent benign tumors in children, predominantly in girls. Most IH cases do not require treatment due to spontaneous involution, but 10% of cases do require early treatment due to size, location, and complications. **Purpose:** This study tried to define the profile, clinical aspects, and therapy of IH in Dr. Zainoel Abidin General Hospital, Banda Aceh. **Methods:** A descriptive approach using a retrospective analysis employing secondary data from the outpatient clinic's patient registration book. This study included all new cases of infantile hemangioma at the outpatient clinic general hospital between 2013 and 2021. **Result:** A total of 105 patients were involved in this study. The majority of IH patients (59%) were under the age of one year, with 64 female patients (61%) making the most visits to the pediatric clinic in 2017, 2018, and 2019 (77.1%). The most prevalent clinical features of skin lesions were nodules in 69 individuals (65.7%), and the most common site was the facial region (13.3%) in 44 patients. In 20 individuals, a combination of propranolol and oral corticosteroids was used as the most effective treatment strategy (19%). **Conclusion:** Infantile hemangiomas is the most frequently reported benign tumor in children. Females are more likely than males to develop IH. The majority of IH is minor and normally resolves on its own without therapy. However, certain rare kinds of IH require clinician attention and systematic treatment.

Keywords: infantile hemangioma, tumor, child health, noncommunicable disease, neoplasma

*Correspondence: Nanda Earlia, Department of Dermatology and Venereology Faculty of Medicine, Syiah Kuala University /dr. Zainoel Abidin General Hospital, Banda Aceh, Jl. Tgk. Daud Beureueh No. 108 Banda Aceh. Telepon: 0651 - 34565. email: nandaearliansc@gmail.com

| Article info |

Submitted: 30-05-2022, Accepted: 10-11-22, Published: 31-07-2023

This is an open access article under the CC BY-NC-SA license <https://creativecommons.org/licenses/by-nc-sa/4.0/>

BACKGROUND

Birthmarks are frequently associated with vascular abnormalities.¹ Vascular tumors are endothelial cell neoplasms, the most prevalent of which is infantile hemangioma (IH).^{2,3} Infantile hemangiomas are the most commonly occurring benign tumors in infants, occurring in around 4-5% of children within their first year of life.^{3,4,5,6} They are more prevalent in females (2 to 3:1 ratio), white, non-Hispanic infants, and children born prematurely, and affect up to 30% of premature infants, particularly those weighing less than 2500 g. Infantile hemangiomas is distinguished from other vascular tumors and

abnormalities by its distinct growth pattern (rapid proliferative phase followed by slower involution). Infantile hemangiomas have a range of morphologies, ranging from small benign growths to functionally debilitating masses, and are most frequently found on the face, neck, and trunk.⁷

Tissue hypoxia, embolization of placental endothelial cells, and enhanced angiogenic and vasculogenic activity are three major theories.⁵ The discovery that GLUT1, a glucose transporter protein, is expressed in red blood cells inspired new hypotheses about the pathophysiology of IH.^{1,4} Over the years, numerous therapeutic methods have been developed,

including corticosteroids, systemic interferon (IFN), beta-blockers, laser treatment, and surgical excision. Typically, no medical intervention is required because the lesions cure naturally. However, it is critical to identify individuals at high risk for lasting deformity, scarring, or organ malfunction and to provide them with surgery or drugs to avoid permanent scars, disfigurement, or organ failure.⁷ Early intervention, treatment decisions and a longer length of therapy based on IH features, patient risk factors, and family preferences boost long-term success rates in IH.⁸

While the majority of IH has a favorable prognosis, with spontaneous involution and few to no sequelae, a considerable minority of IH results in permanent deformity or medical complications. Approximately half of all treated patients will regain normal skin, while the remaining half may have residual atrophy, scarring, telangiectasias, or fibrofatty soft tissue remnants.¹ The size of the hemangioma, its location, the child's age, and the treatment have an effect on the quality of life of children with IH and their parents. The goal of this study is to describe the characteristics of infantile hemangiomas patients treated at Dr. Zainoel Abidin General Hospital Aceh between 2013 and 2021.

METHODS

This is a descriptive study conducted retrospectively utilizing secondary data from the patient register book and medical records at Dr. Zainoel Abidin General Hospital's outpatient clinic. The sample for this study comprised all new cases of IH diagnosed between 2013 and 2021 at the outpatient clinic at General Hospital that met the inclusion and exclusion criteria. The inclusion criteria for this study were new cases of IH and re-visited infantile hemangioma patients. The data consisted of a total number of new patient visits and generic descriptions of the patient, including age, sex, clinical characteristics, and therapy. The data were analyzed using SPSS 18 for Windows, and the results were presented in tabular form as frequency distributions and percentages for each variable. This study was approved by the Ethics Committee of Research of the Faculty of Medicine, University of Syiah Kuala, Dr Zainoel Abidin Hospital, Banda Aceh, Indonesia, with the certificate number 415/EA/FK-RSUDZA/2021.

RESULT

Between January 2013 and October 2021, 105 patients with IH were treated at the outpatient clinic Dr. Zainoel Abidin General Hospital. The majority of IH

patients, 62 (59%), were in the 0-1 year age group, followed by the 1-4 year age group (26.7%), and those older than 5 years (14.3%). The smallest patient was one month old, and the oldest was thirteen years old. Sixty four patients (61%) were female, while 41 patients (39%) were male (Figure 1).

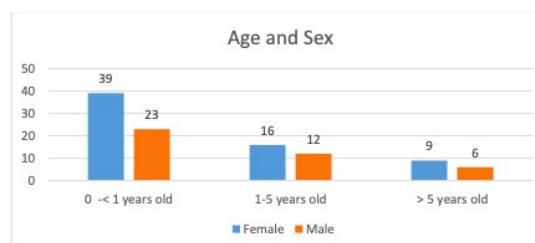


Figure 1. The age and sex distribution of infantile hemangiomas patients at Dr. Zainoel Abidin General Hospital's outpatient clinic in Aceh from 2013 to 2021.

According to Figure 2, nodules were the most often encountered clinical feature of skin lesions, occurring in 69 individuals (65.7%). The other was that 16 patients had red macules (15.2%). Eight patients were found to have a combination of skin lesions, nodules, and red macules.

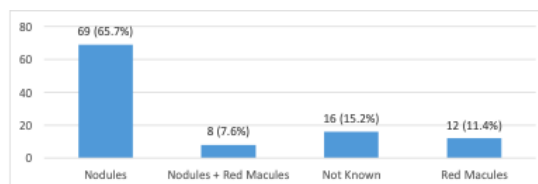


Figure 2. The clinical features of skin lesion distribution in infantile hemangiomas patients at Dr. Zainoel Abidin General Hospital's outpatient clinic in Aceh from 2013 to 2021.

In 44 patients, the most prevalent finding was in the facial region (13.3%). Other prevalent sites of lesions included the superior extremities in 13 patients (12.4%), the neck in seven patients (6.7%), and the inferior extremities in six individuals (5.7%). The remaining sections included the face, neck, extremities, thorax, and belly, as seen in Figure 3.

According to Figure 4, the majority of patients with IH at the outpatient clinic of Dr. Zainoel Abidin General Hospital received a combination of propranolol and oral corticosteroids as the primary treatment option in 20 patients (19%), followed by surgical therapy in 19 patients (18.1%). Ten patients (10%) took propranolol

in combination with oral and topical corticosteroids. Three individuals (2.9%) received timolol maleate. Additionally, we found that patients received single therapy, as reported by 4 patients (3.8%) and 3 patients (2.9%), respectively, consisting of propranolol and an oral corticosteroid.

Figure 3. Distribution of the skin lesion location of infantile hemangioma patients at Dr. Zainoel Abidin General Hospital's outpatient clinic in Aceh from 2013 to 2021.

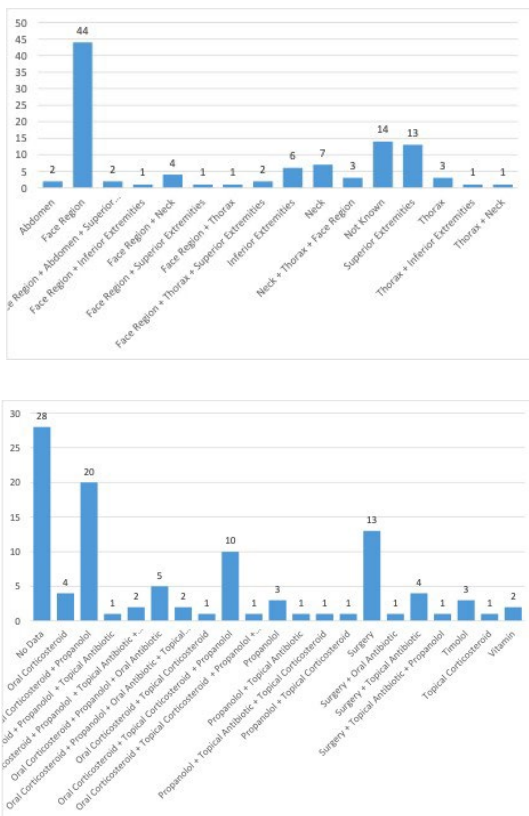


Figure 4. The distribution of therapies in infantile hemangioma patients at Dr. Zainoel Abidin General Hospital's outpatient clinic in Aceh from 2013 to 2021.

Additionally, combinations of propranolol, oral and topical corticosteroids, oral and topical antibiotics, and surgery were considered. A sufficient clearance was noted in 81.9% of the 105 cases of infantile hemangiomas that received medicinal therapy and in 18,1% of the cases that underwent surgery (Figure 5). At this time, all the patients who thought they had been cured did not come back to the hospital.

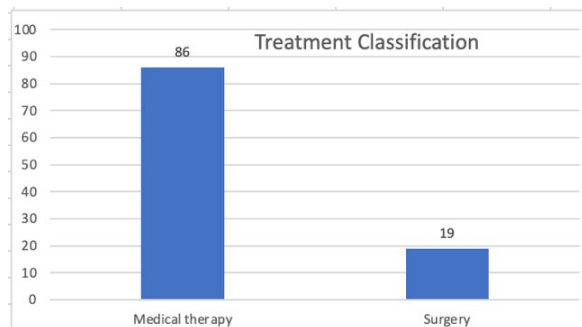


Figure 5. Treatment classification in infantile hemangioma patients at Dr. Zainoel Abidin General Hospital's outpatient clinic in Aceh from 2013 to 2021.

DISCUSSION

With 62 patients, the majority of IH patients (59%) were younger than one year old. In prospective research conducted in the United States, 594 newborns were enrolled, and the incidence of hemangiomas was found to be 4.5% at three months of age. After examining 1034 valid questionnaires from women in Australian hospitals, it was determined that the incidence of infantile hemangioma in Australian neonates at 6 weeks was 2.6%. A study of 6-year-old children in Tyrol, Austria, found that roughly 3% of mature newborns had hemangiomas, while the frequency of hemangiomas was as high as 12.5% in preterm infants.^{9,10} Lidyawaty and Zulkarnain stated that the majority of IH patients in Surabaya were under the age of one year (71.42%).¹¹

Almost all IH with a superficial component manifest themselves within the first month of life, and the majority double in size within the first two months. The early proliferative phase is characterized by rapid nonlinear growth, with the peak period of IH growth occurring between 5.5 and 7.5 weeks of age. While 80% of growth occurs by three months of age, 80% of IH complete all growth by five months of age. After peak rapid development, the late proliferative stage of continuous slower growth often stops by 9 months of age; just 3% of IH have clinically verified growth beyond this age. The early and late proliferative growth phases are followed by a slower involution phase that lasts months to years in length.^{1,12}

We discovered that the majority of IH patients (61.0%) were girls, compared to males (39%), with a female-to-male ratio of 1.5:1. Seiffert et al. discovered that females were more likely to have IH than males. In Germany, the risk of IH is approximately 1.4 times greater for females than for boys.⁵ Prospective studies in the United States and Europe have revealed that

newborns with IH are more likely to be female (male to female ratios range from 3:1 to 1.4:1), white, non-Hispanic, Caucasian, premature, and of low birth weight, and up to 30% of preterm babies are affected, particularly those weighing less than 2500 g.^{1,4} In India, a retrospective study discovered a female predominance of 2.3:1.^{1,4,13}

The incidence of IH in Germany between 2007 and 2012 was 2.0%–3.2%, according to an analysis of medical data from people with medical insurance in the country. In Taiwan, a study examined IH in pigmented birthmarks on 500 infants and discovered that the incidence of IH was 0.2%.¹⁰

In 69 patients, the most common type of skin lesion was nodules (65.7%). The others were red macules and a combination of nodules and red macules on the skin. Lydiawati et al. (2020) stated that macules, tumors or nodules, and plaque were the most frequently encountered lesions in IH.¹¹ The majority of IH have nonlinear growth curves. An IH begins to multiply after 1–3 weeks, but an IH begins to proliferate within the first 3 months of life; as a result, tumors may not be recognized until after birth.⁶

Infantile hemangiomas can be distinguished from other childhood malignancies by their characteristic bright red skin lesions and specific life cycle.⁸ These lesions are often less than 3 cm in diameter and are usually found on the face, neck, and trunk. Infantile hemangiomas may manifest at birth as mild telangiectasias or reddish macules, but they most frequently become evident between two and three weeks of age after proliferation begins. Deep IH consists of subcutaneous tissues, is blue in color, and develops later than surface lesions. Infantile hemangiomas have a biphasic life cycle that includes proliferating and regressing. The proliferation period, which begins in the first weeks of life and lasts until 4 to 6 months of age, is characterized by fast growth. Up to 80% of growth happens between the ages of three weeks and three months. Following proliferation, involution begins, marked by a stop to growth and a progressive resolution of IH throughout early childhood.¹² Regression occurs at a variable rate and extent, ranging from partial to complete resolution over a period of one to ten years.^{1,8} This disease can cause lifelong deformity due to skin scarring or anatomic landmark distortion.¹⁴

We discovered that the most frequently occurring location was the facial region. The remaining sections included the face, neck, extremities, thorax, and belly. Wang et al. (2017) observed that the craniofacial and neck region (109), which accounted for

50% of all IH, was the most common location, followed by the trunk (44), extremities (36), visceral involvement (16), and diaper area (12). Epidermis, dermis, and subcutaneous fat of the skin were the predilection areas, but they can also affect internal organs such as the liver, gastrointestinal tract, respiratory tract, brain, and other organs.² Infantile hemangiomas have a range of morphologies, ranging from benign, tiny growths to functionally debilitating masses. These lesions are often less than 3 cm in diameter and are usually found on the face, neck, and trunk.⁷

The anatomic location of an IH may have prognostic significance, for example, newborns with segmental or large focal IH overlaying the lumbosacral spine may be at a greater risk of spinal cord tethering or genitourinary problems. Other IH of the head and neck may predispose babies to ocular axis occlusion, astigmatism, amblyopia, tear duct occlusion, airway hemangiomas, and an increased risk of ulceration and deformity.³

Multiple lesions (usually more than five) increase the chance of visceral involvement, most notably in the liver and gastrointestinal tract. Visceral lesions are generally asymptomatic, benign, and self-limiting; however, they can rarely result in high-output cardiac failure via a shunt mechanism. In the case of suspected visceral hemangiomas, ultrasound, computed tomography, or magnetic resonance imaging can assist in differentiating an IH lesion from a more malignant process. Certain congenital syndromes have been associated with the presence of IH, which is frequently anatomically specific. PHACE(S), a congenital syndrome characterized by posterior fossa brain malformations, hemangiomas, arterial anomalies, aortic coarctation, cardiac defects, ocular abnormalities and possibly ventral neural defects may be associated with large segmental hemangiomas (>5 cm in diameter), particularly those on the face. PHACE(S) is a somewhat uncommon but not uncommon condition.^{1,3,4}

The majority of patients with IH at Dr. Zainoel Abidin General Hospital's outpatient clinic received no therapy or a combination of propranolol and oral corticosteroids. Additionally, combinations of propranolol, oral and topical corticosteroids, topical timolol, oral and topical antibiotics, and surgery were considered. Due to spontaneous involution, the majority of IH does not require treatment. Nonetheless, approximately 10% of cases require immediate treatment due to their size, location, and consequences.² Numerous treatment regimens were considered for difficult IH, based on their location, size, and features.⁵

Using numerous therapy modalities concurrently may result in a quicker clinical response.⁷

This research has several limitations. Patients were admitted to our hospital, which treats 86 patients medically and performs¹⁹ surgical procedures, some did not return to the hospital after they believed they had been cured. The treatment eligibility determination, made by the same center's team of doctors, is an example of selection bias. Additionally, more significant and comparable sample sizes across all groups would have been preferred for a more precise statistical comparison. It is unusual nowadays for a dermatology unit to be focused on medical therapy and a pediatrics section to be committed to treating surgery in the same hospital, which restricts this kind of inquiry.

There are several important concepts are emphasized in guideline for the management of IH. Indications include ulcers, very thick lesions, permanent scarring and disfigurement (such as facial IH, functional impairment (such as periorbital IH), associated abnormalities and lesions that interfere with vital organs such as the eyes, mouth, nose, genitalia and perianal area, which can potentially cause disability and bleeding. Most IH resolve spontaneously without significant sequelae and are usually completed by 5 months of age. Observation treatment was made in small sizes, located far from vital organs and without complications.^{1,14}

Propranolol is an effective medication with a favorable safety profile. Currently, oral propranolol is considered the first-line therapy for problematic IH.^{14,16} Patients with a single lesion had a better response to treatment in terms of color fading and size reduction. Vasoconstriction, suppression of vasculogenesis and angiogenesis, and activation of apoptosis are all proposed modes of action.⁴ Additionally, male patients responded better to propranolol medication in terms of color fading than female patients, and initiating treatment prior to six months after birth was more beneficial for weight loss.¹⁵ Oral propranolol (a nonselective beta-blocker) is currently considered the first-line medication for IH needing systemic treatment; this therapeutic use is based on randomized controlled trials demonstrating a 60% success rate compared to 4% for patients receiving a placebo.¹⁶

In some cases, such as in the case of beta-blocker resistance or contraindications, systemic corticosteroids are used. Surgical excision may be considered in circumstances needing immediate intervention, such as airway blockage; it may be used

in conjunction with laser therapy to remove remnant tissue; or it may be used when repairing sections of deformity responses.¹⁶ There is compelling evidence to support the use of topical timolol maleate for superficial lesions. Eyedrops may be a more economical option.¹⁶ When it comes to timolol, the most frequently prescribed formulations are 0.5% eyedrop solution and 0.5% gel foaming solution, even if their clinical outcomes do not appear to be comparable.⁸ Laser therapy or a combination of laser therapy was more likely to obtain an "excellent" outcome in terms of treatment outcomes. Combining propranolol orally with laser therapy may improve the curative effect compared to monotherapy. Whether in children under the age of six months or not, laser therapy combined with topical b blockers has shown superior efficacy to other methods. The most effective laser therapy may be the long-pulsed dye laser. Propranolol at a higher dose and for a longer duration of treatment resulted in a better success rate and increased adverse effects. The pulse dye laser in combination with propranolol caused the fewest adverse responses, including ulcers, color sinking, and color decrease. Infantile hemangiomas can be treated with a combination of beta blockers and laser, preferably a longer pulsed dye laser.¹⁷ Laser and operative treatment may be considered for relief of sequelae an, in some considerations early in the disease process, such as very thick or ulcerated HI.¹⁴

The objectives of IH treatment are to avert life-threatening complications and permanent disfigurement, alleviate patient and family psychosocial stress, and avoid unnecessary interventions. The possibility of life-threatening consequences, ulceration, and permanent scarring are all reasons to treat IH. The most common purpose for therapy is to avoid deformity and chronic scarring.⁸

Treatment of IH patients at RSUDZA complies with current guidelines for managing IH. This treatment consists of a combination of oral beta blockers, oral corticosteroids, topical beta-blockers or surgery. Treatment indications are adjusted to the IH condition of the patient. In some cases, with secondary infection, antibiotics have been given. Administration of adjuvant therapy such as vitamins is given in IH conditions that only require observation. Due to the limitations of laser therapy can not be done.

In children, IH is the most common benign tumor. Females are more likely than males to have IH. While the majority of IH is minor and normally resolves on its own without treatment, certain types of IH require clinical attention and structured treatment. The

profiles of infantile hemangiomas in Aceh, Indonesia, were comparable to those in other countries, according to this study.

REFERENCES

- MacArthur K, Puttgen K. Vascular tumors. In: Kang S, Amagai M, Bruckner A, Enk A, Margolis D, McMichael A, et al, editor. Fitzpatrick's Dermatology. 9th ed. New York: McGraw Hill Medical; 2019. p. 2042–58.
- Jung HI. Update on infantile hemangioma. *Clini Exp Pediatr.* 2021; 64(11): 539-72. doi:10.3345/cep2020.02061
- Smith CJF, Friedlander SF, Guma M, Kavanaugh A, Chambers CD. Infantile hemangiomas: an updated review on risk factors, pathogenesis, and treatment. *Birth Defects Res.* 2017;109(11):809-15. doi: 10.1002/bdr2.1023.
- Vivar, Mancini AJ. Infantile hemangiomas: an update on pathogenesis, associations, and management. *Indian J Paediatr Dermatology.* 2018;19: 293-303. doi: 10.4103/ijpd.IJPD_53_18
- Seiffert A, Schneider M, Roessler J, Larisch K, Pfeiffer D. Incidence, treatment patterns, and health care costs of infantile hemangioma: results of a retrospective german database analysis. *Pediatr Dermatol.* 2017; 34(4): 450-7. doi : 10.1111/pde.13187
- Qiu T, Yang K, Dai S, Chen S, Ji Y. Clinical features of segmental infantile hemangioma: a prospective study therapeutic and clinical risk management. 2021; 17: 119-25. doi: 10.2147/TCRM.5291059
- KIM JHS, Lam JM. Paediatrics: how to manage infantile hemangioma. *Drugs in Context.* 2021; 10: 1-13. doi: 10.7573/dic.2020-12-6
- Tiemann L, Hein S. Infantile hemangioma: a review of current pharmacotherapy treatment and practice pearls. *J Pediatr Pharmacol Ther.* 2020;25(7):586-99. doi : 10.5863/1551-6776-25- 7.586
- Wang C, et al. Quality of life in children with infantile hemangioma: a case control study. *Health and Quality of Life Outcomes.* 2017; 15:221: 1-8
- Cai Y, et al. Treatment pattern and outcomes in children with infantile hemangiomas: a retrospective observational analysis. *SAGE Open Medicine.* 2021;9:1-8. doi: 10.1177/205031212111056844
- Lydiawati E, Zulkarnain I. Infantile hemangioma: a retrospective study. *BIKKK.* 2020;32(1):21-6.
- Higgins E, Glover M. Dermatoses and hemangiomas of infancy. In: Griffiths C, Barker J, Bleiker T, Chalmers R, Creamer D, editor. *Rook's Textbook of Dermatology.* 9th ed. New Jersey: WILEY Blackwell; 2016. p. 117.16-23.
- Luca AC, Luca AC, Miron IC, Trandafir LM, Cojocaru E, Pădureț IA, Trandafirescu MF, et al. Morphological, genetic and clinical correlations in infantile hemangiomas and their mimics. *Rom J Morphol Embryol.* 2020; 61(3): 687–695. doi: 10.47162/RJME.61.3.07
- Krowchuk DP, Frieden IJ, Mancini AJ, Darrow DH, Blei F, Greene AK. Clinical practice guideline for the management of infantile hemangiomas. *Pediatrics.* 2019; 143(1): e2018347 5. doi: 10.1542/ped.2018-3475
- Kim J, Hang JW, Roh TS, Lee WJ. Oral propranolol in 23 infants with infantile hemangioma. *Arch Plast Surgery.* 2018; 43: 517- 24. doi: 10.5999/aps.2018.00318
- Filoni A, Ambrogio F, Marco AD, Pacifico A, Bonamonte D. Topical betablockers in dermatologic therapy. *Dermatologic Therapy.* 2021; 34: 1-8. doi: 10.1111/dth.15016
- Fei Q, Lin Y, Chen X. Treatment for infantile hemangioma: a systematic review and network meta-analysis. *Eclinical Medicine.* 2020; 26: 1-5. doi:10.1016/j.eclinm.2020.1005