



## Susceptibility of Male who Have Sex with Male to High-Risk Type *Human Papillomavirus* (HPV) 16 and 18 with Condyloma Acuminata

Prasetyadi Mawardi<sup>1</sup> , Danu Yulianto<sup>1</sup>

<sup>1</sup>Department of Dermatology and Venereology, Faculty of Medicine Sebelas Maret University/ Dr. Moewardi General Hospital, Surakarta-Indonesia

### ABSTRACT

**Background:** Condyloma acuminatum (CA) or genital warts is sexually transmitted infection resulting from *Human papillomavirus* (HPV). It is estimated that CA occurs in >80% of reproductive age in many countries, with the most common types being low risk types HPV 6 and 11, but sometimes could be combined with high-risk types are HPV 16, 18. Gen E6 is an oncoprotein that cooperates with E7 to provide a suitable environment for viral DNA replication and inhibits cellular apoptotic processes. The E6 gene has characteristic properties as a p53 tumor suppressor protein. **Purpose:** To analyse the high-risk types HPV 16 and 18 in CA patients. **Methods:** This study was a cross-sectional, observational analytic study that assessed data collection concurrently over time. Specimens were patients diagnosed with condyloma acuminatum, biopsies were performed, and immunohistochemical (IHC) staining was also performed to examine E6 of high risk types HPV 16 and 18. The sampling technique used sequential sampling, and the inclusion criteria included patients who came to our hospital for treatment. **Result:** Twenty patients with CA were include in this study consist of 11 male and 9 female, meanwhile 9 subjects in homosexual group and 11 subjects in heterosexual group. Based on IHC examination 33% cases were detected of high-risk types HPV 16 and 18 especially among homosexual group. According to t-test obtained significant result of high-risk types and low-risk types of HPV from IHC staining ( $p=0.038$ ). **Conclusion:** Condyloma acuminatum is a sexually transmitted infection that commonly caused by low-risk types HPV 6 and 11, but this study showed high risk types HPV16 and 18 also found in MSM (Male Sex with Male) patients with CA, so that it is necessary to be aware of the possibility of transformation to malignancy.

**Keywords:** *Condyloma acuminata*, MSM, high risk HPV, Immunohistochemistry, Sexual Transmitted Infection.

Correspondence: Prasetyadi Mawardi, Department of Dermatology and Venereology Faculty of Medicine Sebelas Maret University/ Dr. Moewardi General Hospital, Surakarta-Indonesia, Jl. Kolonel Sutarto No.132, Jebres, Kec. Jebres, Kota Surakarta, Jawa Tengah 57126, Indonesia. Phone: +62-8122975021, [prasetyadimawardi@gmail.com](mailto:prasetyadimawardi@gmail.com) / [prasetyadi\\_m@staff.uns.ac.id](mailto:prasetyadi_m@staff.uns.ac.id).

| Article info |

Submitted: 02-06-2022, Accepted: 18-08-2022, Published: 30-11-2022

This is an open access article under the CC BY-NC-SA license <https://creativecommons.org/licenses/by-nc-sa/4.0/>

### BACKGROUND

Genital warts or condyloma acuminatum (CA) is sexually transmitted infections (STIs) caused by human papillomavirus (HPV), specifically subtypes 6 and 11, and are characterized by fibroepithelial neoplastic lesions on the skin and mucous membranes.<sup>1</sup> The prevalence of HPV has increased rapidly over the past 3 years.<sup>2</sup> CA has been found in adults of reproductive age. In general, HPV infection is very common, not only in patients between the ages of 20 and 40, but also in children and adolescents. There was no difference in the incidence of HPV by gender.<sup>3,4</sup> It is estimated that CA infections occur in >80% of

working-age men and women in many countries.<sup>5</sup> Condyloma acuminatum is the most common STI, in Dr. Moewardi General Hospital, Surakarta, Indonesia.<sup>6</sup> HPV mainly affects the epithelial cells of the skin and mucous membranes. Infection rates vary depending on the amount, type, intensity, and duration of viral particle exposure and the patient's immune status.<sup>4</sup> Malignancy is a hazard caused by high-risk (HR) HPV.<sup>7</sup> Some studies suggest that HPV infection is carcinogenic. The fact that interconnected processes, chronic inflammation, and important cofactors can provide new insights for approaches in pathogenesis

and therapeutic.<sup>8</sup> The purpose of this study was to identify HR-HPV in various condyloma acuminata.

## METHODS

This study is an analytical, cross-sectional, observational study with data from July 2020 to October 2020 at Dr. Moewardi General Hospital, Surakarta, Indonesia. The study specimens were CA skin biopsy specimens that underwent both excision and core biopsy after a histopathological diagnosis of CA. In addition, one immunohistochemical staining for polyclonal HPV 16 and HPV 18 E6 Bioss antibodies® was performed at Pathology Laboratory Darma Usada November 2nd 2020 until November 14th 2020. Label and bind directly to the target antigen, a one-step staining method because there is only one labeled antibody. Histopathological diagnosis of CA and analysis of IHC staining was performed by a pathologist. The interpretation was positive if cells were stained in the nucleus or combined in the nucleus and cytoplasm. Categorical variables were described as numbers and percentages and continuous variables were expressed as medians. The demographics characteristic data include sex, age, occupation, sex orientation, and HIV status. The difference in the expression of gen E 6 HPV 16 and 18 on CA patients with low risk strain HPV and high risk strain HPV

groups infection was analyzed by *t*-test. All data were statistically analyzed with SPSS version 22 and a *p*-value of 0.05 was considered significant. This study was approved by the Health Research Ethical Committee of Dr. Moewardi Hospital/Faculty of Medicine, of Sebelas Maret University, Surakarta, Indonesia (803/VI/HREC/2020).

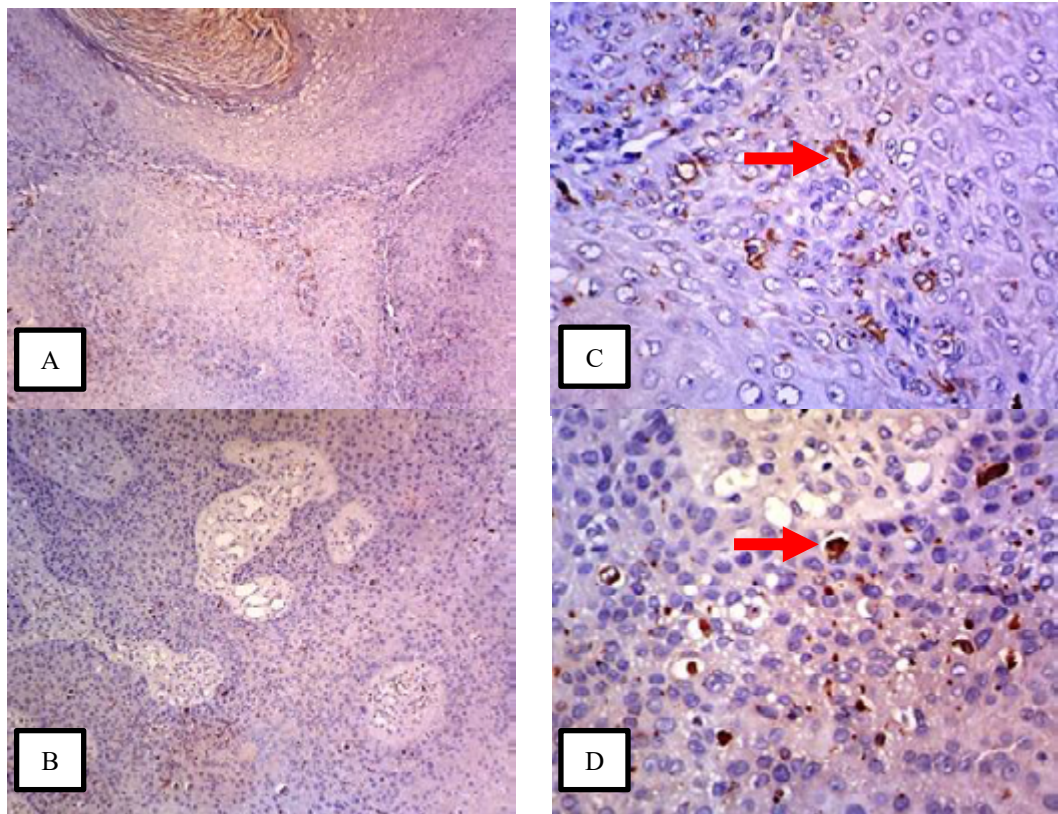
## RESULT

Our sample consisted of 20 patients, 11 male and 9 female, aged 16 to 67 years, mean age was 41.27 ± 14 years, based on sexual orientation are grouped into 2 categories, namely homosexual (40 %) and heterosexual (60%). In contrast, all women with CA had heterosexual. Table 1 described the demographic data from all the subject of the study who were patient diagnosed with CA from July to October 2020 at Dr. Moewardi General Hospital. In this table, most patients were younger than 50 years (90%). Patients were mainly students and private employees, depending on their occupation, 14 (70%). Only 1 patient is official. According to anti-HIV testing, 6 male CA patients with HIV positive (66.7%) and all females revealed HIV negative. When examining HPV strains, 3 patients are MSM (33.3%) showed HR HPV strains. HR-HPV was not found in women (Table 2).

**Table 1.** Characteristic of study

	Male	%	Female	%
Gender	11	55	9	45
Age				
< 20 y.o	3	15	-	
21-30	5	25	2	10
31-40	2	10	4	20
41-50	0		2	10
51-59	0		-	
61-70	1	5	1	5
Occupation				
Civil service employee	0		1	5
Employee	8	40	3	15
Student	3	15	-	
Housewife	0		4	20
Farmer	0		1	5
Sexual Orientation				
Homosexual	8	40	-	
Heterosexual	3	15	9	45
HIV				
Reactive	6	30	-	
Non-reactive	5	25	9	45

HIV=Human Immunodeficiency Virus



**Figure 1.** A & B Immunohistochemistry staining showed dispersed single cell staining in well-differentiated squamous cell carcinoma, C & D shown E6 high risk- HPV expression with brown-coloured cytoplasmic (red arrow). (Magnification 10x).

The HPV genome is divided into three main parts, namely, long control region (LCR), early region (E) and late region (L). The E region codes for proteins required for viral gene expression, replication and survival. E6 is an oncoprotein that cooperates with E7 to provide a suitable environment for viral DNA replication and inhibits cellular apoptotic processes. The E6 gene has characteristic properties as a p53 tumor suppressor protein. Stained slides were analyzed by two pathologists for variable representation of epithelial and stromal components and immunoreactivity. Squamous epithelial cells, with brown-colored cytoplasmic staining for E6,7 protein, were identified and graded as follows: 0, no staining; 1.1–25% staining; 2.26–50% staining; 3.51–75% staining; and 4.76–100% staining. The staining intensity for each marker was not taken into consideration. The examination and scoring of immunohistochemistry slides were confirmed by a panel of more than two certified professionals in pathology. The results revealed gen E6 positivity in 3 cases of 20 patients (15 %).

## DISCUSSION

Condyloma acuminata commonly associated with HPV 16 and 18 subtypes infections with most

contagious and tend oncogenic behavior. Those types lead epidermal dysplasia and develop to malignancy. Based on genotyping study reported 70% cases of squamous cell carcinoma on the cervix related to carcinoma of the vulva, penis, vagina and oropharynx.<sup>9</sup> Condyloma acuminata can be established by history taking and physical examinations, meanwhile immunostaining and polymerase chain reaction (PCR) testing can be used to demonstrate oncogenic potency.<sup>10</sup> Figliuolo et al. reported the incidence of HPV infections among HIV-infected male mostly observed in heterosexual group. In a study of Zambian patients, 56.8% of males were said to have had unprotected sex eventhough after genital ulcers. In Brazil, Figliuolo et al. HPV incidence has been observed in HIV-positive heterosexual men.<sup>11</sup> The prevalence of HPV infections in our study commonly found in heterosexual compare to homosexual group (60% : 40%). Previous study from Insinga et al. reported that CA mostly occurs among women over the age of 20 and men over 25-years-old, in contrast to our result that the highest incidence of CA among women over 31-years-old.<sup>12</sup> One of Karadaghy et al. A cross-sectional study conducted found that 5.5% of students contracted CA during the study period.<sup>13</sup>Z

**Tabel 2.** Sexual Orientation to HPV and HIV Correlation

Variable			P value
	MSM	Heterosexual	
Age	23.89 ± 7.22	41.27 ± 14.17	0.004
Gender			
Male	9 (100%)	2 (18.2 %)	0.000
Female	0 (0 %)	9 (81.8%)	
Employment			
Employes	3 (33.3%)	4 (36.4%)	0.888
Unemployes	6 (66.7%)	7 (63.6%)	
HIV			
Reactive	3 (33.3%)	11 (100%)	0.000
Non-reactive	6 (66.7%)	-	
HR- HPV			
Negative	6 (66.7%)	11 (100%)	0.038
Positive	3 (33.3%)	-	

HIV = Human Immunodeficiency Virus

HR-HPV = High Risk-Human Papillomavirus

MSM = Male Sex with Male

Statistical significant with  $p < 0.05$

The transmission rate of condyloma acuminata between infected and susceptible partners is high, about 65%. The incubation period of HPV infection was 3 weeks up to 8 months, and the median time to appearance of skin lesions was 2 months.<sup>14</sup> Our study revealed 6 male patients (30%) with HIV reactive, 5 of them were homosexual. Patients with untreated HIV infection more easily to get CA due to immune system imbalance against the virus.<sup>15</sup> Several studies showed the correlation between CA and HIV/AIDS incidence mostly in homosexual sexual group.<sup>16</sup> A study in Africa reported a significant association between HPV infection and HIV, with immunocompromised patients more likely to develop dysplastic lesions and potential HPV reactivation.<sup>17</sup> Because HPV is considered more contagious than HIV, given the impact of HPV infection on HIV transmission, it is possible that women were exposed to both infections and were infected with HPV before HIV, assuming the effect of HPV infection on HIV transmission.<sup>18</sup> In our study, 3 patients were found to have The HR-HPV strain (15%) was found only in gay men, and one of the 16-year-olds had a child if any previous sexual intercourse was denied. Sinclair et al. Sexual abuse was found to have a 37% chance of CA. 4-8 year olds, 70% of children over 8 years old.<sup>19</sup> A meta-analysis study reported that HR-HPV was more common among HIV-positive MSM and bisexual men than HIV negative men.<sup>20</sup> A study of male volunteers in Kenya found that 3.8% of men with HR had an increased risk of HIV seroconversion-HPV.<sup>21</sup> High-risk HPV integration, particularly types 16 and 18, was associated with

cervical large cell neuroendocrine carcinoma.<sup>22</sup> A retrospective study revealed which men had a higher HPV-associated contingency of developing KA, intraepithelial squamous anal lesions and HPV-associated anal carcinoma, compared with women.<sup>23</sup> Whereas men and women share the main HPV types, prevalence varies between the man and women. There are differences in prevalence between sexes. In men, most high-risk carcinogenic types are associated with HPV 18. In women, HPV 16 is the most common high-risk type.<sup>24</sup> Considering that approximately 68.2% of invasive cervical cancers are associated with HPV 16 or 18, these data emphasize the importance of screening.<sup>25</sup> Individuals who are immunosuppressed are said to have higher rates of HPV infection, are resistant to treatment of HPV-related diseases and are also prone to accelerated progression of HPV-associated cancers. Concluding that condyloma acuminata is a common sexually transmitted disease often associated with HIV infection. Several types of HPV are highly infectious and oncogenic potency particularly in MSM, whereas immunostaining analysis can be used to determine the high risk oncogenic strains. All patients with HR-HPV in our study are MSM. Furtherly, examination of high risk strains of CA using IHC staining can be done with a larger and varied number of samples, and can also be used as a screening in cases of suspected malignancy.

#### Limitation Of The Study

A Single centre study with small sample.

**Acknowledgement**

We would like to thank Dr. dr. Cahyono Hadi SpOG(K-Fer), Director of Dr. Moewardi General Hospital, for willing to provide funding for this research.

**Author Contribution**

All authors contributed to data analysis, drafting or revising the article, have agreed on the journal to which the article will be submitted, gave final approval of the version to be published, and agree to be accountable for all aspects for the work

**Conflict of Interests**

None declared.

**REFERENCES**

1. Androphy EJ, Kirnbauer R. Human papillomavirus infections. In: Goldsmith LA, CAtz SI, Gilchrest BA, Paller AS, Leffell DJ, Wolff K, editors. Fitzpatrick's Dermatology in General Medicine. 8<sup>th</sup> ed. New York: Mc Graw Hill; 2012. p. 2421-33.
2. Centers of Disease Control and Prevention. Community Approaches to Reducing Sexually Transmitted Disease Initiative. Sexually transmitted diseases 2021; 48(1): 49-55.
3. Winer RL, Koutsky LA. Genital human papillomavirus infection. In: Holmes KK, Sparling PF, Stamm WE, Piot P, Wasserheit JN, Corey L, et al, editors. Sexually Transmitted Disease. 4<sup>th</sup> ed. New York: Mc Graw Hill; 2008. p.489-508.
4. Handsfield HH. Color Atlas & Synopsis of Sexually Transmitted Disease: Human Papillomavirus Infection and Genital Warts. 3<sup>rd</sup> ed. New York: Mc Graw Hill; 2011.p.133-148
5. Parthenis C, Panagopoulos P, Margari N, Kottaridi C, Spathis A, Pouliakis A, Tsiodras S. The association between sexually transmitted infections, human papillomavirus, and cervical cytology abnormalities among women in Greece. International journal of infectious diseases 2018; 73(1): 72–7.
6. Mawardi P, Febrianto B, Yulianto D, Sumandjar T. Comparing the efficacy of chemical cautery to cryosurgery on CD4+ status of HIV Patients with condyloma acuminata. Clinical, cosmetic and investigational dermatology 2021; 14:1453-1458.
7. De Marco F, Bucaj E, Foppoli C, Fiorini A, Blarzino C, Filipi K, et al. Oxidative stress in HPV-driven viral carcinogenesis: redox proteomics analysis of HPV-16 dysplastic and neoplastic tissues. PloS one 2012; 7(3): 1-13.
8. Fathi R and Tsoukas MM. Genital warts and other HPV infections: Established and novel therapies. Clinic in dermatology 2014; 32(2): 299–306.
9. Egelkrout EM, Galloway DA. The biology of genital human papillomaviruses. In: Holmes KK, Sparling PF, Stamm WE, Piot P, Wasserheit JN, Corey L, et al., editors. Sexually transmitted disease. 4th ed. New York: The McGraw-Hill Companies; 2008. p.463-88
10. Oktavianti RN, Barakbah J. Patient profile condyloma akuminata. Periodicals of dermatology and venereology 2018; 30(3): 240-7.
11. Figliuolo G, Maia J, Jalkh AP, Miranda AE, Ferreira LCL. Clinical and laboratorial study of HPV infection in men infected with HIV. International brazilian journal of urology 2012; 38: 411-8.
12. Khopkar US, Rajagopalan M, Chauhan AR, Kothari-Talwar S, Singhal PK, Yee K, Garland SM. Prevalence and burden related to genital warts in India. Viral immunology 2018; 31(5): 346–51.
13. Karadaghy B, Camal NM, Othman N. Prevalence and knowledge about genital and other warts among students in sulaimani polytechnic university: A cross-sectional study. Kurdistan journal of applied research 2018; 23: 96-101.
14. Williamson AL. The interaction between human immunodeficiency virus and human papillomaviruses in heterosexuals in Africa. Journal of clinical medicine 2015; 4(4): 579-2.
15. Wiraguna A, Andriani P, Adiguna M. Comparison of plasma zinc levels Among HIV+ and HIV- Subjects Infected with Condyloma Acuminata. Asian pacific journal of cancer prevention 2019; 20(3): 943-9.
16. Yarchoan, R., and Uldrick, T. S. HIV-Associated Cancers and Related Diseases. New England journal of medicine 2018; 378(11): 1029–41.
17. Galati L, Brancaccio RN, Gupta P, Lohmann E, Robitaille A, Mandishora RSD, Gheit T. Diversity of human papillomavirus in the anal canal of HIV-positive and HIV-negative men. Journal of infection 2021; 82(1): 112–6.
18. Araldi RP, Sant'Ana TA, Módolo DG, de Melo TC, Spadacci-Morena DD, de Cassia Stocco R, de Souza EB. The human papillomavirus (HPV)-related cancer biology: An overview. Biomedicine & pharmacotherapy 2018; 106: 1537–56.
19. Wangu Z and Hsu KK. Impact of HPV vaccination on anogenital warts and respiratory

- papillomatosis. Human vaccines & immunotherapeutics 2016; 12(6): 1357–62.
20. Machalek DA, Poynten M, Jin F, Fairley CK, Farnsworth A, Garland SM, et al. Anal human papillomavirus infection and associated neoplastic lesions in men who have sex with men: a systematic review and meta-analysis. *The Lancet oncology* 2012; 13(5):487-500.
  21. Smith JS, Moses S, Hudgens MG, Parker CB, Agot K, Maclean I, et al. Increased risk of HIV acquisition among kenyan men with human papillomavirus infection. *The Journal of infectious diseases* 2010; 201(11):1677-85.
  22. Alej M, Alemany L, Clavero O, Quiros B, Vighi S, Seoud M, Lloveras B. Contribution of Human papillomavirus in neuroendocrine tumors from a series of 10,575 invasive cervical cancer cases. *Papillomavirus research* 2018; 5: 134–42.
  23. Habibie DP, Barakbah J. Retrospective Study: Profile of condylomata acuminata patients on HIV/AIDS. *Periodical of dermatology and venereology* 2016; 28(3): 1-6.
  24. Park E, Kim JY, Choi S, Kim DS, Oh YL. Carcinogenic risk of human papillomavirus (HPV) genotypes and potential effects of HPV vaccines in Korea. *Scientific reports* 2019; 9(1): 31-7
  25. Bruni L, Albero G, Serrano B, Mena M, Gómez D, Munoz J. *Human Papillomavirus and related diseases in the world*. Barcelona: ICO/IARC Information centre on HPV and cancer 2019.