



Epidemiologic Profile of Seborrheic Keratosis and Acrochordon at the National Referral Hospital in Indonesia

Lusiana Purbasari¹, Anindya Larasati¹, Larisa Paramitha Wibawa¹ 

¹Dermatology & Venereology Department, Faculty of Medicine Universitas Indonesia, Jakarta - Indonesia

ABSTRACT

Background: Seborrheic keratosis (SK) and acrochordon are common benign neoplasms of the skin that can be diagnosed clinically. Management of SK and acrochordon has a wide range of purposes, including aesthetic appearance and health concerns. Epidemiologic data for these entities is rare in Indonesia. **Purpose:** To determine the epidemiology of SK and acrochordon patients at the Dermatology & Venereology (DV) Clinic, dr. Cipto Mangunkusumo National Central General Hospital (RSCM). **Methods :** Patient registry data at the DV Clinic, RSCM from 2014 to 2017 was collected retrospectively. Data was obtained by using the total sampling method and retrieving characteristics such as age, sex, and outpatient-based procedures. **Result:** In the four-year period, there were 1.202 SK patient visits with 447 new cases and 374 acrochordon patient visits with 169 new cases. The proportion of SK patients in this study was 2.2%; acrochordon was 1.8% of all patients at the DV Clinic of RSCM. The highest prevalence of SK was found in patients older than the 6th decade, while for acrochordon, it was within the 4th decade. Both SK and acrochordon were seen higher in women, with a male-to-female ratio of 1:2. Electrosurgery was the most common office procedure performed. **Conclusion:** Seborrheic keratosis and acrochordon proportion, respectively, are 2.2% and 1.8% at the DV Clinic, RSCM. Seborrheic keratosis and acrochordon are more frequent in women, with the peak occurring in 6th decade and 4th decade, respectively.

Keywords: Seborrheic keratosis, acrochordon, epidemiology, office procedure.

Correspondence: Larisa Paramitha Wibawa, Dermatology & Venereology Department, Faculty of Medicine Universitas Indonesia/ RSUPN dr. Cipto Mangunkusumo, Jl. Pangeran Diponegoro No. 71, Jakarta Pusat, DKI Jakarta, 10430, Indonesia, e-mail: larisa.paramitha@ui.ac.id, phone (+6221)31935383.

| Article info |

Submitted: 15-01-2023, Accepted: 29-08-2023, Published: 30-11-2023

This is an open access article under the CC BY-NC-SA license <https://creativecommons.org/licenses/by-nc-sa/4.0/>

BACKGROUND

Seborrheic keratosis (SK) and acrochordon are common epidermal skin tumors that appear to become more frequent with increasing ages.^{1,2} SK is usually presented as a pigmented lesion, while acrochordon may range from a skin-colored to hyperpigmented pedunculated lesion. Both SK and acrochordon are commonly found in the head and neck area.^{2,3} Both of them are typically benign and can be diagnosed clinically. However, in some cases, a further diagnostic examination would be needed.^{2,4}

Hereditiy, sun exposure, and human papilloma virus (HPV) have been suggested as risk factors for SK,³ while acrochordon is commonly found in women around menopausal age and is often associated with obesity, diabetes, acromegaly, and intestinal polyps.^{5,6} Many procedures may be performed to destruct SK and

the acrochordon lesion.^{1,7} Epidemiology data for these diseases have been rarely reported, especially in Indonesia. The data on SK and acrochordon prevalence at dr. Cipto Mangunkusumo Hospital (RSCM) has not been reported yet. This study aims to determine the epidemiologic profile of SK and acrochordon at the Dermatology and Venereology (DV) Clinic at RSCM from 2014 -2017.

METHODS

Patient registry data was retrospectively collected at the DV Clinic at RSCM from 2014 to 2017. The data was obtained by using the total sampling method. The proportions of SK and acrochordon were calculated based on new patient visits compared to all new patient visits at the DV Clinic at RSCM.

Characteristics such as age and sex were collected from the new patient registry, and for outpatient-based procedures, they were collected from total SK and acrochordon patient registry data. The data will be presented as figures and percentages. This study was ethically approved by the Ethic Committee of the Faculty of Medicine, Universitas Indonesia with protocol number 23-01-0087.

RESULT

The total new patient population at the DV Clinic at RSCM from 2014 to 2017 was 20.743. In that period of four years, there were 1.202 SK patients and

374 acrochordon patients, of whom 447 and 169 were new cases, respectively. According to this data, the proportion of SK and acrochordon patients in this study was 2.2% and 1.8%, respectively. Figures 1A and 1B show the number of new cases of SK and acrochordon by sex group according to the year. Figures 2A and 2B show the total number of new cases of SK and acrochordon by age group. Figures 3A and 3B show office procedure modalities for SK and acrochordon patients. Histopathological examinations were performed on 34 SK patients and 4 acrochordon patients.

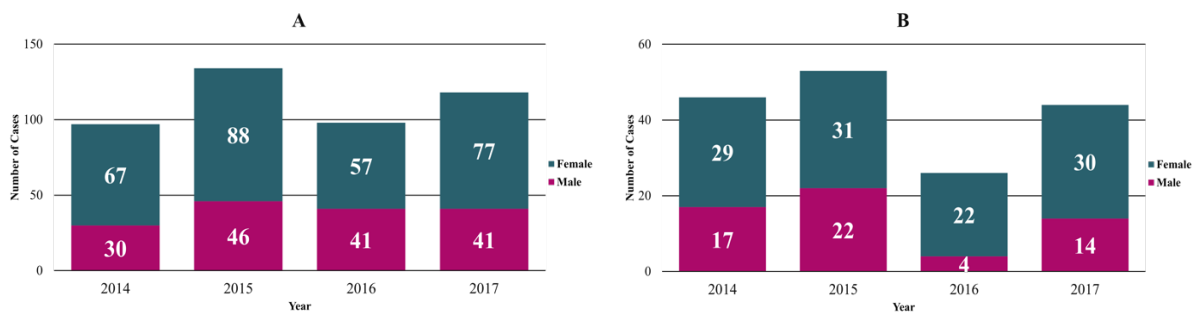


Figure 1. Number of new cases by sex group according to year for (A). Seborrheic keratosis and (B). Acrochordon at the Dermatology and Venereology Clinic at dr. Cipto Mangunkusumo Hospital in 2014 – 2017.

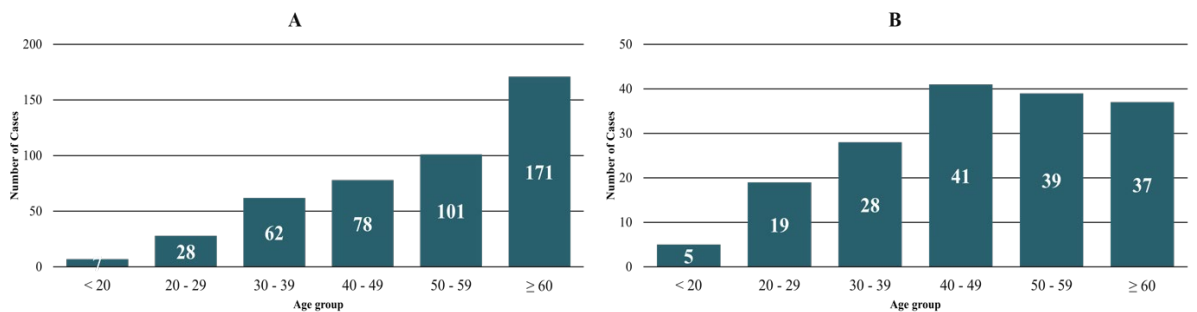


Figure 2. Total number of new cases by age group for (A). Seborrheic keratosis and (B). Acrochordon at the Dermatology and Venereology Clinic at dr. Cipto Mangunkusumo Hospital in 2014 – 2017.

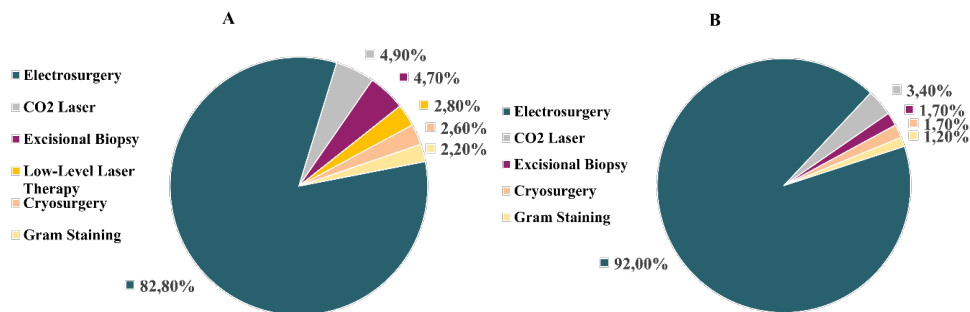


Figure 3. Office procedure modalities for (A). Seborrheic keratosis and (B). Acrochordon patient at the Dermatology and Venereology Clinic at dr. Cipto Mangunkusumo Hospital in 2014 – 20.

DISCUSSION

The total new patient population at the DV Clinic at RSCM in that 4 years' period was 20.743. In that period there were 447 SK and 169 acrochordon new cases. A study about the epidemiologic profile of benign skin tumors at Prof. Dr. R. D. Kandou Central General Hospital Manado from 2009 to 2011 reported that the total new patient population at the DV Clinic was 3.055, with 478 of them being diagnosed with benign skin tumors. Of the 478 benign skin tumor patients, SK was the second-highest case with a total of 118 cases after verruca vulgaris, while acrochordon was not on the list. The proportion of SK in that study was 3.9%, which is about 1.5 times higher than the proportion of SK in our study (2.2%).⁸ This is probably due to the higher proportion of new patients coming to the DV Clinic at RSCM, Jakarta, annually. Other possibilities may be reflected by the fact that most of the SK and acrochordon patients had already been treated by other primary or secondary health care providers around our hospital.

The highest frequency of SK was found in the age group of ≥ 60 years (38.3%), followed by 50 – 59 years (22.6%). As mentioned in the previous study, there was an increase in SK frequency after the age of 50 years.^{9,10} Acrochordons were found highest in the 40-49 age group (24.2%), followed by the 50-59 age group (23%), as stated that their occurrence increases after the fourth decade of life.⁷ Although the pathogenesis remains unclear, it is suggested that chronic skin exposure to ultraviolet (UV) B radiation from sunlight may contribute as a factor to induce SK through stress oxidative mechanisms.^{11,12} The epidermal growth factor receptor (EGFR), which results from the activation of reactive oxygen species (ROS), played an important role in the development of SK. This cumulative oxidative damage is more likely to occur as one ages.^{11,13} Acrochordons have been associated with insulin resistance and hyperinsulinemia. Decreasing skeletal muscle insulin sensitivity, elevation of adiposity, and physical inactivity are known to be the determinants of insulin resistance, which tends to increase in the elderly.^{14,15}

The proportion of SK in this study was found to be higher in women (64.7%) than in men (35.3%), with a female-to-male ratio of 2:1. A similar proportion by sex group was also seen in acrochordon, with 66.2% occurrence in women compared to 33.7% in men (female-to-male ratio 2:1). Although other studies stated no sex difference in SK, this finding might be due to the hospital-based registry in our study.¹⁶ Women often pay more attention to their appearance

and seek therapy to improve it. A study in the United States found that women are more concerned about the SK treatment than men, particularly in the face area, due to appearance and health reasons.¹⁷ Previous studies reported equal prevalence of acrochordons among males and females, but some suggested they are more common in middle-aged and elderly women.^{6,18} This is explained by the possible role of androgen and estrogen receptors in the pathogenesis of skin tags. There are significant estrogen receptor and androgen receptor levels in the development of skin tags, which in turn explains the absence of skin tags before puberty and the decrease in their development following menopause.¹⁹

The most frequently performed procedure in SK and acrochordon patients in this study was electrosurgery. Various studies about SK therapy found that cryosurgery is the most common removal procedure in the American population. Other commonly used procedures for SK include excision, electrosurgery, curettage, or combinations of these.²⁰⁻²² Medical treatment of acrochordons includes several medical procedures, such as snip excision, cauterization/electrosurgery, cryosurgery, and CO₂ laser.⁴ Electrosurgery was more common compared to cryosurgery in our institution due to the side effect of hypopigmentation in skin of color for the treatment of cryosurgery.²³ Most procedures for these lesions were done for aesthetic purposes, thus electrosurgery and CO₂ laser were chosen more frequently in our DV Clinic. CO₂ laser was the second most common procedure for SK and acrochordons due to its cost and not being covered by our National Health Insurance.

SK lesions typically occur as circumscribed patches or plaques and later become more papular or verrucous with a "stuck-on appearance".¹ While acrochordon is also known as skin tags, soft warts, fibroepithelial polyps, and papillomas.^{2,5} Most of these tumors were easily diagnosed clinically by dermatologists, but atypical lesion needed a biopsy. Histopathological examinations were performed on 34 (4.7%) SK patients and 4 (2.4%) acrochordon patients. This number was relatively small, compared to the total number of new SK and acrochordon cases, due to the routine use of dermoscopy at the DV Clinic at RSCM to improve diagnosis. In our institution, Gram staining is commonly performed to exclude infection from inflammation, while low-level laser therapy is performed to reduce inflammation and hasten wound healing. These last 2 procedures were probably performed after previous primary treatment for SK and

acrochordon, which sometimes cause superficial wounds.

Seborrheic keratosis and acrochordon are common benign skin tumors, with 2.2% and 1.8% proportions at the DV Clinic at RSCM, respectively. The frequency of SK and acrochordons reaches its peak in the 6th decade and the 4th decade, respectively. The proportion of SK and acrochordons in this study was found to be higher in women, with both having 1:2 male-to-female ratios. The most common procedure for SK and acrochordon at the DV Clinic at RSCM is electrosurgery. Only 4.7% SK and 2.4% acrochordon were biopsied to rule out malignancy in atypical lesions.

REFERENCES

- Cuda JD, Rangwala S, Taube JM. Benign epithelial tumors, hamartomas, and hyperplasias. In: Kang S, Amagai M, Bruckner AL, Enk AH, Margolis DJ, McMichael A, et al, editors. Fitzpatrick's dermatology. 9th ed. New York: McGraw-Hill; 2019. p.1799-1802.
- Belgam Syed SY, Lipoff JB, Chatterjee K. Acrochordon. [Updated 2021 Aug 11]. Treasure Island (FL): StatPearls Publishing; Downloaded in 2022 Jan 15.
- Phulari RG, Buddhev K, Rathore R, Patel S. Seborrheic keratosis. *J Oral Maxillofac Pathol.* 2014; 18(2): 327-30.
- Minagawa A. Dermoscopy-pathology relationship in seborrheic keratosis. *J Dermatol.* 2017; 44(5): 518-24.
- Rasi A, Soltani-Arabshahi R, Shahbazi N. Skin tag as a cutaneous marker for impaired carbohydrate metabolism: A case-control study. *Int J Dermatol* 2007; 46: 1155-59.
- Maluki AH, Abdullah AA. Metabolic associations with skin tags. *Int J Dermatol Clin Res.* 2016;2(1):004.
- Pandey A, Sonthalia S. Skin tags. [Updated 2021 Dec 12]. In: StatPearls [Internet]. Treasure Island (FL): StatPearls Publishing; 2022.
- Gefilem GA, Suling PL, Kapantouw MG. *Profil tumor jinak kulit di poliklinik kulit dan kelamin RSUP Prof. Dr. R. D. Kandou Manado periode 2009-2011* (in Indonesian language). *J E-Clinic.* 2013; 1(1): 1-10.
- Gill D, Dorevitch A, Marks R. The prevalence of seborrheic keratosis in people aged 15 to 30 years. *Arch Dermatol.* 2000;136:759-62.
- Belmourida S, Meziane M, Ismaili N, Benzekri L, Senouci K. Giant seborrheic keratoses: an historical case. *J Clin Med Img Lib.* 2021;7:174.
- Rhinnerthaler M, Bischof J, Streubel MK, Trost A, Richter K. Oxidative stress in aging human skin. *Biomolecules.* 2015;5:545-89.
- Widiatmoko A, Tantari SHW, Ardian Y. *Korelasi antara kadar superoksida dismutase dengan malondialdehid pada jaringan keratosis seboroik* (in Indonesian language). *MDVI.* 2019;46(3):127-31.
- Saeed AK, Salmo N. Epidermal growth factor receptor expression in mice skin upon ultraviolet B exposure – seborrheic keratosis as a coincidental and unique finding. *Adv Biomed Res.* 2012;1(4):1-9.
- Saldivar GG, Gutierrez RR, Candiani JO, Gonzalez JG, Flores MG. Skin manifestations of insulin resistance: from a biochemical stance to a clinical diagnosis and management. *Dermatol Ther.* 2017;7(1):37-51.
- Karakelides H, Irving BA, Short KR, O'Brien P, Nair KS. Age, obesity, and sex effects on insulin sensitivity and skeletal muscle mitochondrial function. *J Diabetes.* 2010;59(1):89-97.
- Sun MD, Halpern AC. Advances in the etiology, detection, and clinical management of seborrheic keratoses. *J Dermatol.* 2022; 238(2): 205-17.
- Rosso JQ. A closer look at seborrheic keratoses: patient perspectives, clinical relevance, medical necessity, and implications for management. *J Clin Aesthet Dermatol.* 2017;10(3):16-25.
- Safoury OS, Ibrahim M. A clinical evaluation of skin tags in relation to obesity, type 2 diabetes mellitus, age and sex. *Indian J Dermatol.* 2011;56(4):393-7.
- Safoury OE, Rashid L, Ibrahim M. A study of androgen and estrogen receptors α , β in skin tags. *Indian J Dermatol.* 2010;55(1):20-4.
- Moscarella E, Brancaccio G, Briatico G, Ronchi A, Piana S, Argenziano G. Differential diagnosis and management on seborrheic keratosis in elderly patients. *Clin Cosmet Investig Dermatol.* 2021;14:395-406.
- Wollina U. Recent advances in managing and understanding seborrheic keratosis. *J Med Sci.* 2018;6(11):2270-5.

22. Wood LD, Stucki JK, Hollenbeak CS, Miller JJ. Effectiveness of cryotherapy vs curettage in the treatment of seborrheic keratosis. *J Am Med Assoc.* 2013;149(10):108-9.
23. Vujevich JJ, Goldberg LH. Cryosurgery and electrosurgery. In: Kang S, Amagai M, Bruckner AL, Enk AH, Margolis DJ, McMichael A, et al, editors. *Fitzpatrick's dermatology.* 9th ed. New York: McGraw-Hill; 2019. p.207.