



Case Report

Difficult Atrial Fibrillation Rate-Control and Digitalis Toxicity in Mitral-Valve Prolapse Patient with HyperthyroidismS. A. Hutomo^{1*} and A. Subagjo^{1,2}¹Faculty of Medicine, Universitas Airlangga, Surabaya, Indonesia.²Department of Cardiology and Vascular Medicine, Faculty of Medicine, Universitas Airlangga, Surabaya, Indonesia.

ARTICLE INFO

Article history:

Submitted August 2020

Reviewed September 2020

Accepted September 2020

Available online September 2020

**Corresponding author:*

suryo.ardi.hutomo-

2015@fk.unair.ac.id

Keywords:

Atrial Fibrillation

Digitalis Toxicity

Rate Control

Hyperthyroidism

Mitral Valve Prolapse

ABSTRACT

Rate-control is important management in patient with atrial fibrillation. The optimum rate control provides a decrease of symptoms, improves hemodynamics and prevents tachycardia-induced cardiomyopathy. Rate-control could be difficult to achieve because of patient's comorbidities and special treatment strategy is needed to resolve it. A-46-yo. male, came to ER with palpitation. Holosystolic murmur was heard at apex, radiating to axilla. ECG showed atrial fibrillation, with rapid ventricular response 180 bpm. Echocardiography showed dilated LA and LV, false-normal LV function with EF 59% and anterior mitral-valve prolapse with moderate mitral regurgitation. Acute treatment was administration of digoxin and beta blockers, but ventricular rate wasn't controlled, until 1.5 mg doses of digoxin was administered. Then patient develops acute digitalis intoxication. After toxicity management, rapid ventricular rate recurs. Patient reevaluation showed hyperthyroidism with low TSH and high T4. Methimazole and propranolol was given and rate-control was achieved shortly after euthyroid state, in 2 months treatment. This patient suffered difficult rate-control despite guidelines-based management. Digitalis intoxication was developed after administration of several therapeutic doses. The diagnosis of hyperthyroidism is central in management of this case. Coexistent of hyperthyroidism and mitral-valve prolapse may be explained by genetic, autoimmune, and thyroid hormone effects in myocardium.

Introduction

Atrial fibrillation is the most common arrhythmia in daily practice. With a prevalence of 1-2% in this decade, it is estimated that this number will continue to increase in the next 50 years. In Indonesia, the incidence of atrial fibrillation always

increases every year, namely 7.1% in 2010, increasing to 9.0% (2011), 9.3% (2012) and 9.8% (2013).^[1,2]

Rate control is one of the main treatments in patients with atrial fibrillation. Optimal control rates can cause reduced complaints and improve hemodynamics by extending ventricular filling time and preventing cardiomyopathy due to tachycardia. Rate control can be done loosely or strictly. The Rate Control Study of Efficacy in Permanent Atrial Fibrillation (RACE) II shows that the control rate is strictly not better than a loose rate control. But sometimes the control rate cannot be achieved with standard rate control, commonly called "difficult atrial fibrillation". In this case a special strategy is needed in its management.^[3]

We reported one patient with mitral regurgitation caused by mitral valve prolapse, and experienced rapid ventricular atrial fibrillation which was difficult to control for heart rate. During treatment, the patient also experienced acute digitalis intoxication and was found to have comorbid hyperthyroidism.

Case Presentation

Mr. S, male, 46 years old came to emergency room with palpitation. Palpitation was felt since 7 days ago, worsening in the last 4 days. It felt especially during heavy activity and fatigue, and improves with rest. In these 2 days it felt even after resting. There is no shortness of breath, chest pain, or swollen

feet. History of diabetes mellitus, hypertension, dyslipidemia is denied.

The patient does not smoke. The patient had never been hospitalized before. On physical examination, irregular-irregular S1-S2 heart sounds were obtained. Holosystolic murmur at cardiac apex radiated to the axilla, grade IV/VI was heard. No rales or wheezing were obtained. Abdomen and extremities are within normal limits. There are no signs of hyperthyroidism such as exophthalmos, enlargement of the thyroid gland, hyperhidrosis or tremor. ECG showed atrial fibrillation with a rapid ventricular response of 180 beats per minute (bpm), normal frontal and horizontal axis. Chest X-ray showed cardiomegaly with 56% cardio-thoracic ratio, grounded apex, left atrial enlargement and cephalization of pulmonary vascularity. Laboratory results within normal limits.

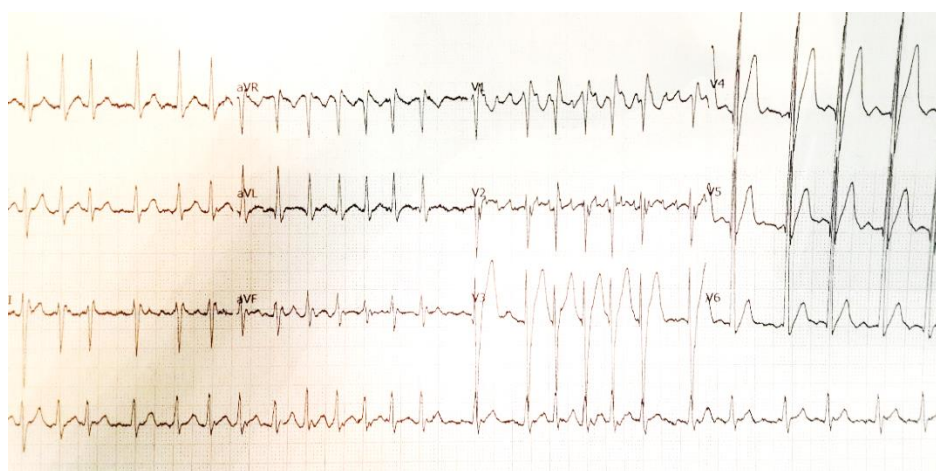


Figure 1. Atrial fibrillation with rapid ventricular response on ECG

Trans-thoracic echocardiography was performed with the following results: (1) valves: there was moderate mitral regurgitation due to anterior mitral-valve prolapse, restricted posterior mitral valve (carpentier type 2) and trivial tricuspid regurgitation. (2) Dilated left atrium (LA) with LA major 6.2 cm, LA minor 6.0 cm; dilated left ventricle (LV) with end diastolic diameter (LVEDD) 5.7 cm; the other chambers were normal; there was no thrombus or

intracardiac vegetation. (3) False-normal LV Systolic Function (EF by Teich 59%; by biplane 61%), Normal RV Systolic Function (TAPSE 1.9 cm). (4) All normokinetics wall motion and (5) eccentric hypertrophy.

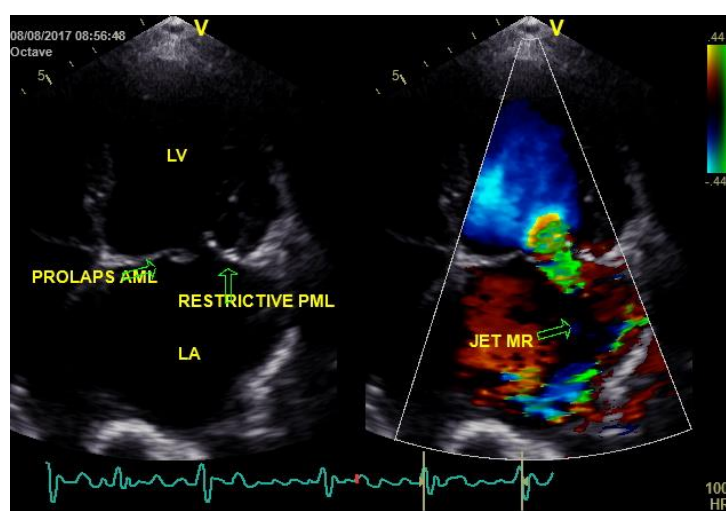


Figure 2. Echocardiography showed dilated LA and LV and moderate-severe mitral regurgitation due to mitral-valve prolapse

Initial assessment was atrial fibrillation (persistent) with a rapid ventricular response, due to mitral regurgitation (caused by mitral valve prolapse). The initial management (at 1st day) was heart rate control through rapid digitalization, using intravenous digoxin (total loading dose of 1.0 mg).

At first, digoxin injection with 0.5 mg intravenously (iv), and an evaluation ECG was carried out 4 hours after digoxin administration. On the ECG recording the evaluation still found atrial fibrillation (FA) rhythms with a rapid ventricular response of 170 bpm. Subsequently, the second digoxin injection was administered (0.25 mg), and the ECG was evaluated for AF with moderate ventricular response of 100 bpm, with palpitation was being

reduced. Furthermore, maintenance of digoxin tablets is given 1x0.25 mg orally (po).

On treatment on the 2nd day, patient felt palpitation again with a blood pressure of 100/60, heart rate 165 bpm, ECG showed AF with rapid ventricular response 170 bpm, then digoxin 0.5 mg iv and bisoprolol 2.5 mg po were administered. ECG evaluation was carried out and a decrease in heart rate with AF with moderate ventricular response 100 bpm. Palpitations are felt to be reduced, but 4 hours after injection of digoxin the patient complains of nausea and profuse vomiting, no abdominal pain is found.

We suspected that there is an acute digitalis intoxication. Then we do rehydration with crystalloid infusion, gave symptomatic drugs injection with ondansetron 3x4 mg iv, stopped digoxin and increased the dose of bisoprolol to 2x5mg orally. We also carried out laboratory tests to support the diagnosis of acute digitalis intoxication, obtained by an increase in Potassium (K 5.3), BUN (12→26) and SK (0.65→1.08). Patients are planned to examine serum digitalis levels, but the laboratory examination was not ready in our hospital.

On the 3rd—6th day of treatment, the patient's condition was improved and vital signs was stable with palpitations had not been felt (ECG showed atrial fibrillation with moderate ventricular response 80—110 bpm), and complaints of gradual nausea and vomiting reduced. But on the 7th day of treatment, the patient complained of palpitation again, with a blood pressure of 110/60 with a heart rate of 160 bpm, and ECG showed atrial fibrillation with rapid ventricular response 160 bpm.

An injection of 150 mg iv amiodarone loading dose was administered for 30 minutes, followed by maintenance 300 mg iv for 6 hours, then 600 mg in 18 hours. Patients performed thyroid physiological examination and obtained an increase in FT4 of 3.97 ng / dL (ref: 0.89—1.76) and a decrease in TSH of 0.06 uIU/mL (0.55-4.78) and a total T3 level of 1.48 ng / mL (ref: 0.60—1.81), which suggests hyperthyroidism. The patient was consulted to internal medicine department, and was assessed as hyperthyroidism with suspicion of Grave's disease (without signs of thyroid crisis). The next procedure is administration of Methimazole 2x20 mg po, propranolol 3x40 mg po and amiodarone was stopped.

After administration of therapy for 5 days, improved thyroid physiological evaluation was obtained. The ECG showed a controlled heart rate with a

ventricular response of 80-110 bpm. On the 14th day the patients were discharged in good condition and given a referral to the heart clinic.

After treatment with anti-thyroid and propranolol drugs for 2 months, the patient performed thyroid physiological evaluation and electrocardiography. Patient has not complained of palpitations, with good hemodynamics. ECG shows an AF with moderate ventricular response 100 bpm with normal thyroid physiological results.

Discussion

Evaluation and acute management of atrial fibrillation

Evaluation and management of acute atrial fibrillation include determination of FA type, hemodynamic stabilization, rate control, sinus rhythm conversion and administration of anticoagulants.^[2,4]

In hemodynamically unstable patients, which are characterized by heart failure, ischemic chest pain, shock and decreased consciousness should be carried out electric cardioversion. In other hand, in patients with stable hemodynamics, direct control or rhythm control can be carried out immediately. The choice of rate or rhythm control is certainly determined based on the characteristics of each case.

Rhythm control is preferred in patients with new onset AF, younger age, and secondary causes of reversible AF. While the rate control is preferred in patients who are difficult or impossible to do Rhythm control, including chronic AF, enlarged size of the atrium more than 4.5 mm, old age, etc.

According to the AFFIRM study, the rate control strategy is not inferior to the rhythm control strategy in terms of Primary End Points (death,

cardiovascular events, etc.). Rate control aims to regulate the ventricular rate when FA occurs, improve hemodynamics, reduce and improve symptoms, prevent heart failure, and reduce the risk of poor cardiovascular outcomes.^[5]

In this case, patients with AF, suffered symptomatic rapid ventricular response, but with stable hemodynamic, so electrical cardioversion was not performed. Rate-control strategy was chosen, because this patient has dilated LA which indicated that AF has occurred for a long time.

Rate control can be done using a variety of drug choices. Among other things: beta-blocker, calcium-channel antagonist, cardiac glycoside (digoxin) and amiodarone. The choice of these drugs, a single or combination drug depends on the symptoms, comorbidities, side effects that can occur, and tolerance in the patient.

Beta-blockers inhibit sympathetic activity (β_1 receptors) in the AV node so that it can inhibit the ventricular rate. These beta-blockers have side effects of bronchoconstriction, fatigue which is contraindicated in asthma patients. Non-dihydropyridine calcium-channel antagonist inhibits AV node conduction by inhibiting calcium channels thereby increasing the refractory period of the AV node. This class of drugs is contraindicated in patients with heart failure and reduced EF, because it has a negative inotropic effect. This drug can also cause hypotension through the effects of vasodilation. Digoxin can reduce ventricular rate by increasing parasympathetic activity thereby reducing AV node conduction. Digoxin has a narrow therapeutic range, and interacts with other drugs (e.g. verapamil, antibiotics) therefore the use of digoxin must be careful especially in elderly patients, decreased kidney function and those who use drugs that can increase the concentration of digoxin in blood.^[6,7]

The use of digoxin in the management of heart rate control in atrial fibrillation, can use fast digitization and slow digitization. Fast digitization can use intravenous or oral injection preparations. Rapid digitalization using intravenous injection was carried out by giving a loading dose of 0.5-1.0 mg, which was divided into 3 times (1/2 dose at the first injection, 1/4 dose on the second and third injection), which then performed maintenance using oral digoxin. Slow digitalization is done by giving oral digoxin tablets 0.25 mg once a day, in 7 days.^[8]

Amiodarone is a drug that can function as a heart rate controller and rhythm converter. Amiodarone has a negative dromotropic effect, used in a small number of patients with acute heart failure, or when beta-blockers or digoxin cannot reduce ventricular rate adequately ^[7]. In acute conditions, intravenous drugs are preferred for rate control, which will be converted to oral preparations for maintenance. The guidelines suggest the use of beta-blockers and non-dihydropyridine calcium-channel antagonists as first-line agents. Giving a combination with digoxin can be done under conditions of heart failure or left ventricular dysfunction.^[2]

In this case we use digoxin and beta-blockers (bisoprolol) as drugs for controlling heart rate. Calcium channel blockers are not used considering that this patient has hypotension (100/60), where if used, the patient's hemodynamics worsens. Also found are signs of decreased left ventricular function in patients.

We used amiodarone after the patient turned out to be intolerant to the use of digoxin and administration of beta-blockers did not provide adequate control of the heart rate.

Detection of hyperthyroidism in patients with atrial fibrillation and its management

Hyperthyroidism is a condition in which thyroid hormone levels increase in the body. It is characterized biochemically by decreased levels of TSH (Thyroid Stimulating Hormone) and increasing levels of T3, T4 or levels of both in the blood [9]. Thyroid hormones are closely related to the cardiovascular system. Increased thyroid levels can cause cardiovascular changes, including increased cardiac output and can reduce peripheral resistance through vasodilation resulting in hyperdynamic conditions.[10]

AF is the most common cardiac complication of hyperthyroidism. AF in hyperthyroidism occurs in about 5-20%, compared with the normal population (about 2%) [10-13]. The pathophysiology of AF in hyperthyroidism can be explained by several mechanisms, including (1) an increase in left atrial pressure caused by an increase in left ventricular mass and disruption of ventricular relaxation, (2) ischemia resulting from increased heart rate at rest and (3) increase in atrial ectopic activity. Hyperthyroidism is also associated with shortening of action potential duration which is a substrate of AF.[12,14]

Because hyperthyroidism is quite common in AF patients, this situation has implications for the clinical evaluation. Examination of thyroid hormone function status is an important evaluation and recommended in first detected AF case. It is also recommended in patients with difficult-to-control AF or in AF who are recurred after cardioversion [1,15]. The cause of difficulty in AF rate control with hyperthyroidism is related to the pathophysiology of AF and also the influence of thyroid hormones on treatment. Hyperthyroidism causes an increase in the digitalis clearance rate, as well as a decrease in digitalis sensitivity caused by an increase in the

amount of Na-K-ATPase under hyperthyroid conditions. In addition, hyperthyroidism also caused a decrease in parasympathetic tone so that rate control is difficult.[10,16]

In this case, evaluation of thyroid function was carried out after difficulties were found in controlling AF ventricular rate after administration of medication to control heart rate (digoxin and bisoprolol) in accordance with the guidelines. Although the ventricular response was normal, the ventricular rate returned to uncontrolled despite regular bisoprolol therapy. Evaluation of thyroid function revealed a decrease in TSH (0.06 uIU/mL), an increase in T4 (3.97 ng/dl) and normal T3, which indicated hyperthyroidism.

The difficulty of rate control in this case is related to the effect of hyperthyroidism on digitalis, which is used as a rate control agent. Hyperthyroidism causes tolerance and decreased digoxin sensitivity. There are several factors that contribute to the emergence of AF, namely the presence of mitral-valve prolapse which experiences mitral valve regurgitation which causes dilatation of the left atrium, which eventually becomes the substrate of AF and also the presence of hyperthyroidism, which causes difficulty in controlling the rate of AF.

Hyperthyroidism also has implications for the management of patients with AF. The management of AF in hyperthyroidism focuses on achieving an euthyroid state and controlling the ventricular rate using beta-blockers. Euthyroid state can be achieved by administering anti-thyroid drugs such as PTU, methimazole, lugol solution or with radioiodine drugs. In 2/3 of patients, euthyroid conditions are achieved after 2-3 months of therapy. In the case of AF with rapid ventricular response, administration of beta-blockers can help to control the heart's ventricular rate. Preparations that can be used include bisoprolol, metoprolol and

propranolol [10,11]. Propranolol has the advantage of controlling heart rate in AF with hyperthyroidism, because it has an effect in preventing the conversion of T4 to T3. Propranolol also has anti-thyroid activity through inhibition of iodide transport in the thyroid follicles.[17,18]

In patients who previously used amiodarone in controlling ventricular rate, it is recommended to stop using amiodarone, because amiodarone contains iodine which if used can trigger amiodarone-induced thyrotoxicosis which leads to a thyroid crisis, a life-threatening condition [1]. In this case, the management of the rate of AF with hyperthyroidism was carried out by administering anti-thyroid methimazole to achieve an euthyroid state. In addition, control of the ventricular rate using beta-blockers (propranolol) is carried out. The euthyroid state was achieved after 2 months of therapy with TSH results, normal FT4. The ventricular rate is also controlled with a ventricular response of 80 bpm. After being diagnosed with the condition of hyperthyroidism, the administration of amiodarone was immediately stopped, to prevent the occurrence of amiodarone-induced thyrotoxicosis.

Digitalis intoxication

Digitalis intoxication is one of the most frequent drug adverse reactions in clinical practice [19,20], although the use of digitalis has declined since 1990 [21]. This is related to the narrow therapeutic range of digitalis (0.8-2.0 ng/mL) [19]. According to the clinical setting, digitalis intoxication is differentiated into acute and chronic intoxication, where conditions in these two conditions are very different. Acute intoxication occurs due to overdosing, which usually occurs in younger individuals, with sudden and severe symptoms. While chronic intoxication is caused by accumulation of digoxin

levels due to the use of long-time digitalis, appearance of symptoms was slow.

Diagnosis of digitalis intoxication is something that is not easy, this is caused by several factors, namely non-specific symptoms and signs, non-specific electrocardiographic findings, and digoxin concentrations in the blood also do not always correlate with the level of toxicity.[19,21,22]

Signs and symptoms of digitalis intoxication can manifest in cardiac or extracardiac [19,23,24]. The most common extracardiac manifestations are gastrointestinal symptoms, such as nausea, vomiting, diarrhea and abdominal pain. These gastrointestinal symptoms occur in 30-80% of cases of digitalis intoxication. Gastrointestinal symptoms are symptoms that are often found in cases of acute intoxication, and arise at the beginning of intoxication. These symptoms can be caused by intravenous or oral digitalis preparations. The next symptom is neurological manifestations and visual disturbances, which can arise in acute or chronic intoxication. Symptoms and signs include malaise, headache, fatigue, depression, hallucinations, blurred vision, and changes in the pattern of vision to color.

Cardiac manifestations are a life-threatening complication of digitalis intoxication. Cardiac abnormalities that occur are mainly related to arrhythmias. Arrhythmias can occur even if the patient does not complain of symptoms. The mechanism of arrhythmias in digitalis intoxication is caused by atrioventricular conduction barriers and increased impulsivity.[22]

ECG images caused by the mechanism of increasing impulse formation are generally in the form of frequent PVC's, both unifocal and multifocal, where the ECG image is an arrhythmia that appears the earliest and most often digitalis

intoxication, which is as much as 50%. ECG images caused by the mechanism of the conduction system include 1st degree to total AV blocks. Normalization of the ventricular response in AF can also be categorized as one of the characteristics of digitalis intoxication.^[22]

Tachyarrhythmias or bradyarrhythmias can occur. Tachyarrhythmias coincide with blockade of the sinus and AV nodes, including atrial tachycardia / junctional tachycardia with AV block. In more severe cases, VT / VF can occur. ECG depictions on digitalis intoxication must be distinguished from ECG images due to digitalis therapy. Some changes in ECG image can occur in patients with digitalis therapy without intoxication. These features include T-wave changes, interval-QT shortening, sagging / scooped ST segment accompanied by ST-segment depression and prolonged PR interval.^[22]

In addition to the above manifestations, there are changes in laboratory parameters that must be watched out for digitalis intoxication. These parameters are serum electrolytes, kidney function, glucose and also digoxin concentrations in serum. In acute intoxication hyperkalemia can occur (K level > 5.1) which can be caused by excessive blocking of the Na-K-ATPase pump. Hyperkalemia is a prognosis factor that can predict outcomes in patients. Acute intoxication also causes a decrease in kidney function.^[25,26]

Measuring the concentration of digoxin in the blood can be done to support the symptoms and signs of digitalis intoxication. Measurement of digoxin concentration is more appropriate to do at least 6 hours after the last digoxin administration. This is related to the time needed for the drug to be distributed evenly throughout the body. If sampling is done before 6 hours, the results obtained will be false positives, where digoxin concentrations

increase but not according to clinical conditions. From several sources, it was stated that the concentration of digoxin in the blood does not always correlate with the patient's clinical severity^[27]. Therefore, the diagnosis of digitalis intoxication should be based on a clinical diagnosis, taking into account the symptoms, signs, changes in ECG and also the laboratory. Measuring the level of digoxin in the blood cannot be used as a single parameter in the diagnosis of digitalis intoxication.

In this case, we confirmed the diagnosis of digitalis intoxication with a clinical diagnosis approach, which was obtained by patients who complained of severe vomiting after administration of intravenous digoxin as much as 1.5 mg. Complaints of nausea and vomiting accompanied by a limp body and blurred eyes. From the ECG picture, AF with a moderate ventricular response of 100 bpm was obtained, where the ventricular rate improved from the previous one (AF rapid ventricular response 170 bpm), showing the effect of conduction inhibition from digoxin. In the laboratory results, hyperkalemia and an increase creatinine and ureum were obtained. There was no examination of digoxin levels in the blood, due to limited facilities at RSDS. The patient also refused to go to a laboratory outside the hospital.

Management of digitalis intoxication consists of several stages, namely (1) assessing the severity of intoxication, (2) evaluating causes of intoxication, (3) airway, breathing and circulation resuscitation, (4) discontinuation of digitalis administration, and (5) administration of digitalis antidotes (as indicated).

Determination of the severity of intoxication is important to determine the appropriate management. In patients with mild intoxication, with symptoms of nausea and vomiting without other serious problems, discontinuation of digitalis is a specific procedure that needs to be done. If there

are more serious problems, such as the involvement of cardiac problems, electrolyte disorders and then faster and more aggressive management is needed.^[23]

Factors that cause intoxication must also be evaluated. Various factors can trigger intoxication. In acute intoxication, the factor that usually plays a role is overdose. Even at therapeutic doses can trigger intoxication due to the narrow range of doses. In chronic intoxication the factors that play a role are hypokalemia, impaired renal function, changes in distribution volume, the presence of heart failure conditions.

In this case we found that patients with acute digitalis intoxication with a mild degree, because only gastrointestinal complaints were obtained without hemodynamic disorders. There is an increase in potassium levels but is still in a mild stage and does not require special management. The precipitating factor of digitalis intoxication is related to the dose of digoxin.

In this patient, maximum therapeutic dose of digoxin is received in 1 day, which is 1.5 mg. Acute digitalis intoxication can occur in therapeutic doses because of the narrow therapeutic range. The condition of hyperthyroidism causes a decrease in myocyte sensitivity to digoxin thereby increasing the dose requirement of digoxin.

Resuscitation is needed for patients who experience severe airway, breathing and circulation. Administration of antidotum digoxin-specific antibody fragments can be considered in cases of severe intoxication. Although the use of antidotum is safe and effective, there has not been a randomized study that supports its routine use. Indications for this antidotum include the presence of life-threatening arrhythmias, cardiac arrest, hemodynamic disorders, potassium levels of more

than 5.5 mmol/L, acute ingestion of digoxin and digoxin level > 10-15 ng/ml.

In this case the treatment of acute digitalis intoxication is with digoxin discontinuation, rehydration, symptomatic drug administration and observation. No resuscitation is needed because there are no disturbances to airway, breathing and circulation. Digoxin antidotum was not needed because acute intoxication in these patients is classified as mild.

Hyperthyroidism and mitral valve prolapse

In this case it was found to be quite interesting, the discovery of more than one factor causing AF: mitral-valve prolapse and hyperthyroidism. Patients with mitral valve prolapse and hyperthyroidism have almost the same symptoms, palpitations. In a 1981 study by Channick et al., there was a high incidence of mitral-valve prolapse in patients with hyperthyroidism, which was 43% compared with 18% of controls.

There are various hypotheses regarding the high incidence of mitral-valve prolapse in hyperthyroidism, namely genetic involvement, autoimmune and also the effects of thyroid hormones that cause cardiac structural abnormalities ^[28,29]. However, in a 2015 study, found conflicting results, that there was no association between mitral-valve prolapse and autoimmune thyroid disease. In contrast, these two opinions certainly require further research to determine the relationship between mitral-valve prolapse and hyperthyroidism.^[30]

Conclusion

We have reported one case of a patient with difficult AF rate-control and also experiencing acute digitalis intoxication. Patients have several factors triggering AF, namely mitral-valve prolapse with moderate mitral regurgitation (causing dilatation of the left atrium as a substrate of AF) and hyperthyroidism. Rate-control cannot be done with standard digoxin and beta blockers therapy. It was obtained after administration of anti-thyroid drugs and propranolol for two months.

Hyperthyroidism plays a central role in the problem of these patients. Hyperthyroidism causes difficulty in controlling the rate of AF through a mechanism for increasing atrial ectopic activity, shortening the duration of potential action and increasing left atrial pressure. Hyperthyroidism also plays a role in the occurrence of digitalis intoxication by causing tolerance and decreasing the sensitivity of myocytes to digoxin. Thyroid function therefore must be evaluated in patients with AF suffering difficult rate-control as well as first-detected AF.

Acknowledgement

There is no conflict of interest in this research. The author would like to thank all of the people who took part in the publication of this article.

References

1. Yuniadi Y, Tondas AE, Hanafy DA, Hermanto DY, Maharani E, Munawar M, et al. Pedoman Tata Laksana Fibrilasi Atrium Perhimpunan Dokter Spesialis Kardiovaskular Indonesia. 2014;54–5.
2. Kirchhof P, Benussi S, Kotecha D, Ahlsson A, Atar D, Casadei B, et al. ESC Guidelines for The Management of Atrial Fibrillation Developed in Collaboration with EACTS. *Europace*. 2016;18(11):1609–78.
3. Kuznar W. New Drug Therapies for Difficult-to-Control Atrial Fibrillation [Internet]. *Value-Based Care in Cardiometabolic Health*, Vol 1, No 1. 2012 [cited 2017 Jun 17]. Available from: <http://www.ahdbonline.com/issues/value-based-care-cardiometabolic-health/may-2012-vol-1-no-1/1015-article-1015>
4. January CT, Wann LS, Alpert JS, Calkins H, Cigarroa JE, Cleveland JC, et al. AHA/ACC/HRS guideline for the management of patients with atrial fibrillation: A report of the American College of cardiology/American heart association task force on practice guidelines and the heart rhythm society. *Circulation*; 2014. 130: 199–267 p.
5. The Atrial Fibrillation Follow-Up Investigation of Rhythm Management (AFFIRM) Investigators. A Comparison of Rate Control and Rhythm Control in Patients with Atrial Fibrillation. *N Engl J Med*. 2002;347(23):1825–33.
6. Heist EK, Mansour M, Ruskin JN. Rate control in Atrial Fibrillation: Targets, Methods, Resynchronization Considerations. *Circulation*. 2011;124(24):2746–55.
7. Van Gelder IC, Rienstra M, Crijns HJGM, Olshansky B. Rate Control in Atrial Fibrillation. *Lancet* [Internet]. 2016;388(10046):818–28. Available from: [http://dx.doi.org/10.1016/S0140-6736\(16\)31258-2](http://dx.doi.org/10.1016/S0140-6736(16)31258-2)
8. Medscape. Lanoxin (digoxin) Dosing, Indications, Interactions, Adverse Effects, and More [Internet]. *Medscape.com*. 2015 [cited 2017 Jul 27]. Available from: <http://reference.medscape.com/drug/lanoxin-digoxin-342432>
9. Grais IM, Sowers JR. Thyroid and the Heart. *Am J Med* [Internet]; 2014 Aug.127(8):691–8. Available from: <http://linkinghub.elsevier.com/retrieve/pii/S0002934314002368>

10. Klein I. Endocrine Disorders and Cardiovascular Disease. In: Mann DL, Zipes DL, Libby P, Bonow RO, editors. *A Textbook of Cardiovascular Medicine*. 10th ed. Elsevier-Saunders; 2015. p. 1798–805.
11. Shimizu T, Koide S, Noh JY, Sugino K, Ito K, Nakazawa H. Hyperthyroidism and The Management of Atrial Fibrillation. *Thyroid* [Internet]; 2002.12(6):489–93. Available from: <http://www.ncbi.nlm.nih.gov/pubmed/12165111>
12. Fadel BM, Ellahham S, Ringel MD, Lindsay J, Wartofsky L, Burman KD. Hyperthyroid Heart Disease. *Clin Cardiol*; 2000. 23:402–8.
13. Jayaprasad N, Johnson F. Atrial fibrillation and hyperthyroidism. *Indian Pacing Electrophysiol J*; 2005. 5(4):305–11.
14. Bielecka-Dabrowa A, Mikhailidis DP, Rysz J, Banach M. The mechanisms of atrial fibrillation in hyperthyroidism. *Thyroid Res* [Internet]; 2009. 2(1):4. Available from: <http://thyroidresearchjournal.biomedcentral.com/articles/10.1186/1756-6614-2-4>
15. Issa ZF, Miller JM, Zipes DP. Atrial Fibrillation. In: *Clinical Arrhythmology and Electrophysiology: A Companion to Braunwald's Heart Disease*. 1st ed. Saunders - Elsevier; 2009. p. 208–86.
16. Kim D, Smith TW. Effects of thyroid hormone on Sodium Pump Sites, Sodium Content, and Contractile Responses to Cardiac glycosides in Cultured Chick Ventricular Cells. *J Clin Invest*; 1984. 74(4):1481–8.
17. Busti AJ. Why Propranolol is Preferred to Other Beta-blockers in Thyrotoxicosis or Thyroid Storm? *Evidence-Based Medicine Consult*. 2015.
18. Murakami S, Nasu M, Fukayama H, Krishnan L, Sugawara M. Propranolol has Direct Antithyroid Activity: Inhibition of Iodide Transport in Cultured Thyroid Follicles. *Cell Biochem Funct*; 1993.11(3):159–65.
19. Bayer MJ. Recognition and Management of Digitalis Intoxication: Implications for Emergency Medicine. *Am J Emerg Med*; 1991. 9(2 SUPPL. 1):29–32.
20. Panampalam. Digoxin toxicity: Case report. *BMJ Best Pract* [Internet]; 2014. (2):9954. Available from: <http://bestpractice.bmj.com/best-practice/monograph/338.html>
21. Pincus M. Management of Digoxin Toxicity. *Aust Prescr*; 2016. 39(1):18–20.
22. Ma G, William JB, Pollack M, Chan TC. Electrocardiographic Manifestations: Digitalis Toxicity. *J Emerg Med*; 2001. 20(2):145–52.
23. Lip GY, Metcalfe MJ, Dunn FG. Diagnosis and Treatment of Digoxin Toxicity. *Postgrad Med J* [Internet]; 1993. 69(811):337–9. Available from: <http://pmj.bmj.com/cgi/doi/10.1136/pgmj.69.811.337>
24. Gómez AL. Digitalis intoxication. *Am Heart J*; 1972. 84(2): 285.
25. Williams RH, Erickson T. Evaluating Digoxin and Theophylline Intoxication in the Emergency Setting. *Lab Med*; 1998. 29(March):158–61.
26. Bismuth C, Gaultier M, Conso F, Efthymiou ML. Hyperkalemia in Acute Digitalis Poisoning: Prognostic Significance and Therapeutic Implications. *Clin Toxicol* [Internet]; 1973. 6(2):153–62. Available from: <http://www.ncbi.nlm.nih.gov/pubmed/4715199>
27. Williamson KM, Thrasher KA, Fulton KB, Lapointe NMA, Dunham GD, Cooper AA, et al. Digoxin Toxicity: An Evaluation in Current Clinical Practice. *Arch Intern Med*; 1998. 158:2444–9.
28. Channick BJ, Adlin EV, Marks AD, Denenberg BS, McDonough MT, Chakko CS, et al. Hyperthyroidism and Mitral-valve Prolapse. *N Engl J Med*; 1988. 319(26).

29. Brauman A, Algom M, Gilboa Y, Ramot Y, Golik A, Stryjer D. Mitral valve prolapse in hyperthyroidism of two different origins. *Br Heart J* [Internet].;1985. 53(4):374–7. Available from:
<http://www.pubmedcentral.nih.gov/articlerender.fcgi?artid=481774&tool=pmcentrez&rendertype=abstract>
30. Baştuğ S, Sarı C, Aslan AN, Bayram NA, Ayhan H, Kasapkara HA, et al. Evaluation of Autoimmune Thyroid Disease in Patients with Mitral Valve Prolapse. *Erciyes Med J*; 2015. 37(3): 98–101.