



Case Report

Cardiac Pacemaker in Pregnancy: How to Manage?Dian P. Kartikasari^{1*} and Rerdin Julario¹¹Department of Cardiology and Vascular Medicine, Faculty of Medicine, Universitas Airlangga, Surabaya, Indonesia.

ARTICLE INFO

*Article history:**Submitted**Reviewed February 2021**Accepted March 2021*

Available online March 2021

Corresponding author:dr.dianparamita@yahoo.com**Keywords:*Bradycardia
Pacemaker
Pregnancy
Sinus arrest

ABSTRACT

Despite the increasing use of permanent cardiac pacemakers in a younger patient population, there are little data related to pregnancy. Normal physiologic alterations of pregnancy need to be taken into account in the management of the pregnant woman with a pacemaker in place. Similarly, gestational events including the potential for surgical intervention require a basic knowledge of pacemaker technology and monitoring. We present a case of a patient with junctional escape rhythm and was implanted pacemaker during pregnancy. A 24 years old woman referred from obstetric outpatient clinic with asymptomatic bradycardia and cryptogenic stroke 2 years earlier. ECG shows sinus arrest with junctional escape rhythm. After multi-disciplinary discussion, team decided to implant double chamber pacemaker implantation. The pacemaker setting is adjusted to prepare caesarean section at 39 weeks gestation with delivery of an aterm infant. The postoperative course was uneventful. Pre-pregnancy pacemaker settings were re-established after the postpartum period. The current literature on managing pregnant patients with pacemakers is quite limited. Such patients require a multidisciplinary approach to care. Electromagnetic Interference (EMI) should be noticed.

Introduction

Along with the improvements in diagnostics and therapy of cardiovascular field, the use of permanently implanted cardiac device is remarkably rising in younger population, including reproductive ages. Normal physiologic alterations of pregnancy need to be addressed in the management of the pregnant woman with pacemaker while there is still limited data available related to pregnancy. Optimal care can be obtained with multidisciplinary discussion of cardiologist, obstetrician and anesthesiologist since early pregnancy so the team can prepare the safe delivery and minimize the possible complications. Similarly, gestational events including the potential for surgical intervention

require a basic knowledge of pacemaker technology and monitoring.

Case Presentation

A 24-year-old woman referred from obstetrics outpatient with asymptomatic bradycardia. No history of syncope, nausea, chest pain, dyspnea. There is no history of hypertension, diabetes and congenital heart disease but she had history of cryptogenic stroke 3 years ago (2017) and history of atrial fibrillation (2017). Previous ECG showed sinus arrest, had been advised to do TEE and pacemaker implantation but patient refused. There is no history of miscarriage. Physical examination is

unremarkable except bradycardia 45x/mins ECG that shows sinus arrest with junctional escape

rhythm 45x/minutes with normal axis and chest x-ray in shown in Figure 1.

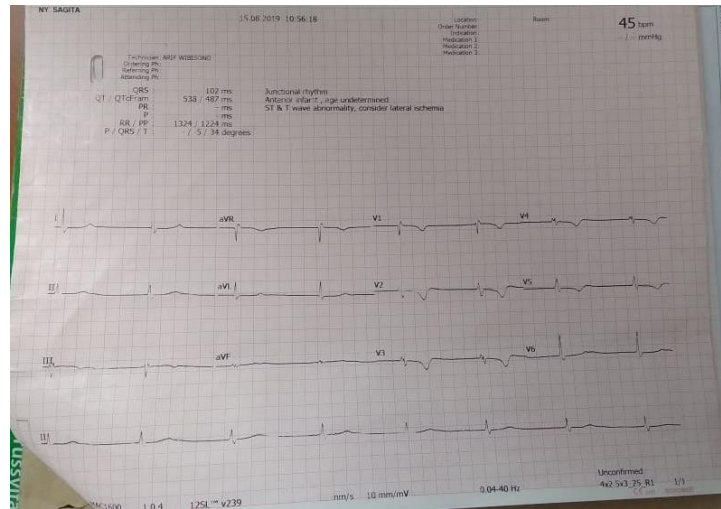


Figure 1. ECG

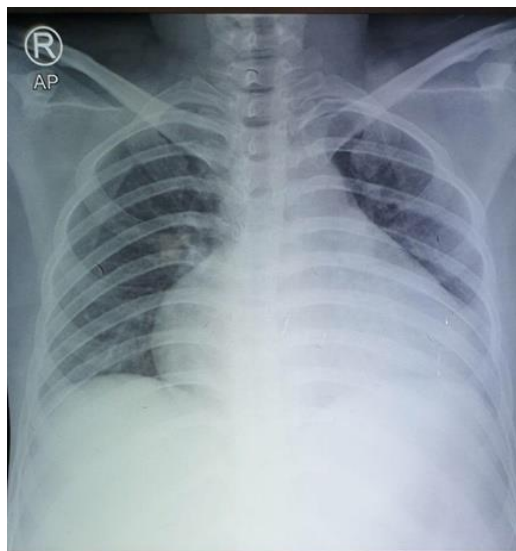

Figure 2. Chest X-Ray

Transthoracic echocardiography (TEE) shows dilated right atrium right and ventricles with trivial tricuspid regurgitation (no pulmonary hypertension) and pulmonic regurgitation. The systolic LV and kinetics are normal. Since there is dilatation on the right heart and history of cryptogenic stroke, the patient was sent to Transesophageal Echocardiogram (TEE) to evaluate whether there was congenital or structural heart disease like atrial septal defect, foramen ovale and also thrombus

evaluation. In TEE there is a suspicion of thrombus in the *left atrial appendage* (LAA) (Figure 2 and Figure 3).

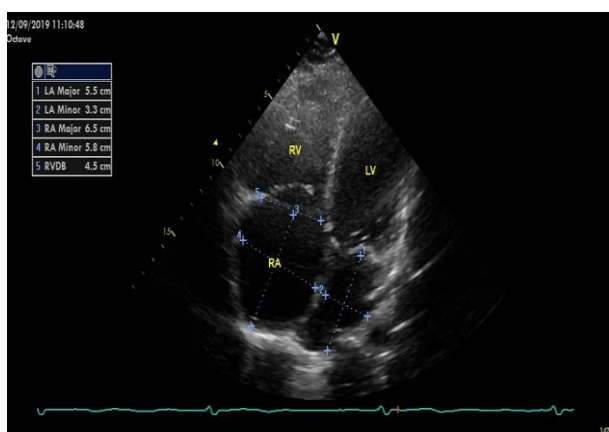


Figure 3. Right Atrial and Ventricle dilatation TTE

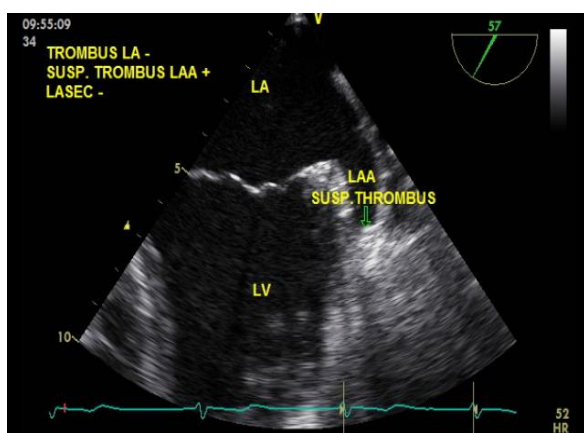


Figure 4. LAA Thrombus (TEE)

Holter examination shows junctional rhythm with episodes of couplet PVC and chronotropic incompetence. A permanent pacemaker is implanted at 33/34 weeks of pregnancy using apron on the abdomen on implantation procedure (Figure 4).

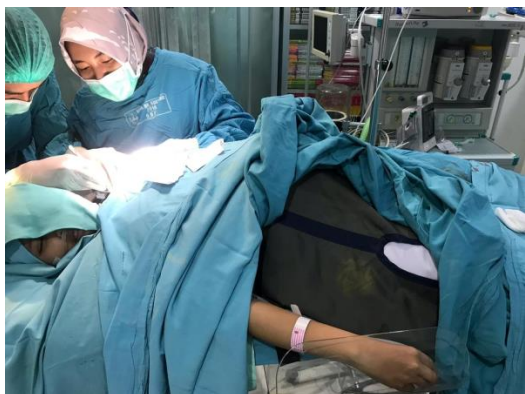

Figure 4. Pacemaker implantation using apron on abdomen

Pacemaker mode is DDDR (pacemaker lead are located in atrium and ventricle with both sensing and pacing mode also rate modulation) without any complication during and post implantation. Patient is scheduled to give birth with c-section with pacemaker mode adjustment into DOO. The delivery process went smoothly without any complication to both mother and baby.

Discussion

Pregnancy correlates with various physiology changes in cardiovascular system. Some changes will need to be followed up with pacemaker implantation while some adjustment will be needed for those who already using pacemaker. In pregnancy, blood volume will physiologically increase 50%. (1-3) Cardiac output is increased approximately 30% in the early pregnancy and remain stable during pregnancy. An increase in cardiac output is initially caused by an increase in stroke volume but at the end of the pregnancy, the increase is caused more by increased heart rate. Decreased cardiac output usually found at the end of gestation because decreased venous return caused by inferior vena cava compression by uterus and left lateral position will minimize this condition. A decrease in vascular resistance often encountered at last trimester, causing low blood pressure both systole and diastole in second trimester, which then will return to normal after delivery. The older age of pregnancy, the more the uterus will urge the diaphragm to proximal so it will cause cardiac deviate to the left and ECG could show frontal axis deviation to the left. Other ECG changes that can be found is new arrhythmia, sinus tachycardia followed by the shortened PR interval and QT interval, small Q waves and inverted P waves in leads III

(affected by inspiration), an increase in R / S ratio in lead V1.^[1]

There are various types of pacemaker, in general pacemaker comprises of generator and leads. Permanent pacemaker lead can be implanted transvenous through cephalic, axillary or subclavian vein. Pacemaker can be externally programmed externally by pacing utility. *The North American Society of Pacing and electrophysiology (NASPE)* and the *British Pacing and*

electrophysiology Group (BPEG) has compiled the nomenclature called NBG code (NASPE / BPEG Generic) to identify the type pacemaker. This code consists of 5 letters: ^[4]

- Letter I: Chambers paced
- Letter II: Chamber sensed
- Letter III: Response to sensing
- Letter IV: Rate modulation
- Letter V: Multisite Pacing

Table 1. NBG Code in Pacemaker

Position I	Position II	Position III	Position IV	Position V
Chamber(s)Paced	Chamber(s)Sensed	Response to Sensing	Rate Modulation	Multisite Pacing
O = None	O = None	O = None	O = None	O = None
A = Atrium	A = Atrium	T = Triggered	R = Rate Modulation	A = Atrium
V = ventricle	V = ventricle	I = Inhibited		V = ventricle
D = Dual (A+V)	D = Dual (A+V)	D = Dual (T+I)		D = Dual (A+V)

In this case, patient is using DDDR mode, indicates that either the atrium or ventricle is paced and sensed when needed and have rate-responsive mode, which is beneficial in this case because patient had chronotropic incompetence.

Pacemaker implantation during pregnancy is not specifically mentioned in the guideline. Guideline only mention that pacemaker is indicated in symptomatic bradycardia or total AV block. Pacemaker implantation during pregnancy has lower risk if implanted after 8 weeks of pregnancy and can be assisted by echocardiography ^[5]. Other literature mentioned that pacemaker implantation in pregnant women with hemodynamically stable junctional escape rhythm may be postponed until after childbirth, In patients with total block and wide

junctional escape rhythm, pacemaker implantation is recommended ^[6]. The Valsalva maneuver during labor can be associated with a vasovagal reaction, resulting in slowing of the heart rate and potentially syncope. Thus, some centers advocate prophylactic temporary transvenous pacing for labor and delivery in asymptomatic women. After multidiscipline discussion and also discussion with the patient, it is decided to implant permanent pacemaker before the labor. ^[2]

Pre-conception Counseling is essential for women with implanted cardiac devices who is planning pregnancy to discuss the increased risks of fetal cardiac anomalies in mothers with congenital heart disease (CHD). Fetal cardiac anomalies might be different with the mother, but it can be a part of the mother's cardiac malformity syndrome. Pre-

conception counseling includes counseling about the risk during pregnancy and delivery, medication allowed during gestation and encouraging genetic test if possible [2]. In this case, the patient had history of stroke at very young age with unknown cause, she is suspected to have congenital heart disease like atrial septal defect or patent foramen ovale. At that time, patient had already scheduled for transesophageal echocardiography but the patient was loss to follow up and decided to come at the clinic when she is already pregnant. TEE then obtained during pregnancy and showed suspicion of a thrombus at LAA so that patients got oral anticoagulant.

Generally, patients with implanted cardiac device will tolerate pregnancy well. Thaman et al. reported a study on 11 women pregnant with pacemaker, with three of them had structural heart disease and experiencing maternal complications. First patient had heart failure at 38 weeks of gestational age, second patient had palpitation with episode of atrial fibrillation, these two patients have abrupt delivery. Third patient had right ventricular failure and the fetus died at 20 weeks of gestational age [7]. According to the worse outcome shown this study, surveillance should be done for pregnant woman with cardiac pacemaker and structural heart disease, but to date the data available is still very limited so the guideline has not been proposed yet. Pregnant women with cardiac pacemaker must regularly visit clinic to have their ECG recorded and their pacemaker interrogated as an evaluation of how dependent she is to pacemaker. [2,3]

Pre-operative management in pregnant patient with pacemaker is essential. Ideally, a consultation with anesthesiologist is done within the early pregnancy, mainly to discuss the delivery method and what anesthesia options available with consideration of mother's condition and comorbidities. On the first phase of labor, cardiac output increases

approximately 12% from baseline and continues to rise along with the labor. When cervical dilatation is maximal, cardiac output increases by 34%. Epidural anesthesia can overcome these changes in cardiac output. [8]

For delivery method in this patient both, delivery method selection both by vaginal and caesarean section have been mentioned in several case reports. Generally, labor patient with cardiac pacemaker have low risk and is not a contraindication for vaginal birth. Choosing the appropriate method is based more on obstetric indications or other comorbidities than the pacemaker itself. Labor with lateral decubitus position can overcome the hemodynamic fluctuations. [8,9]

In patients who underwent c-section, the anesthesiologist must be aware with the pacemaker mode, implantation time of pacemaker and the remaining battery life, the physician also should be aware of the signs when cardiac output starting to decrease and ECG changes that indicate pacemaker dysfunction, also electrolyte disturbance mainly by potassium that may alter the pacemaker threshold.

In choosing anesthesia regimen for surgery, it should be considered to avoid maternal hypotension since hypotension can reduce uteroplacental flow. For this reason, epidural anesthesia is chosen over spinal. This is important in patients on pacemaker which is notable to have tachycardia response over hypotension related to anesthesia regimen. Baron et al found no difference in maternal heart rate in before and after epidural anesthesia. [8-10]

During c-section procedure, bipolar electrocautery can be used only in short period of time to avoid interference with Electromagnetic

Interference (EMI) that can affect the pacemaker output and reset the pacemaker. Resetting pacemaker into asynchronous mode can minimize Electromagnetic Interference (EMI) and this mode is usually preferred for pacemaker-dependent patient. The grounding plate for cautery system should be placed in the nearest to operation site but furthest from pacemaker.^[8,9]

Conclusion

The current literature on managing pregnant patients with pacemakers is quite limited. Such patients require a multidisciplinary approach to care. Normal physiologic changes in pregnancy may necessitate rate adjustments. Route of delivery is generally based on obstetric indications. During surgery consider using bipolar electro cautery in place of unipolar electro cautery, to reduce electromagnetic interference. Also, the placement of the grounding pad should be as far away from the pacemaker as possible. It should be anticipated that the patient will return to her baseline cardiac status postpartum and therefore pacemaker settings can be adjusted accordingly.

Acknowledgement

There is no conflict of interest in this research. The author would like to thank all of the people who took part in the publication of this article.

References

1. Soma-Pillay P, Nelson-Piercy C, Tolppanen H, Mebazaa A. Physiological changes in pregnancy. *Cardiovasc J Afr*. 2016;27(2):89–94.
2. Grover S, Sheth P, Haines DE, Khan M, Gonik B. Management of Cardiac Pacemakers in a Pregnant Patient. *Open J Obstet Gynecol*. 2015;05(01):60–9.
3. Harris AL, Yap S, Silversides C. Maternal conduction disorders and bradycardia during

pregnancy.pdf. 2019;1–12.

4. Hidaka N, Chiba Y, Fukushima K, Wake N. Pregnant women with complete atrioventricular block: Perinatal risks and review of management. *PACE - Pacing Clin Electrophysiol*. 2011;34(9):1161–76.
5. Regitz-Zagrosek V, Blomstrom Lundqvist C, Borghi C, Cifkova R, Ferreira R, Foidart JM, et al. ESC Guidelines on the management of cardiovascular diseases during pregnancy. *Eur Heart J*. 2011;32(24):3147–97.
6. Brignole M, Auricchio A, Baron-Esquivias G, Bordachar P, Boriani G, Breithardt OA, et al. 213 ESC Guidelines on cardiac pacing and cardiac resynchronization therapy. *Eur Heart J*. 2013;34(29):2281–329.
7. Thaman R, Curtis S, Faganello G, Szantho G V., Turner MS, Trinder J, et al. Cardiac outcome of pregnancy in women with a pacemaker and women with untreated atrioventricular conduction block. *Europace*. 2011;13(6):859–63.
8. Bouslama MA, Ferhi F, Hacheni F, Ons K, Abdeljelil K, Jazia K Ben, et al. Pregnancy and delivery in woman with implantable cardioverter-defibrillator: What we should know. *Pan Afr Med J*. 2018;30:1–5.
9. Salman MM, Kemp HI, Cauldwell MR, Dob DP, Sutton R. Anaesthetic management of pregnant patients with cardiac implantable electronic devices: case reports and review. *Int J Obstet Anesth [Internet]*. 2018;33:57–66. Available from: <http://dx.doi.org/10.1016/j.ijoa.2017.07.011>
10. Bernstein DA, Daubert J _Claude, Fletcher RD, Hayes DL, Luderitz B, Reynolds DW, et al. BERNSTEIN_et_al-2002- Pacing_and_Clinical_Electrophysiology. *J pacing Clin Electrophysiol*. 2002;25(2).