




Case Report

Successful Typical AVNRT Ablation

Angela Bety Ratnasari^{1*}, Budi Baktijasa¹ ¹Cardiology and Vascular Medicine Department, Universitas Airlangga, Surabaya.

ARTICLE INFO

Article history:

Submitted 06 March 2021

Reviewed 31 October - 24 May 2021

Revised 07 July - 21 September 2021

Accepted

Available online 30 September 2022

**Corresponding author:*

angelabety88@gmail.com

Keywords:

Atrioventricular nodal reentrant tachycardia

Catheter ablation

Electrophysiology

Slow/fast avnrt

Supraventricular tachycardia

ABSTRACT

AVNRT is the most common regular arrhythmia in humans, and therefore the most commonly encountered during ablation attempts for regular tachycardias. **Case Summary:** We present a 41-year-old female patient with chest palpitations in the last 10 years, but prior to hospitalization felt heavy sensation on her chest and hospitalized due to heavy chest palpitations and documented SVT. She had no history of hypertension, diabetes mellitus, coronary heart conditions, or stroke. Physical examination showed fair general condition with GCS E4V5M6, blood pressure 130/80, pulse rate 96x / minute, breath rate 18 x / minute and saturation of 99%. Physical examinations are within normal limits. **Discussion:** Catheter ablation for AVNRT is the current treatment of choice in symptomatic patients. It reduces arrhythmia-related hospitalizations and costs, and substantially improves quality of life. Catheter ablation approaches aimed at the fast pathway have been abandoned; slow pathway ablation, using a combined anatomical and mapping approach, is now the method of choice. This approach offers a success rate of 95 %, has a recurrence rate of approximately 1.3 – 4.0 %, and has been associated with a low risk of atrioventricular (AV) block.

Introduction

Supraventricular Tachycardia (SVT) is a tachycardia (atrial rate of 100 beats per minute) by the mechanism of involving tissue from His-bundle and above [1]. Epidemiological studies in the SVT population are limited. In the general population, the prevalence of SVT is 2.25 / 1000 person, and the incidence is 35/100.000 person-years. Women have twice the risk of developing an SVT than men, and people who are >65 years of age have more

than five times the risk of developing an SVT than younger individuals.[1]

Atrioventricular nodal re-entrant tachycardia (AVNRT) is the most common supraventricular tachycardia seen in daily practice. AVNRT is a paroxysmal type of SVT that results from a re-entry circuit within or adjacent to the AV node.[1,2]

Cardiac electrophysiology studies have evolved over the past 30 years. In 1969, started by His-bundle first tape, to diagnose and treat arrhythmias

in early 1970s. continued by electrical mapping and arrhythmia surgical ablation during late 1970s. Developed into radiofrequency catheter ablation (RFCA) for supraventricular tachycardia and idiopathic tachycardia in 1980-1990s. In general, Catheter ablation is the current preferred treatment of choice. This intervention provides 97% high success rate with 1.3-4% recurrence rate with a 1% developing AV block risk.^[3,4]

Case Presentation

A 41-year-old female presented in the cardiology department of Dr. Soetomo General Hospital, referred from Soewandi Hospital. The patient suffered chest palpitations in the last 10 years, but prior to hospitalization felt heavy sensation on her chest and hospitalized due to heavy chest palpitations and documented SVT. Patient had no history of hypertension, diabetes mellitus, coronary heart conditions, and stroke. Physical examination showed fair general condition with GCS E4V5M6, blood pressure 130/80, pulse rate 96 beats per minute, breathing rate 18 times per minute and saturation of 99%. Physical examination within normal limits.

On the ECG examination, the sinus rhythm was found 93 beats per minute, normo-axis, PR interval 174 ms. Previous ECG results during hospitalization at Soewandhi Hospital obtained a regular tachycardia rhythm with a narrow QRS of 167 times per minute with no visible P wave.

Laboratory tests and chest radiograph were within normal limits. Echocardiography examination showed normal structure and function with ejection fraction (EF) 77%. Routine therapy consumed by patient is Diltiazem 1x100 mg and bisoprolol 1x2.5 mg.

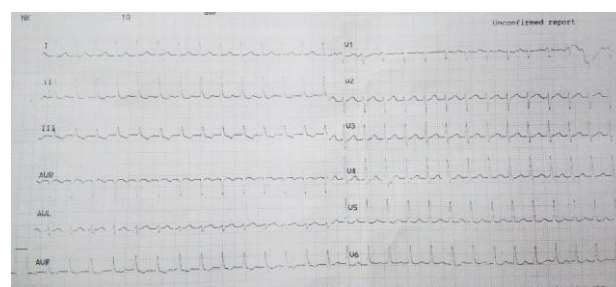


Figure 1. ECG during AVNRT

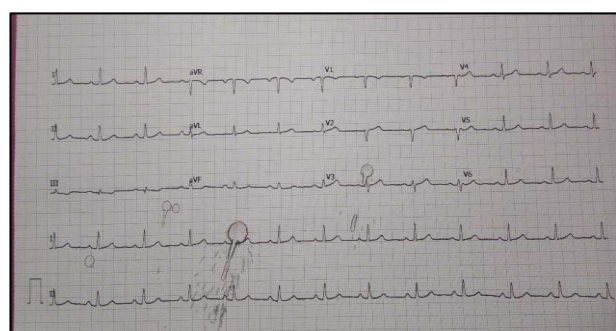


Figure 2. Patient ECG Baseline

Electrophysiological studies were performed on this patient. Puncture of the right femoral vein at three sites and insertion of two 6F sheaths and one 7F sheath in the right femoral vein with the aid of a wire. The quadripolar catheter is inserted through the 6F sheath and placed in the RV, and His-bundle. The ablation catheter is inserted through the 7F.

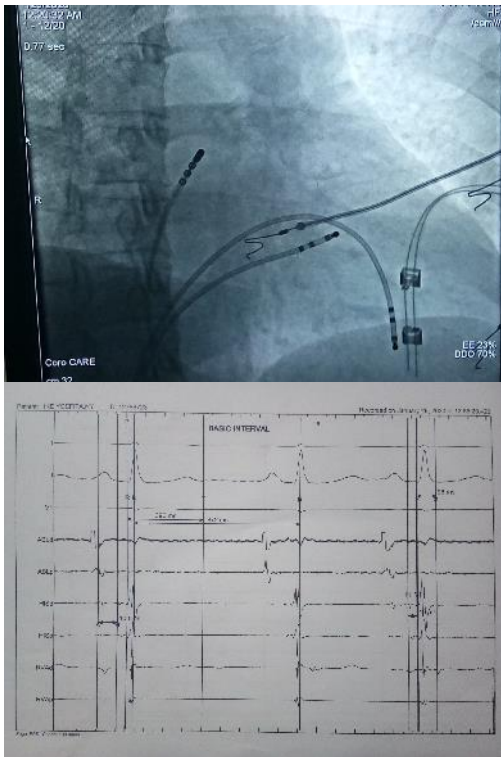


Figure 3. Placement of electrophysiological diagnostic catheter, His-bundle and right ventricle (left image) and baseline interval electrogram results

On basic interval examination of electrogram, an A-H interval of 100 ms was obtained; H-V 46 ms; QRS 96 ms; RR interval 872 ms, QT 396 ms. On incremental ventricular pacing, a WP retrograde of 355 ms was obtained. An extra stimulus test was performed on the ventricles and found AVN ERP <230 ms, V ERP 220 ms. On incremental atrial pacing, WP antegrade 405 ms was obtained. Atrial extrastimulus test was performed and tachycardia-induced with PPI: 534 ms; TCL 308 ms; PPI-TCL > 115 ms; VAV; VA interval 46 ms. Obtained A-H jump 86 ms and No Reset. It was concluded that the underlying mechanism was typical slow / fast AV nodal reentrant tachycardia.

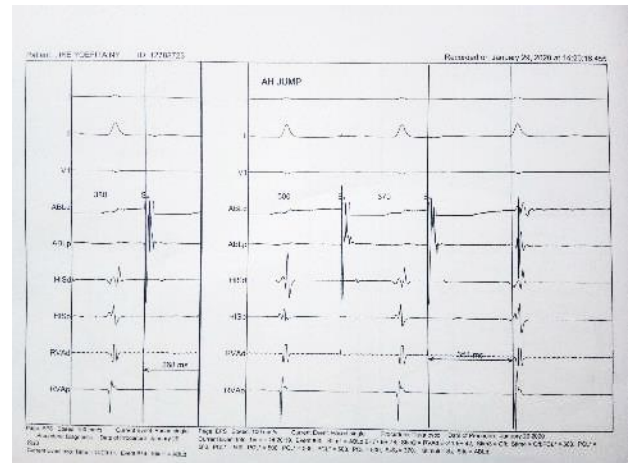


Figure 4. AH jump

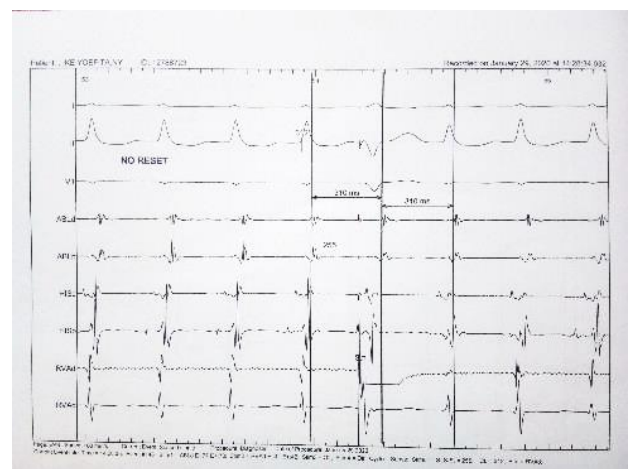


Figure 5. Maneuver response His refractory premature ventricular contraction, “no reset” obtained

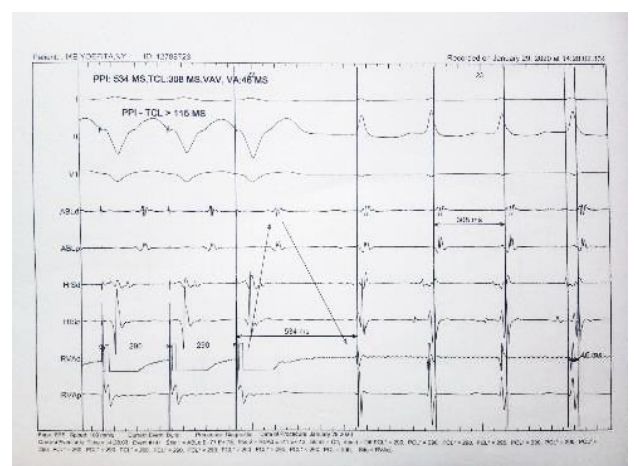


Figure 6. Post pacing maneuver response and post pacing interval

Then slow pathway ablation performed around CS ostium with radiofrequency (40 C; 30-40 watts) for 30 seconds. During radiofrequency ablation a transient junctional rhythm is obtained. Evaluated for 15 minutes and given pacing stimulation, no AH jump was obtained, and tachycardia was not induced. Evaluation followed by extra-stimulus test in the atrium obtained AVN ERP 290 ms and A ERP 210 ms.

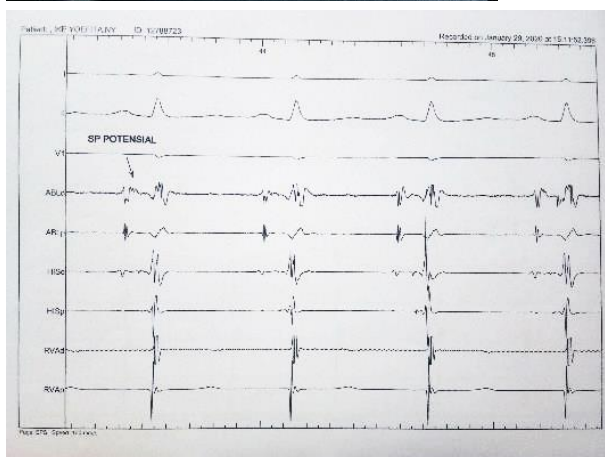
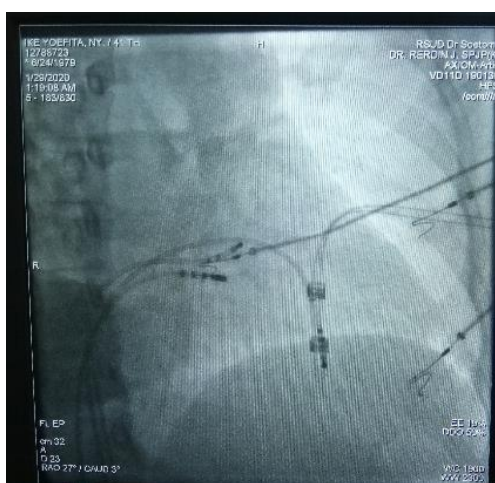

Figure 7. Ablation location with anatomical and electroanatomic approach obtained “slow pathway potential”

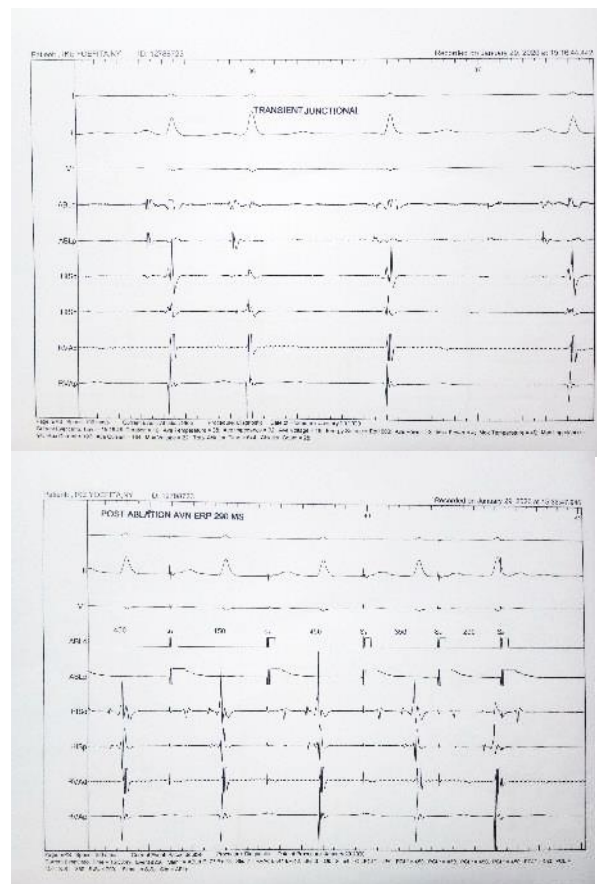


Figure 8. Transient junctional are present during the act of ablation; post-ablation evaluation was not induced tachycardia and obtained AVN ERP 200 ms

Discussion

This case describes a clinical presentation of patient with typical slow/fast AVNRT, an arrhythmia problem which occur due to paroxysmal supraventricular tachycardia (SVT) and treated using slow pathway ablation. The diagnosis of AVNRT based on clinical manifestations and ECG.

Patient with AVNRT present with clinical paroxysmal SVT syndrome, characterized by rapid and regular tachycardia with sudden onset and termination times. Patients usually complain of palpitations, weakness, chest discomfort, spinning headaches, tightness, and decreased consciousness.^[8,9]

AVNRT can occur spontaneously or on provocation with activity, caffeine, or alcohol. The typical physical examination is a neck pounding (also known as frog sign) due to atrial and ventricular contraction against tricuspid valve, and AVNRT is the most common cause. ECG examination when tachycardia occurs is ideal, the patient should see medical personnel immediately when an episode of tachycardia occurs. Examination of the 12 lead

ECG during tachycardia is very efficient in diagnosing SVT.

The common ECG presentation shows a narrow complex tachycardia (NCT) with duration of RS <120ms with regular R-R interval and no P wave detected. The P wave is usually retrograde and inversely visible in the inferior lead, but it is not visible because the atria and ventricles are simultaneously activated, and therefore the P waves are embedded in the QRS. This is the most common presentation of AVNRT which is around 66%. Based on distance between P and QRS, SVT divided into 2 groups; (1) short RP interval; (2) long RP interval. Shorter distance between P wave and QRS indicates short RP tachycardia, conversely.^[5,6]

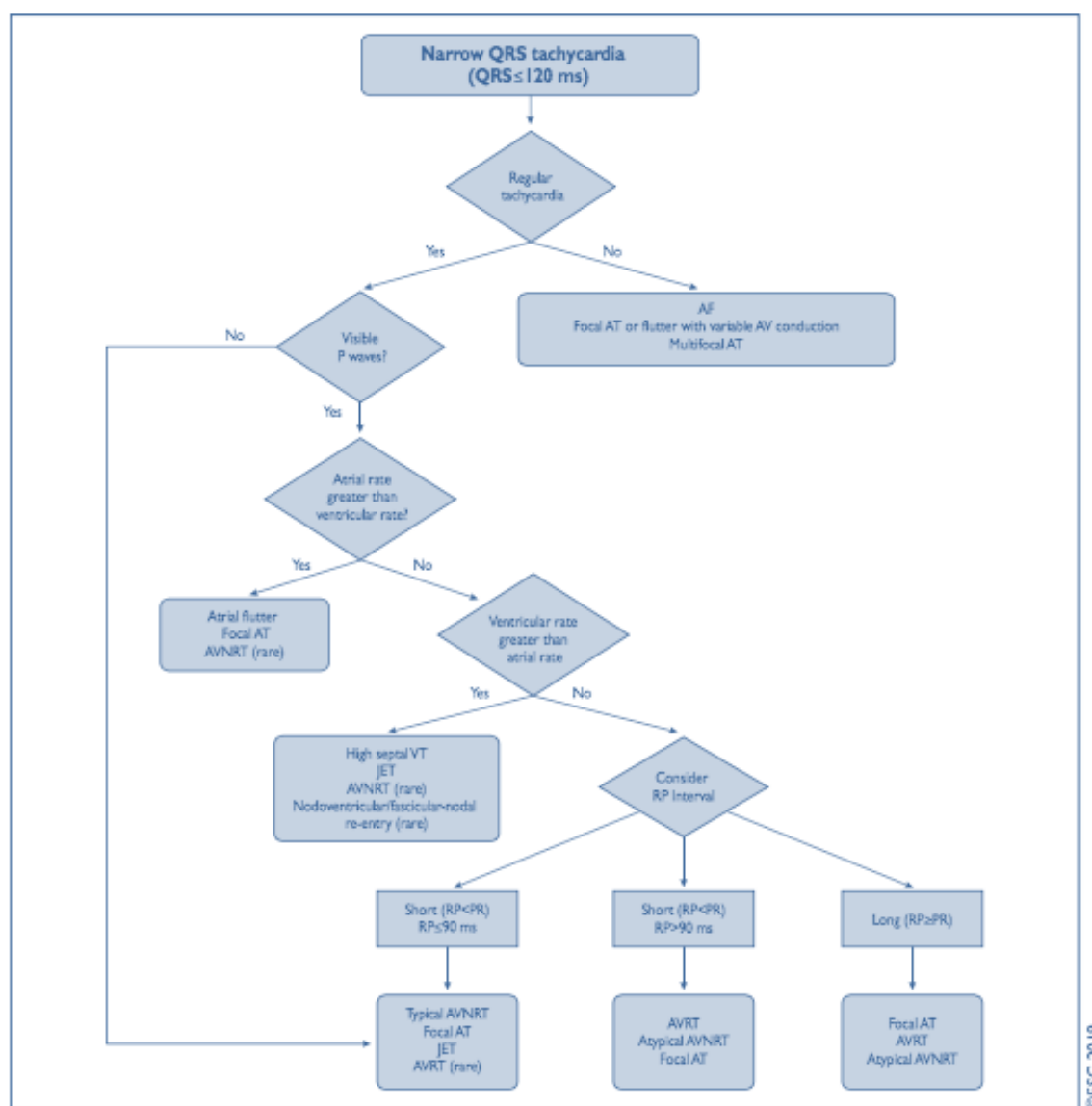


Figure 9. Diagnosis algorithm of narrow QRS tachycardia

In general, AVNRT is a benign arrhythmia and does not affect life expectancy. The main indication of therapy is to improve patient's quality of life and reduce ER visit [6,7]. A clinical test showed that patients with symptomatic and recurrent periodic tachycardia are mainly treated with ablation catheter as the first line of AVNRT management compared to anti-arrhythmia therapy. This modification of slow pathway ablation is effectively better for both atypical and typical AVNRT with

success rate of 97%, 1.34% recurrency level, and AV block incident <1%. However, patient with minimum symptoms could be given anti-arrhythmia agents, to suppress AVN conduction. In this current situation, patient had received routine diltiazem and bisoprolol therapy. Due to ineffective drugs, patient's tachycardia frequency increases with symptoms of severe tightness occurred. Thus, it can be continued with electrophysiological studies management and AVNRT ablation catheter.[5]

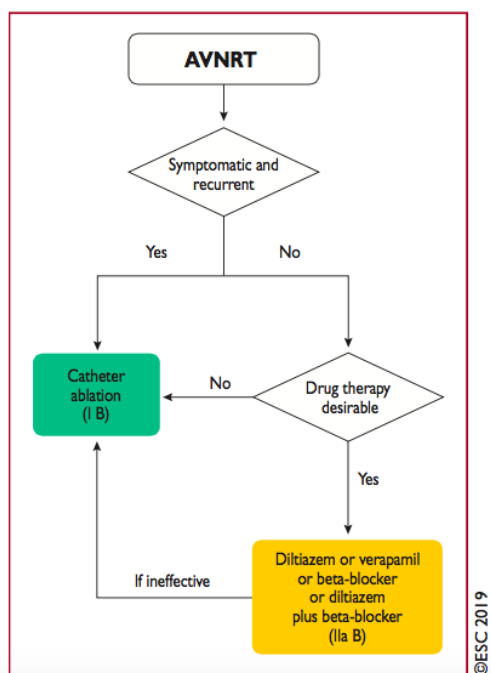


Figure 10. Chronic AVNRT Management

Electrophysiological studies were performed to assess inducibility, the mechanism of SVT and to guide catheter ablation. Examination was performed with three quadripolar catheters positioned in the right atrium, right ventricular apex, and His-bundle region; as well as a decapolar catheter placed in the coronary sinus [7,8]. The basic observation showed normal sinus rhythm. Anterograde physiologic AVN dual pathway was identified by the discovery of; (a) the AH interval jumps in response to increasingly premature atrial extra stimulus; (b) the presence of two ventricular responses to a single atrial impulse; (c) The P-R interval exceeds the R-R interval during atrial pacing; (d) and / or different PR or AH intervals when normal sinus rhythm or atrial pacing remains.[7,9]

AH time and relative AH / HA interval have been proposed as criteria for distinguishing fast-slow and slow-slow types of AVNRT. The difference between AVNRT subtypes, especially the atypical type, was determined by His-atrial (HA) interval > 70 ms and VA > 60 ms, regardless of the AH / HA ratio. In a typical (slow / fast) AVNRT, the onset of atrial activation appears before, at, or immediately after the QRS complex, therefore the AH / HA ratio is > 1. The HA interval is typically <70 ms, measured from the earliest deflection of His bundle activation to the earliest rapid deflection of atrial activation on His bundle electrogram, and the VA interval, measured from the onset of ventricular activation on the surface ECG to the earliest rapid deflection of atrial activation on His bundle electrogram. is <60 ms.[7,8,10]

Ablation Target

Selective ablation of the AVN slow pathway by lesions made posteroinferiorly near the base of the Koch triangle between the CS ostium and the tricuspid annulus (posterior approach) has been approved with higher success and safety rates. There are two point of views for determining the location of radiofrequency (RF) operations, namely the anatomical and electroanatomic approaches. The anatomical approach uses the Koch triangle landmark to determine the RF application site. The target of ablation is along the tissue between the tricuspid annulus and the CS ostium, the safest and

most effective area is along the anterior tricuspid annulus of the CS ostium, this site has a 95% success rate. [3,7,8]

Electroanatomic approach using electrogram recording in the posterior septum to show a slow pathway. It will be appeared as “slow potential” as described by Haissaguerre et al. or “slow pathway potential” as described by Jackman et al. This potential form an atrial deflection and is recorded in the mid-septum or the area between the coronary sinus ostium and the posterior (inferior) annular tricuspid septum.[2,11]

For slow-slow and fast-slow AVNRT ablation, the slow pathway used for retrograde conduction during tachycardia should be targeted. by ablation, and this target may differ from the slow AVN pathway used for anterograde conduction. Therefore, ablation may be guided by the location of the earliest retrograde atrial activation during AVNRT or ventricular motion, which is usually localized to the tissue isthmus between the tricuspid annulus and CS ostium in terribly slow AVNRT and along the anterior aspect of CS in slow AVNRT.[2,11]

Technique of Ablation

Catheter is inserted through femoral vein; another rare approach is through the superior vena cava only when the inferior vena cava obstruction obtained. To avoid AV block, quadripolar ablation

catheter with 4 mm tip and has deflection ability is used for slow pathway ablation.[7,12,13]

Few measures must be considered during the delivery of radiofrequency energy in maximum power of 50 W and maximum temperature of 30-60 seconds or until junctional rhythm formed to to avoid complication of total AV block; (i) Start the ablation at least 5 minutes after cessation of isoprenaline IV drip to relieve hyperdynamic cardiac contractility; (ii) ablation is recommended during sinus rhythm and never during tachycardia, because of tip ablation dislocation can occur; (iii) a good anatomical marker of Koch triangle, His-bundle catheter is they key point. In addition, some experts also catheters in the proximal coronary sinus to shows the ostium clearer. In this patient, ablation was performed on slow pathway, around the ostium CS with anatomical approach. An overview of electroanatomic potential in slow pathway was obtained. During ablation there is transient junctional, and no AV block is present.[7,12,13]

The target of slow pathway ablation is disappearance of AVNRT. The evaluation of slow pathway ablation divided into two criteria; (i) completed slow pathway, characterized by complete disappearance of A-H jump interval when atrium and ventricle stimulated also delayed AV 1:1 conduction, (ii) modification of slow pathway, characterized by existence of A-H jump interval

post ablation or maximum of 1 echo beat without tachyarrhythmia induction. In this patient showed after atrium and ventricle stimulated, no sign tachycardia induced, and no sign of AH jump.^[14]

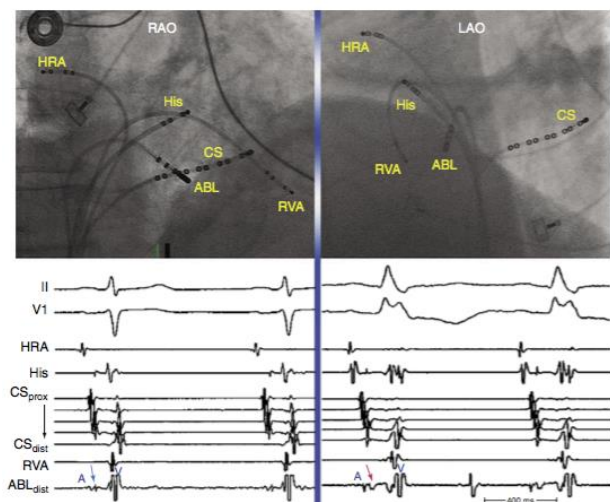


Figure 11. Placement of the ablation catheter with anatomical and electroanatomic approach shows a slow pathway potential (arrow)

Conclusion

This case presented a 41-year-old woman with complaints of chest palpitations accompanied by tightness and recurrence. ECG when SVT occurs found tachycardia with narrow QRS, P waves difficult to detect, possibly an AVNRT. From the results of electrophysiological studies, it can be concluded that the mechanism underlying the tachycardia is typical slow / fast AV nodal reentrant tachycardia. Ablation was performed on the slow pathway with no AH jump and no tachycardia induction. It was concluded that the slow pathway ablation was successful.

Acknowledgement

There is no conflict of interest.

References

1. Gonzalez M, Banchs J, Rivera J. Ablation of Atrioventricular Nodal Reentrant Tachycardia and Variants. Elsevier Inc. 2006.
2. Chrispin J, Misra S, Marine JE, Rickard J, Barth A, Kolandaivelu A, et al. Current management and clinical outcomes for catheter ablation of atrioventricular nodal reentrant tachycardia. 2017;1–9.
3. Heidbu H. How to ablate typical 'slow / fast' AV nodal reentry tachycardia. 2000;15–9.
4. Katritsis DG, Data CG. Expert Opinion Catheter Ablation of Atrioventricular Nodal Reentrant Tachycardia: Facts and Fiction Catheter Ablation of Atrioventricular Nodal Reentrant Tachycardia. 2018;230–1.
5. Brugada J, Katritsis DG, Arbelo E, Arribas F, Bax JJ, Blomstrom-Lundqvist C, et al. 2019 ESC Guidelines for the management of patients with supraventricular tachycardia The Task Force for the management of patients with supraventricular tachycardia of the European Society of Cardiology (ESC). Eur Heart J. 2019;00:1–65.
6. Knight BP, Verma N. Atrioventricular Nodal Reentrant Tachycardia. Card Electrophysiol. 2020.
7. Issa Z, Miller J. Clinical Arrhythmology and Electrophysiology A Companion to Braunwald's Heart Disease. 2nd Editio. 2012. 744 p.

8. Veenhuizen GD, Mrcp FRQ. Review Article Principles of Entrainment : Diagnostic Utility for Supraventricular Tachycardia. Indian Pacing Electrophysiol J. 2008;8(1):51–65.
9. Peiker C, Pott C, Eckardt L, Kelm M, Shin D, Willems S, et al. Dual atrioventricular nodal non-re-entrant tachycardia. Europace. 2016;18(June 2014):332–9.
10. Ho RT, Frisch DR, Pavri BB, Levi SA, Greenspon AJ. Electrophysiological Features Differentiating the Atypical Atrioventricular Node – Dependent. Circ Arrhythm Electrophysiol. 2013;597–606.
11. Willems S, Weiss C, Shenasa M. Optimized Mapping of Slow Pathway Ablation Guided by Subthreshold Stimulation : A Randomized Prospective Study in Patients With Recurrent Atrioventricular Nodal Re-entrant Tachycardia. J Am Coll Cardiol. 2001;37(6).
12. Katritsis DG, Zografos T, Katritsis GD, Giazitzoglou E, Vachliotis V, Paxinos G, et al. Catheter ablation vs . antiarrhythmic drug therapy in patients with symptomatic atrioventricular nodal re-entrant tachycardia : a randomized , controlled trial. 2016;1–5.
13. Stavrakis S, Jackman W, Lockwood D, Nakagawa H, Beckman K, Elkholey, et al. Slow/Fast Atrioventricular Nodal Reentrant Tachycardia Using the Inferolateral Left Atrial Slow Pathway: Role of the Resetting Response to Select the Ablation Target. Circ Arrhythm Electrophysiol. 2018;11(9).
14. Brachmann J, Lewalter T, Kuck K, Andresen D, Willems S, Spitzer SG, et al. Long-term symptom improvement and patient satisfaction following catheter ablation of supraventricular tachycardia : insights from the German ablation registry. 2017;49:1–10.