

## Case Report

## Management of Multidisciplinary Aesthetic Treatment in Rotation and Crossbite Tooth with Avulsion Due to Trauma Injuries

Nanik Zubaidah<sup>1</sup>, Nadira Nurin Febrianti<sup>2</sup>, Ivan Nur Fadela<sup>2</sup>, Cindy Ramadhan Putri<sup>3</sup>, Muhammad Dimas Aditya Ari<sup>4</sup>, Nirawati Pribadi<sup>1</sup>, Sri Kunarti<sup>1</sup>

<sup>1</sup>Conservative Department, Faculty of Dental Medicine Universitas Airlangga, Surabaya, Indonesia

<sup>2</sup>Undergraduate Student, Faculty of Dental Medicine Universitas Airlangga, Surabaya, Indonesia

<sup>3</sup>Postgraduate Student, Faculty of Dental Medicine Universitas Airlangga, Surabaya, Indonesia

<sup>4</sup>Prosthodontics Department, Faculty of Dental Medicine Universitas Airlangga, Surabaya, Indonesia

### ABSTRACT

**Background:** Anterior teeth that experience rotation and crossbite also lose avulsed teeth due to trauma but can be treated with endo restoration treatment. Loss of anterior teeth due to trauma can impact the appearance and decrease self-confidence due to aesthetic factors and phonetic disorders. **Purpose:** to provide information about the management of anterior teeth that undergo rotation and crossbite accompanied by avulsion due to traumatic injury by correcting the position of the teeth through a multidisciplinary approach. **Case:** A 21-year-old woman with 12 teeth had distobuccal rotation and 22 crossbite, while her front teeth 11 and 21 were avulsed due to trauma from falling from a motorcycle. Patients feel embarrassed and lack confidence when laughing and experience phonetic disturbances when speaking. According to the stomatognathic system, the patient comes to the clinic to treat his front teeth to restore their shape, esthetics, and function. **Case management:** Endo restoration treatment was carried out on 12 rotated teeth and 22 crossbites through root canal treatment, insertion of posts, and cores which will be used as abutments in the manufacture of fixed-fixed bridges avulsed teeth to rehabilitate function, anatomical and aesthetic forms. **Conclusion:** Teeth that experienced rotation, crossbite, and avulsion due to trauma can be treated with multidisciplinary treatment through endo restoration and fixed-fixed bridge to rehabilitate stomatognathic function.

**Keywords:** esthetic anterior teeth; traffic accident; rotation teeth; traumatic injury; avulsion; endo restoration; dental health

Correspondence: Nanik Zubaidah, Department of Conservative Dentistry, Faculty of Dentistry, Universitas Airlangga. Jl. Mayjen Prof. Dr. Moestopo 47 Surabaya 60132, Indonesia. E-mail: nanik-z@fkg.unair.ac.id

### INTRODUCTION

Trauma is one of the factors that can cause changes in the position and anatomical shape of the teeth, for example falling from a motorcycle and causing the front teeth to hit the pavement (road barrier) due to blows to the front of the face.<sup>1</sup> All abnormalities in the form of tooth discoloration, malposition or teeth coming out of the dental arch, and cavities, teeth that experience rotation and crossbite or even loss of teeth (avulsions), especially front teeth due to trauma, will significantly reduce the aesthetics of one's appearance when smiling and lack of confidence.<sup>2</sup> For anterior teeth that undergo rotation or crossbite to return their shape to normal teeth, dental arch repairs must be carried out. Teeth with these abnormalities can be treated with endo restoration, which includes root canal treatment accompanied by the provision of posts and cores. This aims to increase retention, change the teeth inclination, and correct the location and position of the teeth following the normal dental arch.<sup>3</sup>

Teeth play an essential role in representing a person's appearance. The position and appearance of the anterior teeth are crucial to impact a person's psychological and social life, such as supporting the success of a particular business or profession, thus affecting the quality of life.<sup>4</sup>

An avulsed tooth is the displacement of a tooth as a whole out of its socket is a rare injury, accounting for only 0.5-16% of all traumatic injuries. This is an experience that reminds dentists to raise awareness that esthetics is a primary concern for patients. Replantation can be done if the missing tooth is still in good condition, has no damage, and is placed in a suitable medium.<sup>5</sup>

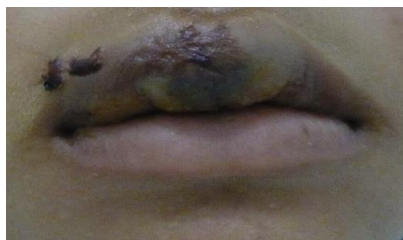
Anterior teeth that undergo rotation and crossbite and avulsion due to traumatic injury can be overcome by endo restoration treatment through endodontic treatment, commonly called root canal treatment, and the provision of core posts used as abutments and the manufacture of fixed-fixed bridges to fill missing teeth.<sup>3,6</sup>

Placement of the post into the root canal is done after the tooth has received root canal treatment. Endodontically treated teeth are usually brittle and break more easily than healthy teeth due to the organic and biological changes that occur due to pulp death, so adding reinforcing posts in the root canal is necessary.<sup>7,8</sup> The principle of post-endodontic treatment is to restore the roots and crowns of the teeth with retentive and stable post crowns so that they do not come off quickly and can be used as long as possible. The choice of restoration after endodontic treatment needs to consider several factors, namely the extent of tooth decay, the remaining supporting tooth tissue, the presence or absence of antagonistic teeth, and the amount of chewing power. These factors determine the type of restoration that will be made to protect teeth that have been treated endodontically and can function normally according to their stomatognathic function.<sup>9</sup>

The success of a restoration is determined by its retention, stability, aesthetic, biological aspects, cooperation, and understanding between the patient and the dentist. Improved appearance, especially esthetics, is becoming increasingly important in modern dental practice.<sup>10</sup> The purpose of this case report is to demonstrate the multidisciplinary management of aesthetic treatment for anterior teeth undergoing rotation and crossbite accompanied by dental avulsion due to trauma.

## CASE

A 22-year-old female patient came to private dental practice with a swollen upper lip and a torn wound due to an accidental fall from a motorcycle (Figure 1). The patient came four days after the accident and complained that he



**Figure 1.** The initial condition of the patient's lips after four days of falling.

wanted to fix the anterior teeth 12, which had rotation, and teeth 11 and 21, which were out of their sockets (avulsion), and the teeth were not found. Meanwhile, tooth 22 had a crossbite, so the patient lacked confidence in his current appearance and had difficulty speaking. Patients want aesthetic treatment on their anterior teeth and expect that the problematic anterior teeth can function like their original teeth and restore the confidence that has been lost after treatment.

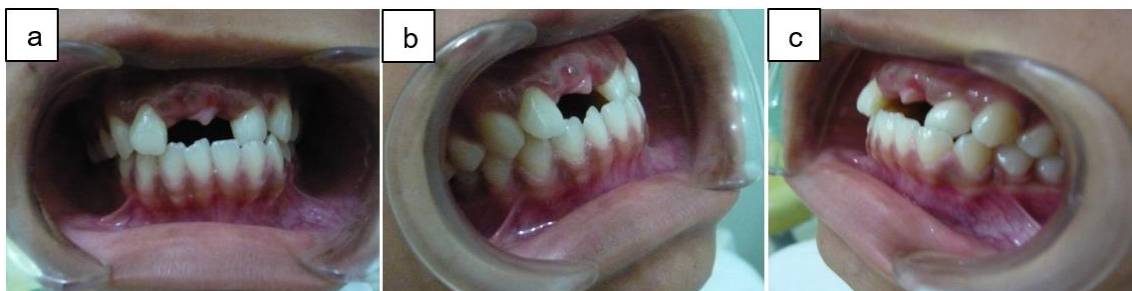Intra-oral examination on teeth 12 had disto-labial rotation, and 22 had crossbites, and teeth 11 and 21 had avulsed teeth where no dental elements were found. For the treatment plan for teeth 12 and 22, clinical photographs were taken to diagnose vital teeth. This case is planned for the manufacture of fixed-fixed bridge 4-units (12, 11, 21, 22) and root canal treatment on tooth 22 with the provision of fabricated posts (casting posts), while tooth 12 with root canal treatment and prefabricated posts which are both used as abutments in the manufacture of fixed-fixed bridges.

## CASE MANAGEMENT

The first time the patient comes to private dental practice, a history is taken then the patient is given an explanation of the procedure for the treatment plan that will be carried out. The patient agreed to the treatment and signed the informed consent. The next stage is an emergency treatment that consists of treating wounds around the lips and mouth using saline. In addition, the administration of antibiotics, analgesics, and anti-inflammatory, chlorhexidine mouthwash, and instructions to maintain oral hygiene and recommended a soft diet.

Clinical photographs were taken before treatment in teeth 11, 21, which had avulsed teeth, 12 is a vital tooth with disto-labial rotation due to trauma, and tooth 22, which had a crossbite (Figure 2). Then the anatomy of the maxillary and mandibular teeth was made using irreversible hydrocolloid impression material to obtain a model study using a one-step printing technique, record the teeth, determine the occlusion and relation, and prepare a temporary fixed-fixed bridge from acrylic on the teeth. 12, 11, 21, and 22 so as not to reduce the aesthetics of the teeth during treatment.

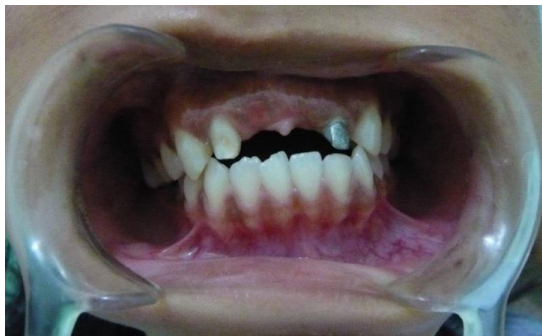Root canal treatment for teeth 12 and 22 were performed with one visit endodontic treatment using a crown down pressureless (CDP) preparation technique using the



**Figure 2.** (a). Teeth 11, 21 (avulsion) and vital teeth 12 (rotation) and tooth 22 crossbite, (b) Right side view, (c) Left side view.

ProTaper file preparation tool. The next stage was obturation on teeth 12 and 22 with a single cone filling technique using gutta-percha filling material which was given a resin-based sealer paste (AH-Plus), then the next stage was taking gutta-percha using a gate glidden drill and followed by a peeso-reamer—leaving approximately 4-5mm from the root canal apex. In tooth 12, a prefabricated post (threaded post/Animatrix) was inserted, and the core was made with multi-core composite resin.

Root canal impression of tooth 22 was carried out using elastomeric impression material for manufacturing fabricated posts (cast posts) and cores manufactured in the dental laboratory. The purpose of this cast peg is to improve inclination, overbite, and overjet. After that, the cast post and core of tooth 22 using GIC type I (Luting cement). Then the preparation was carried out on each core of teeth 12 and 22 on the same day to obtain good alignment of the position and arch of the jaw and facilitate insertion—fixed-fixed bridge four units (12, 11, 21, and 22) (Figure 3).



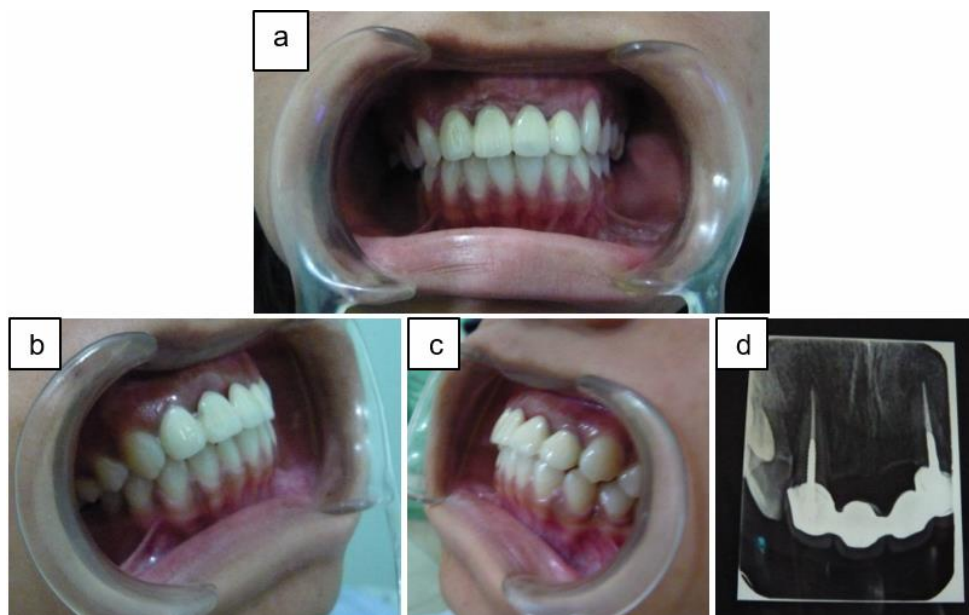
**Figure 3.** Insertion of a fabricated post for tooth 22 and insertion of a prefabricated post for tooth 12.

Posts from teeth 12 and 22 that had been inserted and matched the anterior dental arch were then imprinted using a putty-wash two-step technique with a putty elastomeric impression material with a light body. Next, a bite registration was made as a guide for the occlusion of the restoration. A temporary bridge is then inserted to maintain space during the final restoration in the dental laboratory. The impressions were sent to the dental laboratory to make fixed-fixed bridge restorations for teeth 12, 11, 21, and 22 made of porcelain fused to metal (PFM).

The dental fixed-fixed bridge coping (11, 12, 21, and 22) was tested at the next visit, and the restoration color was selected for the next visit. At this stage, an evaluation of the accuracy of the edge of the abutment tooth preparation is carried out. The restoration was then continued in the dental laboratory to complete fixed-fixed porcelain fused to metal bridge. After the restoration was completed, trial and error were performed, and an evaluation of the patient profile, preparation margins, color match, occlusion, and articulation was carried out. In the final stage, a fixed-fixed bridge was inserted for teeth 12, 11, 21, and 22 made of porcelain fused to metal (PFM) using glass ionomer type I (luting cement) (Figure 4). Then the patient was instructed to do a follow-up after one week, three months, seven months and one year after the insertion of fixed-fixed bridge restorations for teeth 11, 12, 21, and 22.

## DISCUSSION

This case is a complex aesthetic case requiring a multidisciplinary approach to obtain an optimal final result. In this case, the patient required aesthetic treatment for his anterior teeth, which had disto-labial rotation on tooth 12.



**Figure 4.** (a) Fixed insertion of fixed-fixed bridge crowns for teeth 12, 11, 21 and, 22 made of porcelain fused to metal (PFM) and the photo is seen from the front (b) right side, (c) left side, and (d) X-ray results after the installation of a porcelain fused to metal (PFM) fixed-fixed bridge crown.



On tooth 22, there was a crossbite with a diagnosis of normal vital teeth. It was necessary to correct the shape, position, and dental arch following normal dental conditions, which can be used as abutments for missing teeth (avulsion of teeth 11 and 21) due to trauma. In addition, teeth 11 and 21 were avulsed (the tooth was detached from its socket and could not be found), thus making the patient feel insecure.

For this purpose, endo restoration treatment in the form of endodontic treatment is needed, namely root canal treatment and the installation of fabricated posts and cores, which aim to increase retention of tooth 22 and improve the position and position of the dental arch. This is following Garg and Garg<sup>11</sup>, who stated that fabricated posts have the advantage of being able to improve the shape and inclination of the teeth to adjust to normal teeth by changing the direction of the core to the post so that it can be used to overcome malpositioned teeth such as tooth 22 which has a crossbite.<sup>11</sup>

The choice of post-core design as a reinforcement in the root canal was adjusted. The amount of occlusal pressure (chewing force), the diameter of the root canal, the location of the tooth, and the periodontal tissue's health are the support for the post crown.<sup>8</sup> Considerations in determining the type of crown of the peg cannot be separated from the peg design. The procedure for selecting the design and preparation of the root canal must be carried out so that it does not further weaken the remaining tooth tissue and pose a risk of post dislodgement.<sup>7</sup>

The 21 teeth were treated using a prefabricated post screw type. According to Setyawati<sup>12</sup>, screwed pegs in the tapered conduit are the most retentive, and long, threaded, parallel-walled post designs can provide good retention. Installation of prefabricated posts on tooth 12 and fabricated posts on tooth 22 was adjusted to the anterior dental arch with normal overbite and overjet so that it was hoped that a good and harmonious esthetic shape would be achieved.

The principle of dental treatment that has undergone endodontic treatment is to restore the clinical roots and crowns of teeth with retentive and stable post crowns and cores so that they are not easily separated and can be used as long as possible the oral cavity like their natural teeth. It should be noted that teeth that have undergone endodontic treatment have thinner root canal walls so that they are relatively more fragile and prone to fractures (fractures) compared to healthy teeth due to the reduction in the internal tissues of the teeth and the weak bond between the enamel and dentin due to grinding of the dentin tissue during treatment—root canal preparation. Therefore, comprehensive protection is needed by providing post and core reinforcement and making porcelain fused to metal (PFM) jacket crowns so that the teeth do not fracture.<sup>8</sup>

The construction of a temporary fixed-fixed bridge aims to maintain esthetics and increase the patient's confidence during treatment before a permanent fixed-fixed bridge is completed. In addition, a temporary fixed-fixed bridge can also help the wound healing process.<sup>13</sup>

The choice of bridge construction (fixed-fixed bridge) was based on the case. The patient experienced avulsion of

teeth 11 and 21 whose teeth could not be found, so a fixed-fixed bridge was selected. In addition, fixed-fixed bridge dentures were chosen because they have good strength and stabilization.<sup>14</sup> The porcelain fused to metal (PFM) material has an excellent aesthetic, especially the anatomical shape and color that matches the natural teeth and can function naturally. In addition, this material also has an affordable price, strength, biocompatibility, and good marginal density.<sup>15,16</sup> This is following the demands of patients who want suitable materials at affordable prices.

The final results of the treatment of the above cases were known at the time of control one week, three months, seven months, and one year after the insertion of the crown of the bridge (fixed-fixed bridge) with the results of the patient having no complaints, no pain and the results of percussion tests and palpation tests were good (normal or negative results). A treatment is considered successful if there are no complaints from the patient determined by retention, stability, aesthetics (especially anterior teeth) to restore the patient's confidence and the absence of difficulty in speaking, in addition to the biological aspect as well as cooperation and understanding between the patient and the dentist is a foundation for successful treatment. Improvement of appearance, especially in aesthetics, is becoming increasingly important in today's modern dental practice.<sup>10</sup> From the description above, it can be concluded that the stomatognathic system can obtain optimal functional and esthetic results. Multidisciplinary treatment is needed in anterior teeth undergoing rotation and crossbite accompanied by dental avulsion due to trauma.

## REFERENCES

1. Celikten B, Uzuntas CF, Safaralizadeh R, Demirel G, Sevimay S. Multidisciplinary Approach for the Treatment of Horizontal Root-Fractured Maxillary Anterior Teeth. *Case Rep Dent.* 2014;1-7.
2. Gouveia THN, Dias Theobaldo J, Vieira WF, Leite Lima DAN, Aguiar FHB. Esthetic smile rehabilitation of anterior teeth by treatment with biomimetic restorative materials: A case report. *Clin Cosmet Investig Dent.* 2017; 9:27.
3. Yadav L, Matto KA, Kapoor A, Shuja S. Factors Associated With Post Core Correction of Malpositioned Teeth. *Int J Res Med Sci Technol.* 2015;1(2):5-7
4. Rao, Lakshmi Nidhi, Aditya Shetty, and Mithra N. Hedge. "Psychological Effects of Trauma to Anterior Teeth." EXECUTIVE EDITOR 11.01 2020: 125.
5. Inayah, Yayah, and Yetty Herdiyati. "Penanganan avulsi dua gigi permanen pada anak usia 12 tahun." *Indonesian Journal of Paediatric Dentistry* 1.1 2019: 86-91
6. Singh M, Khan A, Ansari A, Sharma K, Sharma S. Esthetic Rehabilitation of Anterior Missing Teeth by Fiber-reinforced Composite: A Case Report. *J Res Adv Dent.* 2021;12(3): 50-54.
7. Perdigao, Jorge. *Restoration of Root Canal-Treated Tooth*, Switzerland, Springer International Publishing. 2016: 28-33.
8. Chan DCN, Myers ML. *Chipped, Fractured, or Endodontically Treated Teeth in Goldstein, RE. Esthetics in Dentistry.* 3<sup>rd</sup> ed. BC Decker Inc, Hamilton, London. 2018:720-740.

9. Awaru BT, Nugroho JJ. Restorasi pada gigi anterior setelah perawatan endodontik Restoration of anterior tooth after endodontic treatment. *J Dentomaxillofacial Sci.* 2012;11(3):187.
10. Contrepolis M, Soenen A, Bartala M, Laviolle O. Marginal adaptation of ceramic crowns: A systematic review. *J Prosthet Dent [Internet].* 2013;110(6):447-454.
11. Garg N, Garg A. *Endodontics.* 4th ed. New Delhi: Jaypee Brothers Medical Publishers; 2019: 415.
12. Setyawati, Any. Restorasi Estetik 1 Kali Kunjungan Dengan Penggunaan Pasak Pada Kasus Fraktur (Laporan Kasus). *Insisiva Dental Journal: Majalah Kedokteran Gigi Insisiva*, 2012, 1.1.
13. Setiawan, Aris, Suryani Catur, and S. Triwindiari. "Prosedur Pembuatan Gigi Tiruan Jembatan Immediate 543 dengan Ovate Pontic sebagai Restorasi Sementara." *Jurnal Kesehatan* 7.1. 2016: 144-147.
14. Madhok, Sakshi. Evolutionary Changes in Bridge Designs. *IOSR Journal of Dental and Medical Sciences (IOSR-JDMS).*2014:51
15. Mona, D. Restorasi Pasak Fiber Dan Porcelain Fused To Metal Pada Fraktur Gigi Insisif Rahang Atas Pasca (Fiber Post Restoration And Porcelain Fused To Metal In Incisivus Maxilla After Endodontic Treatment). *Andalan Dental Journal.* Jakarta .2013:72.
16. Karim A, Dharmautama M, Machmud E. Bentuk Preparasi Akhiran Servikal Mahkota Porcelain Fused to Metal Mempengaruhi Insidensi Gingivitis Pada Gigi Insisivus Sentralis Rahang Atas. *J Dentomaxillofacial Sci.* 2013;12(3):183.