

Case Report

Anterior maxillary teeth crown lengthening and indirect veneer for esthetics rehabilitation: A case report

Ganiezha Cindananti¹, Nina Dhanian¹, Widya Saraswati², Nurshiffa Hanifatul Amrina Jaelani¹, Cathelea Raihan Avicenna¹

¹Resident of Conservative Dentistry, Faculty of Dental Medicine, Universitas Airlangga, Surabaya, Indonesia

²Department of Conservative Dentistry, Faculty of Dental Medicine, Universitas Airlangga, Surabaya, Indonesia

ABSTRACT

Background: Crown lengthening is a surgical procedure performed to create a symmetrical gingival line and is carried out to expose necessary additional tooth structure. A short clinical crown occurs as a result of dental malformations, eruption disharmony, and genetic variation. **Purpose:** The purpose of this case report is to explain the treatment management of crown lengthening over the case of diastema closure by indirect veneer restoration. **Case:** 32 years old female presented with a chief complaint over a space between her anterior maxillary teeth. She wants to rectify her smile. **Case Management:** The management in this case are preparation of Digital Smile Design (DSD), crown lengthening on 11 and 21, and indirect veneer on 11, 21, 22. **Conclusion:** Aesthetical rehabilitation could be attained by an indirect veneer treatment followed by a gingival management which is crown lengthening.

Keyword: Crown Lengthening; Veneer; Diastema; Esthetics

Correspondence: Ganiezha Cindananti, Resident of Conservative Dentistry, Faculty of Dental Medicine, Universitas Airlangga. Jl. Mayjen Prof. Dr. Moestopo No. 47, Surabaya 60132, Indonesia. Email: ganiezha.cindananti-2020@fkg.unair.ac.id

INTRODUCTION

Crown lengthening is a surgical procedure which designed to improve the width of supra-gingival tooth structure for restorative or aesthetic purpose by positioning gingival margin to the apical or removing a supporting bone, or the combination of both, to achieve a symmetrical gingival line.^{1,2} The purpose of crown lengthening are to provide an adequate dimension of crown for a stable dentogingival complex and for a placement of restorative margin, therefore it may finally achieve prudent final restoration with the best and esthetical marginal seal.¹

The general causes of clinically short crown are caries, erosion, teeth malformation, fracture, attrition, eruption disharmony, and genetic factor.^{1,3} Nowadays, esthetical treatment protocol could be used to overcome any discrepancy and as a guidance in decision making under a multidisciplinary approach to establish a satisfying and predictable result. Digital Smile Design (DSD) is a diagnostic tool which useful in evaluating a tooth size, shape, position, and gingival contour, and also allowing us in acquiring expected result from the treatment plan. In the case of a clinically short crown, collaboration with periodontist may be needed to fix the abnormality of tooth symmetry and contour by surgery.⁴ The purpose of this case report is to explain the treatment management of crown lengthening over the case of diastema closure by indirect veneer restoration.

CASE

Female patient, 32 years old, came to Universitas Airlangga Dental Hospital (RSMGP Unair) with a condition of there is a gap between her maxillary incisors teeth. She wants to rectify her smile. No sore has been reported from the patient. The result of intra oral clinical examination (Figure 1A) stipulates: central diastema, gingival margin look more to the coronal, gingival over the teeth are normal, no mobility, and teeth 11, 21, 22 are vital. No periapical abnormality has been found by dental radiographic assessment (Figure 1B). Saliva test results are: hydration 18 second, pH 7, viscosity watery, quantity 7ml/5second, buffer 12. Teeth 11, 21, 22 diagnosed with normal pulp and normal periapical tissue. Treatment plan for this patient is preparation of DSD (Figure 2), surgical Crown Lengthening teeth 11, 21 and indirect veneer restoration over teeth 11, 21, 22.

CASE MANAGEMENT

In the first visit, the DHE, inform to consent and informed consent were given. The preparation of crown lengthening (Figure 3) is begin with the measurement of tooth proportion using a T-Bar proportion Gauge (*Chu Aesthetic Gauge*), then continued with the measurement of the depth of periodontal pocket using periodontal probe. Teeth 11 and 21 has 3mm

facial sulcus depth. Area within teeth 11 and 21 were anesthetized using 1ml local anesthetic infiltration and the position of alveolar bone were measured using bone sounding on region 11 dan 21. The result: midfacial osseus crest on teeth 11 and 21 were 5mm from the gingival margin.

In the second visit, patient's systemic condition was checked to assure that the patient in the good condition to

undergo a surgical procedure and continue to undertake the crown lengthening procedure (Figure 4 and 5). Asepsis procedure during pandemic is the patient has to gargle a 1% povidone iodine for 30 second, the application of sterile surgical linen, and an extra and intra oral asepsis.

Topical anesthetic was given to mucolabial fold of teeth 11 and 21 and then local infiltration of lidocain HCl 2% were

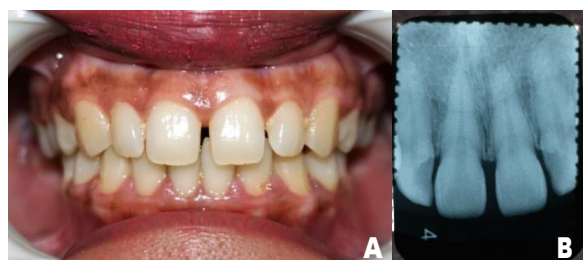

Figure 1. A. Pre-operative clinical picture; B. Pre-operative periapical radiographic.

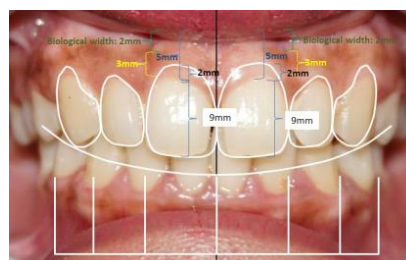

Figure 2. Digital Smile Design (DSD) result.

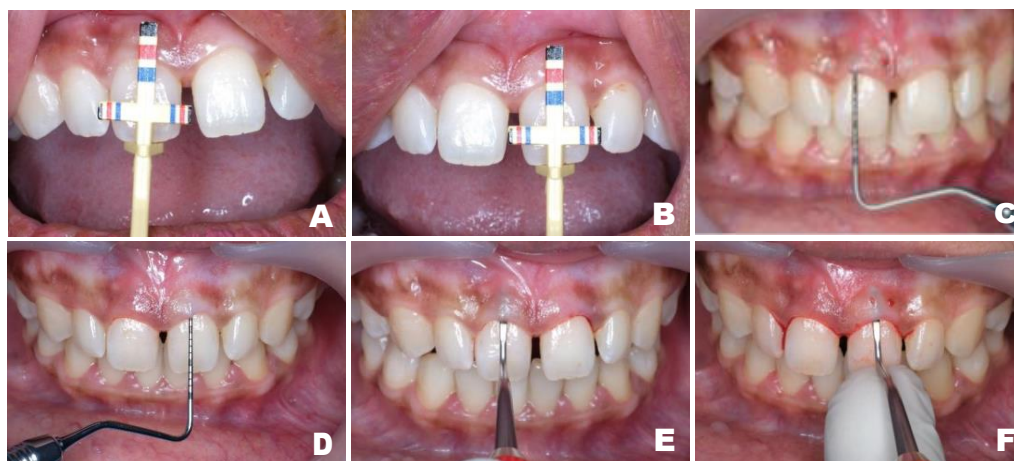


Figure 3. A. The measurement of teeth 11 proportion using T-Bar Proportion Gauge; B. The measurement of teeth 21 using T-Bar Proportion Gauge; C. The measurement of tooth sulcus depth on teeth 11; D. The measurement of tooth sulcus depth on teeth 21; E. The measurement of alveolar bone position on teeth 11; F. The measurement of alveolar bone position on teeth 21.

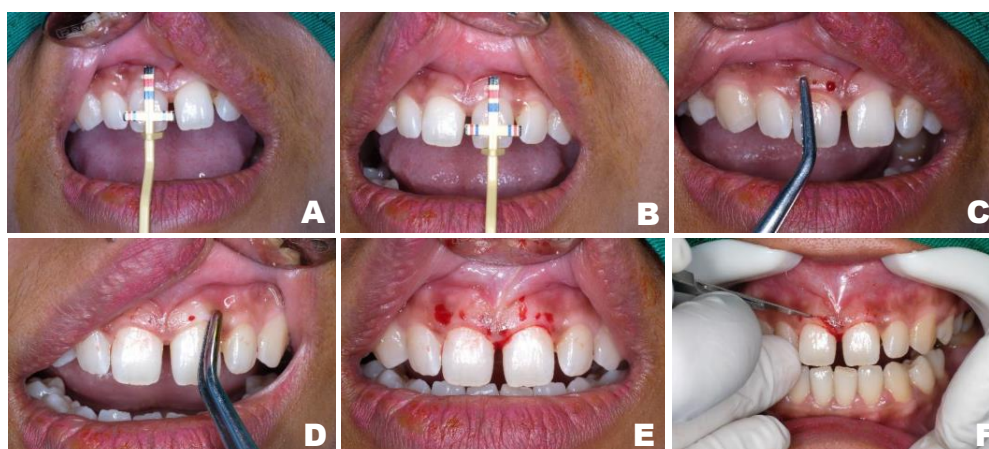


Figure 4. A. The bleeding point measurement on teeth 11 using T-Bar Proportion Gauge; B. The bleeding point measurement on teeth 21 using T-Bar Proportion Gauge; C. Bleeding point on gingival region 11; D. Bleeding point on gingival region 21; E. Bleeding point result; F. Gingival region incision on teeth 11 & 21

injected. Prior measurement of bleeding point taken using T-Bar proportion Gauge and bleeding point is formed at the gingival labial margin of tooth 11 and 21 using a pocket marker forcep. The incision of gingival margin gingival teeth 11 and 21 by external bevel incision using scapel no 15c right from the apical with an approximately of 45° angle over the central maxillary incisors surface inside the tissue limit which has been previously marked using a pocket marker forcep. Incised tissues are taken by curettage and the gingival is contoured, using Kirkland periodontal knife on the facial part, and for the interdental part, using Orban periodontal knife. The gum line is evaluated using periodontal probe in the cervical and the depth of alveolar bone has also been evaluated. Saline irrigation is made over surgery area and periodontal pack is installed. Patient is given a post-surgical instruction and a 500 mg mefenamic acid recipe (to be consume only if in pain), and a *chlorhexidine gluconate 0.2% oral gargle*.

The patient came for dental control and suggests that there is no complaint one week after the second visit. The periodontal pack fell off 1 day before the third visit and the gingival are in good condition (Figure 6A). Teeth area 11 and 21 irrigated by saline and patient's tooth are printed using an irreversible hydrocolloid material for following laboratory dental wax-up (Figure 6B).

The fourth visit, patient's control has also stipulated that there is no complaint and the gingival are in good condition.

Moreover, the teeth color were determined (Figure 7A) using Ivoclar A-D shade guide B2. Wax up result was printed to make a silicon index (Figure 7C). Depth cuts over teeth 11, 21, 22 are prepared first using depth cutting bur with 0.5 mm depth on cervical, 0.5 mm depth on medial, and 0.7 mm depth on 1/3 incisal. Tooth preparation (Figure 7B) were done with an incisal overlapping design using round end tapered bur, then retraction cord was installed (Figure 7D). The upper jaw is made with an elastomer double impression material whilst for the lower jaw made with an irreversible hydrocolloid material. Bite registration were made. Temporary veneers (Figure 7E) were installed and the tooth impression were sent to the laboratory to make an emax veneer.

On the fifth visit, the patient has no complained, the temporary veneer were in good condition, and the gingival around those teeth are normal. The temporary veneer is removed and the indirect veneer were try in, and the test of marginal adaptation with on the tooth tissue, color conformity, shape, and occlusion are in commensurable condition, and therefore *try in* using pasta *try in*. Veneer was etched by using 9% buffered hydrofluoric acid for 90 second (Figure 8A), it cleaned and dried off, and silane solution applied (Figure 8B). Teeth 11, 21, and 22 were etching using 37% phosphoric acid in 20 second (Figure 8C), irrigated, dry off, and bonding applied and then light curing for 20 second. Veneer inserted using light curing luting composite (Variolink Esthetic LC), and the excess

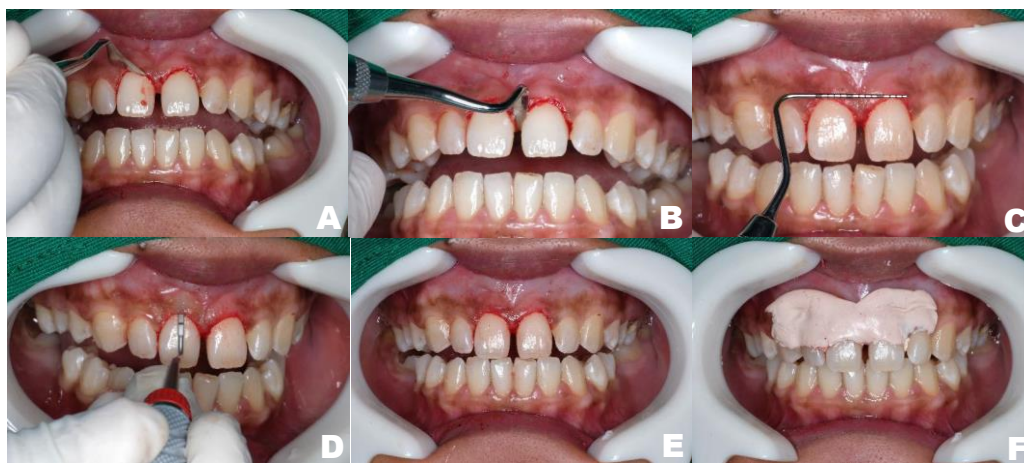


Figure 5. A. Gingival facial contour using *Kirkland* periodontal knife; B. Gingival interdental contour using *Orban* periodontal knife; C. Gum line symmetry evaluation; D. Alveolar bone depth evaluation; E. Labial look after *crown lengthening*; F. *Periodontal pack* installment.

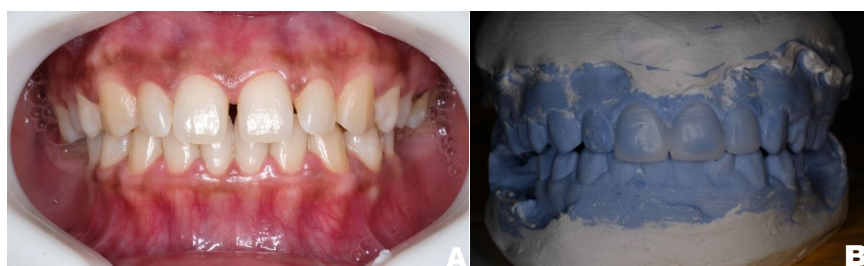

Figure 6. A. Gingival condition post crown lengthening; B. Wax up model.

dental cement is cleaned up (Figure 8D and 8E). One week follow up after insertion, the patient has no complaint and veneer is in prudent condition, gingival around the teeth is in normal condition (Figure 9).

DISCUSSION

Crown lengthening is proceed for an aesthetical fixation during restoration, and in teeth with subgingival caries or fracture. Moreover, this surgical procedure could establish an accurate bone width and right gingival asymmetry. Crown lengthening treatment is based on two principles

which are: the establishment of *biological width* (BW) and the maintenance of *keratinized gingiva* (KG) near tooth. BW is a dimension of soft tissue which attached to teeth coronal section up to the tip of alveolar bone.⁵

Adequate space between restoration margin and the top of the bone is needed to attain a healthy gingival. The attachment dimension range are approximately between 1.77 to 2.43 mm. Thus, there must be at least 2.5 mm between restoration margin and the alveolar crest. Average BW is 1.91 mm, where 1.14 mm is a *junctional epithelium* and the other 0.77 mm is a connective tissue attachment. Average sulcus depth is 1.32 mm.^{5,6} Crown lengthening aimed to expose a necessary additional tooth structure,

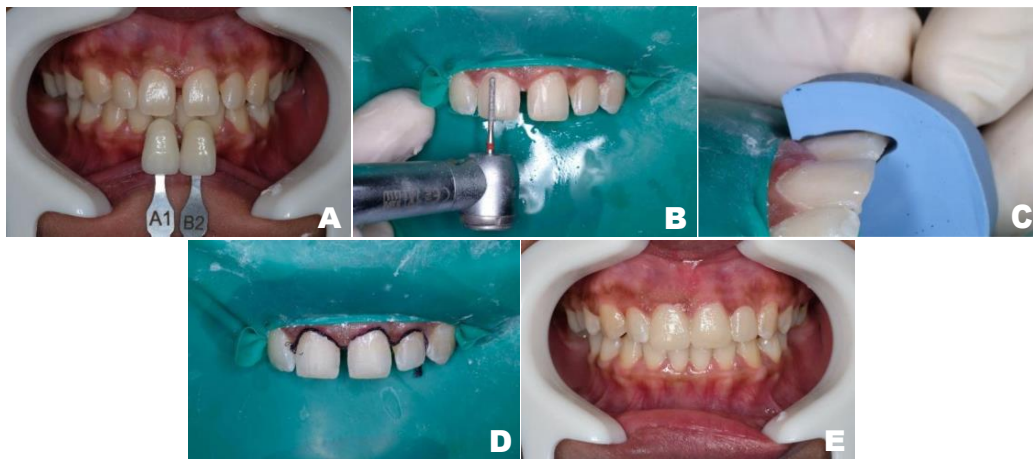


Figure 7. A. Deciding tooth colour; B. Veneer preparation; C. Silicon Guide; D. Retraction cord installment; E. Temporary veneer.

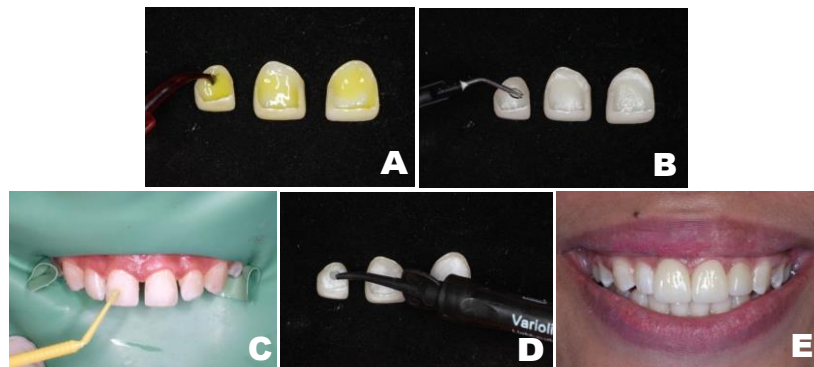


Figure 8. A. Hydrofluoric acid 9% application; B. Silane application; C. Etching and bonding on teeth; D. Veneer cementation; E. Veneer insertion.

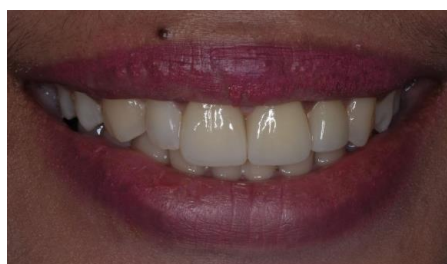

Figure 9. One week follow up after insertion.

and even though the attachment of soft tissue around the teeth of each person may vary but there must be at least 3 mm of restorative margin to the crest of alveolar bone, so thus it will allow of 2 mm BW and 1 mm sulcus depth to hinder a biological width violation.^{1,2} On this case report, an incision was done by a guidance to determine a new gingival zenith. A zenith point is the most apical point of the gingival marginal. It measured as the distance of the highest gingival margin position to the vertical bisected line, bisecting the midline of the apical, and incisal contact area positions of the teeth. Except for a lateral incisivus teeth, because the tip point is on the middle of the teeth.⁷ A maximum symmetrical zenith placement is highly necessary, especially on the central maxillary incisors teeth because of the gap between those teeth and the face midline.¹⁴

“Aesthetic” implies beauty, naturalness, and ageless look despite of someone’s age. Esthetic Dentistry created a new dimension in giving such aesthetic and functional rehabilitation.⁸ The wrong teeth proportion and dimension related to “an unpleasing smile”, because of an excessive opening on gingival zone. Beside of the proportional balance between the soft and hard tissue, there is another important component on which it has to be considered in evaluating a smile. Those components are the middle line position, smile line, incisal edge, incisal crenels, age, sex, colour, and tooth structure.⁹

To simplify this case management, a modest technique is used. It only takes a software (ie. power point or keynote) and a picture taken by a digital camera. The usage of a DSD has made the achievable treatment of aesthetical tooth reparation in a brief moment. This digital tool has facilitated an aesthetic result, from the line placement and digital image on extra and intra-oral picture following certain order to guide and evaluate an aesthetical relation between the tooth, gingival, smile, and face.¹⁰ Making an accurate gingival level for each teeth is the key in creating a harmonious and ideal smile. The gingival margin of a lateral incisivus teeth is 0.5-2.0 mm under the central maxillary incisors teeth. An expected gingival placement on lateral incisivus teeth is too apical if compared to the incisivus central and canine teeth.⁷

Diastema is a gap with more than 0.5 mm space between proximal teeth and the other tooth next to it. This often caused aesthetic disturbance for some people, especially those having it at the anterior. There are plenty ways fixing diastema, either orthodontics treatment, restoration, veneer, crown, or resin composite. Indirect veneer is a prudent choice in giving a satisfying aesthetic result and for sustaining tooth structure. Indirect techniques have some benefits in giving an accurate anatomy, softer fake tooth surface, remarkable aesthetic, good strength, durability, and takes only a little remark for finishing.¹¹

On this report, a veneer *porcelain lithium disilicate* were used for an aesthetic rehabilitation. It is the thinnest veneer. The fracture toughness and biaxial strength of this material are the biggest than other materials.¹² Veneer preparation must be conducted, among 50-70% area enamel area,

especially on the part of preparation margin. Debonding ceramic veneer thus been reported when the dentin area has attained 80% of the complete preparation area, but on the contrary, debonding were not usually happen if the preparation margin were located at the enamel.¹³ In conclusion, aesthetical rehabilitation could be attained by an indirect veneer treatment followed by a gingival management which is crown lengthening.

ACKNOWLEDGEMENT

This full paper has been presented on the National Scientific Seminar (SINI) V, IKORGI, with theme: “From Scientific Evidence to Clinical Practice in Conservative Dentistry” on 11-13 November 2022 at the Indonesia Convention Exhibition/ ICE BSD.

REFERENCES

- Oliveira Pablo Santos De et al. 2015. Case Report Aesthetic Surgical Crown Lengthening Procedure. Hindawi Publishing Corporation Case Reports In Dentistry Volume 2015, Article Id 437412, 4 Pages.
- Patil Nikita. 2021. Clinical Crown Lengthening: A Case Report. International Journal Of Applied Dental Sciences 2021; 7(1): 323-326.
- Sharma Ashu Et al. 2012. Short Clinical Crowns (Scc) – Treatment Considerations And Techniques. J Clin Exp Dent. 2012;4(4):E230-6.
- Passos Leandro Et al. 2016. Case Report Esthetic Rehabilitation Through Crown Lengthening Surgery And Conservative Cad/Cam Veneers: A Multidisciplinary Case Report. Hindawi Publishing Corporation Case Reports In Dentistry Volume 2016, Article Id 5720851, 7 Pages Http://Dx.Doi.Org/10.1155/2016/5720851
- Bhochhibhoya A & Shrestha R .2020.Biologic Width-A Review. Journal Of Nepalese Prosthodontic Society (Jnps) Vol. 3/No. 2/July-December, 2020
- Gopikrishna. 2021. Grossman’s Endodontic Practice 14th Edition. Chennai India: Wolter Kluwer
- Sri Wahjuni Et Al. 2021.The Making Of Snap-On Smile With Acetyl Thermoplastic Resin To Improve The Aesthetics And Function In Case Of Tooth Loss. Journal Of Vocational Health Studies 04 (2021): 136-145
- Hayman HO. 2011. Sturdevent: Art And Science Of Operative Dentistry 6th Ed. St Louis, Missouri: Elsevier
- Coachman C, Calamita M. Digital Smile Design: A Tool For Treatment Planning And Communication In Esthetic Dentistry. Quintessence Dent Technol 35 (2012): 103-111.
- Santi Marina Rodrigues Et al. 2020. Digital Smile Design Applied To Dental Esthetic: A Case Report. Dent Res Oral Health 2020; 3(3): 141-152 Doi: 10.26502/Droh.0028
- Prawesthi Endang Dan Hasan Moh.2017.Case Report: Labial Veneer All Porcelain With Press Method For Improving Aesthetic On Patient With Central Diastema Case. Sanitas: Jurnal Teknologi Dan Seni Kesehatan Vol. 8 (1). 2017: 48 – 56
- Kaushik Pratyasha Et Al. 2020.Lithium Disilicate Ceramic Veneers For Esthetic Restoration Of Anterior Teeth: Two Case Reports. Journal Of Dental Research And Review Vol 7

Issue 3 Page 142-146

13. Krump Michal And Krumpova Zelmira. 2022. Esthetic Rehabilitation Of Anterior Dentition With Different Types Of Ceramic Restorations: Two Case Reports. Eur J Dent. 2022 Feb; 16(1): 234–239. Published Online 2021 Oct 1. Doi: 10.1055/S-0041-1732805
14. Ganji Kiran Kumar, et al. 2018. Facial profile based evaluation of gingival zenith position in maxillary central incisors among Saudi, Indian & Bangladeshi population. Saudi Dental Journal 30: 342-347.