

Case Report

One visit endodontic with internal bleaching on tooth 12 post trauma: A case report

Reyz Pasenda Mulyadi¹, Sofi Arnesti Wahab¹, Febriastuti Cahyani², Widya Saraswati²

¹Resident of Conservative Dentistry, Faculty of Dental Medicine, Universitas Airlangga, Surabaya, Indonesia

²Conservative Dentistry Department, Faculty of Dental Medicine, Universitas Airlangga, Surabaya, Indonesia

ABSTRACT

Introduction: Post-traumatic non-vital teeth is one of the indications for One Visit Endodontic. Trauma to the teeth may arise from conditions that cause the teeth to become necrotic so that the teeth will look darker and experience discoloration. Clinical conditions that indicate the death of the dental pulp and teeth require endodontic treatment. This situation will cause discoloration of the teeth that occur as a result of the metamorphosis of calcified pulp. Internal whitening is a treatment that can be done after the first treatment. **Purpose:** To provide information about discolored teeth management after trauma which causes pulp necrosis by doing root canal treatment and internal bleaching to change tooth color. **Case:** A 31-year-old woman came to the RSKGMP Universitas Airlangga with a referral from the orthodontics department where her teeth were darker in color and interfered with her appearance. In the previous history, the patient had an accident and trauma 10 years ago. **Case Management:** The first step is access opening and a good glide path. Root canal preparation was performed using the Crown Down Pressureless technique. The obturation technique used is Single Cone. The results were good and there were no symptoms during the control. **Conclusion:** One visit endodontic can be a treatment option for post-traumatic non-vital teeth. Internal bleaching with Walking Bleach Technique is also proven effective in restoring the original tooth color without excessive reduction of the dental crown.

Keywords: One Visit Endodontic, Internal Bleaching, Necrosis, Chronic Apical Abscess, Trauma

Corresponding authors: Widya Saraswati, Department of Conservative Dentistry, Faculty of Dental Medicine, Universitas Airlangga. Jl. Mayjen Prof. Dr. Moestopo no. 47, Surabaya 60132, Indonesia. E-mail: widya-s@fkg.unair.ac.id

INTRODUCTION

Dental trauma is one of the factors causing pulp damage. With caries-induced dentinal fissures around the restoration, accidental exposure of the pulp, infection, or bleeding gums facilitates entry of bacteria. Another factor that affects pulp damage is physical trauma, both mechanical and thermal. Mechanical injury to the pulp generally caused by trauma or wearing dentures. Traumatic injuries may or may not be associated with crown or root fractures. These injuries are also commonly caused by impact on the teeth, whether due to sports activities or accidents. In this case, the patient had an impact and accident ten years earlier and her teeth were discolored.¹

Tooth color is one of the most important aesthetic factors. Discolored teeth can have significant psychological effects, for example, excessive self-confidence, such as a reluctance to speak and smile. Tooth discoloration (discoloration) is classified into intrinsic and extrinsic discoloration. Causes of extrinsic tooth discoloration include colored foods and drinks, such as coffee, tea, tobacco, mouthwash, or plaque on the tooth surface. Intrinsic causes of tooth discoloration include impact trauma, systemic disorders,

metabolic, genetic, dental treatment procedures, fluorosis, and tetracycline antibiotics.²

In this case, the initial treatment is root canal treatment because the tooth has undergone necrosis. The principle of root canal treatment is one visit treatment, including cleaning, shaping, and disinfection of the root canal, followed by filling the root canal in one visit. Multi-visit root canal treatment potentially increases contamination and flare up, causing treatment failure. One Visit Treatment for root canal treatment can reduce the risk of microorganism contamination in the root canal and save time without compromising the quality of treatment.³

Various managements (treatments) for non-vital anterior teeth discoloration can be treated, including full crown restorations, veneers, and internal bleaching. In the case of anterior teeth with relatively intact crown structures, internal bleaching is one of the best treatment choices. This procedure is minimally invasive compared to full crown or veneer restorations, which require the removal of some of the tooth structure. The Walking Bleach Technique using 35% hydrogen peroxide can be the procedure for internal bleaching. The Walking Bleach Technique, if done precisely, can treat tooth discoloration effectively and safely. In this

case report, we will discuss internal bleaching with the walking bleach technique on the maxillary right lateral incisor after trauma approximately ten years ago.⁴

CASE

A 31-year-old woman visited RSKGMP Universitas Airlangga with a referral from the orthodontics department. Some teeth are darker in color and worsen her appearance. The patient’s previous history was an accident and trauma ten years ago, which makes the patient bothered by his appearance and wants her teeth to return to normal. A few days ago, she suffered tooth pain and eventually subsided, but a white lump was found around the teeth. The tooth was so sore, but it returned to normal. The patient had no history of systemic disorders and no allergies. Initial clinical appearance can be seen in Figure 1a. Clinical examination revealed that the teeth were darker in color, percussion (-), bite test (+), and labial fistulas. Examination of the vitality of tooth 12 obtained a cavity test (-), and salivary hydration salivary hydration examination for 25 seconds (green). As seen in Figure 1b, radiographic examination showed a diffuse radiolucent border on the apical area of tooth 12. The tooth was then diagnosed with pulp necrosis with a chronic apical abscess on tooth 12.

CASE MANAGEMENT

The patient was given IEC, DHE, and a request for informed consent and informed consent at the first visit. Root canal treatment begins with determining the initial color using the Vita 3D Master (4M3) shade guide. Rubber dam is applied

and followed by tooth 12 Access Opening with an endo access bur. Negotiation using K-File #8 and determining working length with the apex locator (PK: 23 mm) as shown in Figure 2a. Next, glide path management and apical gauging using K-file #30 can be seen in Figure 2b.

As shown in Figure 2c, root canal preparation using Rotary Protaper Next file up to X3 needle. Irrigation was carried out using 2.5% NaOCl at each file change and uses K-File #10 to recapitulate. After preparation, a Trial Guttap can be done with Gutta Percha X3 (Protaper Next) can be seen in Figure 2d. In the final stage of irrigation, irrigation can be done with 2.5% NaOCl, 17% EDTA, and aquadest, activation of irrigation materials using sonic activation. Furthermore, the root canal was drained using endo suction and a paper point tip. Obturation can be performed using a single cone technique with a calcium silicate-based sealer. Furthermore, radiographs are taken to confirm the results of the obturation, as shown in Figure 3.

On the second visit, the patient gargled with 1% povidone iodine solution for 30 seconds. Initial shade guide measurement can be seen in Figure 4a. During this visit,

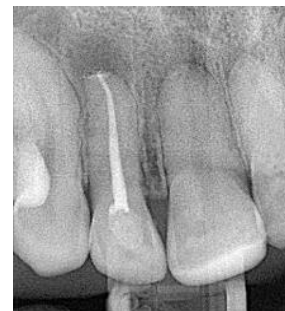

Figure 3. Root canal filling radiography.

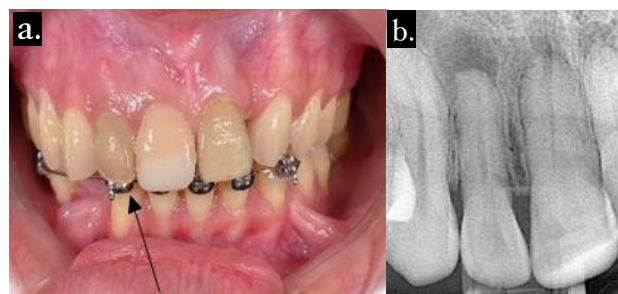


Figure 1. a. Initial clinical appearance, b. Initial radiological appearance.

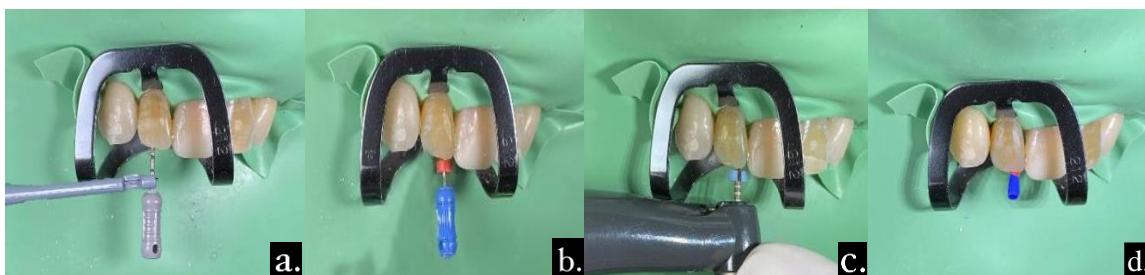


Figure 2. a. Work length measurement, b. Apical gauging, c. Preparation using Protaper Next, d. Trial gutta point.

both extraoral and intraoral examinations were performed. On extraoral examination, there were no abnormalities, while on intraoral examination, percussion (-), bite test (-) and the temporary filling were in good condition with the surrounding gingiva being normal. Subsequently, the rubber dam was installed and the temporary filling was opened. Gutta percha was collected 2 mm below the CEJ can be seen in Figure 4b, and radiographs were taken

for confirmation. Afterwards, as shown in Figure 4c, the GIC barrier was applied with ski slope formation from the proximal direction and bobsled tunnel from the labial direction until the radiographic confirmation. Application of internal bleaching agent by using 35% hydrogen peroxide can be seen in Figure 4d. Hydrogen peroxide 35% was used for the application of internal bleaching agent. This was followed by temporary filling with GIC. The patient

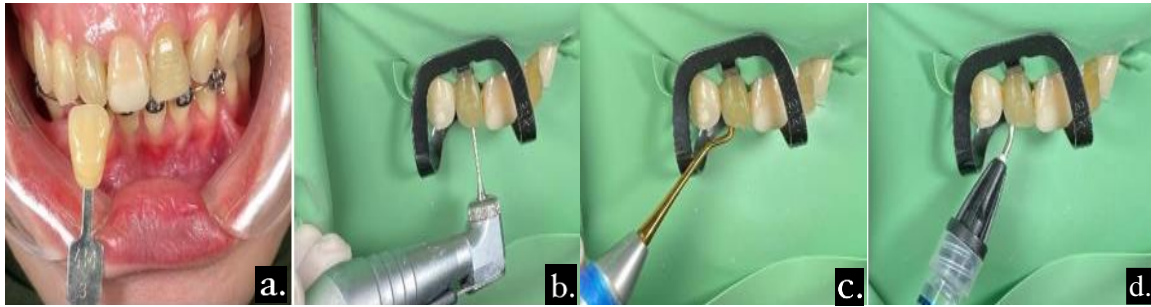

Figure 4. a. Initial shade guide measurement, b. Gutta point reduction, c. GIC application, d. Bleaching material application.

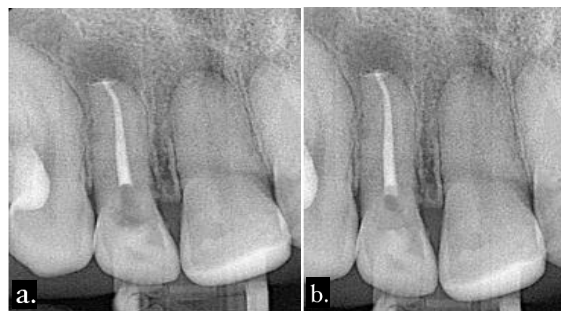


Figure 5. a. Filling reduction radiograph, b. Root canal GIC Barrier radiograph.

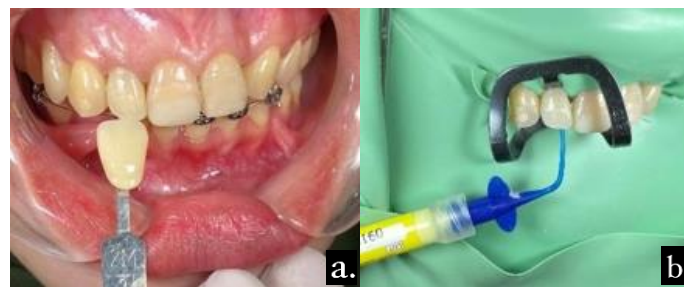

Figure 6. a. Final shade guide measurement, b. Ca(OH)₂ application.

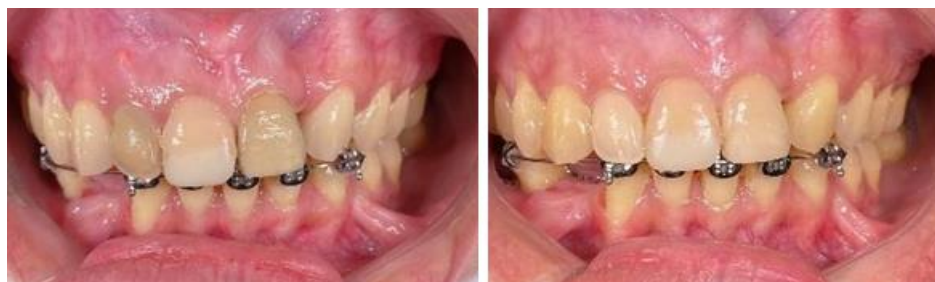

Figure 7. Before and after treatment.

was instructed to check the tooth color change daily and to report via Teledentistry. Filling reduction radiograph can be seen in Figure 5a, meanwhile root canal GIC barrier radiograph in Figure 5b.

On the third visit, the patient rinsed her mouth with 1% povidone iodine solution for 30 seconds. The control was performed, with the extraoral (-) and intraoral (-) examinations, bite test (-), and the condition of the filling was good and the surrounding gingiva was normal. As shown in Figure 6a, the tooth color was checked using the Vita 3D master shade guide (2M3) and the color was in accordance with the patient's preference and was harmonious with the adjacent teeth. Afterwards, a rubber dam was placed and the GIC filling was opened. Cavities were irrigated to remove the remaining bleaching material then dried. Calcium hydroxide material was applied can be seen in Figure 6b, and then closed temporarily.

On the fourth visit, the patient underwent intraoral and extraoral examination. Extraoral examination (-) and intraoral examination (-), there was no discoloration, the color of the tooth seemed harmonious with the adjacent teeth, the temporary filling was in good condition, the surrounding gingiva was normal. Rubber dam was placed and temporary filling was removed. Phosphoric acid 37% etching application on palatal cavities, rinse and dry. Bonding application then light curing. The composite filling was performed with incremental technique and then light curing. Afterwards, occlusion and articulation checking can be done. Finishing and polishing as well as instructions are given to the patient to maintain OH and avoid food and drinks that can cause tooth discoloration. On the fifth visit, an extraoral examination (-) and intraoral examination (-) were performed, the filling was in good condition, the tooth color remained unchanged, and the marginal fit was good. Before and after treatment photos can be seen in Figure 7.

DISCUSSION

Bacterial infection of the root canal causes an inflammatory response that results in lesions in apical periodontitis. Periapical radiolucency is common in these lesions. Inflammatory reaction at the apex of the tooth causes the formation of periapical lesions on non-vital teeth. After necrosis of the pulp, the root canal system becomes a breeding ground for microorganisms. Due to the physiological pathological correlation between the pulp and the periapex, the cellular, bacterial, and fungal components promote the periapical tissue inflammation process. Therefore, root canal treatment should be performed.⁵

A thorough examination prior to endo and bleaching procedures should include anamnesis and clinical examination, from dental and medical history, family history, systemic or genetic disorders, medications that have been or are currently being administered. Hereafter, a treatment plan could be prepared by considering expectations. From this case, endodontic treatment is the initial treatment prior

to internal bleaching. Root canal treatment with One Visit Treatment defined as conservative and non-surgical root treatment that includes complete biomechanical preparation and root canal filling in one visit.³

Indications for one visit endodontic treatment are in cases of open pulp due to iatrogenic trauma without periapical lesions, irreversible pulpitis without periapical lesions, tooth necrosis without clinical symptoms and periapical lesions, tooth necrosis with periapical abscess with fistula, teeth with normal root canal shape, single or multiple root canals, patients requiring complete oral rehabilitation, patients with physical limitations who are unable to visit the dentist frequently, patients requiring sedation, anterior teeth or bicuspid fractures, and intentional root canal treatment. Contraindications to one-time root canal treatment are pain in tooth necrosis without a fistula for drainage, severe anatomical abnormalities, teeth with anatomical abnormalities such as classification and curved root canals, acute periodontitis with severe pain on percussion, patients with TMJ disorders, or when patients are unable to open their mouths for a long time and are limited to opening their mouths and in most cases re-treatment.³

The purpose of one visit root canal treatment is to complete treatment in the shortest possible time without compromising the quality of treatment. The advantages of one visit endodontic treatment include minimizing the risk of microorganism contamination of the root canal, more efficient because the operator does not need to explain the treatment, and avoiding patients who sometimes do not complete endodontic treatment. The operator may perform access preparation, root canal negotiation, preparation and filling at the same time to reduce potential errors or root canal finding difficulties compared to multiple visits for root canal treatment. Therefore, no intracanal medication is required, and anesthesia is only administered once, thus reducing the patient's fear and anxiety. Therefore, the tooth can be restored immediately, so the risk of fracture and pain during treatment can be reduced, the costs are more economical, and prosthetic work can be initiated immediately.³

In this case, discoloration of the teeth occurred. Discoloration itself can be divided into intrinsic and extrinsic discoloration or a combination of both. Extrinsic discoloration occurs on the external surface of the teeth and can be easily removed with abrasive pastes, polishing and scaling.⁴ In this case, it was found that there were intrinsic factors due to intrapulpal hemorrhage and decomposition of pulp tissue, blood product fragments and bacteria. Trauma to the tooth structure causes the pulp chamber capillaries to rupture and bleed. The blood components that fill the pulp chamber then enter the dentinal tubules through a diffusion process, and then the blood cells undergo a hemolysis process to release hemoglobin. Then, the iron component is released due to hemoglobin degradation. The iron component will combine with bacterial products, namely Hydrogen Sulfide and produce black ferric sulphate compounds. The compound then penetrates the dentinal tubules and causes discoloration of the tooth crown.⁶

In this case, bleaching was preferred as the labial tooth structure was still intact and restorable with a recomposite. Full crown restoration was avoided as it would have removed the remaining tooth structure and required more cost. Bleaching is a treatment that uses a strong oxidizing agent, namely Hydrogen Peroxide. In dentistry, there are two methods of bleaching, which are external bleaching of non-vital teeth and internal bleaching of non-vital teeth. Hydrogen Peroxide is a whitening agent used by dentists (office whitening) with a concentration of 30-35% or without doctor supervision (home bleaching) with a concentration of 10-15%. The use of hydrogen peroxide has become a better preference compared to the use of Carbamide Peroxide or Sodium Perborate because of faster penetration.⁷

The mechanism of teeth whitening is the oxidation reaction of peroxide. Hydrogen Peroxide is characterized by a low molecular weight, allowing it to penetrate enamel and dentin. Hydrogen peroxide is an oxidizing agent with free radicals that lack paired electrons, which subsequently bind to the enamel and cause the oxidation reaction process. Bleaching agents are oxidizers that react to the organic structure of the hard tissues of the teeth, the long-chain pigments slowly break down into simple molecules such as carbon dioxide, oxygen and water, which are lighter in color, inorganic molecules that do not break down. In the bleaching process, the term redox reaction refers to the reduction-oxidation reaction. In general, unstable peroxides later become unstable free radicals. These free radicals react with unstable bonds and induce electron conjugation and energy absorption changes in dentin and tooth enamel structures. By adding oxygen, the tooth molecules alter the chemical structure and will result in the shrinking of the enamel molecules thus resulting in the use of bleaching agents to make the teeth appear shinier.⁸

Bleaching of teeth that have undergone root canal treatment has shown favorable success rates, especially for teeth with blackening or light-yellow discoloration. Further tooth discoloration can be effectively treated with glass ionomer cement and composite restorations. Restoration materials can be utilized in cases of intrinsic discoloration. Post internal bleaching there are numerous options, one of which is indirect restoration, such as crowns and veneers. In addition, the aim is to use invasive techniques. Composite resin can be applied using a layering technique, which is a

simple and conservative approach that minimizes damage to tooth structure.⁹

The study can conclude that the success of One Visit Endodontic treatment corresponds with a thorough diagnosis, correct case selection, operator skills, and treatment facilities. One Visit Endodontic is also one of the options for non-vital teeth treatment. Furthermore, internal bleaching with Walking Bleach Technique can be an option to treat non-vital teeth after endodontic discoloration.

REFERENCES

1. Kartinawanti AT, Asy'ari AK. Penyakit pulpa dan perawatan saluran akar satu kali kunjungan: literature review. *Jurnal Ilmu Kedokteran Gigi*. 2021 Dec; 4(2): 64–70.
2. Rosidah NA, Erlita I, Ichrom MY. Perbandingan efektivitas jus buah apel (*malus sylvestris mill*) sebagai pemutih gigi alami eksternal berdasarkan varietas. *Dentin Jurnal Kedokteran Gigi*. 2017 Apr; 1(1): 1–5.
3. Hutami OS, Muryani A. Perawatan saluran akar (PSA) satu kali kunjungan pada gigi molar pertama bawah kanan dengan restorasi endocrown resin komposit. *Jurnal Kedokteran Gigi Universitas Padjadjaran*. 2020 Nov; 32(1): 54-6.
4. Chaya M, Hidayat OT. Penatalaksanaan diskolorisasi gigi pasca perawatan endodontik dengan teknik walking bleach. *Jurnal Kedokteran Gigi Universitas Padjadjaran*. 2021 Feb; 32(2): 98-104.
5. Aryanto M. Perawatan saluran akar non bedah pada gigi anterior dengan lesi periapikal yang meluas (laporan kasus). *Jurnal Ilmiah dan Teknologi Kedokteran Gigi*. 2018 May; 14(1): 16-19.
6. Mona D. Perawatan internal bleaching pada insisivus sentral kiri atas pasca perawatan endodontic pada pasien dengan riwayat trauma (laporan kasus). *Jurnal B-Dent*. 2016 Jun; 3(1): 68-74.
7. Al-Habsyi SN, Kun I, Samporno G. The role of epigallocatechin-3-gallate as an antioxidant after dental bleaching on shear bond strength of composite resin restoration. *Conservative Dentistry Journal*. 2021; 11(1): 42-45.
8. Soesilo D. Perawatan internal bleaching untuk estetik gigi pasca perawatan endodontik. *Denta Jurnal Kedokteran Gigi*. 2016; 10(2).
9. Salicha RP, Ismiyatin K, Sari PT, Widjaja OV, Puspita, Sari RP. Internal bleaching of a non vital anterior tooth in patient with postural hypotension. *Dentika Dental Journal*. 2020; 23(2): 45-50.