

## Case Report

## Management open apex with bioceramic root repair material: A case report of permanent anterior teeth

Setyabudi<sup>1</sup>, Yeyen Yohana<sup>2</sup>

<sup>1</sup>Department of Conservative Dentistry, Faculty of Dental Medicine, Airlangga University, Surabaya, Indonesia

<sup>2</sup>Resident of Conservative Dentistry Specialist Program, Faculty of Dental Medicine, Airlangga University, Surabaya, Indonesia

### ABSTRACT

**Background:** Trauma to immature teeth can cause disrupt of the blood vessel supply in the pulp which leads to pulp necrosis. This can then, indirectly disrupts of root formation and incomplete apex closure. Young permanent teeth with wide open apex to be a challenge for root canal treatment, especially during obturation. Apexification is a treatment option for open apex with necrotic pulp. **Purpose:** The purpose is to create an apical stop at the apical third of the apex so that obturation can be achieved. **Case:** A 27-year-old man came to Airlangga University Dental Hospital with chief complaints that his upper front teeth were fracture and discolored and the pain had disappeared since march 2023. From the clinical examination, tooth 21 showed Ellis fracture class III and there was tooth discoloration. Pulp vitality examination with cavity test and unresponsive k-file test, percussion (+) and bite test (+). Radiographic examination show an exposed pulp and exposed apex of tooth 21 accompanied by an unclearly defined radiolucent image at the apex of tooth 21. The diagnosis of this tooth was pulp necrosis with symptomatic apical periodontitis. **Case Management:** Apexification use bioceramic root repair material as apical plug at the apex. After that, obturation is achieved using a thermoplastic technique. Final restoration with individual customized post and lithium disilicate crown. **Conclusion:** Apexification is an option in cases of pulp necrosis with an open apex using bioceramic root repair material. Bioceramic root repair material is a bioactive material, that induces osteogenesis, is easier to apply, has faster setting time, biocompatible, hydrophilic, high pH and has anti-microbial properties.

**Keywords:** Apexification, open apex, bioceramic root repair material

Correspondence: Setyabudi, Department of Conservative Dentistry, Faculty of Dental Medicine, Airlangga University. Jl. Prof. Dr. Moestopo No 47 Surabaya, 60132 Indonesia. Email: setyabudi@fkg.unair.ac.id

### INTRODUCTION

Root canal treatment is a procedure that involves removing all necrotic pulp tissue, form a tooth root canal to prevent recurrent infections.<sup>1</sup> One of the important aspect in root canal treatment is root canal obturation, this leads to proper apical seal with a “fluid-tight” obturation which prevents bacterial ingress and ensures favorable outcome.<sup>2</sup> However, achieving a proper apical seal becomes difficult in patients with open apex. Obturation becomes a challenge due to the large open apex, diverging walls, thin dentinal walls that are susceptible to fracture, and associated frequent periapical lesion.<sup>3</sup> The most common teeth with open apex are maxillary anterior. This is due to its position in the jaw which is more prone to trauma and less due to caries.<sup>3</sup>

Trauma to immature teeth can in disrupt of the blood vessel supply in the pulp which causes pulp necrosis which indirectly causes disruption of root formation and incomplete apex closure.<sup>4,5</sup> Apexification is a treatment

option for immature necrotic permanent teeth with open apex. This will induce the development of apex closure, but not root canal wall thickening.<sup>6,7</sup> Apexification is defined as a method to induce a calcific barrier across an open apex of an immature, pulpless tooth. Apexification was done in three steps: canal debridement, forming an apical plug, and obturation.<sup>2</sup>

In apexification treatment, the apical barrier is formed using materials, which one is bioceramic root repair material. The aim of placing an apical barrier is to create an apical stop at the open apical third so that obturation can be achieved.<sup>9,10</sup> This case report describes the apexification of an immature, necrotic tooth using bioceramic root repair material (BC-RRM).

### CASE

A 27-year-old male patient came to Airlangga University Dental Hospital with a chief complaint that his upper

front teeth were fracture and discolored and the pain had disappeared since march 2023. From the anamnesis, it was discovered that the patient had a history of trauma 9 years ago. The patient wants his teeth treated.

From the clinical examination, tooth 21 showed a class III Ellis fracture and there was tooth discoloration (Figure 1A). Pulp vitality examination with cavity test and unresponsive k-file test, percussion (+) and bite test (+). Radiographic examination revealed an exposed pulp and immature wide open apex tooth 21 accompanied by a radiolucent image with unclear boundaries (Figure 1B). Based on subjective, objective and supporting examinations, the diagnosis of tooth 21 was pulp necrosis with symptomatic apical periodontitis. The treatment plan in this case is apexification with Bioceramic Root Repair Material (BC-RRM) and individual customized post and lithium disilicate crown as the final restoration.

### CASE MANAGEMENT

At the first visit, subjective, objective and supporting radiographic examinations are carried out to confirm the diagnosis, then KIE and DHE are given to the patient. Inform to consent and informed consent is provided. Following rubberdam placement, access opening was done on tooth 21 with endo access bur, working length was determined with an apex locator (Figure 2A) and confirmed with periapical radiography that the working length to be 23 mm (Figure 2B). Apical gauging obtained a tugback with K-file #100 and root canal debridement was carried out using a circumferential filling motion technique according to the working length. Next, sequence irrigation using a side vented irrigation needle 30G NaOCl 2.5%, rinse with aquadest, EDTA 17% (on the coronal 2/3) then rinse with distilled water, irrigate with aquadesr on the apical 1/3,

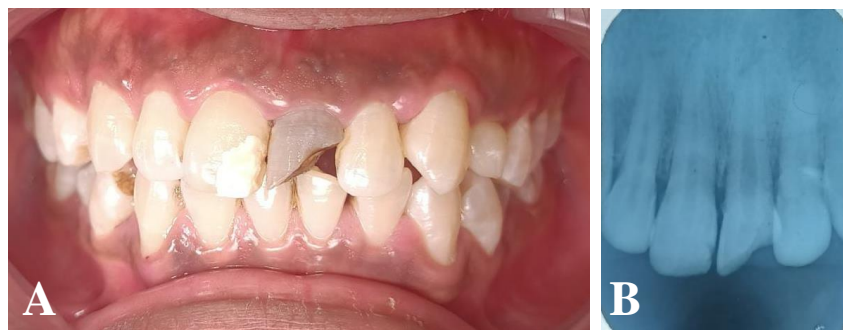

Figure 1. Pre-operative (A), and pre-operative radiograph (B).

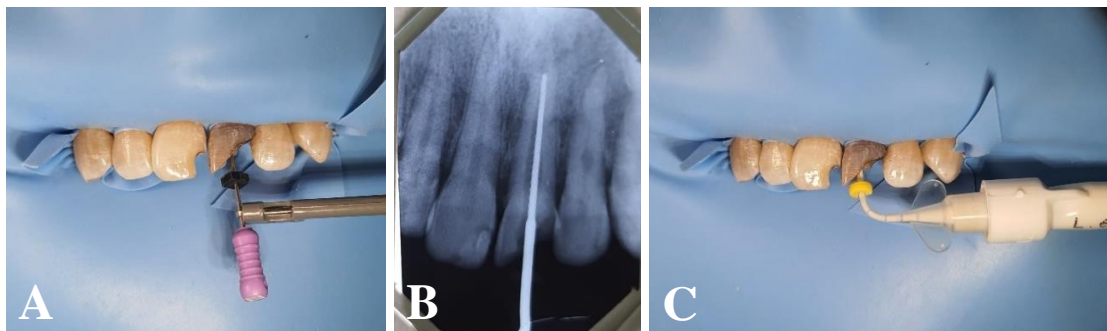


Figure 2. Working length with apex locator (A), diagnostic wire photo (B), and bioceramic dressing application (C).

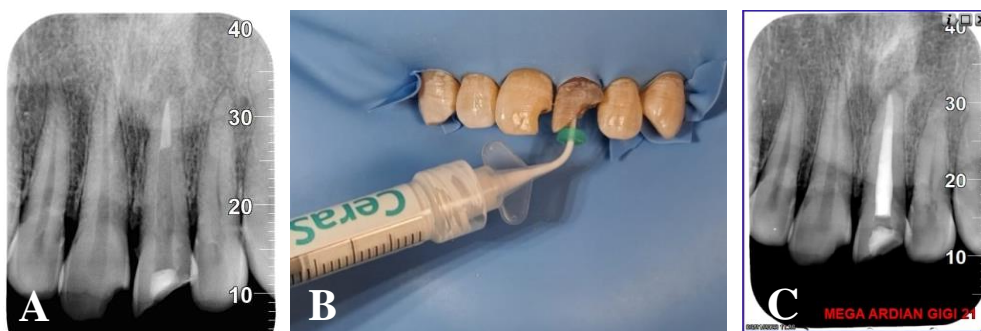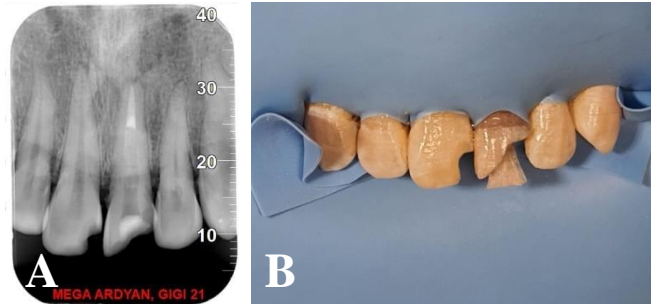


Figure 3. Apical plug is formed (A), bioceramic sealer application (B), and obturation confirmation (C).

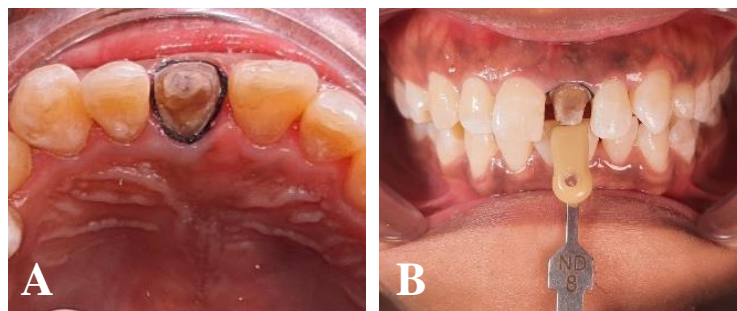
dry with an endo suction tip and paper point. Next, the root canal is dressed with a bioceramic dressing (Figure 2C) and then the cavity was sealed with a cotton pellet and temporary filling.

At the second visit, the patient returned after 2 weeks. Results of subjective and objective examination, showed

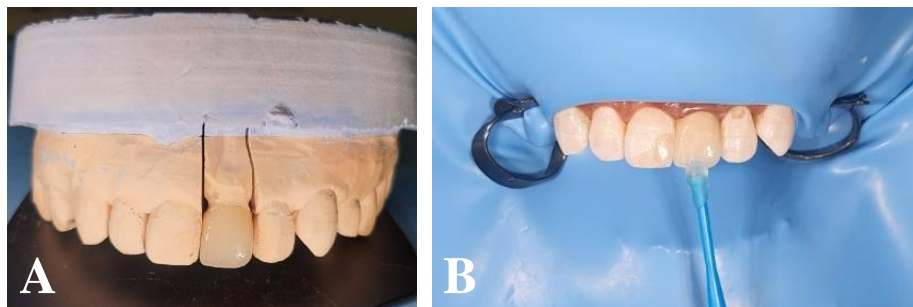
no complaints on tooth 21. The working area was isolated with rubber dam. The temporary filling was removed and the final irrigation was done with NaOCl 2.5%, aquadest, and EDTA 17%. The root canal was then dried with sterile paper points. BC-RRM application into the root canal 4mm long in the apical third and condensed with a plugger that has



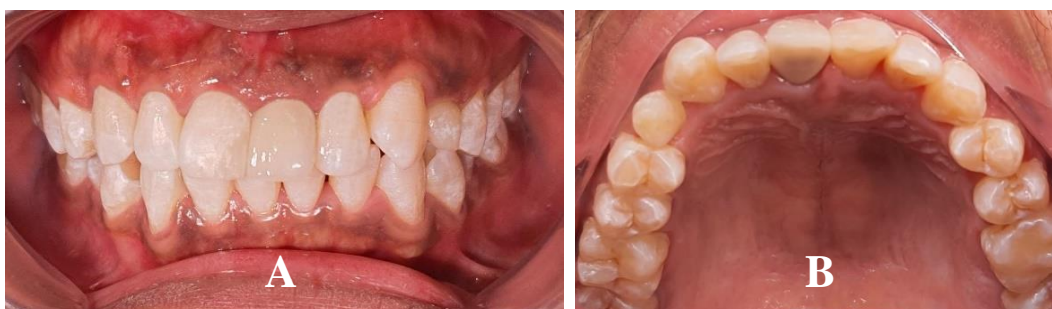**Figure 4.** Gutta percha reduction (A) and insertion post (B).



**Figure 5.** Gingival management (A) and taking shade guide discoloration color (B).



**Figure 6.** Crown lithium disilicate on the model (A) and crown insertion (B).



**Figure 7.** Post-operative (labial) (A) and post-operative (palatal) (B)..

a stopper. The access cavity was sealed, and this confirmed by periapical radiography after BC-RRM application (Figure 3A). Patients were instructed to return for follow up in one week.

At the third visit, after 1 week, subjective and objective examinations showed no complaints on tooth 21. The working area was with rubber dam. The temporary filling was removed and the preparation for obturation using thermoplastized techniques. The root canals were irrigated with aquadest and dried with paper points. Bioceramic sealer was applied and root canal obturation was done using thermoplastized and vertical condensation (Figure 3B). The cavity was sealed and the root canal obturation was confirmed (Figure 3C).

At the fourth visit, subjective and objective examination showed no complaints on tooth 21. Following rubber dam placement, the temporary filling was removed and the length the post was determined. Reduce the guttup with a peeso reamer and confirming with radiograph (Figure 4A). Then, try installing it with an individual customized everstick post adjusted to the root canal and cemented it then core built up (Figure 4B). The shade guide was then used to determine the color, which was 3R1.5 and the crown of tooth 21 was prepared with a chamfer. Then gingival management (Figure 5A). After the preparation was complete, taking shade guide the discoloration color using ND shade to obtain ND-8 (Figure 5B), molding and insertion a temporary crown. Lab instructions and crown insertion were completed 1 week later (Figure 6A and 6B). The patient felt satisfied and had no complaints of pain at the follow-up (Figure 7A and 7B).

On the fifth visit to follow up after one month, subjective and objective examination showed no complaints on tooth 21. The extraoral examination revealed no abnormalities. The intraoral examination showed that the crown is in good condition.

## DISCUSSION

A history of trauma to immature teeth is one of the causes of stopping root formation, resulting the apex is incompletely closed. Open apex is a normal condition in young permanent teeth. However, if the pulp becomes necrotic before root growth is complete, dentin formation stops and root development stops.<sup>11</sup>

In this case, the patient had a history of dental trauma 9 years ago, when the patient was 18 years old. The trauma caused the tooth to fracture and the pulp to be exposed accompanied by discoloration of tooth 21. The radiograph shows that the apical foramen is open and incompletely closed and there is a radiolucent area at the apex. The diagnosis of tooth 21 was pulp necrosis with symptomatic apical periodontitis. Trauma experienced, stopped root development resulting in wide apical constriction. Wide apical constriction will make obturation difficult and can reduce the success rate of root canal treatment, as it provides a pathway that connects the periapical tissue with the root

canal, allowing bacteria to grow and infect the periapical area. With apexification treatment, the result is closure of the apex with the formation of an apical barrier that prevents extrusion of gutta-percha material from the apex.<sup>2</sup> This also prevents the passage of bacteria and toxins into the periradicular area of the root canal.<sup>2</sup>

Indications of apexification are young permanent teeth with blunderbuss canal and necrotic pulp, as well as long standing fractures of the crown involving pulp and teeth can be restored.<sup>12</sup> Contraindications of apexification include very short roots which requires increasing root length and wall thickness, replacement resorption ; horizontal and vertical root fractures.<sup>2,12</sup> According to Nitest *et al.*, apexification has the advantages that the treatment can be finished more quickly compared to revascularization, and it can induce root closure in necrotic immature permanent teeth.

Apexification in this case used bioceramic root repair material (BC-RRM). Chemically, BCRRM consists of zirconium oxide, calcium silicate, tantalum oxide, calcium phosphate, and filler.<sup>13</sup> Bioceramic root repair material is a bioactive material, that induces osteogenesis, is easier to apply, has faster setting time, biocompatible, hydrophilic, High pH, anti-microbial properties.<sup>13,14</sup>

Obturation technique uses a thermoplastic technique with bioceramic sealer. The advantage of the thermoplastic technique is that the gutta percha can adapt to the canal walls because it has the ability, resulting in a dense and hermetic obturation.<sup>15,16</sup> The choice of bioceramic sealer has the advantages of being biocompatible, good seal. The bioceramic material contains calcium phosphate which improves the binding properties of the bioceramic and produces a chemical composition. and a crystalline structure similar to dental and bone apatite materials, thereby improving the bond of the dentin sealer to the root.<sup>17,18</sup>

In this case, there was discoloration of tooth 21 but internal bleaching was not carried out because the tooth was more than half fractured, requiring intracoronary retention with a post and crown. The selection of posts using individual customized posts, namely EverStick, has the advantage of being minimally invasive and can maintain root canal anatomy so that reducing the risk of root fracture.<sup>19</sup> In conclusion, apexification is an option in cases of pulp necrosis with an open apex using bioceramic root repair material. Bioceramic root repair material is a bioactive material, that induces osteogenesis, is easier to apply, has faster setting time, biocompatible, hydrophilic, high pH and has anti-microbial properties.

## REFERENCES

1. Garg, N. and Garg, A. Textbook of Endodontics. 4th ed. New Delhi: Jaypee Brother Medical Publisher. 2019.
2. Nitesh Patil, Ashish Jain, Deepak Hegde, Amit Patil. Management of teeth with blunderbuss canals and its esthetic rehabilitation. Int J Med Dent Case Rep. 2020; 1-5.
3. Jain JK, Ajagannavar SL, Jayasheel A, Bali PK, Jain CJ. Management of a fractured nonvital tooth with open apex

- using mineral trioxide aggregate as an apical plug. *Int J Oral Health Sci.* 2017; 7: 44-7.
4. Andreasen FM, Kahler. Diagnosis of acute dental trauma: the importance of standardized documentation: a review. *J-Dent Traumatol.* 2015; 31: 340-9.
  5. Yu CY, Abbot. Responses of the pulp, periradicular and soft tissues following trauma to the permanent teeth. *Aus Dent J.* 2016; 61:39-58.
  6. Dylewski J. Apical closure of non-vital teeth. *Oral Surgery, Oral Medicine.* 1971 ;32:82-9.
  7. Finucane D, Kinirons MJ. Non-vital immature permanent incisors: factors that may influence treatment outcome. *Endod Dent Traumatol.*1999; 15: 273–7.
  8. Trope M. Treatment of immature teeth with non vital pulps and apical periodontitis. *Endotopic.* 2007;14-51-59
  9. Grossman, L. I., Chandra, B. S., Gopikrishna, V. *Grossman’s Endodontic Practice* 13th ed. India: Wolters Kluwer Health. 2014.
  10. Khanduri N, Kurup D. Single Visit apexification with biodentine and platelet rich fibrin. *Endodontology.* 2018; 30: 181-3
  11. Andreasen JO, Farik B, Munksgaard EC. Long-term calcium hydroxide as a root canal dressing may increase risk of root fracture. *Dent Traumatol.* 2002; 18: 134–7.
  12. Garg, N. dan Garg, A. *Textbook of Operative Dentistry.* 2nd ed. New Delhi: Jaypee Brother Medical Publisher. 2013.
  13. Swapnika G, Kalyan Satish, Santosh Kumar. Bioceramic Perforation Repair Materials. *Int J Med Sci Clin Invent.* 2022; 2(6); 528-33
  14. Shokouhinejad N, Nekoofar MH, Razmi H, Sajadi S, Davies TE, Saghiri MA, Gorjestani H, Dummer PM. Bioactivity of EndoSequence root repair material and bioaggregate. *Int Endod J.* 2012; 45: 1127-34.
  15. Vianna, Kauhanna., Flávia Sens Fagundes., Beatriz Serrato. Thermoplastic endodontic obturation – TC system: case report. *RSBO.* 2016 ;13(1): 46-9.
  16. Swadhin Raghuwanshi, Pradeep Jain, Pallav Mahesh Patni, Dentinal Adaptation of Warm Thermoplastic Obturating Material and Cold Thermoplastic Obturating Material: An In vitro Study. *Contemp Clin Dent* 2019; 10: 64-8.
  17. M. P. Ginebra, E. Fernandez, E. A. P. De Maeyer et al., Setting reaction and hardening of an apatitic calcium phosphate cement. *J Dent Res.* 1997; 76(4): 905–12.
  18. Afaf AL-Haddad and Zeti A. Che Ab Aziz. Bioceramic-Based Root Canal Sealers: A Review. *Int J Biomaterials.* 2016; 1-10.
  19. Priyali Chauhan, Anjali Miglani, Panna Mangat and Anil K Tomer. A comparative evaluation of fractured resistance of custom made Post and everStickPOST system in endodontically treated teeth- An in vitro study. *Int J Appl Dent Sci.* 2017; 3(1): 78-80