

Case Report

Esthetic crown lengthening treatment on the maxillary anterior teeth

Dian Agustin Wahjuningrum¹, Galih Sampoerno¹, Eric Priyo Prasetyo¹, Widya Saraswati¹, Setyabudi^{1*}, Pravinna Saravanan², Tiara Lathifah Riyadi², Venny Lusanda Ambarwati³

¹Departement of Conservative Dentistry, Faculty of Dental Medicine, Universitas Airlangga, Surabaya, Indonesia

²Undergraduate Program, Faculty of Dental Medicine, Universitas Airlangga, Surabaya, Indonesia

³Conservative Dentistry Specialist Program, Faculty of Dental Medicine, Universitas Airlangga, Surabaya, Indonesia

ABSTRACT

Background: Asymmetrical smile design due to uneven gingival margin heights of the anterior upper teeth can lead to aesthetic issues and inadequate crown restorations, necessitating crown lengthening treatment. **Purpose:** The objective of this case report is to demonstrate the outcomes of crown lengthening to achieve improved aesthetics and symmetric gingival margin heights. **Case:** A 16-year-old female patient sought treatment for decayed left maxillary anterior teeth. Clinical examination revealed a non-vital tooth (tooth 21) with decay and excessively low gingival margins, along with asymmetrical gingival heights between the incisors and canines. Radiographs indicated radiolucent mass in the pulp chamber. **Case Management:** Crown lengthening was performed on teeth 12, 11, 21, and 22, and apexification was conducted on tooth 21 using a customized fiber post and lithium disilicate crown. Follow-up evaluations showed no complaints, well-maintained crowns, and healthy gingiva. **Conclusion:** Crown lengthening is feasible for anterior teeth with low gingival margins, enhancing clinical crown length to support aesthetic and final restorations in maxillary anterior teeth.

Keywords: crown lengthening, esthetic, margin gingival height, anterior teeth

Correspondence: Setyabudi, Departement of Conservative Dentistry, Faculty of Dental Medicine, Universitas Airlangga, Jl. Mayjen Prof. Dr. Moestopo No.47 Surabaya, 60132, Indonesia. Email: setyabudi@fkg.unair.ac.id

INTRODUCTION

The asymmetrical smile appearance resulting from uneven gingival margins in the anterior teeth poses aesthetic challenges and compromises the adequacy of crown restorations, necessitating crown lengthening treatment. This surgical procedure aims to increase the visible part of the tooth (clinical crown) for aesthetic enhancement, restorative purposes, or both. Crown lengthening is considered when there is insufficient tooth structure or access for restorative procedures, typically due to conditions like subgingival or extensive caries leading to short teeth, fractures, or short clinical crowns because of inadequate exposure of the tooth's natural crown shape.¹

Various conditions such as dental caries, tooth misalignment, cracks, eruption irregularities, exostosis, and genetic variations can result in shortened clinical crowns, often with a cervico-incisal distance less than 2 mm, which complicates the retention of restorations. A crucial aspect of successful root canal treatment is the final restoration, which aims to restore both function and aesthetic appearance while safeguarding the remaining tooth structure.²

A significant challenge in achieving optimal restoration outcomes lies in addressing the insufficient clinical crown

length to establish stability in the dentogingival complex, ensuring proper placement of restoration margins and achieving pleasing aesthetic results.³ Techniques to increase clinical crown length may involve procedures such as gingivectomy and apically repositioned flap surgery, with or without osteotomy. Crown lengthening procedures are planned with consideration of biological factors, including the distance between the alveolar crest and the free gingival margin, as well as anatomical factors such as crown-root length and proportion.⁴

CASE

A 16-year-old female patient visited the Airlangga University Dental Hospital, complaining about a cavity in tooth #21 and feeling self-conscious about the short appearance of her upper front teeth. The cavity had been present for several years and had previously been filled, but the filling had become dislodged. She experienced recent pain which has since subsided.

Upon examination, the extraoral findings were normal. Intraorally, deep decay was noted on the mesial surface of tooth #21. Tests for percussion and bite were negative,

indicating no mobility or fistula. The gum line of tooth #21 was positioned higher than that of tooth #11, while tooth #11 gum line aligned with teeth #12 and #22 (Figure 1). Radiographs showed radiolucent areas in the mesial crown (Figure 2). The diagnosis for tooth #21 was pulp necrosis with a chronic apical abscess. The treatment plan involves apexification using Mineral Trioxide Aggregate (MTA) to create an apical barrier, and crown lengthening to achieve symmetry gingival heights and ideal restoration margins. Gutta percha filling using heat-softened techniques will precede the final step of restoring the tooth with custom-fit fiber posts and lithium disilicate crowns.

CASE MANAGEMENT

In the first visit, anamnesis was conducted, followed by objective examination, supplementary examination, informed consent, and the patient signed the informed

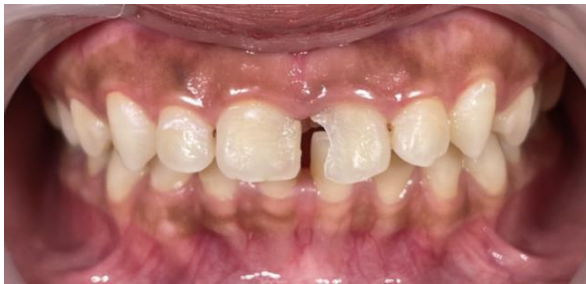

Figure 1. Initial clinical presentation (labial view).

consent form. The examination proceeded with measuring pocket depths on the labial, mesial, and distal sides: 3mm for tooth #21 and tooth #11, and 2mm for tooth #12 and tooth #22. Bone sounding measurements were also taken: 5mm for tooth #21 and tooth #11, and 4mm for tooth #12 and #22 (Figure 3).

Treatment continued with isolation of the work area using a rubber dam. Access opening was performed, followed by negotiation and determination of working length using a #10 K-file, resulting in a working length of 23 mm. Apical gauging was done using a #70 K-file. Root canals were cleaned accompanied by sequential irrigation with 2.5% NaOCl, 17% EDTA, and distilled water. Irrigation solutions were activated using ultrasonic technique. The root canals were dried using endo suction and sterile paper points. Calcium hydroxide (Ca(OH)₂) dressing was applied into the root canals, followed by temporary filling. The patient was instructed to return for a follow-up visit.

In the second visit, one week later, the subjective and objective examinations revealed no complaints regarding tooth #21. The temporary filling and Ca(OH)₂ were removed, and sequential irrigation was performed again with 2.5% NaOCl, 17% EDTA, and distilled water. The root canals were dried using endo suction and sterile paper points. MTA was prepared according to manufacturer's instructions. MTA filling was performed along 3mm of the apical 1/3 using an MTA carrier and condensed with a plugger. Confirmation radiographs were taken to verify the MTA filling. Moist cotton pellets were applied to the cavity and the cavity was temporarily filled. The patient was instructed to return for further follow-up.

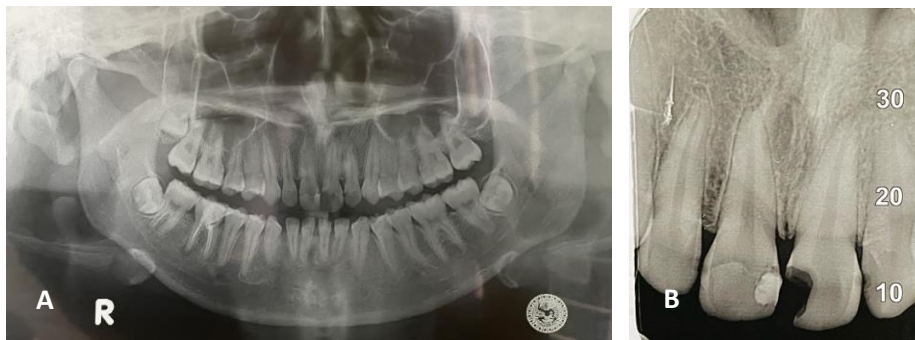


Figure 2. Radiographic images, A. panoramic view, B. periapical view.

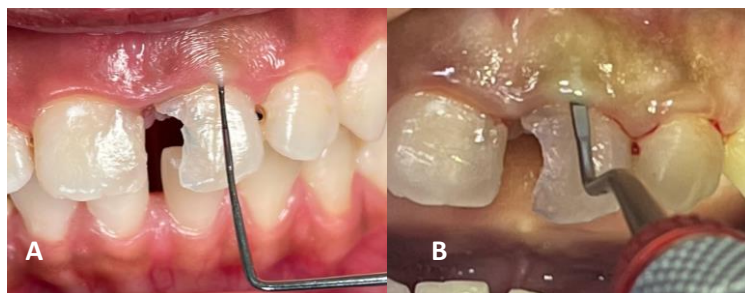

Figure 3. A. Probing examination, B. Bone sounding examination.

In the third visit, one week after the second visit, both subjective and objective examinations revealed no issues with tooth #21. The temporary filling was removed, and the root canal was filled using the thermoplastic technique (back fill). Radiographs confirmed a complete seal. The cavity was sealed with cotton pellets and temporarily restored. The patient was scheduled to return in one week.

In the fourth visit, the tooth shade was selected using the Vita 3D shade guide (resulting in shade 2M2). The temporary filling was removed, and the gutta-percha was trimmed to 16 mm using a peeso reamer. A fiber post was trial-fitted and confirmed with radiographs. The tooth was acid-etched with 37% phosphoric acid for 20 seconds, rinsed, and dried. Bonding agent was applied to the root canal and cured with light. The post was inserted, and a core buildup was created using a dual-cure composite core material, followed by light curing.

In the fifth visit, on anamnesis the patient reported no issues, with good general health and blood pressure of 102/78 mmHg. Crown lengthening was performed on teeth #12, #11, #21, and #22. Aseptic procedures were followed with local anesthesia administered. Bleeding points were marked using a pocket marker. Gingival tissue was then contoured using a no. 15 C blade along the marked gingival margins. Gingival tissue shaping was done using curettes and gingival knives (Orban and Kirkland). Saline irrigation was performed, and the outcome of the crown lengthening procedure was evaluated. A periodontal pack was applied, and post-surgical instructions were given along with analgesics. The step by step procedure is shown in Figure 4.

In the sixth visit, upon follow up, the patient reported no complaints. The gingiva appeared healthy without signs of hyperemia or swellings (Figure 5). Subsequently, the crown restoration process was initiated.

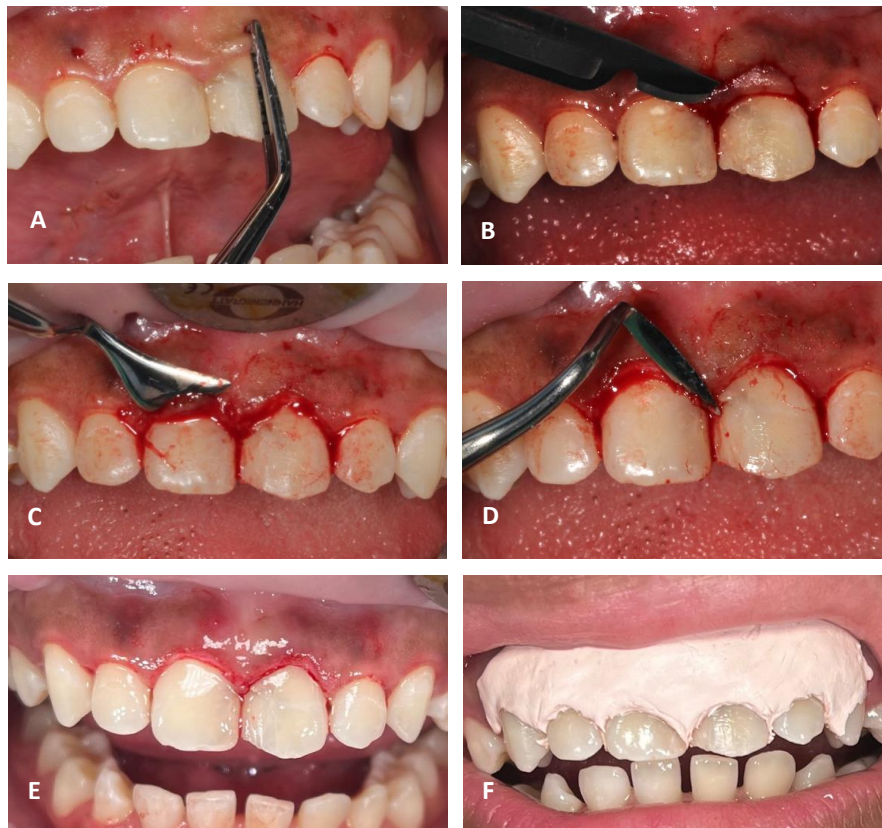


Figure 4. A. Marking bleeding points with a pocket marker, B. gingival trimming, C. gingival contouring with Kirkland knife, D. Orban knife, E. final outcome of crown lengthening, F. placement of periodontal pack.

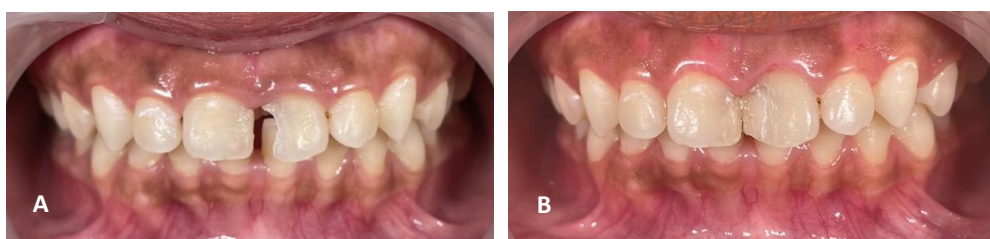

Figure 5. Clinical photos: A. before treatment and B. after treatment.

DISCUSSION

In this case, there was observed asymmetry in the heights of the gingival margins between the central incisor and the canine. The gingival heights of tooth #11 were similar to tooth #12, while tooth #21 was positioned higher than tooth #22. Moreover, tooth #21 presented deep caries necessitating apexification and root canal treatment. Given these findings, crown lengthening was deemed necessary to achieve an optimal clinical condition that would ensure satisfactory aesthetic and functional outcomes.

Crown lengthening aims to increase the length of the visible part of the tooth, known as the clinical crown, extending from the gingiva line to the chewing surface. It serves two primary purposes: functional and aesthetic. Functional crown lengthening is performed to create a proper foundation for restorations, access cavities below the gum line, and correct issues with the biological width. Meanwhile, aesthetic crown lengthening is aimed at improving the appearance of anterior teeth, addressing concerns like a gummy smile and correcting irregularities in gingiva margin height.⁵

The objective of crown lengthening in this case was to enhance the aesthetic appearance of the patient's smile, particularly addressing the varying lengths of the upper front teeth, which resulted in shorter clinical crowns on the left central and lateral incisors. The contour of the gingiva margin across all six upper front teeth plays a crucial role in achieving an aesthetically pleasing smile. Ensuring symmetry and proper gingiva contour are crucial for achieving an ideal smile appearance.⁶ Additionally, loss of healthy tooth structure, particularly due to extensive decay, underscores the need for functional crown lengthening to restore proper tooth structure post-endodontic treatment.⁷

There are several techniques available for performing crown lengthening, such as external or internal bevel gingivectomy and flap surgeries with or without bone removal.⁸ Gingivectomy can be carried out using various tools, including surgical blades, electrosurgery, radiosurgery, or laser treatment.⁹ In this specific case study, gingivectomy with a surgical blade was utilized. When adjusting subgingival margins or performing crown lengthening for restorative purposes, it is essential to avoid disturbing the attachment of the gum tissue or the underlying connective tissue during the preparation and impression stages. Research suggests maintaining a minimum space of 3 mm between the margin of the restoration and the underlying bone to ensure the health of the periodontal tissues, comprising 2

mm for the biological width and 1 mm for the depth of the gingiva pocket. Additionally, it is recommended to maintain at least 2 mm of keratinized gingiva tissue around teeth to promote overall gingiva health.¹⁰

In conclusion, crown lengthening using a gingivectomy procedure yields favorable aesthetic and functional outcomes, as demonstrated in this case by achieving symmetrical gingival margins. It is a suitable treatment option for anterior teeth to improve aesthetics and provide support for final restorations.

REFERENCES

1. Vidya N, Hafiyah OA. Functional Crown Lengthening as a pre-restorative procedure in the aesthetic zone. *Interdental Jurnal Kedokteran Gigi*. 2024; 20(1): 149-55.
2. Prathivi HK, Karina VM. 2022. Functional crown lengthening with osteotomy in anterior teeth as a prevention against restoration failure: A case report. *Kne Medicine The International Online Seminar Series on periodontology in conjunction with Scientific Seminar*. 2022; 2022: 223-31.
3. Pradeep K. Full mouth rehabilitation of severe fluorosis teeth with an interdisciplinary approach (6 handed dentistry). *Journal Of Clinical and Diagnostic Research*. 2013; 7(10): 2387-9.
4. Malawat A, Mitra D, Chakraborty. Crown Lengthening Procedure: An Aesthetic, Prosthetic & Restorative Solution. *International Journal of Research in Health and Allied Sciences*. 2019; 5(5): 10-15.
5. Danesh-Meyer M. Surgical crown lengthening - building a solid foundation for restorative excellence. *Australasian Dental Practice*. 2012: 58-62.
6. Primasari, VS. Crown lengthening surgery for treating asymmetric gingiva: A case report. *Kne Medicine The International Online Seminar Series on periodontology in conjunction with Scientific Seminar*. 2022; 2022: 9-14.
7. Yudistian I, Untara TE. Crown lengthening disertai perawatan saluran akar dengan restorasi pasak parallel selfthreading dan mahkota penuh fusi metal. *MKGK (Majalah Kedokteran Gigi Klinik) (Clinical Dental Journal) UGM*. 2019; 5(2): 56-61.
8. Ardakani MRT, Khalilian F, Nateghi Z, Esmailnejad A, Janbakhsh N. A review of the crown lengthening surgery: The basic concepts. *British Journal of Medicine and Medical Research*. 2016;13(3): 1-7.
9. Oliveira PS, Chiarelli F, Rodrigues JA, Shibli JA, Zizzari VL, Piattelli A, Iezzi G, Perrotti V. Aesthetic surgical crown lengthening procedure. *Case Reports in Dentistry*. 2015; 1:437412.
10. Winda DA, Martina A, Sally SK, Trimurni A. Crown Lengthening dan Frenektomi Pada Daerah Estetik (Laporan Kasus). *Cakradonya Dental Journal*. 2021; 13(2): 114-9.