

## Case Report

## Aesthetic surgical crown lengthening on teeth 11 and 21

Mardikaning Riasta Saptaningrum<sup>1</sup>, Dian Agustin Wahjuningrum<sup>2</sup>, Galih Sampoerno<sup>2</sup>, Eric Priyo Prasetyo<sup>2</sup>, Jessica Christy Handoko<sup>3</sup>, Nicole Ava Chang<sup>3</sup>, Kun Ismiyatin<sup>2</sup>

<sup>1</sup>Conservative Dentistry Specialist Program, Faculty of Dental Medicine, Universitas Airlangga, Surabaya, Indonesia

<sup>2</sup>Departement of Conservative Dentistry, Faculty of Dental Medicine, Universitas Airlangga, Surabaya, Indonesia

<sup>3</sup>Undergraduate Program, Faculty of Dental Medicine, Universitas Airlangga, Surabaya, Indonesia

## ABSTRACT

**Background:** In dental treatment planning, aesthetic considerations are crucial due to the relationship between a smile and facial beauty. Crown lengthening is a procedure used to achieve aesthetic smiles, particularly in cases of subgingival caries, fractures, and short clinical crowns. **Purpose:** The purpose of this case report is to achieve aesthetic improvement of the central incisors through crown lengthening procedures. **Case:** A 31-year-old female patient presented with a complaint of a broken upper left front tooth and easily bleeding gums. Clinical examination revealed Ellis class 1 fracture at the incisal-distal of tooth 21. The patient exhibited poor oral hygiene with visible calculus on upper and lower jaw teeth. There was gingival hyperplasia, redness, bleeding tendency, and the gingival margin height of teeth 11 and 21 appeared lower than teeth 12 and 22. Radiographically, the alveolar crest was distant from the CEJ. **Case Management:** Treatment plan included crown lengthening on teeth 11 and 21 with composite restoration on tooth 21. Crown lengthening, a surgical procedure designed to increase the extent of supragingival tooth structure for restorative or aesthetic purposes by repositioning the gingival margin apically was performed. This procedure is indicated for teeth with subgingival caries, extensive caries shortening the tooth, fractures, and short clinical crowns. **Conclusion:** Crown lengthening should consider the biological width to prevent bone resorption, gingival recession, inflammation, or hypertrophy. When performed under ideal clinical conditions, crown lengthening provides satisfactory outcomes both functionally and aesthetically.

**Keywords:** biological width, crown lengthening, aesthetics, gingival margin

Correspondence: Dian Agustin Wahjuningrum, Departement of Conservative Dentistry, Faculty of Dental Medicine, Universitas Airlangga, Jl. Mayjen Prof. Dr. Moestopo No.47 Surabaya, 60132, Indonesia, dian-agustin-w@fkg.unair.ac.id

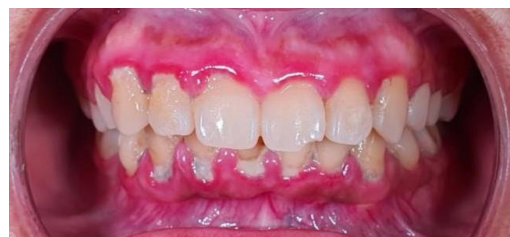## INTRODUCTION

A captivating smile can enhance a person's appearance. In dental treatment planning, aesthetic considerations are paramount due to the relationship between a smile and facial beauty. Crown lengthening procedures are typically employed to achieve an aesthetic smile. This procedure is also used to expose tooth structure when the clinical crown is inadequate for restoration placement, and to maintain the dentogingival complex in optimal condition. Crown lengthening in the anterior sector is indicated following periodontal analysis and smile design, which are critical aspects of aesthetic dentistry.<sup>1</sup>

## CASE

A 31-year-old female patient came to the Conservative Dentistry Clinic, Faculty of Dentistry, Universitas Airlangga, complaining of a fractured upper left anterior tooth, tooth 21, and bleeding gums. There was no spontaneous pain reported

in the affected tooth. The patient has no history of systemic diseases or drug allergies. Extra-oral examination revealed no abnormalities. Intra-oral examination showed Ellis class 1 fracture on the incisal-distal aspect of tooth 21. The patient has poor oral hygiene with visible calculus deposits on the upper and lower jaw teeth regions. The gingiva is hyperplastic, red, easily bleeds, and the gingival margin appears lower on teeth 11 and 21 compared to teeth 12 and 22 (Figure 1). Radiographic examination showed the alveolar crest distant from the CEJ is still normal (Figure 2).

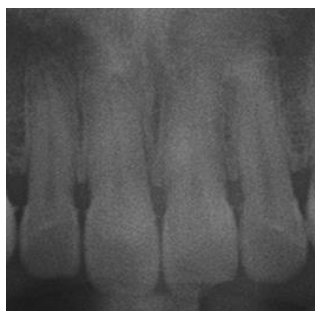

**Figure 1.** Clinical view before calculus removal.

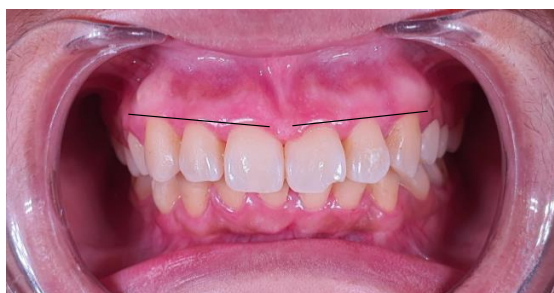## CASE MANAGEMENT

The treatment plan for this case includes calculus removal, crown lengthening surgery, followed by tooth restoration. After completing calculus removal and a follow-up examination (Figure 3), the next step involves the crown lengthening surgical procedure.

On the second visit after calculus removal, DHE and KIE were conducted, along with completing the inform to



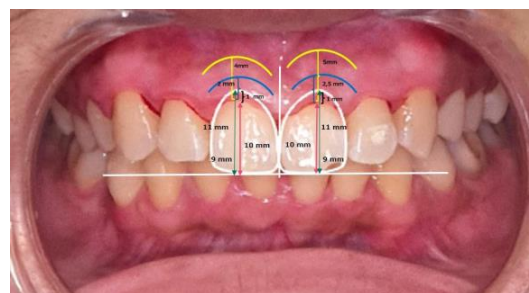
**Figure 2.** Radiographic image showing the alveolar crest distant from the CEJ (Cemento-Enamel Junction).



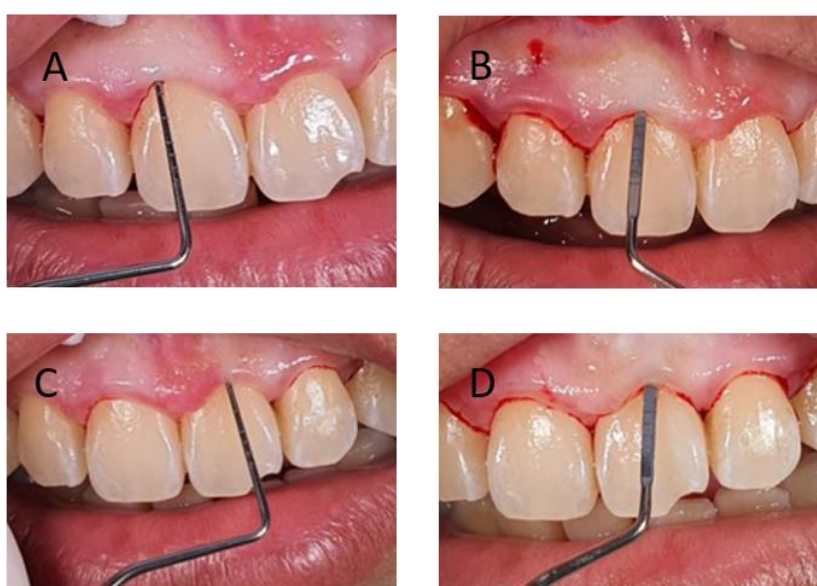
**Figure 3.** Clinical view 3 weeks after calculus removal.

consent and informed consent forms. Intraoral examination of tooth 11 revealed a gingival sulcus depth of 2 mm using a probe, with a bone sounding depth of 4 mm. Subsequently, tooth 21 exhibited a gingival sulcus depth of 2.5 mm, with a bone sounding depth of 5 mm (Figure 4). Digital Smile Design (DSD) was conducted using the Medit application, resulting an initial width and height ratio of 90% for teeth 11 and 21. To correct the gum line margin height and achieve the ideal width and height ratio of 80%, based on probing and bone sounding results, a 1 mm reduction in gingival margin was indicated for teeth 11 and 21 (Figure 5).

On the third visit, crown lengthening was performed on teeth 11 and 21. The patient's general condition was good, with a blood pressure of 115/72 mmHg. The surgical area was prepared aseptically both extra-orally and intra-orally. Anesthesia was administered using prilocaine, followed by creating bleeding points from distal aspect of tooth 11 to distal 21 using a pocket marker forceps. External bevel incisions were made on the mesial gingiva of teeth 11 and 21 with a no. 15C scalpel, angled approximately 45° apically against the tooth surface at the marked tissue boundary indicated by the pocket marker forceps. Tissue removal was performed with a curette.



**Figure 5.** Digital Smile Design (DSD).



**Figure 4.** Gingival sulcus probing depth of 2 mm for tooth 11(A); Bone sounding depth of 4 mm for tooth 11(B); Gingival sulcus probing depth of 2.5 mm for tooth 21(C); Bone sounding depth of 5 mm for tooth 21 (D).

Gingival contouring was carried out using a Kirkland periodontal knife on the facial aspect and an Orban periodontal knife on the interdental area. Evaluation of the gingival zenith was performed, followed by irrigation of regions 11 and 21 with saline solution, and placement of a periodontal pack (Figure 6). The patient was given post-operative instructions following crown lengthening surgery, prescribed analgesic medication, and scheduled for a follow-up appointment in one week.

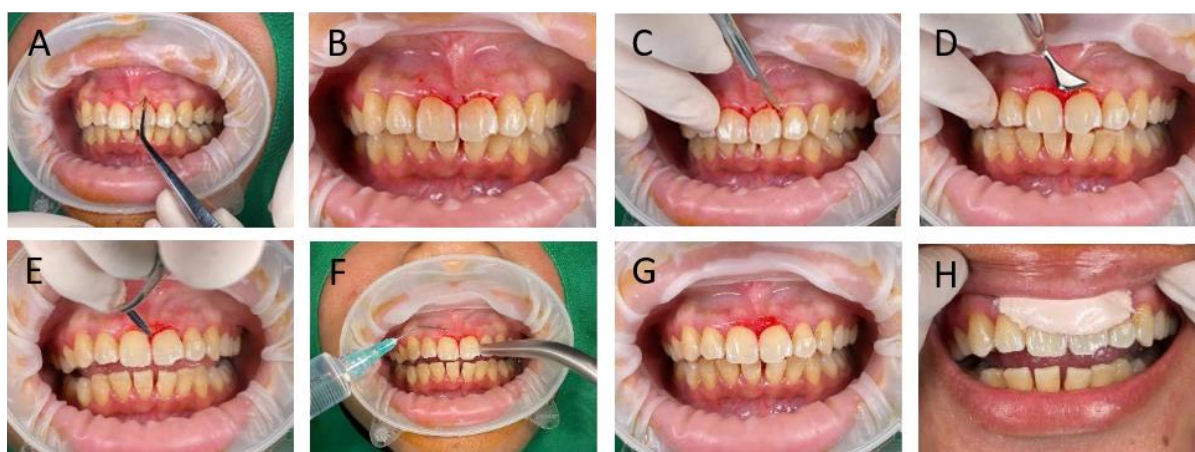On the fourth visit, 13 days after the crown lengthening procedure on teeth 11 and 21, the patient returned for a follow-up. The patient denied any pain and reported that the periodontal pack had fallen out 7 days after surgery. Intraoral examination showed normal gingiva around teeth 11 and 21. Saline irrigation was performed, followed by composite filling procedure on tooth 21 (Figure 7).

## DISCUSSION

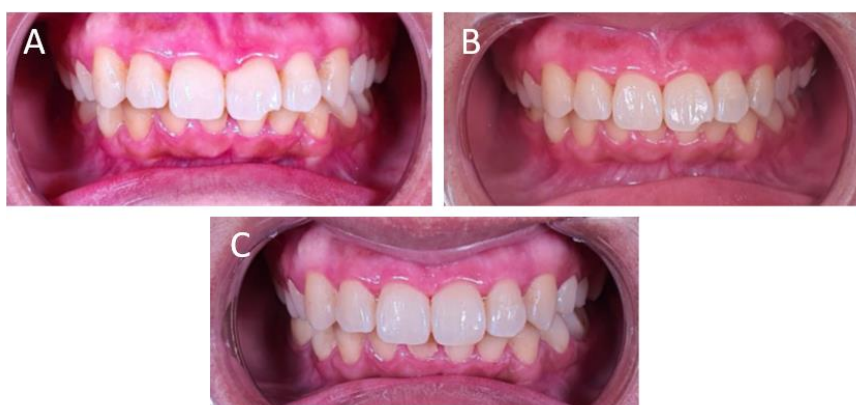Crown lengthening is a surgical procedure designed to increase the height of the supragingival tooth structure for restorative or aesthetic purposes by repositioning the

gingival margin apically, removing supporting bone, or both. Indications for crown lengthening include teeth with subgingival caries or extensive caries that shorten the tooth, fractures, and short clinical crown.<sup>2</sup> Crown lengthening must consider the biological width (the natural distance between the base of the gingival sulcus and the height of the alveolar bone) to avoid violations that can lead to bone resorption, gingival recession, inflammation, or hypertrophy.<sup>3</sup> Studies indicate that a minimum biological width of 3 mm, including 2 mm for biological width and 1 mm for sulcus depth, between the restoration margin and alveolar bone is adequate for periodontal health.<sup>2</sup>

The upper central incisor is considered the primary reference tooth, more critical than other anterior teeth in terms of visible crown structure.<sup>4</sup> For aesthetic purposes, upper anterior teeth should be proportional to facial morphology.<sup>5</sup> Ideally, the upper central incisor should have a width and height ratio of around 80%, although reported ratios vary between 66% and 80%. A golden standard for the width and height ratio of upper central incisors in the range of 75% to 80% is found in 20.4% of the population, influenced by racial and gender factors, with males typically having wider width and height ratios compared to females.<sup>6</sup>



**Figure 6.** Pocket marker forceps (A); Bleeding point (B); External bevel incision (C); Facial contouring using Kirkland (D); Interdental contouring using Orban (E); Saline irrigation (F); Final result of crown lengthening (G); Placement of periodontal pack (H).



**Figure 7.** Initial clinical photograph (A); Clinical photograph at 13-day follow-up post crown lengthening (B); Clinical photograph after composite filling procedure on tooth 21 (C).



In this case, Digital Smile Design (DSD) revealed an initial width and height ratio of 90% for teeth 11 and 21. To correct the gingival margin height and achieve a width and height ratio of 80% for teeth 11 and 21, based on probing and bone sounding results, a 1 mm apical gingival margin retraction was performed. This 1 mm gingival margin reduction still maintains a 1 mm sulcus depth and a 2 mm biological width. Since this treatment required several visits, the success of this treatment was supported by the patient's cooperation in following the operator's instructions.<sup>7</sup> A successful treatment is a collaboration between the patient's cooperation and the operator's skills and knowledge.

In conclusion, crown lengthening should consider the biological width to avoid bone resorption, gingival recession, inflammation, or hypertrophy. When performed under ideal clinical conditions, crown lengthening provides satisfactory outcomes both functionally and aesthetically.

## REFERENCES

1. Pedraza JAQ, Salinas BRG, Fierro NC, Najera RIS, Trevino JJF, Delgado IR. Crown lengthening procedure using aesthetic measurement gauges: A case report. *Int J Appl Dent Sci* 2017; 3(2): 95-7.
2. Patil N, Dondani J. Clinical crown lengthening: A case report. *Int J Appl Dent Sci* 2021; 7(1): 323-326.
3. Marzadori, M., Stefanini, M., Sangiorgi, M., Mounssif, I., Monaco, C., & Zucchelli, G. 2018. Crown lengthening and restorative procedures in the esthetic zone. *Periodontology* 2000. 77(1): 84-92.
4. Lunardhi CGJ, Prasetyo EP. Esthetic rehabilitation of crowded and protruded anterior dentition. *Dental Journal* 2009; 42(1): 46-9.
5. Prasetyo EP. Anterior makeover on fractured teeth by simple composite restoration. *Dental Journal* 2011; 44(3): 150-3.
6. Bhochhibhoya, A., Shrestha, R., Guragain, M., Sharma, R., & Joshi, K. R. 2022. Clinical Crown Length, Width and the Width/Length Ratio of the Maxillary Central Incisor Among Patients Reporting to a Tertiary Care Center in Nepal. *Journal of Nepalese Prosthodontic Society*. 5(2): 71- 77.
7. Sampoerno G, Hendani R, Prasetyo EA. The relationship between patient's dental and oral health attitude towards patient's obedience during multi visit treatment. *Conservative Dentistry Journal* 2020; 9(2): 97-104.