

Case Report

Endodontic retreatment in case of failure: case report

Kevin Prayogo, Dian Agustin Wahjuningrum and Ari Subiyanto

Department of Conservative Dentistry
Faculty of Dental Medicine, Universitas Airlangga,
Surabaya, Indonesia

ABSTRACT

Background: In medical practice, clinicians come across a lot of obstacle during a treatment, that can lead to a failure, like other dental treatments, endodontics too can fail. Inappropriate mechanical debridement, persistence of bacteria in the canals and apex, poor obturation quality, over and under extension of the root canal filling, and coronal leakage are some of the commonly attributable causes of failure. Despite the high success rate of endodontic treatment, failures do occur in a large number of cases and most of the times can be attributed to the already stated causes. **Purpose:** Endodontic retreatment of a failure is required by the increased desire to preserve the tooth on the dental arch, preventing the need for dental extraction that may have adverse consequences in terms of functional and psychological effect on patients. **Case:** This article presents a case report about dental retreatment with 2 common failure, that was under filling obturation and non-fit post. **Case management:** The failure was corrected with endodontic retreatment, and finally restored with fiber post and porcelain fused to metal crown. **Conclusion:** Endodontic retreatment was done successfully on underfilling obturation and non-fit post. The patient was satisfied with the result.

Keywords: endodontic failure; retreatment; incomplete obturation; failed post; crown

Correspondence: Dian Agustin Wahjuningrum, Department of Conservative Dentistry, Faculty of Dental Medicine, Universitas Airlangga. Jl. Prof. Dr. Moestopo 47 Surabaya, 60132, Indonesia. E-mail: dian-agustin-w@fkg.unair.ac.id

INTRODUCTION

Endodontic retreatment is a procedure which is done on a tooth previously endodontically treated, but whose current condition requires further endodontic treatment to achieve a successful result. Despite the fact that the success rate of endodontic treatment is high, each clinician must be prepared to endodontically retreat the endocanalicular system, if initial treatment fails. Several specialists showed that 30-50% of their clinical work is represented by endodontic retreatments.

The usual factors which can be attributed to endodontic failure are Persistence of bacteria (intra-canal and extra-canal), Inadequate filling of the canal (canals that are poorly cleaned and obturated), Overextensions of root filling materials, Improper coronal seal (leakage), Untreated canals (both major and accessory), Iatrogenic procedural errors such as poor access cavity design, Complications of instrumentation (ledges, perforations, or separated instruments).

The aim of endodontic treatment is thorough debridement and cleaning of the root canal system of any infected pulp tissue so the canal space can be shaped and prepared to be filled with an inert material thus preventing or minimizing any chances of reinfection. However, failure ensues when

the endodontic treatment falls short of the standard clinical principles.

CASE

A female patient, showed up in the dental office complaining of discomfort when eating in the right mandibular arch. She states that she got a wide range of allergic to drugs, including anesthesia and analgesic. Following clinical and radiological examination, it was noted that in the right mandibular region, at the level of 4.5 tooth, there were present post restoration of that tooth, but it was chipped. The patient state that the restoration fail 3 month prior, and as seen it shown a metal post. The radiological exam showed us that, at the 4.5 tooth had been treated endodontically, but it shown under filling and failed post (Figure 1), but fortunately, has no presence of periapical pathology.

CASE MANAGEMENT

The management was started by removing the post with Satelec scaler using narrow tips (Figure 2). Penetration holes into root canals were highlighted with gates glidden

drill at first and continued with Retreatment file (Dentsply) with solvling agent. After removing all the filling material, radiograph was done as confirmation, CaOH was applied as dressing. Three days after, the treatment was continued with canal preparatin using Protaper Next (Dentsply) until it reached X3, and got the tug back. Irrigation was done using Sodium Hypochlorite at 5.25%, Aquadest, and EDTA at 17% and activated with Endoactivator (Dentsply).

Obturation using Single cone tehcnique was done with X3 Guttap Percha (Dentsply). Radiograph was taken for confirmation of the obturation and for the template for determine the Post. Fibre Post was chosen and cemented with Resin cement PermaCem 2.0 (DMG) and Core Build up composite is used for rebuild the core using LuxaCore Z (DMG).

Preparation of final restoration was done, and Restoration was done using PFM Crown, and Cemented using GIC Lutting (GC). Follow up was scheduled on 4 weeks, and patient came with no complain and satisfied with the result.

DISCUSSION

In situations when we diagnose a failure of initial endodontic treatment, there are three possible variants of solving the existing problem. The first and most indicated solution is represented by endodontic retreatment. The second option is represented by apical surgery followed by retrograde sealing of the root canal, while the last option,

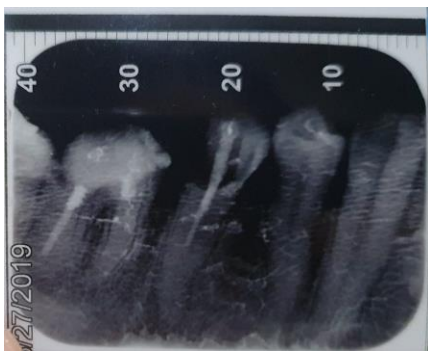


Figure 1. Incomplete root canal filling.

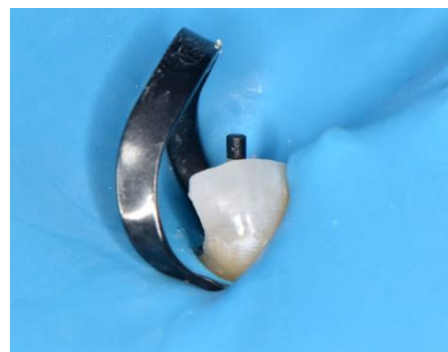

Figure 4. Try in fiber post.

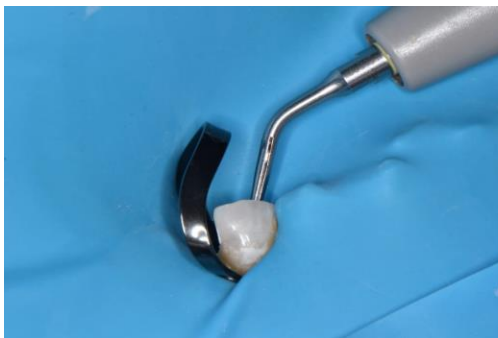

Figure 2. Removing old metal post using Satelec.

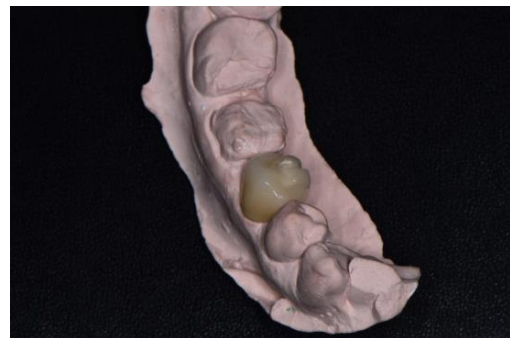

Figure 5. PFM restoration.

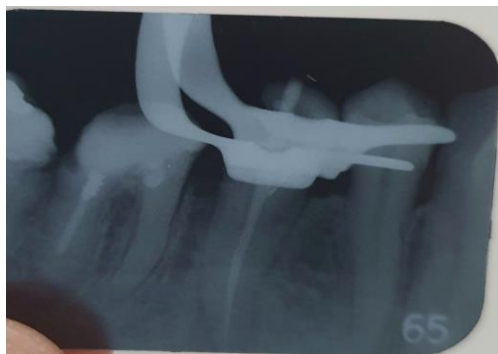

Figure 3. Final endodontic retreatment.

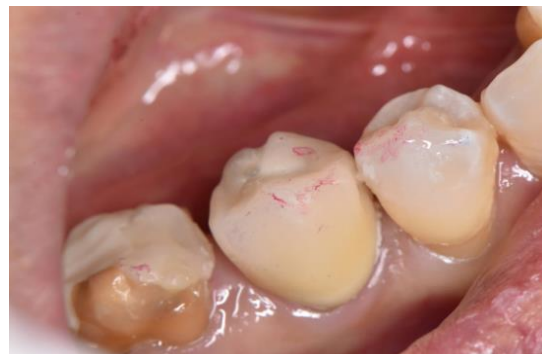

Figure 6. Final restoration.

which is not desirable, is represented by dental extraction. The latter is necessary if the first two options can not be achieved.

The first option- non-surgical endodontic retreatment is preferable in case of endodontic treatment failures, when gaining access to the root canals is possible. During endodontic retreatment we should do cleaning, shaping, and three-dimensional filling, with an inert filling material in all previously obturated root canals.

One of the foremost causes of endodontic failure is persistent microbiological infection. The role of bacteria in periradicular infection has been well established in literature and endodontic treatment will be afflicted with a higher chance of failure if microorganisms persist in the canals at the time of root canal obturation. Bacteria harbored in root canal areas such as isthmuses, dentinal tubules and ramifications may evade disinfectants.

Apart from proper disinfection and debridement of canals, another factor which is of colossal importance is the quality of obturation. The quality of root canal obturation was the most important factor in the success of the endodontic treatment in a study carried out on 1001 endodontically treated teeth. In another study which assessed teeth with endodontic failures, 65% of the cases exhibited poor quality obturation whereas 42% of the teeth had some canals which were left untreated. Success rates are naturally lower for obturations which are under or overextended and are highest for those which end flush or within 2 mm of the apex.

According to guidelines by European Society of Endodontology, the assessment of root canal filling should be checked with a radiograph and this radiograph should show the root apex with at least 2–3 mm of the periapical region.

Adequate density of root canal filling is an important factor for long term success of endodontic treatment. Poor fillings can lead to endodontic treatment failure due to micro leakage along the root canal walls. Poor root fillings occurred in 28.5% in the present study. The results were similar to the previous studies by Barrieshi-Nusair et al. Who reported 27.4% poor density fillings and Bahareh

Dadresanfar et al. reported 29.3% in their study. However, it varied with other studies.

Modern endodontic practice adjuncts such as electronic apex locators and rotary nickel-titanium instruments were not used during the treatment of these cases. It has been shown that electronic apex locators are more accurate than radiographs to identify the working length of the root canal. Furthermore Ni-Ti rotary instruments shape the root canal better than conventional stainless steel instruments with less iatrogenic errors.

REFERENCES

1. Barrieshi-Nusair KM. Gutta-percha retreatment: effectiveness of nickel-titanium rotary instruments versus stainless steel hand files. *J Endod* 2002; 28:454–456.
2. Kirkevang, Horsted-Bindslev P, Ørstavik D, Wenzel. Frequency and distribution of endodontically treated teeth and apical periodontitis in an urban Danish population. *Int Endod J* 2001; 34: 198-205.
3. Dugas NN, Lawrence HP, Teplitsky PE, Pharoah MJ. Periapical health and treatment quality assessment of root-filled teeth in two Canadian populations. *Int Endod J* 2003; 36:181-192.
4. Friedman S. Considerations and concepts of case selection in the management of post-treatment endodontic disease. *Endod Topics* 2002; 1: 45-64.
5. Stabholz A, Friedman S. Endodontic retreatment – case selection and technique. Part 2: treatment planning for retreatment. *J Endod* 1988; 14: 607-614.
6. Holland R, Valle GF, Taintor JF, Ingle JI. Influence of bony resorption on endodontic treatment. *Oral. Surg* 1983; 55:191.
7. Friedman S. Treatment outcome and prognosis of endodontic therapy. In: Ørstavik D, Pitt Ford TR, editors. *Essential endodontology*. London: Blackwell Scientific; 1998. p. 367–401
8. Sjögren U, et al. Factors affecting the long-term results of endodontic treatment. *JOE* 1990; 16:498.
9. Gutmann JL. Clinical, radiographic, and histologic perspectives on success and failure in endodontics. *Dent Clin North Am*. 1992; 36: 379-392