

A Type 2 Diabetes Patient Who Suffered With Fournier's Gangren

Kholidatul Husna¹, Hermina Novida^{2*}

¹Department of Internal Medicine, Faculty of Medicine, Universitas Airlangga – Dr. Soetomo General Hospital Surabaya, Indonesia.

²Division Endocrinology and Metabolic, Department of Internal Medicine, Faculty of Medicine, Universitas Airlangga – Dr. Soetomo General Hospital Surabaya, Indonesia.

ABSTRACT

Diabetes mellitus increases the risk of infection, including Fournier's gangrene. Fournier's gangrene (FG) is rare, with an average incidence of 1.6 cases per 100,000 population per year. We report a case of a 60-year-old presented with the history of wounds of the buttocks, penis, and scrotum. The patient had a history of uncontrolled diabetes mellitus for 3 years. There were perianal abscesses and necrotic tissue on the penis and scrotum. Radiological evaluation in the patient showed the presence of gas-forming in the scrotal area. Therefore, incision and drainage procedures with necrotomy and debridement were performed, together with antibiotics and blood glucose regulation, followed by the closure of the defect with skin graft and flap use. The patient was discharged with an improved clinical condition.

Keywords: Diabetes mellitus, Fournier's gangrene, Perianal abscesses, Skin graft

Correspondence: Hermina Novida

E-mail: hermina-n@fk.unair.ac.id

Article history: •Received 11 December 2020 •Received in revised form 27 January 2021 •Accepted 28 January 2021

INTRODUCTION

Diabetes mellitus (DM) increases the risk of infection, including gangrene (Tjokroprawiro, 2017). Fournier's gangrene (GF) is progressive necrotizing fasciitis of the perineal, perianal or genital areas. Fournier's gangrene was first discovered in 1883 by a French venereologist, Jean Alfred Fournier (Vargas et al., 2011). This case is quite rare and mainly affects male patients with a peak incidence over 50 years of age (Sorensen et al., 2009). Although initially described as idiopathic gangrene, the cause can be identified in 75-95% of cases. The most common cause is a perianal abscess in uncontrolled diabetes (Nisbet & Thompson, 2002; Hirugade et al., 2016). Fournier's gangrene is an emergency case of general surgery and urological department because it has a very sudden onset, progressive disease and causes septic complications. FG's mortality rate is quite high (20-40%), so an early diagnosis and prompt treatment are essential because it determines the patient's prognosis (Martinschek et al., 2012). We reported a patient with type 2 diabetes who had Fournier's gangrene and perianal abscess due to trauma.

CASE REPORT

A 60-year-old male came to the emergency room of Dr. Soetomo Hospital with a chief complaint of wounds of the buttocks, penis, and scrotum 5 days before admission, and it was getting worse. The patient had fallen from the tree, and the buttocks were swollen, painful, reddish and felt warm. There was wound in buttocks widened up to the scrotal, penis area,

and purulent drainage. The patient also complained of fever, lower abdominal pain, nausea and vomiting in the last 1 day. The defecation was normal. The urination was smooth, and frequent urination in the last 3 years. He also complained of easily hungry and thirsty, and weight loss of 15 kg in the last 2 years. There were no complaints of wounds of the feet or blurred vision. Patient had been diagnosed with type 2 diabetes for 3 years, but he did not take any medications. He had no history of high blood pressure, stroke, or heart disease. There was no family history of diabetes.

The physical examination showed that the general condition was moderate illness, compos mentis (GCS 4-5-6) with blood pressure 110/70 mmHg, heart rate 110x/minute (regular and adequate pulse), respiratory rate 20x/minute, and axillary temperature 38.1°C. Head, neck, and chest examination was within normal limit. There was erythematous skin in lower abdomen area with normal bowel sounds. There were perianal abscesses and necrotic tissue on the penis and scrotum. Rectal touche examination was within normal limit (Figure 1).

The laboratory examination showed: Hb 12.0 g/dl; leukocyte 13,840/ μ L; granulocyte 88.6%; platelet 546,000/ μ L; RPG (random plasma glucose) 428 mg/dl; AST 20 U/L; ALT 22 U/L; BUN 25 mg/dl; serum creatinine 1.24 mg/dl; albumin 2.66 g/dl; CRP 313.43 mg/L; Na 134 mmol/l; K 4.5 mmol/l; Cl 96 mmol/l. Urinalysis: yellow, SG 1.010; pH 6.0; prot (+2); gluc (+3); uro 16 mmol/L; bil (+1); nit (-); leu (-); bld (-); leut 2-5/hpf; ery 10-15/hpf. Blood gas analysis: pH 7.54; PCO₂ 28 mmHg; PO₂ 72 mmHg; HCO₃ 24 mmol/l; BE 1.

1, SO₂ 96.3%. ECG: sinus rhythm 108x/minute, normal axis. Chest x-ray was normal. The pelvic x-ray showed the present of gas forming in scrotal area (Figure 2).

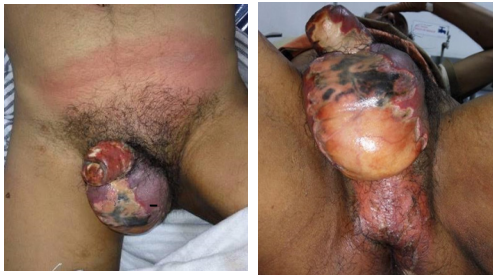

Figure 1. Initial physical examination

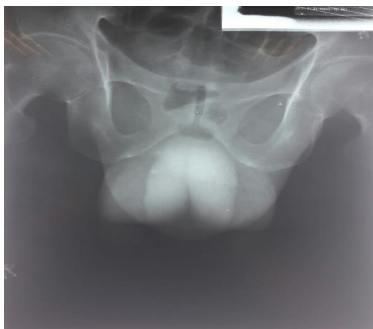

Figure 2. Pelvic x-ray showed gas formation in scrotal area.

Interdepartmental consultations, 1) Urology: the patient was diagnosed with Fournier gangrene, suggested to perform necrotomy and debridement; 2) Digestive: the patient was diagnosed with perianal abscesses, the patient was planned to undergo an emergency incision and drainage procedure.

Based on anamnesis, physical, laboratory & radiology examination, the patient has been diagnosed with Fournier's gangrene + perianal abscesses + type 2 diabetes + hypoalbuminemia. Blood glucose was regulated with insulin correction 4 unit intravenous injection three times and NaCl 0.9% infusion 1,000 ml in an hour. Then the patient has undergone an emergency joint surgery of digestive and urology surgeon: incision and drainage procedure, also necrotomy and debridement procedure (Figure 3).

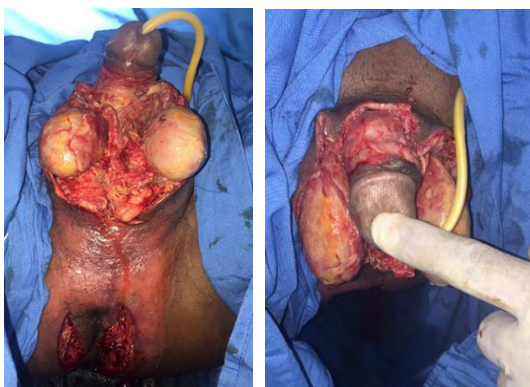


Figure 3. After necrotomy and debridement procedure.

The patient was planned to perform serial blood glucose during and post-surgery, fasting plasma glucose (FPG), 2 hours plasma glucose (2h-PG), blood, and pus cultures. After surgery, the patient was given G diet 2,100 kcal/

day, fluid balance I=O+500, NaCl 0.9% infusion 1,500 ml/day, ceftriaxone 1 gram/12 h intravenous injection, metronidazole 500 mg/8 h intravenous injection, prandial insulin 8 unit subcutaneous injection 3 times daily, ketorolac 30 mg/8 h intravenous injection, and wound care. The patient was monitored for complaint, vital signs, and blood glucose.

On the 4th day of admission, the patient complained of surgical wound pain, and fever became better. Vital signs were within normal limit. The patient had a perianal drain and rectal tube, and wound condition showed in Figure 4 on the third day of wound care. The wound was in good condition, with no pus, and visible granulation tissue. Urine production was 1,500 ml/24 h. Laboratory finding: FPG 297 mg/dl; albumin 2.13 g/dl. The pus culture result: *Staphylococcus aureus* dan *Klebsiella pneumoniae*, resistance for ceftriaxone. The tissue culture result: *Staphylococcus pasteurii*. The patient was then given cefotaxime 1 gram/8 h based on sensitive culture result, basal insulin 10 unit subcutaneous injection once daily, and albumin transfusion.

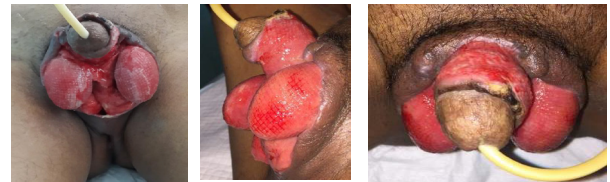

Figure 4. On third day of wound care

On the 14th day of admission, the patient had no complaints with stable vital signs. The wound was in good condition, with no pus, and visible granulation tissue. Urine production was 1,800 ml/24 h. Laboratory finding: Hb 10.3 g/dl; leukocyte 7,900/ μ L; granulocyte 72%; platelet 580,000/ μ L; FPG 126 mg/dl; 2h-PG 166 mg/dl; AST 20 U/L; ALT 22 U/L; BUN 26 mg/dl; serum creatinine 0.95 mg/dl; albumin 3.3 g/dl. Blood culture was sterile. The patient was consulted for the closure of the defect to the plastic surgery department. The antibiotics have been discontinued.

On the 35th day of admission, the patient had undergone plastic procedure (closure of the defect with thick STSG (Split Thickness Skin Grafts) and bilateral pudendal perforator artery flap). After one week of the closure of the defect, the flap was in good condition: viable, warm, and the color was the same as the surrounding skin (Figure 5).

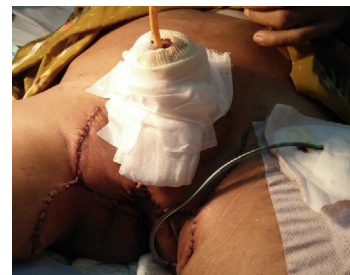

Figure 5. After skin graft procedure.

The patient was advised to control the endocrinology metabolic of internal medicine, plastic surgery, urology,

and digestive outpatient clinics. The insulin medication was continued: prandial insulin 8 unit subcutaneous injection three times daily, and basal insulin 10 unit subcutaneous injection once daily.

DISCUSSION

Fournier's gangrene (FG) is progressive necrotizing fasciitis of the perineal, perianal or genital areas. Diagnosis of Fournier's gangrene is mainly based on clinical examination. The patients usually complain of swelling and pain in the pubic area, accompanied by fever. On physical examination, a systemic inflammatory response syndrome, severe sepsis, skin edema, erythema, ulcers, necrosis, crepitus, and purulent drainage from the wound can be found. Crepitation can be found in FG cases due to anaerobic bacteria that produce exotoxins that cause necrosis and gas formation. Other investigations can be done to confirm the diagnosis. Laboratory findings may indicate anemia, leukocytosis, thrombocytopenia, electrolyte imbalance, hyperglycemia, acute kidney injury, and hypoalbuminemia. A radiological examination can be carried out if the diagnosis is still in doubt, but this should not delay surgical treatment. Plain radiographs of Fournier's gangrene can show gas in the soft tissue, characterized by hyperlucency (Malikarjuna et al., 2012; Jeje et al., 2017).

Fournier's gangrene diagnosis in this patient was made based on history, physical examination, and other investigations. The patient complained of the scrotal and penis area wound extending from the buttocks due to trauma. He also complained of fever. From the physical examination, it was found necrotic tissue and crepitus on the penis and scrotum. On laboratory examination, there were leukocytosis, hyperglycemia, and hypoalbuminemia. While the pelvic x-ray showed the presence of gas forming in scrotal area.

Fournier's gangrene mostly affects males, with a peak incidence at 40-70 years of age. The necrosis process usually originates from infection in the anorectal area (13-50%), urogenital tract (17-87%), while others from local trauma or skin infection around the genital area (Czymek et al., 2009). The causes of the anorectal area include perianal abscess, anal fissure, and bowel perforation resulting from colorectal injury or malignancy, colonic diverticulitis, and appendicitis. In the urogenital tract, FG causes include infection of the bulbourethral gland, urethral injury, iatrogenic injury secondary to manipulation of urethral strictures, epididymitis, orchitis, or lower urinary tract infection. Whereas in dermatology, the causes include suppurative hidradenitis and trauma (Sughishita et al., 2008; Altarac et al., 2012). The scrotum is the most common infection site at initial diagnosis, but FG also occurs in the perineal area, penis, and lower abdomen. The scrotum is prone to necrosis because its blood flow is relatively limited. Anorectal and urogenital trauma can be the port of commensal bacteria's entry, such as *Staphylococcus spp.* and *Escherichia coli* into the perineal area that become virulent and cause tissue damage due to impaired cellular immunity, followed by thrombosis and decreased blood flow that is resulting in ischemia. Tissue hypoxia increases the proliferation of anaerobic bacteria and fascia necrosis so that the infection is polymicrobial in

the presence of aerobic and anaerobic bacteria (Singh et al., 2016; Jeje et al., 2017).

This patient was a 60-year-old male, with the cause of FG was trauma (falling from a tree) that resulting in perianal abscess and extends to the scrotal and penis area. The pus culture results showed *Staphylococcus aureus* and *Klebsiella pneumoniae* bacteria growth, while the tissue culture showed *Staphylococcus pasteurii* bacteria.

Fournier's gangrene predisposing factors are general poor conditions such as malnutrition, use of immunosuppressants, alcohol, diabetes mellitus, chronic liver disease, and chronic kidney disease (Czymek et al., 2009; Martinschek et al., 2012). Uncontrolled diabetes is the most common predisposing factor for FG in 32 - 66% cases (Nisbet & Thompson, 2002; Hirugade et al., 2016). According to the American Diabetes Association (ADA) 2017, a diagnosis of diabetes can be made if it meets one of the following criteria: 1. HbA1C \geq 6.5%; 2. Fasting plasma glucose \geq 126 mg/dl; 3. 2-hour plasma glucose \geq 200 mg/dl with oral glucose tolerance test; 4. Random plasma glucose \geq 200 mg/dl with classic symptoms or hyperglycemic crisis (ADA, 2017). Persistent hyperglycemia in diabetes increases the aerobic fermentation to anaerobic environment; gas is produced, and the oxidation potential decreases. The anaerobic environment increases infection by anaerobic bacteria. Hyperglycemia also decreases the immune system by reducing cellular immunity, chemotaxis activity, and phagocytosis, thereby prolonging the healing process. The increased tissue glucose, poor tissue perfusion, and weak immune response in diabetic patients lead to more progressive infection and can progress rapidly to sepsis (Nisbet & Thompson, 2002; Singh et al., 2016; Jeje et al., 2017).

The predisposing factor for FG in this patient was diabetes mellitus. The patient had a history of uncontrolled diabetes for three years, accompanied by classical symptoms (polyuria, polydipsia, and weight loss) and random plasma glucose 428 mg/dl. The patient's HbA1C was 7.8%, so the patient was diagnosed with type 2 diabetes mellitus.

FG management principles are to improve the patient's general condition, administration of antibiotics, and surgical debridement. In patients with hypoperfusion or systemic organ failure, immediate resuscitation to restore normal organ perfusion should take first than diagnostic procedures. Antibiotics that can be given are systemic broad-spectrum antibiotics that include staphylococci, streptococci, Enterobacteriaceae, and anaerobes. Commonly used antibiotic combinations are penicillin or clindamycin for streptococcal species, third-generation cephalosporins or carbapenems for gram-negative bacteria, and metronidazole for anaerobes bacteria. A surgical debridement is required for definitive diagnosis and excision of necrotic tissue. Gangrene gas formation can reach 1 cm² per hour, so surgical debridement must be done as soon as possible. Patients with uncontrolled diabetes require more aggressive wound care and extensive debridement. Sometimes, it is necessary to make urine diversion through cystostomy or stool diversion by performing a colostomy to avoid contamination, but this procedure is still controversial and should be applied according to the individual patient's condition. Surgical reconstruction may be performed,

depending on the size of the wound. Primary suturing can be performed mainly in flexible skin, such as the scrotum, but if the wound is large enough, skin grafts and multiple flaps can be used. Therapy with hyperbaric oxygen can also be used as part of FG management (Heyn & Theron, 2007; Malakarjuna et al., 2012; Singh et al., 2016).

Perioperative insulin therapy generally depends on the type of diabetes, the type of surgical procedure, previous pharmacological therapy, and glycemic control status before the surgical procedure. Before surgical procedures, the target blood glucose is 140-180 mg/dl (PERKENI, 2006). In hyperglycemia, especially in an emergency case, it is necessary to immediately reduce blood sugar levels by administering correctional insulin, either intravenously or subcutaneously (ADA, 2017). Giving insulin during hospitalization aims to control blood glucose levels more intensively to inhibit the suppression of the immune response due to hyperglycemia and accelerate the healing process of infection. Several previous studies have reported that insulin has anti-inflammatory effects (Jack & George, 2002). Nutritional therapy in diabetic patients with gangrene can be given a G diet consisting of 60% carbohydrates, 20% fat, and 20% protein; high arginine, 25-35 g/day of fiber, <300 mg/day of cholesterol, extra folic acid, B6 and B12 vitamins. The calories that needed at normal body weight is 30 kcal/day (Tjokropawiro, 2017).

This patient's management includes crystalloid infusion and blood sugar regulation with intravenous insulin because the patient was planned to perform an emergency debridement procedure. Before surgery, the patient was given intravenous antibiotics, ceftriaxone 1 gram and metronidazole 500 mg, and a urine catheter installation. The patient has then undergone a joint surgery by urological and digestive surgeons, necrotomy and debridement in the necrotic area, and abscess drainage. After surgery, the patient was given fluid infusion as needed, G diet G 2100 kcal/day, antibiotics, basal and prandial insulin that dose adjusted based on latest blood glucose results, albumin transfusion, and wound care. The patient underwent a plastic surgeon's closure of defect procedure with a thick STSG (Split Thickness Skin Grafts) technique and bilateral pudendal perforator artery flap.

Fournier's gangrene is an infectious disease with high mortality (20-40%). Several previous studies have developed a method to estimate the patient's prognosis, one of which is the Fournier's gangrene severity index (FGSI) (Ochoa et al., 2010; Martinschek et al., 2012; Benjelloun et al., 2013). FGSI is a numerical score obtained from a combination of physiological hospital admission parameters (Table 1).

Table 1. Fournier's gangrene severity index (FGSI)

Physiological variables	High abnormal values			Normal values			Low abnormal values		
	4+	3+	2+	1+	0	1+	2+	3+	4+
Assigned numeric score	4+	3+	2+	1+	0	1+	2+	3+	4+
Temperature °C	>41	39-40.9	-	38.5-38.9	36-38.4	34-35.9	32-33.9	30-31.9	<29.9
Heart rate	>180	140-179	110-139	-	70-109	-	56-59	40-54	<39
Respiratory rate	>50	35-49	-	25-34	12-24	10-11	6-9	-	<5
Serum sodium (mmol/l)	>180	160-179	155-159	150-154	130-149	-	120-129	111-119	<110
Serum potassium (mmol/l)	>7	6-6.9	-	5.5-5.4	3.5-4	3-3.4	2.5-2.9	-	<2.5
Serum creatinine (mg/100ml)	>3	2-3.4	1.5-1.9	-	0.6-1.4	-	<0.6	-	-
Haematocrit %	>60	-	50-59.9	46-49	30-45.9	-	20-29.9	-	<20
Leukocytes (total/mm ³ x 1000)	>40	-	20-39.9	15-19.9	3-14.9	-	-	1-2.9	-
<1 Serum bicarbonate	>52	41-51.9	-	32-40.9	22-31.9	-	18-21.9	15-17.9	<15 (venous, mmol/l)

They stabilized that an FGSI score above 9 is sensitive and specific as a mortality predictor in FG patients, FGSI score above 9 has a mortality rate up to 75%, while FGSI under 9 has a survival rate up to 78% (Ochoa et al., 2010; Martinschek et al., 2012; Benjelloun et al., 2013).

The patient's FGSI score when he came to the emergency room for each parameter: temperature 38.1 (0), pulse 110x (+2), breath rate 20x (0), sodium 134 (0), potassium 4.5 (0), creatinine 1, 24 (0), hematocrit 36.1 (0), leukocytes 13,840 (0), and bicarbonate 24 (0). The patient's total FGSI score was 2, so it could be predicted

that the patient's prognosis was good, with a survival rate of 78%. The patient was discharged from the hospital with an improved clinical condition.

CONCLUSION

Fournier's gangrene is an emergency case of the urological department because it has a very sudden onset and progressive disease so that an early diagnosis and prompt treatment are essential for a good outcome. We have reported a male patient diagnosed with Fournier's gangrene with perianal abscess etiology due to trauma, and

the predisposing factor was uncontrolled diabetes. This patient has been performed an emergency debridement, blood glucose regulation, antibiotics, and reconstructive surgery to discharge with an improved clinical condition. The FGSi scoring system is used to predict Fournier's gangrene patient's outcome. The lower the score, the better the prognosis.

CONFLICT OF INTEREST

The author declare there is no conflict of interest of this study.

REFERENCES

- Altarc S, Katusin D, Crnica S, 2012. Fournier's gangrene: Etiology and outcome analysis of 41 patients. *Urologia Internationalis*, 88: 289-93.
- American Diabetes Association (ADA), 2017. Standard of Medical Care in Diabetes. *Diabetes Care*, 1: S14-62.
- Benjelloun EB, Souiki T, Yakla N, Ousadden A, Mazaz K, Louchi A, Kanjaa N, Taleb KA, 2013. Fournier's Gangrene: Our Experience With 50 Patients and Analysis of Factors Affecting Mortality. *World Journal of Emergency Surgery*, 8 (13): 1-5.
- Czymek R, Hildebrand P, Kleemann M, Roblick U, Hoffmann M, Jungbluth T, 2009. New insights into the epidemiology and etiology of Fournier's gangrene: A review of 33 patients. *Infection*, 37: 306-12.
- Heyn CF, Theron PD, 2007. Fournier's Gangrene. In: Markus Hohenfeller, *Emergencies in Urology*. New York USA: Springer, 50-59.
- Hirugade S, Patil HN, Hirugade SS, 2016. Fournier's gangrene and diabetes mellitus: Our experience with 50 patients. *International Journal of Recent Trends in Science & Technology*, 20 (2): 209-13.
- Jack SD, George K, 2002. Management of diabetes mellitus in surgical patients. *Diabetes spectrum*, 15 (1): 44-8.
- Jeje AE, Mofikoya BO, Oliyide AE, 2017. Fournier's gangrene and perianal abscess: Is there a common denominator?. *Journal of Clinical Science*, 14: 53-5.
- Malikarjuna MN, Vijayakumar A, Patil VS, Shivswamy BS, 2012. Fournier's Gangrene: Current Practices. *ISRN Sugery*, 1-8.
- Martinschek A, Evers B, Lampl L, Gerngroß H, Schmidt R, Sparwasser C, 2012. Prognostic aspects, survival rate, and predisposing risk factors in patients with Fournier's gangrene and necrotizing soft tissue infections: Evaluation of clinical outcome of 55 patients. *Urologia Internationalis*, 89:173-9.
- Nisbet AA, Thompson IM, 2002. Impact of diabetes mellitus on the presentation and outcomes of Fournier's gangrene. *Urology*; 60: 775-9.
- Ochoa G, Lira C, Macias V, 2010. Usefulness of Fournier's gangrene severity index: A comparative study. *Revista Mexicana de Urologia*, 70: 27-30.
- Perkumpulan Endokrinologi Indonesia (PERKENI), 2006. *Petunjuk Praktis Terapi Insulin pada Pasien Diabetes Melitus*. Jakarta: PERKENI, 29-30.
- Tjokroprawiro A, 2017. *Formula Klinik Praktis (FKP) Dibidang Diabetologi, Endokrinologi, Metabolisme, Fokus: Diabetes*. Surabaya: Pusat Diabetes dan Nutrisi Surabaya, 5th edition.
- Singh A, Ahmed K, Aydin A, Khan MS, Dasgupta P, 2016. Fournier's gangrene, A clinical review. *Archivio Italiano di Urologia e Andrologia*, 88 (3): 157-64.
- Sorensen MD, Krieger JN, Rivara FP, Broghammer JA, Klein MB, Mack CD, Wessel H, 2009. Fournier's Gangrene: population based epidemiology and outcomes. *Journal of Urology*, 181: 2120-6.
- Sughisita Y, Nagashima M, Ooshiro M, Urita T, 2008. Fournier's gangrene progressing from the buttocks to the scrotum following a perianal abscess. *Journal of Infection and Chemotherapy*, 14: 56-58.
- Vargas AH, Carbonell J, Osorio D, Garcia HA, 2011. Evaluation of Fournier's necrosis in a high complexity hospital. *General urology*. *Archives Espanoles de Urologia*, 64: 948-52.