

Case Report:**MEDICAL, GROWTH AND DEVELOPMENT, AND QUALITY OF LIFE ASPECTS IN CHILDREN WITH 46,XX TESTICULAR DISORDER OF SEX DEVELOPMENT (DSD)****Nur Rochmah, Muhammad Faizi, Irwina Rahma Andriani, Soraya Salle Pasulu**

Department of Pediatrics, Faculty of Medicine, Universitas Airlangga, Dr Soetomo Hospital, Surabaya, Indonesia

ABSTRACT

46,XX testicular disorder of sexual development (DSD) is characterized by male phenotype with 46,XX karyotype. The incidence rate is 1:25,000 in male newborn. Infants with ambiguous external genitals will be confronted with issue of gender assignment and may result in a stressful condition in the parents. Since gender assignment is inevitable, several factors should be considered in DSD management. The management approach for children born with DSD is individualized and multidisciplinary. Gender assignment aims to facilitate the patient to obtain the best quality of life. Adaptation of children with 46,XX testicular DSD as a determinant of quality of life is also influenced by psychological and family conditions. The purpose of this report was to observe medical growth and development aspects of the child with 46,XX testicular DSD as indicated by the aspects of growth and development, and health related quality of life, as well as the influential aspects. PA, 18 months, was diagnosed with 46,XX testicular DSD. The patient routinely visited to endocrinology clinic, urologic surgery, and child psychiatry clinic from the age of 6 months. The parents decided to raise patient as male. The patient had undergone surgery for hypospadias correction, hormone injections, child growth monitoring, and psychological monitoring (medical records of Dr. Soetomo Hospital, Surabaya in 2015). Management should consider individual and multidisciplinary accompaniment of the patient and parents, the importance of group support, and follow-up to adulthood, as well as possible longterm outcomes that will occur in the future so that the patients and the parents need to be prepared.

Keywords: 46,XX testicular; DSD; management; quality of life

ABSTRAK

46,XX testicular disorder of sexual development (DSD) ditandai dengan fenotip laki-laki dengan 46,XX kariotipe. Angka kejadian 1:25.000 pada bayi laki-laki yang baru lahir. Bayi dengan genitalia eksterna ambigu akan dihadapkan dengan keadaan masalah dalam gender assignment dan dapat mengakibatkan kondisi stress pada orang tua. Mengingat adanya gender assignment maka dalam manajemen DSD perlu dipertimbangan beberapa faktor. Pendekatan tatalaksana untuk anak lahir dengan DSD adalah individual dan multidisiplin. Gender assignment bertujuan memfasilitasi agar pasien dapat memperoleh kualitas hidup terbaik. Adaptasi anak dengan 46,XX testicular DSD sebagai penentu kualitas hidup juga dipengaruhi oleh kondisi psikologis dan keluarga. Tujuan dari laporan kasus panjang ini adalah untuk pengamatan aspek medis, tumbuh kembang, dan kualitas hidup anak dengan 46,XX testicular DSD yang ditunjukkan dengan pertumbuhan, perkembangan, dan kualitas hidup (health related quality of life) serta aspek yang mempengaruhinya. An. PA, 18 bulan terdiagnosis 46,XX testicular DSD. Pasien rutin kontrol poliklinik endokrinologi, bedah urologi, dan psikiatri anak sejak usia 6 bulan. Orang tua memutuskan untuk membesarkan pasien sebagai laki-laki. Pasien telah menjalani operasi untuk koreksi hipospadia, injeksi hormon, pemantauan tumbuh kembang anak, dan pemantauan psikologis (rekam medis RSUD Dr. Soetomo 2015). Tatalaksana harus mempertimbangkan pendampingan pasien dan orang tua yang bersifat individual dan multidisiplin, pentingnya support group, dan follow up sampai dewasa, serta kemungkinan longterm outcome yang akan terjadi di masa mendatang sehingga pasien dan orang tua perlu dipersiapkan.

Kata kunci: 46,XX testicular; DSD; tatalaksana; kualitas hidup

Correspondence: Nur Rochmah, Department of Pediatrics, Faculty of Medicine, Universitas Airlangga, Dr Soetomo Hospital, Jalan Prof dr Moestopo 6-8, Surabaya 60286, Indonesia. E-mail: drnurrochmah@gmail.com

INTRODUCTION

Patient with 46,XX testicular disorder of sexual development (DSD) is characterized by male phenotype with 46,XX karyotype. The incidence rate is 1:25,000 in male newborn. The manifestations depend on the gender assignment of the Y chromosome (SRY gene). The external genitals undergo virilization in 90% of 46,XX testis cases with SRY-positive (SRY+). Whereas, ambiguous genitals are found in 10% of cases with SRY-negative (SRY-) (Houk & Lee 2010, Anik et al 2013).

In Endocrinology Clinic of Dr. Soetomo Hospital in 2016, there were about 30 patients with ambiguous genitalia who routinely visited the clinic (medical records Dr. Soetomo Hospital in 2016). Infants with ambiguous external genitals will be confronted with a state of gender assignment problem and may result in a stressful condition for the parents. The management approach of children with DSD is individual and multidisciplinary (Tridjaja & Marzuki 2010).

The gender management approach in 46,XX testicular DSD case is based on potential fertility, traditional sexual activity, and genital repair by surgery. In addition, cultural background and parental opinion are also considered to make gender assignment decision. Gender assignment aims to facilitate the patient to obtain the best quality of life. Interaction of various factors will create a good quality of life for children. The adaptation of children with 46,XX testicular DSD as a determinant of quality of life is also influenced by psychological and family conditions (Ocal 2011, Vilain 2009).

CASE REPORT

PA, male, 18 months old with 46,XX testicular DSD, was a patient of Endocrinologic Clinic, Dr. Soetomo Hospital, Surabaya, Indonesia, since the age of 6 months. The patient was the second child of two siblings of the Javanese ethnicity who lived in Ponorogo. The mother did not suffer any particular illness before and during pregnancy. The mother routinely visited a doctor and was said to have a healthy baby. The baby was born healthy and gained adequate nutrition. The history of similar diseases in the family lineage was denied. Family history between parents was also denied.

At the age of 6 months, the patient came to Endocrinologic Clinic, Dr. Soetomo Hospital with the main complaint of abnormal genital. The urine did not come out at the end of the genital but lead downwards, a condition that happened since birth. Furthermore, the patient was diagnosed with ambiguous genitalia and planned for further investigation.

On external genital examination, the penis length was 2.8 cm in strength of penile length (normal 4.1 ± 0.8). On palpability test, testes were palpable on the right and left of the scrotum. Right testicular volume was 1 mL and left testicular volume was 1 mL. When urinating, the flow of urine was not at the tip of the penis but lead down. External genitalia in infant PA was in accordance with Prader 4.

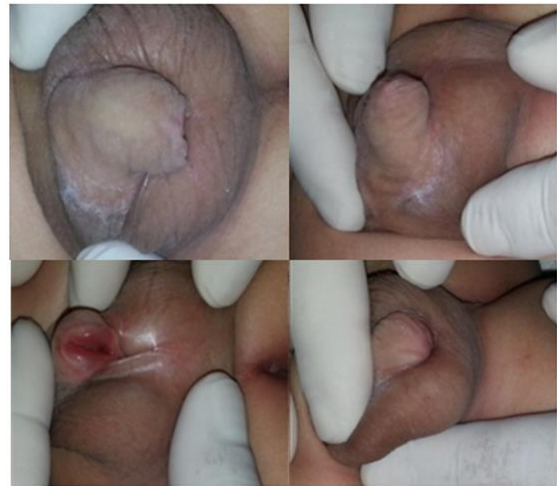

Fig. 1. The external genital of a 6 month old infant PA.

Examination of testosterone levels showed results <2.50 ng/dL. After injection of β HCG, it increased to 1,109.00 ng/dL, which were within normal limits. In the lower abdominal ultrasonography, the right and left testes were palpable on the scrotum. The size was appropriate for an individual of 6 months old. Uterus and ovaries were not found. The genitographic examination showed the administered contrast was backflow and no inlet was found, showing that the uterus and ovaries were not present. Examination of blood karyotyping analysis showed 46,XX chromosome. Chromosomes were analyzed by fluorescence in situ hybridization (FISH), and in the results showed XX chromosomes without Y chromosome.

The patient was then consulted to the urology surgery clinic. From the results of anamnesis, physical, and supportive examination, the patient was diagnosed with 46,XX testicular DSD with posterior hypospadias. The patient was then consulted to the child psychiatry for parental and patient assistance related to the decision to determine the gender assignment or parenting for the patient. After counseling and discussion, the parents agreed to take care of and raise the patient as a male. The patient then underwent surgery to repair posterior hypospadias with cordectomy and urethroplasty. Evaluation showed that penis size and testicular volume was

steady since the patient was 4 months of age, which was 2.8 cm in SPL and the volume of 1 mL on the right and left testes, so that 4-times testosterone injections were given for 4 months. The evaluation showed that the penis increased in size to 3.6 cm (3.8 cm - 5.4 cm) at strength penile length with the volumes of the right and left testis of 2 mL each. However, the parents informed that when the patient was urinating, the urine was seeping and dripping down. Thus, a reparative surgery was planned.

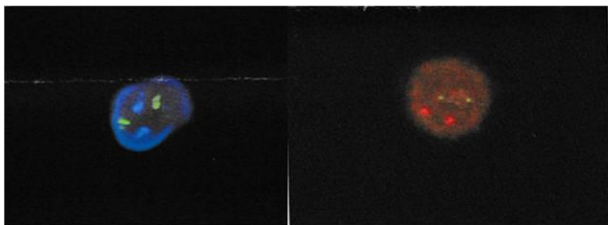


Fig. 2. Fluorescence in situ hybridization (FISH), Probe 13, 18, 21 and Y. Right: Probe X: green color indicates X chromosome. Left: 2 green dots show 2 chromosomes 13 and 2 red dots indicate 2 chromosome 21.

The patients' growth parameters of body weight, height, and head circumference using the 2007 WHO standard growth chart showed normal results. Development pre-screening to the patients who had been 24 months old using Prescreening Developmental Questionnaire (PDQ) showed questionable child development, so the test was followed-up with Denver II examination. The results indicated that the child had disrupted personal and social aspect. The parents received counseling and

accompaniment by a psychiatrist, and the child was also stimulated, which was practiced by the parents every day. The pediatric quality of live (PedsQL) assessment using PedsQLTM 4.0 parent report indicated low but increasing quality of life of the patient.

DISCUSSION

The initial diagnosis of 46,XX testicular DSD can be established based on genital abnormalities of phallus size, urethral meatus position, and pigmentation, supported by examination of testosterone levels, genital ultrasonography, genitography, gonadal biopsy, and karyotyping (Malone et al 2012). Patients with 46,XX testicular DSD are often accompanied by hypospadias but in a small number of cases may manifest as normal male genital. Examination of testosterone is done before and after injection of the hormone β HCG with various results, which can be normal or decreased. Genital ultrasonography aims to observe internal genital organ structures in the patient, such as the uterus, ovum, and testes. Genitography is an X-ray examination that aims to observe the genital tract by entering contrast through the penile or vaginal urethral meatus. Gonad biopsy aims for histopathological examination to determine the testes or ovum. Karyotyping is the chromosome examination focusing to the number and type of the chromosomes of the patient (Alves et al 2010, Rey & Grinspon 2011, Jurayyan et al 2013). Based on the results of examination of testosterone hormone, genital ultrasound, genitography, and karyotyping, the patient was diagnosed as having 46,XX testicular DSD. Diagnostic flow chart of 46,XX testicular DSD is shown in Fig. 3 (Ocal 2011, Ahmed 2011, Lee 2006).

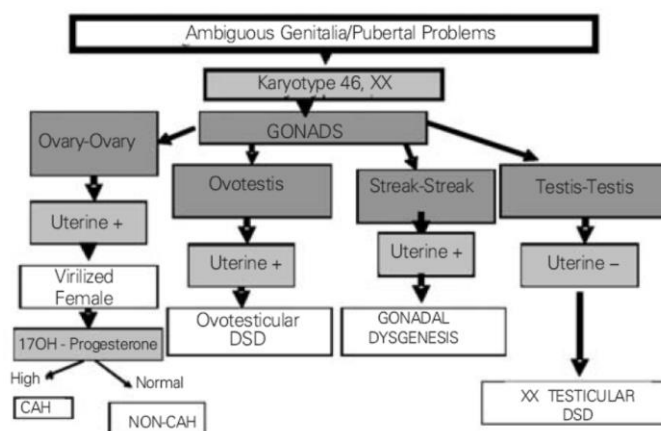


Fig. 3. Diagnosis algorithm of 46,XX testicular DSD with ambiguous genitalia. Source: Öçal G, Current Concepts in Disorders of Sexual Development. J Clin Res Ped Endo.2011; 3: 105-14.

SRY gene has an important role for gonadal bipotential differentiation into testes that encodes the sex-determining Y protein region. In most mammals, including humans, the Y-chromosomal master gene that controls testicular development is SRY. SRY gene is the gene which is mostly associated with the occurrence of 46,XX testicular DSD (Grinson & Rey 2015, Rajender et al 2006).

After the patient was diagnosed with 46,XX testicular DSD, the next step was to determine the gender assignment. Each patient should be evaluated individually with a multidisciplinary approach. Gender assignment should be performed after a complete diagnostic process, including clinical examination, genetic examination, biochemistry, and psychiatry. The whole procedure should be fully explained to the parents and they should take part in the discussions and decisions. The management of DSD children is primarily a gender assignment, decided by the family after obtaining complete information (Caroline et al 2010).

Patient management with 46,XX testicular DSD requires multidisciplinary collaboration, i.e. child endocrinology, child development, urologic surgery, psychiatry, and social work. Therapeutic approaches to the patient include sex assessment, sex rearing, hormonal treatment, surgical correction, growth monitoring, psychological condition and quality of life (Houk et al 2006).

Gender assignment aims to facilitate patients to obtain the best quality of life. Gender assignment should take into account the condition and development or the appearance of the genital organ, sexual function capacity, potential for fertility, family cultural background, parents' opinions and wishes, possible surgical options, and long-term hormone therapy (Caroline et al 2010, Kim 2012).

Based on the results of examination of external genitalia, laboratory, and radiology results, the patient anatomically had male genital organs. The patient has normal penis size, testicular volume, and testosterone level so that the patient was anatomically male. Both parents decided to educate and raise patients as male.

Gender assignment is related to dominant cultural and social factors. Genital disorders can bring stigma to the patient and his family. The role of gender may change at different levels of society, suggesting that social factors also alter gender roles. In children, the development of gender identity begins before the age of 30-36 months. Earliest age, when a child's gender identity can be assessed, has not been studied sufficiently. Currently, the age of 18 months is considered the upper limit of age for sex change but we should be cautious and

conservative observation is necessary (Schober et al 2012, Woodward & Neilson 2013).

Surgery can alleviate the suffering of the parents but there is still controversy about the optimal timing of genital surgery. Some experts say that the decision to correct genital abnormalities should not be done immediately and is more appropriate to delay the surgery until the patient is old enough to fully approve the intervention to be performed. However, there are also recommendations for genital surgery performed at age 2 and 6 months (Castagnetti & El-Ghoneimi 2010, Snodgrass et al 2011). Complexity and number of operations to be performed should be considered, and surgery itself does not always solve all problems. The agreement to conduct operations between both parents and the medical team who handle the patients should be done as soon as possible (Schober et al 2012, Woodward & Neilson 2013).

DSD patients in hypogonadal condition require hormonal therapy. Hormone replacement therapy is beneficial to bone health, preventing osteopenia and osteoporosis, initiating and maintaining the development of secondary sex characteristics and psychosocial development. Hormonal therapy should be considered and discussed with patients and families (Lee et al 2012, Goede et al 2011).

The evaluation of body weight, height, nutritional status and head circumference showed normal age-appropriate results according to the WHO growth chart standards 2000. Patients with 46,XX testicular DSD at the age of children and adolescents have normal growth parameters: body weight, height, and head circumference because hormonal conditions have not significantly affected the growth rate. In puberty hyalinization of seminiferous tubule will result in the missing spermatogonia. Therefore, despite having a normal penis size, the patient can be infertile. Hormone therapy can be started if clinical and laboratory examination show symptoms and signs of androgen deficiency (Vorona et al 2007, Warne et al 2005, Paramayuda et al 2012).

Studies comparing growth for the parameters of body weight and height between patient with 46,XX testicular DSD with normal male and female groups showed significant different in those parameters. The patient with 46,XX testicular DSD had lower body size. This may occur during puberty and young adulthood due to hormonal influence (Vorona et al 2007, Warne et al 2005, Paramayuda et al 2012).

Growth of penile and testicular size can be normal in childhood and early puberty. However, the size of the testis becomes abnormal in early young adulthood.

Testicular volume is determined by sertoli cells, in which during the onset of puberty the testicular volume increases progressively to 4 mL up to 6-8 mL due to sertoli cell proliferation. The function of sertoli and Leydig cells is normal in childhood and early puberty. However, testicular dysfunction occurs when the increase in testicular volume is determined by germ cell proliferation in puberty (Grinspon & Rey 2015, Warne et al 2005).

Holistic management of the patient also includes the spiritual aspect. Spiritual accompaniment should be given from early age. The patient had been taught to pray and study diligently since the age of 2 years. Both parents were very supportive and provided good examples in terms of spirituality. In the last decade, an increase in the number of DSD patients who were followed to adulthood indicated discontentment of gender assignments that may affect their quality of life (Schober 1999).

Clinical DSD management in Indonesia is full of challenges due to limited knowledge, diagnostic facilities and treatment. According to a study conducted by Ediati in 2015 in Semarang, it was found prior to her study that most DSD patients were not treated, raised with ambiguous genitals, and doubts about their gender. The study concluded that the percentage of patients who change gender is quite high. The desire for sex change is especially seen in patients with progressive masculinisation. It was mentioned that patients with ambiguous genitalia suffered from stigmatization. This condition and the presence of rejection results in reaction from those patients. Therefore, clinical evaluation, treatment, parenting education, and early self-acceptance teaching may be sufficient to help improving the quality of life (Ediati et al 2015).

CONCLUSION

Diagnosis of patient with 46,XX testicular DSD should be done as soon as possible. Most cases come with complaints of genital abnormalities. The management approach is individual and multidisciplinary. Upon an upright diagnosis, gender assignment is conducted by considering the influential aspects. Reparative surgery for genital abnormalities considers the age and growth of the patient. Testosterone injection is considered in hypogonadal state. Management of the patient with 46,XX testicular DSD has a long term characteristic. Monitoring of growth and development, as well as assessment of the quality of life of the patients and the parents, are important to do. The importance of group support, facilitation or follow-up to adult patients, and the possibility of long-term outcomes are needed in the

future, so that the patients and the parents need to be prepared. Assistance to the patients and the parents, including in psychological and religious aspects, is also required.

REFERENCES

- Ahmed SF, Achermann JC, Arlt W, Balen A, Conway G, Zoe L, et al (2011). UK guidance on the initial evaluation of an infant or an adolescent with a suspected disorder of sex development. *J Clin Endocrinol* 75, 12-26
- Alves C, Braid Z, Coeli FB, Mello MP (2010). 46,XX Male – testicular disorder of sexual differentiation (DSD): hormonal, molecular and cytogenetic studies. *Arq Bras Endocrinol Metab* 54, 8-10
- Anik A, Çatli G, Abaci A, Böber E (2013). 46,XX male disorder of sexual development: a case report. *J Clin Res Pediatr Endocrinol* 5, 258-60
- Caroline E, Creighton SM, Mushtaq I, Carmichael PA, Barnicoat A, Honour JW, et al (2010). Holistic management of DSD. *Best Pract Res Clin Endocrinol Metab* 24, 335-54
- Castagnetti M, El-Ghoneimi A (2010). Surgical management of primary severe hypospadias in children: systematic 20-year review. *J Pediatr Urol* 184, 1469-74
- Ediati A, Juniarto AZ, Birnie E, Okkerse J, Croix A, Wisniewski A, et al (2015). Gender change and stigmatization in late-treated Indonesian children, adolescent, and adult patients with DSD. *Inter J Pediatr Endocrinol* 56, 1-3
- Goede J, Hack WW, Sijstermans K, Voort-Doedens LM, Ploeg T, Meij-de Vries A, et al (2011). Normative values for testicular volume measured by ultrasonography in a normal population from infancy to adolescence. *Horm Res Paediatr* 76, 45-60
- Grinspon R, Rey R (2015). Disorders of sex development with testicular differentiation in SRY negative 46 XX individual: clinical and genetic aspects. *Karger* 10, 425-34
- Houk CP, Hughes IA, Ahmed SF, Lee PA (2006). Summary of Consensus Statement on Intersex Disorders and Their Management. *Pediatrics* 118, 753-7
- Houk CP, Lee PA (2010). Approach to assigning gender in 46,XX congenital adrenal hyperplasia with male external genitalia: replacing dogmatism with pragmatism. *J Clin Endocrinol Metab* 95, 4501-8
- Jurayyan NA, Mohamed SH, Babiker A M, Otaibi HM (2013). Radiological imaging of disorders of sex development (DSD). *Sudan J Paediatr* 13, 10-6
- Kim J, Kim KS (2012). Disorders of sex development. *Korean J Urol* 53, 1-8

- Lee JH, Ji YH, Lee SK, Hwang HH, Ryu DS, Kim KS, et al (2012). Change in penile length in children: preliminary study. *Korean J Urol* 53, 870-4
- Lee PA, Houk CP, Ahmed SF, Hughes IA (2006). Consensus Statement on management of intersex disorders. *Pediatrics* 118, 488-502
- Malone PS, Craggs MA, Mouriquand PD, Caldamone (2012). The anatomical assessment of disorders of sex development (DSD). *J Pediatr Urol* 8, 585-9
- Öçal G (2011). Current concepts in disorders of sexual development. *J Clin Res Ped Endocrinol* 3, 105-14
- Paramayuda C, kartapradja H, Ambarwati D, Anggaratri H, Suciati L, Marzuki N, et al (2012). Chromosome abnormalities in Indonesian patient with short stature. *Molecular cytogenetics* 5, 35-43
- Rajender S, Rajani V, Gupta N, Chakravarty B, Lalji S, Thangara K (2006). SRY-negative 46,XX male with normal genitals, complete masculinization and infertility. *Molecular Hum Reproduct* 12, 341-6
- Rey RA, Grinspon RP (2011). Normal male sexual differentiation and aetiology of disorders of sex development. *Best Pract Res Clin Endocrinol Metab* 25, 221-38
- Schober J, Nordenstro A, Hoebeke P, Lee P, Houk C, Looijenga L, et al (2012). Disorders of sex development: Summaries of long-term outcome studies. *J Pediatr Urol* 8, 616-23
- Schober JM (1999). Quality-of-life studies in patients with ambiguous genitalia. *J Pediatr Urol* 17, 249-52
- Snodgrass W, Macedo A, Hoebeke P, Mouriquand PDE (2011). Hypospadias dilemmas: around table. *J Pediatr Urol* 7, 145-57
- Tridjaja B, Marzuki A (2010). Disorder of sex development. In: Batubara J, Tridjaja B, Pulungan A, editor. *Buku ajar endokrinologi anak*. 1st ed. Jakarta, Badan penerbit IDAI, p 43-72
- Vilain EJ (2009). 46,XX testicular disorder of sex development. NCBI bookshelf A service of the National Library of Medicine, National Institutes of Health
- Vorona E, Zitzmann M, Gromoll J, Andreas N. Schüring, Nieschlag E (2007). Clinical, endocrinological, and epigenetic features of the 46,XX male syndrome, compared with 47,XXY Klinefelter patients. *J Clin Endocrinol Metab* 92, 3458-65
- Warne G, Grover S, Hutson J (2005). A long-term outcome study of intersex conditions. *J Pediatr Endocrinol Metab* 18, 555-67
- Woodward M, Neilson A (2013). Disorders of sex development. *Paediatr surgery II* 31, 12-7