

PCI IN PATIENT WITH HEAVY CALCIFIED LESION. MANAGEMENT AND BALLOON RUPTURE COMPLICATION

Yudi Her Oktaviono

Department of Cardiology and Vascular Medicine,
Faculty of Medicine, Universitas Airlangga,
Dr Soetomo Hospital, Surabaya

ABSTRAK

Angioplasti balon pada kalsifikasi lesi koroner dapat mengalami penurunan angka keberhasilan dan peningkatan insiden komplikasi. Lesi ini masih merupakan tantangan teknis di bidang kardiologi intervensi meskipun terdapat pendekatan dan perangkat yang baru. Kami menjelaskan kasus kalsifikasi lesi koroner berat pada LAD yang tidak hanya resisten terhadap inflasi tekanan tinggi balon non-compliant konvensional, dan balon terpotong, namun juga inflasi yang mengakibatkan balon pecah. Bahkan, balon pertama mengalami fraktur dan terjebak dalam LAD. Balon yang fraktur dapat diambil dengan menggunakan inflasi baloon kedua pada LCX. Angioplasti balon berhasil dilakukan setelah aterektomi rotasi dengan rotablator dan berhasil dilanjutkan dengan pemasangan stent DES. (FMI 2015;51:257-267)

Kata kunci: lesi kalsifikasi berat, ruptur balon, balloon entrapment, gagal angioplasti, aterektomi rotasional

ABSTRACT

Balloon angioplasty in calcified coronary lesions may have a decreased success rate and an increased incidence of complications. This lesion remain a technical challenge in interventional cardiology despite novel approaches and devices. We describe a case with heavy calcified coronary lesion in LAD that was not only resistant to high-pressure inflation of conventional, non-compliant balloons and cutting balloon but the inflations also results in balloon rupture. Even, the first balloon became fracture and entrapment in LAD. The fractured balloon could be removed using second baloon inflation in LCX. The angioplasty balloon was successfully performed after rotational atherectomy by rotablator and succesfully continued by implantation stent DES. (FMI 2015;51:257-267)

Keywords: heavy calcified lesion, balloon rupture, balloon entrapment, failed angioplasty, rotational atherectomy

Correspondence: Yudi Her Oktaviono, Department of Cardiology Dr. Soetomo Hospital, Jl. Mayjen Prof. Dr. Mustopo 6 – 8, Surabaya, East Java, Indonesia. Phone: 62-31-5501701. E-mail : yhoktaviono@yahoo.com

INTRODUCTION

Treatment of coronary artery disease (CAD) using a catheter has advanced substantially over more than 40 years since Andreas Grüntzig's action of percutaneous transluminal coronary angioplasty or PTCA in humans for the first time. Currently the intervention using percutaneously catheter (percutaneous coronary intervention/PCI) is a therapeutic option that is safe, reliable and effective for millions of CAD patients worldwide (Baber et al 2010, Kern 2013). The application of PCI in patients with CAD continues to grow. The latest data showed a clinically balanced between PCI action and coronary artery bypass surgery (CABG) in complex coronary lesions (Baber et al 2010).

Coronary lesions with calcification or calcified lesions is a common phenomenon in CAD (Farman et al 2011). Coronary lesions is defined as any form of calcium that seemed to be on target of vascular angiography (Nguyen et al 2003). Calcified lesion is one form of complex

lesions (Baber et al 2010). Estimates of the prevalence of calcified coronary lesions in patients who will run the PCI range from 1.7%, while in the randomized trial study to 35% at the real population (Baber et al 2010). The existence of coronary calcification is a marker of significant CAD and increases long-term mortality. Coronary lesions is not a PCI homogeneous lesion and its response varies based on the severity of calcification (Levine et al 2011).

Heavy calcified lesions respond quite poorly to the actions of balloon angioplasty (Levine et al 2011). Coronary lesions that have become resistant to the coronary blood vessel lumen becomes difficult to be widened (Farman et al 2011). In fact, predilatation with balloon is required to make adequate lumen size before stenting (Asakura et al 1998). Typically, normal-sized conventional balloon is sufficient to dilate the target blood vessel, although sometimes necessitates inflation with high pressure (Asakura et al 1998). Because it is a complex lesions, the success of PCI in these lesions

action requires sophisticated engineering, specialized approach or tools (Baber et al 2010, Teirstein et al 2007). PCI action results in these lesions are usually suboptimal because only 24% of cases reach 90% of recommended cross-sectional lumen area (Nguyen et al 2003). In addition, this action will frequently encounter complications such as balloon rupture, catheter breakage, and both can be trapped inside the coronary, coronary artery dissection and perforation, and under-expanded stents (Levine et al 2011, Asakura et al 1998).

Here we report a case of coronary lesions with severe calcification where high pressure inflation using conventional angioplasty balloon and balloon cutting failed to dilate blood vessels lumen and even the balloon became ruptured. PCI procedure in the patient was successfully performed up to the stenting placement, starting with the rotational atherectomy.

CASE REPORT

A patient, Mr. AM, male, age 55 years, with a history of specific complaints of chest pain spreading to the left of the left shoulder repeatedly, especially when during an activity, sometimes accompanied by cold sweats. Chest pain disappears when the patient is resting or drinking ISDN since 1 year before admission with shortness of breath when walking and pushing his carts since 3 months prior to the admission. He visited the hospital for elective PTCA. Past medical history of the patient, he suffered from hypertension since 1 year, smoked for \pm 40 years, now sometimes still smoking. quitted from alcohol drinking 20 years ago. He had high levels of cholesterol and uric acid, denied suffering from diabetes. Patients had been treated in the ICCU of a heart attack and pulmonary edema, then underwent cardiac catheterization a year before admission. Since the heart attack the patient routinely visited in Heart Clinic, with the last therapy with 1x100 aspilet, 1x20 mg simvastatin, 3x5 mg isosorbide di nitrate, 3x25 mg captopril and 1x20 mg furosemide. Family history, the patient's father died suddenly at the age of 62 years.

The physical examination upon arrival at the hospital revealed good general condition, blood pressure 140/90 mm Hg, pulse frequency 70x/min and frequency of breathing 18x/min. The results of a physical examination of the heart was not enlarged, murmur negative, and extra systole negative. In lung examination, vesicular breath sounds did not reveal ronchi or wheezing. From extremity examination, edema was not found.

Electrocardiographic examination revealed sinus rhythm 69x/min normal axis. The images of the thorax showed heart shape and size was still within normal limits. From

the results of laboratory tests: hemoglobin 15.1 g/dL, leukocytes 7,800/ μ L, platelets 256,000/ μ L, BUN 10 mg/dL, serum creatinine 0.8 mg/dL, potassium 4.5 mMol/L, sodium 135 mMol/L, glucose 108 mg/dL, cholesterol 170 mg/dL, triglycerides 130 mg/dL, HDL 41 mg/dL, LDL 107 mg/dL.

The results of echocardiography showed mitral-valve regurgitation was mild; normal chamber dimensions with LVIDd 4.3 cm; left ventricular systolic function was normal (ejection fraction/EF by Teich 62% and by Biplane 59% but the diastolic function of the left ventricle disturbed while the systolic function of the right ventricle normal. Analysis of segmental left ventricular obtained hypokinetic in anteroseptal (basal-mid) and inferoseptal (basal-mid) segments and also concentric hypertrophy of the left ventricle (LVMI 107.15 gr/m²).

Then the patients performed coronary angiography with the result: Left Main Artery (LMCA): normal; Left Anterior Descending Artery (LAD): irregularities of the proximal-distal with critical stenosis in the mid and proximal LAD; Left Circumflexia Artery (Cx): Critical stenosis in bifurcatio Cx-2-Obtuse Marginal artery (OM2), collateral of Cx to right coronary artery (RCA), RCA: CTO at mid before the branch RV (Figure 1-4).

We performed percutaneous transluminal coronary angioplasty (PTCA) in the LAD. This action used a 7F sheath femoral artery with a catheter guide (GC) Judkins Left Curve (JL) 4.0 7Fr which engaged into ostial Left Coronary Artery (LCA). PTCA begins with the inclusion of guidewire (GW) to LAD, using runthrough NS hypercoat wire. The patient was given intravenous heparin 7500 IU. The balloon BRIO size 2.5x20 mm (type monorail, semi-compliant) was inserted, Nominal Pressure (NP) 6 atm, Rate Burst Pressure (RBP) 14 atm, Average Burst Pressure (ABP) 22 atm to LAD, then it was inflated up to 8 atm for 20 seconds (8/20) and 8/12 in Mid LAD, because once being inflated for the second time, the balloon did not expand perfectly, so after 12 seconds it was immediately deflated. But the balloon did not deflate perfectly, so we tried to inflate the balloon with higher and longer pressure 18/24, 20/14, 20/15 with the hope to enhance perfect balloon deflation (Figure 5, 6).

After being developed to a pressure of 20 atm, balloon ruptured or bursted. When it was drawn into the GC, the balloon separated into two parts, the distal end of the balloon remained in proximal LAD and its proximal end was in GC. Various strategies had been attempted so that residual fractions of the balloon caught up in the coronary arteries could be removed: with a deep seat of GC while rotating slightly, pushing forward-backward

and pulled the balloon gently; by linking the second wire with the first wire with the intention to attract the distal end of the first wire-distal from the remaining balloon fractions and buddy balloon and techniques was applied, but the second wire was hard to get into the LAD.

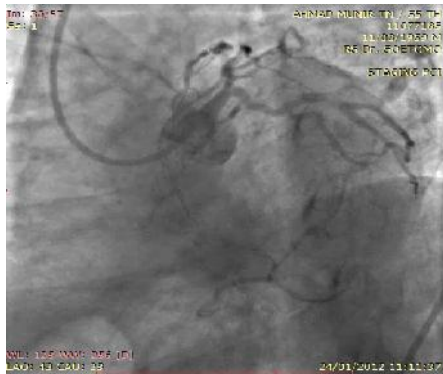


Figure 1. LAO-CAU projection: left main

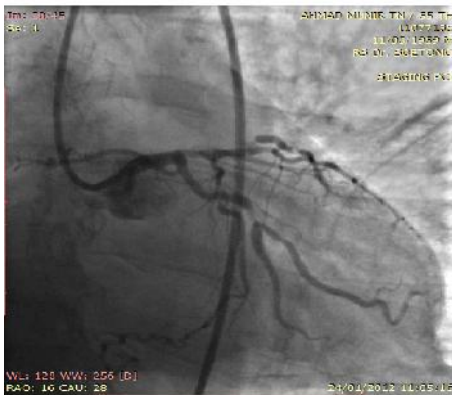


Figure 2. RAO-CAU projection: LCA

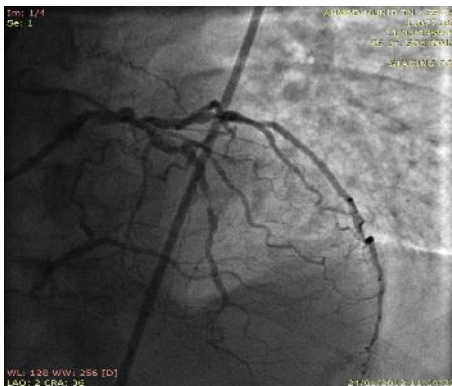


Figure 3. AP-CRA projection: LCA

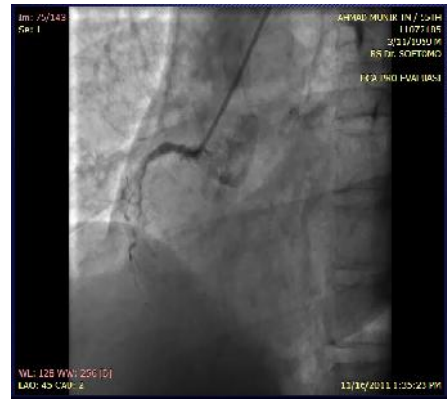

Figure 4. LAO projection: RCA

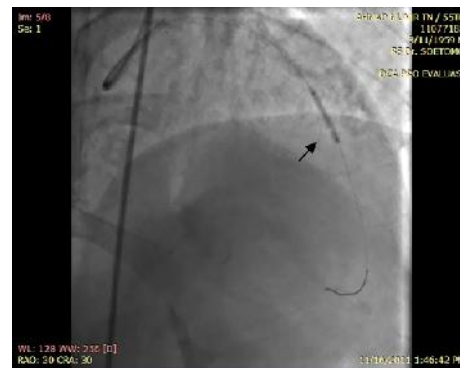

Figure 5. Brio balloon in mid LAD

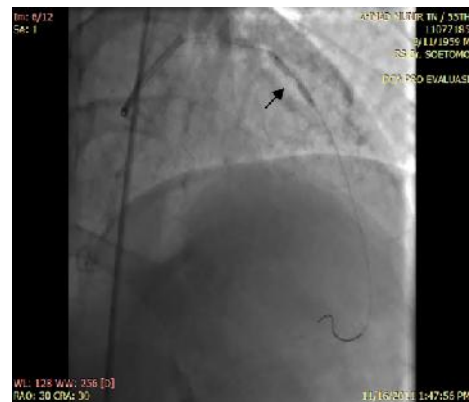

Figure 6. Brio balloon in prox-LAD (dog-bone shape)

Finally, the distal portion of the balloon was successfully drawn in GC in the following way: the second GW (runthrough hypercoat) entered the LCX accompanied with Maverick balloon sized 1.5x15 mm (small profile, monorail type, one radioopaque marker, NP 6atm, RBP 12 atm), which was then inflated in ostial-proximal Cx, at 16/15, and 12/25; in conjunction inflation of the balloon in Cx, so the ruptured balloon stucked in LAD

was drawn quickly with a little beat, so that the rest of the balloon in the LAD was retractable into GC. During this procedure we found no complaints, no life-threatening ECG profile or hemodynamic changes. The blood flow in the LAD was still good. (Figure 7-10).

Balloon angioplasty procedure was followed with the use of Pro-HP Balloon size 2.5x15 mm (type monorail, high pressure, steady compliant, NP 6 atm, RBP 18/20 atm, ABP 24/26 atm) from the mid to proximal, inflated by pressure for 20/9, 24/15, 12/10, 10/5, 8/4, 20/12, and 20/15 each. The balloon once again was unable to be inflated maximally (dog-bone shape) and ruptured when inflated in the proximal LAD. Later PTCA in proximal LAD was followed in turn by using Cutting Balloon Flextome size 2.0x10 mm (type monorail, nominal size 6 atm, RBP 12 atm) inflated by the pressure of 6 atm for 27 seconds and 5 atm/40 sec. Quantum Maverick Balloon size 2.5x12 mm (type monorail, non-compliant balloon, NP 12 atm, RBP stent 18 atm, RBP 20 atm) was inflated by the pressure of 8-24 atm for 8-30 minutes, repeated by Cutting Balloon Flextome size 2.25x10 mm with a pressure of 12 atm for 13 seconds and followed by Quantum Maverick Balloon size 2.5x12 mm with pressure/for 8/5, 22/20, and 23/10 each, still in the proximal LAD. Each balloon failed to inflate maximally and ended with the damage in the structure of the balloon.

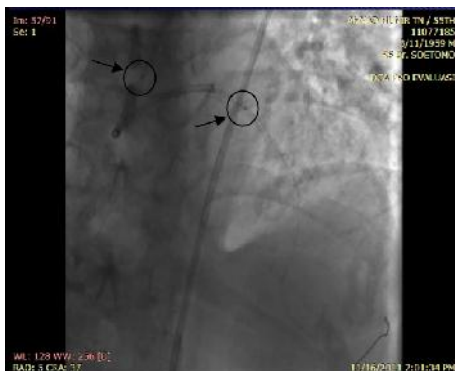


Figure 7. Brio balloon ruptured, distal part entrapped in LAD, proximal part in GC (arrow)

PTCA procedure was declared a failure and lesions in the LAD lead to a conclusion that there was high calcified lesion from proximal LAD. Four weeks later, PCI was repeated in LAD started with rotational atherectomy. This used the femoral artery sheath 7F with GC Extra Back-Up (XBU) 3.5 7Fr which engaged into ostial LCA, then an attempt was made to insert GW into LAD, using wire rotablator. The patient was given 5000 IU intravenous heparin. Furthermore,

rotablation was done from mid-proximal LAD using rotablator burr 1.5 mm at a speed of 190,000 RPM 3x (Figure 11).

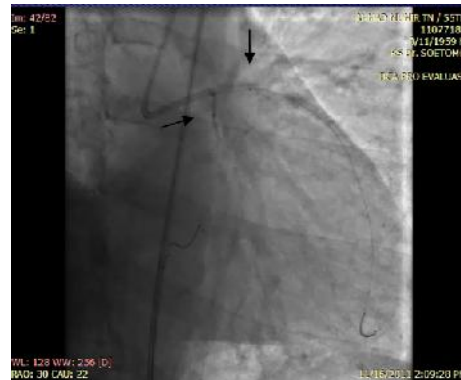


Figure 8. Attempt to withdraw distal part of Brio balloon entrapped in LAD with mild dilatation of the second balloon in prox LCx.

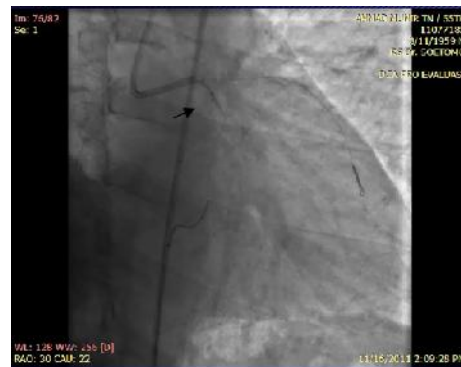


Figure 9. Remains of distal part of Brio balloon successfully retracted into GC.

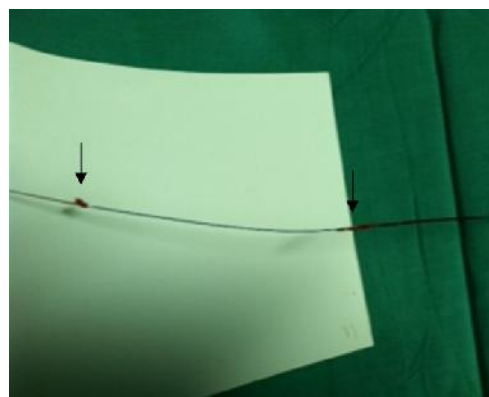


Figure 10. Separated distal and proximal end of Brio balloon

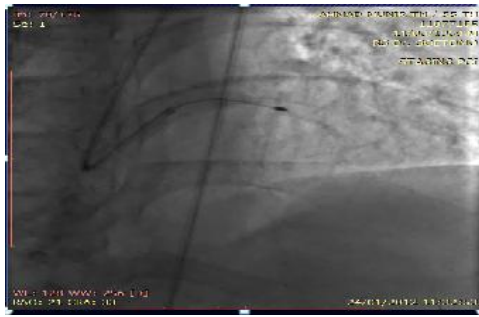

Figure 11. Rotational atherectomy with rotablator

After that, with the help of fine cross microcatheter, Pro-HP Balloon 2.0x15 mm was inserted into mid-distal LAD, inflated from 16 atm to 20 atm. Because the balloon could not be fully inflated, it was decided to do rotational atherectomy again in mid LAD using rota-

blator burr 1.5 mm at a speed of 185,000 RPM as 1x, followed by re-entering floppy wire II and the support from microcatheter for carrying out PTCA using Pro-HP Balloon 2.0x15 mm to mid LAD inflated at 18 atm. This was continued by using Cutting Balloon Flextome size 2.5x10 mm inflated in the mid-distal LAD with 14-16 atm pressure as much as 5x, for nearly one minute for each inflation time. The patient was given with intravenous heparin 5000 IU. Finally PTCA was terminated by installation of Drug Eluting Stents (DES) Promus Element (everolimus) 2.5 x 38 mm to mid-distal LAD, which was dilated with a balloon stent until the pressure of 10 atm and post-dilatation with a pressure of 18 atm (Figure 12). The patient was also given with intracoronary nitrate 1 mg. PCI results was good with 0% residual stenosis (Figure 13). The patient was planned for PCI staging in proximal LAD and LCX 2 weeks later.

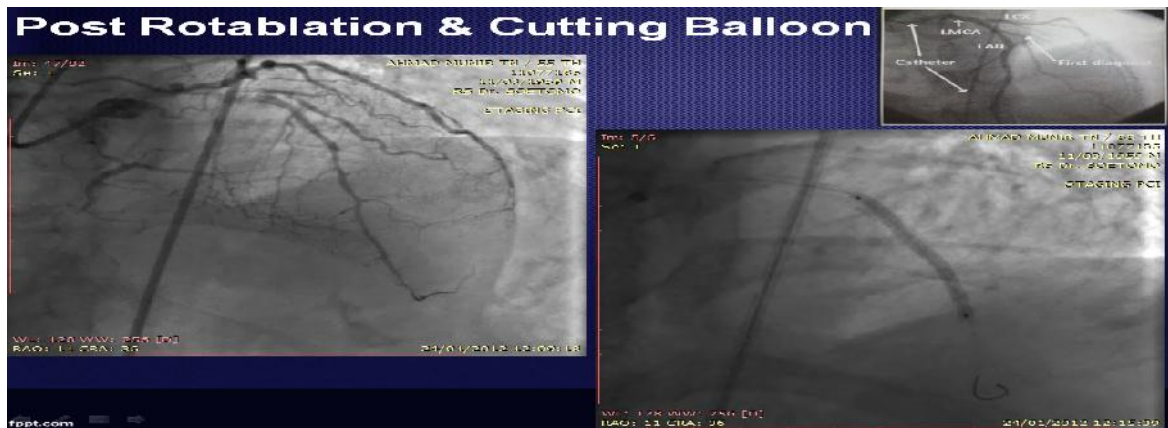


Figure 12. Outcome after rotational atherectomy - cutting balloon - during balloon stent inflation

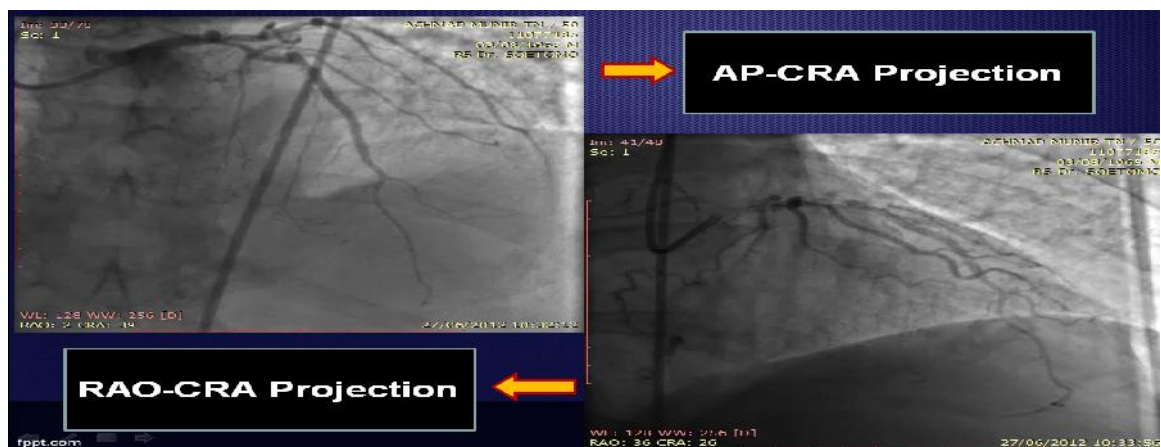


Figure 13. Outcome after stent placement

DISCUSSION

Percutaneous transluminal coronary angioplasty (PTCA) is a procedure that is relatively safe and effective to relieve myocardial ischemia (Soylu et al 2006). This procedure actually uses a miniature balloon which is inflated and expanded inside coronary arteries, pressing the plaque into the arterial wall and cracked the wall in order to expand narrowed blood vessels so that the blood can flow (Cleman 1992) and the size of the blood vessels is enough for stenting (Kern 2013).

Balloon rupture is a rare complication during PTCA, only about 4% of the entire intracoronary procedure. Although balloon rupture is not considered a significant problem during angioplasty, some serious complications can occur, such as coronary perforation, air embolism, dissection and balloon and wire are caught up in the coronary arteries, and even death. Repeated rupture of the balloon is likely due to the morphology of the lesion, particularly calcified lesion (Gilutz et al 2000, Breisblatt 1993). One drawback of using an angioplasty balloon is dilatation of calcified stenosis (Breisblatt et al 1993), wherein the success rate of the angioplasty procedure is low (Gilutz et al 2000). High pressure (> 15 atm) of the balloon is required when calcified lesion is being dilated, thus caused rupture of the balloon (Breisblatt 1993, Siddiqi et al 2013). Balloon trapped inside coronary arteries is one further complications of balloon rupture, which should be removed before further complications may take place, such as thrombosis, coronary artery embolization or perforation (Soylu et al 2006). So it is important for the operator to pay attention to NP and RBP of the balloon used when inflation is taking place (Bonzel et al 2012).

In general, the balloon is designed that when the rupture causes longitudinal tear it will not cause significant problems. Circumferential balloon ruptures are rarely reported. But if this is the case, it will have serious effects. In previous cases, there were reports on balloon that being trapped between coronary artery catheters. Balloon is rarely trapped before rupture and it is difficult to be deflated between lesions. One case of circumferential balloon rupture showed that the position in the middle of the lesion is an important factor of balloon entrapment in blood vessels and cause difficulties during deflation of the balloon in distal portion (Breisblatt 1993). In this condition it is advised to re-inflate the balloon with prolonged with higher pressure. sometimes this can solve the problem so that the balloon can be deflated completely before being pulled out of the coronary (Bonzel et al 2012).

The patient in this case showed irregularities in the LAD with critical lesions in the mid and prox. Then we

carried out balloon angioplasty in mid LAD using semi compliant balloon. Having inflated with pressure slightly above NP the balloon remained not fully inflated (waist balloon was still there) even after deflating the deflation was not perfect. Then the balloon was attempted to be inflated with a higher pressure than RBP with the effect that the balloon ruptured even splitted into two parts. The balloon distal portion was stuck in the proximal LAD.

The conventional approach to this complication include the use of snare percutaneously or emergency open heart surgery (Soylu et al 2006, Shantanu 2011). Other strategies to free the trapped balloon is trying to inflate and deflate the balloon alternately with a gentle push and pull the balloon forward and backward with a slight twisting motion, deep seated from GC, using a second wire for gaining the first wire. The second strategy and technique is buddy balloon that has a goal to stretch and straighten the coronary artery where the balloon is trapped. The latter is a surgical strategy if all the non surgical interventions failed. In this non-surgical procedure the evaluation of the possibility of perforation and dissection of the coronary arteries should also be monitored (Cleman 1992, Shantanu 2011, Sánchez-Recalde et al 2008).

In this patient, the distal part of the balloon caught in the proximal LAD was sought to be drawn into GC. However, of the strategies mentioned above none of them managed to reach the trapped balloon part in the LAD. Finally, the distal portion of the balloon was retractable into GC with second balloon technique inflated by high pressure in the proximal ostial LCX. The second balloon was used like a kind of an anchor in Cx.

Repeated failure to inflate the balloon perfectly, in which balloon waist was still visible (dog-bone shape) and ruptured, is associated with resistance of coronary lesions. One of the causes of coronary lesions resistance (lesions that are difficult to be dilated) is calcified lesions. Resistant coronary lesions itself is a challenge in the world of modern angioplasty (Teirstein et al 2007, Bertrand et al 1997). The process with which balloon can cross the lesion and carrying out predilatation and ended with stenting provides a challenge to the skills and experience of the operators who handle heavy calcified lesions, since the lesion is accompanied by highly angulated lumen and resistance to dilation (Bonzel et al 2012). The presence of calcium makes blood vessels become so rigid that the stent inflation was not optimal and this condition may increase the risk of stent thrombosis and restenosis despite using drug eluting stent (DES) (Ahn et al 2009). Direct stenting in severe calcified lesion is not recommended because it

led to imperfect inflation of the stent, so the potential complications may occur (Siddiqi et al 2013).

Calcified lesion is one form of complex lesions, defined as any form of calcium that seemed to be on target of vascular angiography (Asakura et al 1998, Kern 2013). Depth calcifications based angiography are divided into mild, moderate and severe. Calcification is said to be mild if the movement of the heart is required to view calcium. Moderate calcification is clearly visible when the calcification is without cardiac motion (Nguyen et al 2003). Meanwhile, a certain characteristic of severe calcification is when density appears between plaque when fluoroscopy is still running, especially if there is a radiopacity profile that does not require movement of the heart before the contrast injection (Farman et al 2011).

Routine diagnostic angiography is sensitive enough to detect lesions calcium wider and less sensitive for detecting calcifications lighter. Intravascular ultrasound (IVUS) is more sensitive in detecting calcified coronary lesions. Unknown 11% calcium lesions visible via angiography was not calcified lesion by IVUS. Angiography is also not able to decipher the structure of intravascular, especially if there is damage or rupture of the balloon used repeatedly during the action PTCA (Gilutz et al 2000). Through IVUS we can evaluate the curvature of calcium (<90°, 91-180; 181-270; 271-360° or circumfrensial); length of calcium (< 5 mm; 6-10; ≥ 11) and the location of calcium (superficial, deep, mix) (Freed & Safian 2011).

In the patients, their coronary lesion has known to be severe calcified lesion only after a failed act of balloon angioplasty. Balloon used during action (brio-semi-compliant balloon, balloon proHP- high pessus, Quantum maverick-non compliant) damaged/ruptured even, cutting ballon cannot widen the target coronary lesions. During diagnostic angiography, the calcified lesions in this patient with was not detected. During the evacuation process, we found no hemodynamic complications or rupture and coronary dissection.

Evaluation of the size and depth of the calcified lesions prior to intervention is very important (Suzuki 2003). Other initial evaluation required in calcified lesion involves three factors, namely, first, the location of the lesion, which is associated with left main, coronary ostium, large side branches (bifurcation); blood vessels graft, large or small blood vessels. Second, angiographic characteristics, severity of calcification; vessel tortuosity; length of calcified lesions; eccentricity of the lesions. Third, the patient characteristics that affect the risk of additional procedures, hemodynamically unstable patients, decreased ejection fraction, recent suffering from an acute myocardial infarction (thrombi).

Selection of intervention tools and strategies used in calcified lesions depends on those three factors. After calculating the above variables, intervention usually begins with the use of balloon-based tool then continued with rotational atherectomy only if inadequate expansion of dilated balloon is found (Nguyen et al 2003, Teirstein et al 2007) (Figure 14).

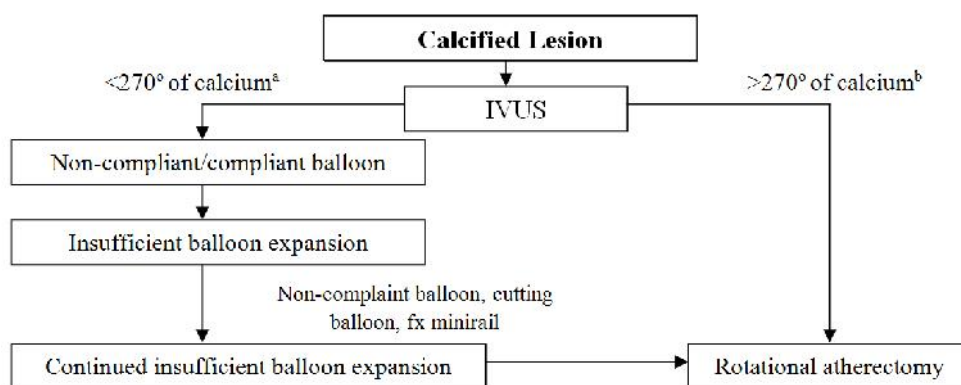


Figure 14. Algorithm of calcified dan undilatable lesion management (Teirstein et al 2007)

Notes (Suzuki 2003):

- a. Coronary artery diameter >2.5 mm, deep calcified lesion or superficial calcified lesion & = 90°
- b. Coronary artery diameter = 2.5 mm or >2.5 mm, superficial calcified lesion & >180° or combination between deep calcified lesion & superficial calcified lesion.

Suzuki (Soylu et al 2006) divides calcified lesion intervention by the diameter of the target coronary arteries (angiography or IVUS). If the size coronary of arteries is small (≤ 2.5 mm) and the lesions are mostly calcified, then we can directly use rotational atherectomy with rotablator approach to erode calcification. However, if the coronary artery diameter > 2.5 mm we must see the calcification first. If the calcification is superficial $\leq 90^\circ$, the balloon may be used, even cutting balloon is quite able to dilate the lesion. If the calcification is superficial and $> 180^\circ$ (severe calcification), then rotablator be the first choice. If the calcification of the coronary arteries turns out to be deep of > 2.5 mm, the use of balloon angioplasty often able to dilate blood vessels entirely targets (Suzuki 2003). Therefore, ideally we should do an evaluation by angiography and IVUS before intervention to get a detailed picture of the lesion (Nguyen et al 2003, Teirstein et al 2007, Suzuki 2003). There will always be cases where IVUS catheter cannot pass through calcified lesions due to severe stenosis or catheter tip suppress solid part of the lesion. In this case we are forced to rely solely on angiographic information (Suzuki 2003) (Figure 15).

In these patients, calcified lesion was located along prox-mid LAD, did not involve left main, ostial LAD and not in bifurcation, severe calcification, hemodynamically stable patients, involving LAD blood vessels, roughly the size of ± 2.5 mm (size LAD almost equal to the big GC 7F, brio balloon diameter of 2.5 mm can pass the LAD).

Balloon angioplasty

First, the lesion is subjected to predilatation before stenting or stenting in percutaneous old balloon angioplasty (POBA). If the lesion can be dilated then stenting can be performed. Most lesions with mild calcification respond to this action (Nguyen et al 2003). Balloon angioplasty trial is done to ensure the potency

of the blood vessel lumen with an expanded lesion (Teirstein et al 2007). Usually initially we use longer balloon with a diameter of 2.5 mm that is inflated in a few seconds and the high pressure is applied in the area of stenosis. Pre-dilatation in calcified lesions are required to use a larger balloon to ensure the opening of the stenosis prior to stenting (Bonzel et al 2012).

The classical approach to dilate calcified lesions including high-pressure balloon inflation, will prolong the process of inflation, using a balloon larger size. When the lesion cannot be dilated, an alternative technique is to use the buddy wire dilatation with one or two GW placed beside a conventional balloon catheter inflated by high pressure, which functions as if cutting balloon to break down plaque. Another way to hugging balloon technique is to inflate two balloons at a time with two wires on the lesion with critical stenosis, using the pressure of 12 atm respectively. Based on research Kanh et al, most lesions can be dilated with pressure below 10 atm (Bertrand et al 1997). In lesions that potentially could be dilated, the choice of balloon used: non-compliant balloon, balloon and fx minirail cutting balloon (Teirstein et al 2007).

Non-compliant balloon

This balloon type uses high pressure with localized force a without excessively inflated so that it can control the localized plaque cracks and dissection. balloon Early inflation with high-pressure still produces less expansion. In such cases, inflation will be longer (according to the patient's tolerance) and pressure equivalent to the RBP can provide maximum balloon expansion. While in the process, the operator must be vigilant if balloon inflation is at a higher pressure than RBP, although sometimes the lesion has been success-fully dilated, but the possibility of complications, such as rupture of the balloon, dissection or perforation and coronary embolism, may occur (Teirstein et al 2007).

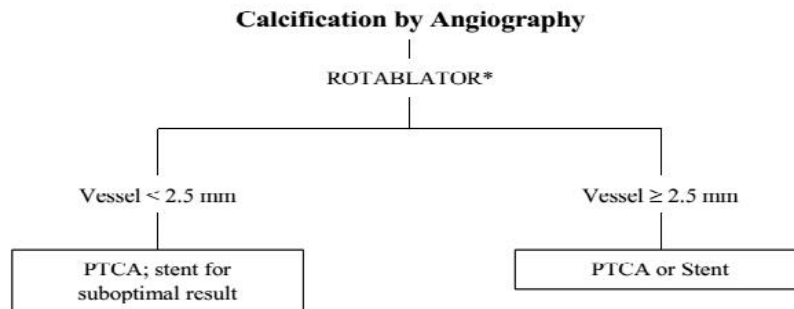


Figure 15. Algorithm treatment of calcified lesions when IVUS is not available (calcification appeared during angiography = severe calcification) (Freed & Safian 2011)

Balloon angioplasty stenosis with severe calcification can lead to the withdrawal of the normal vessel wall that dissection or rupture may occur in the border area and the elastic calcified stenosis (Siddiqi et al 2013). In addition, the lumen enlargement suboptimal mechanism is including the inability to dilate the lesion and elastic coil phenomena. Because of the necessary of high pressure balloon inflation on the lesions, there is a risk of balloon rupture and dissection (Freed & Safian 2011).

Cutting balloon

If the lesions are resistant to high-pressure balloon inflation, we can use cutting balloon. The balloon is made up of three to four microblades (depending on the size of the balloon), longitudinally attached to the balloon, serves to print the plaque after balloon expands. Microtomes are 3-5 times sharper than conventional scalpel. Through the basic mechanisms of stress fracture, Microtomes 3-5 times sharper than a scalpel with a force that can be scaled according to the size balloon 200000-400000 times, can make the plaque cracks. This tool is not recommended for use on tortuous lesions, eccentric lesions, calcified lesions partially because the risk of arterial dissection and perforation which microblade can injure healthy blood vessel walls. Cutting balloon can also be used in predilatation before stenting (Teirstein et al 2007, Cleman 1992, Bertrand et al 1997, Bonzel et al 2012).

Rotablator

Several new technologies have been used in the treatment of calcified lesions. The new most technique effective is rotational atherectomy. Nevertheless, in some cases the use of the new technology still requires additional balloon angioplasty (Bertrand et al 1997, Pedersen et al 2003). This technique is done if it is found lesions in the distal segment, while the proximal segment shows heavy calcification and tortuous (angulation of > 60 degrees), where the cutting balloon difficult to achieve (Nguyen et al 2003) as well as in the event of a failure to act balloon angioplasty (Teirstein et al 2007). Rotablation is suggested as the primary intervention measures in lesions with severe calcification (Nguyen et al 2003). Based on ACCF/AHA/SCAI practice guideline for PCI, the procedure belongs to recommendation grade IIa and LOE C, while based on the last guideline the European Society of Cardiology for myocardial revascularization, it is included in recommendation grade IC, if the lesion with severe calcification cannot be penetrated by balloon catheter or lesion cannot be adequately dilated before stenting action (Kern 2013, Hellig et al 2012). This procedure

has a success rate of >90% with the incidence of complications of <5% in overcoming calcified stenosis (Freed & Safian 2011, Hellig et al 2012).

Rotablator consists of a rugby ball shaped burr or almonds in size from 1.25 to 2.50 mm, made of stainless steel where the surface is plugged into a rock-cut diamond with a diameter of 30-120 microns. To be able to function, burr connected with the control shaft rotating at high speeds 140000-200000 rpm. Usually the use of burr starts with a size of 1.5 mm is increased to 1.75 mm in accordance with the size of blood vessels and GC were used. Starting rotation speed used was 150,000 rpm for 15-20 seconds, while the evaluation of the deceleration (drop in rotation speed > 5000 rpm) which allows the occurrence of complications dissection, perforation and trapping burr. This procedure aims to dilate the vessel lumen by way erode or remove atherosclerotic plaque clogging, improve compliance plaque, making it easier balloon mendilatasi lesions and expansion of the stent. However, this action enables the microcirculation disorders due to embolization of plaque debris, platelet aggregation or vasospasm (Teirstein et al 2007, Ahn et al 2009, Hellig et al 2012).

In these patients, severe calcified lesions was known after failed balloon angioplasty. So the management of calcified lesions in these patients was according to the flow of calcified coronary lesions if evaluated by IVUS calcification arc <270 degree. It was started using brio balloon 2.5x20 mm- size semi compliant that has failed to dilate perfectly even rupture. Then we used high-pressure Pro-HP balloon which also failed to dilate perfectly and damaged. Furthermore, we used Quantum non-compliant maverick balloon with the same result, failed to dilate perfectly and broken until finally we used flextome cutting balloon that could be dilated perfectly but the coronary stenosis remains resistant. Finally, the intervention of calcified lesions succeeded in widening LAD prox-mid coronary blood vessels assisted with rotational atherectomy procedure with balloon angioplasty followed with rotablator with cutting balloon flextome.

Adjuvant PTCA (using non-compliant balloon) or stenting action often produces lumen enlargement without dissection (Bertrand et al 1997). Stenting or simply PTCA alone after rotablation or not depends on the location of calcified lesion in or superficial and depends on the size of the lumen of a coronary artery intervention (Freed & Safian 2011). (Figure 16) Rotational atherectomy followed with DES stenting could significantly reduce the incidence of restenosis (Hellig et al 2012).




Figure 16. Algorithm of treatment of calcified lesions stenting or just PTCA (Freed & Safian 2011)

In this patient, due to stenosis in coronary artery lumen LAD was successfully widened, so stenting could be performed and DES stenting could be installed perfectly after predilatation and post-dilatation in mid-distal LAD with residual stenosis of 0%.

CONCLUSION

A man with a history of stable angina pectoris and risk factors of smoking, alcohol, hypertension, and dyslipidemia had been treated with results of diagnostic coronary angiography demonstrated triple vessel disease with a CTO in RCA, irregularities in the LAD with critical lesions in the mid and prox and obtained critical LCX lesion in bifurcation Cx-OM2. LAD lesion was found to be a highly calcified lesion of pro-mid after a failure of PTCA in which the balloon catheter (semi-compliant, non-compliant, cutting balloon) used repeatedly failed to inflate, even when the initial balloon angioplasty was performed, it became ruptured and fractured into two pieces and its distal end was trapped within the LAD. Finally, the distal portion of the fractured balloon was retractable to GC with the second balloon technique used as anchor in Cx and LAD intervention was succeeded with the help of rotational atherectomy procedure with rotablator and stenting with DES.

REFERENCES

Ahn MS, Yoon J, Lee JW, Lee KH, Kim JY, Yoo BS, Lee SH, Choe KH (2009). Effectiveness of the hugging balloon technique in coronary angioplasty for heavy, encircling, calcified coronary lesion. *Korean Circ J* 39, 499-501

Asakura Y, Furukawa Y, Ishikawa S, Asakura K, Sueyoshi K, Sakamoto M, Takagi S, Takatsuki S, Oyama K, Okabe T, Mitamura H, Ogawa S,

Hinohara T (1998). Successful predilatation of a resistant, heavily calcified lesion with cutting balloon for coronary stenting: a case report. *Cathet Cardiovasc Diagn* 44, 420-422

Baber U, Kini AS, Sharma SK (2010). Stenting of complex lesions: an overview. *Nat Rev Cardiol* 7, 485-496

Bertrand OF, Bonan R, Bilodeau L, Tanguay JF, Tardif JC, Rodés J, Joyal M, Crépeau J, Côté G (1997). Management of resistant coronary lesions by the cutting balloon catheter: initial experience. *Cathet Cardiovasc Diagn* 41, 179-184

Bonzel T, Hamm C, Schachinger V, and Strupp G (2012). Balloon angioplasty technology. In: Eeckhout E, Serruys PW, Wijns W, Vahanian A, van Sambeek M, De Palma R (eds). *The PCR-EAPCI Textbook: Percutaneous Interventional Cardiovascular Medicine Volume II*, UK, PCR Publishing, p 180-190

Breisblatt WM (1993). Inflated balloon entrapped in a calcified coronary stenosis. *Cathet Cardiovasc Diagn* 29, 224-228

Cleman MW (1992). Coronary angioplasty and interventional cardiology. In: Zaret BL, Moser M, Cohen LS (eds). *Yale University School of Medicine Heart Book*, New Haven, Yale University School of Medicine (updated 2002). Available from <http://info.med.yale.edu/library/heartbk/24.pdf>. Accessed July 24, 2012

Farman MT, Sial JA, Khan NU, Masood T, Saghir T (2011). Undefeatable coronary lesion. *J Pak Med Assoc* 61, 185-187

Freed MS and Safian RD (2001). Calcified Lesions. In: Safian and Freed (eds). *The Manual of Interventional Cardiology*, Abridged Third Edition, Massachusetts, Jones & Bartlett Learning, p 245-254

Gilutz H, Weinstein JM, Ilia R (2000). Repeated balloon rupture during coronary stenting due to a calcified lesion: an intravascular ultrasound study. *Catheter Cardiovasc Interv* 50, 212-214

- Hellig F, Pandie S, Barbato E, Colombo A, Heyndrickx GR (2012). Rotational atherectomy. In: Eeckhout E, Serruys PW, Wijns W, Vahanian A, van Sambeek M, De Palma R (eds). *The PCR-EAPCI Textbook: Percutaneous Interventional Cardiovascular Medicine Volume II*, UK, PCR Publishing, p 195-211
- Kern MJ (2013). Basics of Percutaneous Coronary Interventions. In: Kern MJ (ed). *The Interventional Cardiac Catheterization Handbook*, 3rd ed, Philadelphia, Saunders
- Levine GN, Bates ER, Blankenship JC, Bailey SR, Bittl JA, Cercek B, Chambers CE, Ellis SG, Guyton RA, Hollenberg SM, Khot UN, Lange RA, Mauri L, Mehran R, Moussa ID, Mukherjee D, Nallamothu BK, Ting HH (2011). 2011 ACCF/AHA/SCAI Guideline for Percutaneous Coronary Intervention: a report of the American College of Cardiology Foundation/American Heart Association Task Force on Practice Guidelines and the Society for Cardiovascular Angiography and Interventions. *Circulation* 124, e574-651
- Nguyen T, Lu C, Wang S (2003). Complex Lesions. In: Nguyen TN, Hu D, Saitu S, Grines CL, Palacios I (eds). *Practical Handbook of Advanced Interventional Cardiology*, 2nd ed, New Jersey, Wiley-Blackwell, p 181-202
- Pedersen WR, Goldenberg IF, Johnson RK, Mooney MR (2003). Successful rotational atherectomy in the setting of extensive coronary dissection: a case of failed balloon angioplasty in a nondilatable calcified lesion complicated by balloon rupture and extensive dissection. *Catheter Cardiovasc Interv* 59, 329-332
- Sánchez-Recalde A, Galeote G, Martín-Reyes R, Moreno R (2008). AngioSculpt PTCA balloon entrapment during dilatation of a heavily calcified lesion. *Rev Esp Cardiol* 61, 1361-1363
- Shantanu D (2011). A case of broken balloon: a simple solution to a complex problem. *Asia PCR Singapore Live*. Available from <http://www.pconline.com/Lectures/2011/A-case-of-broken-balloon-a-simple-solution-to-a-complex-problem>. Accessed February 12, 2013
- Siddiqi N, Suh WH, Uretsky BF, Edris A, et al (2013). Interventions: Calcific Vessels, Coronary Bypass Conduits, Elderly Patients, and Cardiac Transplantation. In: Kern MJ (ed). *The Interventional Cardiac Catheterization Handbook*, 3rd ed, Philadelphia, Saunders, p 194
- Soylu A, Ozdemir K, Duzenli MA (2006). Removal of fracture balloon catheter using another balloon inflation in coronary artery: case report. *International Journal of Cardiology* 113, e81-e83
- Suzuki T (2003). *Angioplasty for Calcified Lesions. Complex Catheter Therapeutics* Kobe Japan. Available from <http://cct.gr.jp/2003/books/bookspdf/suzuki07.pdf>. Accessed February 12, 2013
- Teirstein PS, Gollapudi RR, and Price MJ (2007). Calcified and undilatable lesions. In: Colombo A and Stankovic G (eds). *Problem Oriented Approaches in Interventional Cardiology*, First Ed, Florida, CRC Press, p 79-86