

Case Report

A RARE CASE OF NEUROENDOCRINE TUMOR FOLLOWING RADICAL NEPHRECTOMY

Muhammad Rozaqy Ishaq, Nafis Audrey Febriansyah,^{ID} Soetojo^{ID}

Department of Urology, Faculty of Medicine, Universitas Airlangga/ Dr. Soetomo General Academic Hospital, Surabaya, Indonesia

ABSTRACT

Neuroendocrine Tumors (NETs) are a diverse range of neoplasms with various biological and histologic features and therapeutic responses. The prevalence of primary renal carcinoids is scarce worldwide. At the moment, complete surgical resection is the primary treatment against primary neuroendocrine tumors of the kidney. Nephrectomy followed by the lymph node dissection is a standard procedure for localized primary renal NETs. Since renal carcinoid tumor is extremely rare, we decided to present a unique case of a 25-years-old male with neuroendocrine renal carcinoid tumor following radical nephrectomy. The results indicated a solid, solitary tumor verified on the frozen section because a postoperative CT-scan showed a recurring mass in the renal fossa following radical nephrectomy. The case emphasized the need to investigate primary renal NET in the workup and histological examination of renal tumors and also contributed to our understanding of this infrequent clinical entity.

Keywords: Neuroendocrine tumors; NETs; carcinoid tumor; radical nephrectomy; tumor

Correspondence: Soetojo, Department of Urology, Faculty of Medicine, Universitas Airlangga/ Dr. Soetomo General Academic Hospital, Surabaya, Indonesia. E-mail: s.tojowirjoprano@yahoo.com

How to cite: Ishaq, M. R., Febriansyah, N. A., & Soetojo, S. (2022). A Rare Case of Neuroendocrine Tumor Following Radical Nephrectomy. *Folia Medica Indonesiana*, 58(2), 192–194. <https://doi.org/10.20473/fmi.v58i2.33283>

pISSN:2355-8393 • eISSN: 2599-056x • doi: 10.20473/fmi.v58i2.33283 • Fol Med Indones. 2022;58:192-194

• Submitted 6 Feb 2021 • Received 28 Mar 2022 • Accepted 8 May 2022 • Published 5 Jun 2022

• Open access under CC-BY-NC-SA license • Available at <https://e-journal.unair.ac.id/FMI/>

Hii j ni j tu

3. Rare occurrence of a large, well-differentiated primary renal neuroendocrine tumor in a young man.
2. Identifying primary renal NET from the workup and histological examination of renal tumors needs to be done to understand more of this infrequent type of tumor.

INTRODUCTION

Neuroendocrine Tumors (NETs) are a diverse range of neoplasms that vary in biological and histologic features and therapeutic responses. NETs are divided into well-differentiated and poorly-differentiated neoplasms (Klimstra et al. 2010). The gastrointestinal system, pancreas, and lungs are the most common sites for well-differentiated NET carcinoid tumors. Carcinoids of the genitourinary tract, especially those arising primarily from the kidney, are extremely rare (Bégin et al. 1998). Less than 1% of reported carcinoid tumors were discovered in the genitourinary system (Murali et al. 2006). However, reported renal carcinoid tumors are only within 19% of all patients with carcinoids in the genitourinary system (Martignoni & Eble 2003). Primary renal carcinoid tumors do not advance progressively. Instead, they grow slowly and become non-functional in most cases. They were detected incidentally and showed no sex predilection. Patients are usually around 23 to 78 years old, with an incidence age lower than renal cell carcinoma (Jain et al. 2010).

Complete surgical resection is the primary treatment against primary neuroendocrine tumors of the kidney. Nephrectomy followed by dissection of the lymph node is a standard procedure for localized primary renal NETs (Korkmaz et al. 2013). Since renal carcinoid tumor is extremely rare, we decided to present a unique case of a 25-years-old male with neuroendocrine renal carcinoid tumor following radical nephrectomy.

CASE REPORT

A 25-year-old male was admitted to the outpatient clinic of Dr. Soetomo General Academic Hospital, Surabaya, Indonesia, with a chief complaint of a lump on the left flank area for a year, and the lump is getting more prominent over the last five months. The patient also complained that the pain was arising from the lump for the last five months. The patient also reported intermittent hematuria. The patient denied fever,

nausea, and vomiting. The patient was also denied for stone expulsion history, and there was no history of smoking. There was no history of diabetes mellitus and hypertension in the family. This patient underwent a radical nephrectomy in Dr. Soetomo General Academic Hospital in 2019. Physical examination showed a tender left flank mass, with no costovertebral angle tenderness.

The mass was solid, round, and mobile with a distinct border. No prostate enlargement was found on digital rectal examination, so it was otherwise normal. Urinalysis and complete blood count showed normal results. Thorax radiographic X-Ray showed normal results, as shown in Figure 1. An abdominal CT scan with contrast showed a complex cyst (16 HU) in the left renal fossa with 14.7 x 9.5 x 6.8 cm in size with contrast enhancement (53 HU). The mass pushed the spleen into the superior area and attached to the psoas major muscle with an indistinct border (Figure 2). The patient was assessed with residual left renal tumor post-radical nephrectomy. We periodically evaluated the clinical features (the sign of haematuria, mass, and metastasis), radiological assessment, and periodic surveillance were done annually.

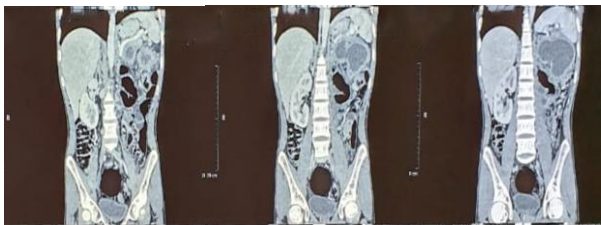


Figure 1. Plain thorax X-ray showing a normal result

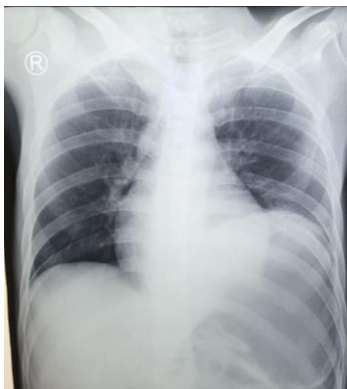

Figure 2. Abdominal CT-Scan with contrast examination indicating a mass in the left renal fossa

DISCUSSION

The prevalence of primary renal carcinoids is scarce worldwide. Approximately 65 cases have been reported (Litwinowicz et al. 2011). The previous study

by Romero et al. (2006) showed that the median age of the patients was 49 years old (ranging from 12 to 68), with 35.7% of patients being under the age of 40. Overall, there was no sex preference, but primary carcinoid tumors in the horseshoe kidneys were more prevalent in males, with a 1.5:1 male-to-female ratio (Romero et al. 2006). The right kidney had more involvement than the left (60.9% vs. 39.1% of all cases). The renal parenchyma was the apparent source of carcinoids in 76.2% of patients with non-horseshoe kidneys. In two cases, the predominant site was the renal pelvis (4.3%) (Kuba et al. 2017, Rudrick et al. 1995). The isthmus or paraisthmus area was predominantly implicated in cases with horseshoe kidneys.

Primary renal carcinoid is often associated with another renal pathology. Horseshoe kidneys were present in 10 patients (17.8%), renal teratomas were present in 8 patients (14.3%), and polycystic kidney disease was found in 1 patient (1.8%) (Kim & Suh 2004 Kurzer et al. 2005). However, the association between primary renal carcinoid tumor and other congenital renal defects is still unclear (Lodding et al. 1997, Okoń 2008). The relative risk (RR) was assessed by Krishnan et al. (1997) to be 62 and by Motta to be 120 (Kawajiri et al. 2004, Lane et al. 2007). The histogenesis is unknown since neuroendocrine cells are not detected in normal adult renal parenchyma, whilst these cells arise in the kidney throughout embryogenesis (Lane et al. 2007, Shurtleff et al. 2005). Abdominal or flank discomfort, hematuria, fever, and weight loss are the most prevalent clinical symptoms identical to those of other renal tumors.

A palpable mass may be seen in 28% of cases. As what was found in this patient, left flank mass and hematuria were apparent. Renal carcinoids seem indistinguishable from other renal tumors on imaging examinations (CT, MRI, USG). Renal cell carcinoma is thus a common diagnosis prior to surgery. Carcinoid tumors are generally solitary, yellowish to tan to grey tumors on the surface. The sizes recorded range from 2 to 17 cm (average 6.4 cm). The lesion is normally solid. However, it might rarely include a cystic component, as found with this patient. Partial or radical nephrectomy with lymph node dissection is the sole therapeutic option. Chemotherapy is only administered when liver metastases are present (Kawajiri et al. 2004, Romero et al. 2006). Due to the tumor's rarity, there is limited information on prognosis or prognostic factors (Rodríguez-Covarrubias et al. 2007).

Strength and limitation

The study reports a rare case of primary neuroendocrine renal carcinoid tumor, which can contribute to the

understanding and knowledge of this infrequent clinical entity. The case emphasizes the importance of investigating primary renal NET in the workup and histological examination of renal tumors, which can help in the diagnosis and management of these tumors.

CONCLUSION

We presented a rare occurrence of a large, well-differentiated primary renal neuroendocrine tumor in a young man. The operational results indicated a solid, solitary tumor verified on the frozen section. A postoperative CT-scan showed a recurring mass in the renal fossa following radical nephrectomy. The case emphasizes the need to investigate primary renal NET in the workup and histological examination of renal tumors and contributes to our understanding of this infrequent clinical entity.

Acknowledgment

We thank the medical record staff of Dr. Soetomo General Academic Hospital, Surabaya, Indonesia.

Conflict of interest

None0

Funding disclosure

P one0

Author contribution

MTI'cpf 'PCU'eqpv'kdwgf vq f guki p)u uwf { . MTI
y tkg "y j o cpwætkr v'cpf i tco o ct' ej gem Uy cu hpcn
eqpv'g'p'v'cpf "ci tggvo gpv.

REFERENCES

- Bégin L, Guy L, Jacobson S, et al (1998). Renal carcinoid and horseshoe kidney: A frequent association of two rare entities--a case report and review of the literature. *J. Surg. Oncol.* 68, 113–119.
- Jain D, Sharma M, Singh K, et al (2010). Primary carcinoid tumor of the kidney: Case report and brief review of literature. *Indian J. Pathol. Microbiol.* 53, 772–774.
- Kawajiri H, Onoda N, Ohira M, et al (2004). Carcinoid tumor of the kidney presenting as a large abdominal mass: Report of a case. *World J. Surg. Oncol.* 34, 86–89.
- Kim J, Suh K (2004). Primary carcinoid tumor in a mature teratoma of the kidney: Ultrasonographic and computed tomographic findings. *J. Ultrasound Med.* 23, 433–437.
- Klimstra D, Modlin I, Coppola D, et al (2010). The pathologic classification of neuroendocrine tumors: A review of nomenclature, grading, and staging systems. *Pancreas* 39, 707–712.
- Korkmaz T, Seber S, Yavuzer D, et al (2013). Primary renal carcinoid: Treatment and prognosis. *Crit. Rev. Oncol. Hematol.* 87, 256–264.
- Krishnan B, Truong L, Saleh D, et al (1997). Horseshoe kidney is associated with an increased relative risk of primary renal carcinoid tumor. *J. Urol.* 157, 2059–2066.
- Kuba M, Wasserman A, Vnencak-Jones C, et al (2017). Primary carcinoid tumor of the renal pelvis arising from intestinal metaplasia: An unusual histogenetic pathway? *Appl. Immunohistochem. Mol. Morphol.* 25, 49–57.
- Kurzer E, Leveille R, Morillo G (2005). Rare case of carcinoid tumor arising within teratoma in kidney. *Urology* 66, 5–6.
- Lane B, Chery F, Jour G, et al (2007). Renal neuroendocrine tumours: A clinicopathological study. *BJU Int.* 100, 1030–1035.
- Litwinowicz R, Szpor J, Januś G, et al (2011). Primary carcinoid tumour in horseshoe kidney. *Int. J. Urol.* 62, 72–74.
- Lodding P, Hugosson J, Hansson G (1997). Primary carcinoid tumour with ossification masquerading as calyx stone in a horseshoe kidney. *Scand. J. Urol. Nephrol.* 31, 575–578.
- Martignoni G, Eble J (2003). Carcinoid tumors of the urinary bladder. Immunohistochemical study of 2 cases and review of the literature. *Arch. Pathol. Lab. Med.* 127, 22–24.
- Murali R, Kneale K, Lalak N, et al (2006). Carcinoid tumors of the urinary tract and prostate. *Arch. Pathol. Lab. Med.* 130, 1693–1706.
- Okoń K (2008). Pathology of renal tumors in adults. Molecular biology, histopathological diagnosis and prognosis. *Polish J. Pathol.* 59, 129–176.
- Rodríguez-Covarrubias F, Gómez X, Valerio J, et al (2007). Carcinoid tumor arising in a horseshoe kidney. *Int. Urol. Nephrol.* 39, 373–376.
- Romero F, Rais-Bahrami S, Permpongkosol S, et al (2006). Primary carcinoid tumors of the kidney. *Adv. Urol.* 176, 2359–2366.
- Rudrick B, Nguyen G, Lakey W (1995). Carcinoid tumor of the renal pelvis: Report of a case with positive urine cytology. *Diagn. Cytopathol.* 12, 360–363.
- Shurtleff B, Shvarts O, Rajfer J (2005). Primary carcinoid tumour of the kidney. A case report and review of the literature. *Adv. Urol.* 7, 229–233.

