

## Case Report: ARTERIOVENOUS MALFORMATION IN FOOT. SURGICAL MANAGEMENT COMBINED WITH SCLEROTING AGENT

Lusi Rustina<sup>1</sup>, Ivan Joalsen MT<sup>2</sup>

<sup>1</sup>Medical Doctor Program, Mulawarman University, Samarinda, Indonesia, <sup>2</sup>Division of Cardiothoracic and Vascular Surgery, Medical school of Mulawarman University, Abdul Wahab Sjahranie General hospital

### ABSTRAK

*Diagnosis dan penanganan malformasi arteriovena (AVM) memerlukan pendekatan multidisiplin dan pengetahuan mengenai patofisiologi pembuluh darah. Insiden anomali vaskular jarang terjadi. Anomali tersebut terutama terjadi di kepala atau ekstremitas atas. Terdapat penelitian mengenai AVM dengan manifestasi dermatologis, namun penelitian yang melibatkan manifestasi di kaki jarang ditemukan. Penelitian ini bertujuan untuk memberikan diagnosis dan penanganan kasus pada pasien laki-laki berusia 19 tahun dengan malformasi arteriovena pada kaki. Pasien tersebut datang dengan keluhan utama adanya massa yang menyakitkan pada plantar medial di kaki kanannya yang muncul sejak lahir dan terus bertambah ukurannya. Pemeriksaan fisik menunjukkan massa plantar medial yang besar, berukuran ± 8 x 5 cm, sedikit dapat bergerak, berwarna kebiruan, lunak, dan tidak dapat ditekan. Massa berdenyut pada palpasi dan tidak terdapat bising. Diagnosis kerja pada pasien ini adalah AVM. MRI menunjukkan bahwa terdapat punction atau nidus, hiperintens granular di tengah dan pedis dengan draining vein. Massa tersebut terletak pada subkutan dan meluas ke lapisan otot. Pasien mendapatkan manajemen bedah. Eksisi AVM pada bagian subkutan dikombinasikan dengan injeksi polidokanol 1% pada sisi otot. Hasil patologi jaringan menunjukkan AVM lunak. Kondisi luka setelah dua hari operasi: tidak ada perdarahan, tidak ada tanda-tanda infeksi, dan rasa sakit berkurang. Pada empat minggu setelah operasi, pasien perlahan dapat menahan beban berat di kakinya, dan massa serta rasa sakit berkurang total. Pasien dirawat di rumah sakit selama empat hari. Laporan ini menggambarkan lokalisasi malformasi arteriovena yang tidak biasa. Kelainan arteri pada kaki merupakan malformasi menantang yang dapat ditangani dengan agen eksisi dan sklerosis. (FMI 2017;53:228-232)*

**Kata kunci:** Malformasi arteri; skleroterapi; reseksi bedah

### ABSTRACT

*Diagnosis and management of arteriovenous malformation (AVM) requires a multidisciplinary approach and includes the knowledge of the pathophysiology of the blood vessels. The incidence of vascular anomalies is rare, and they are mainly localized in the head or upper extremity. There are studies on AVM with dermatological manifestations. However, studies involving manifestations in foot are rare. The goal of this report is to provide diagnosis and treatment case of an 19 year-old boy with arterio-venous malformation of the foot. A 19-year-old Indonesian male presented with a chief complaint of a painful mass on his plantar medial right foot that had been present since his birth and had increased in size. Physical examination revealed a large plantar medial mass, with size ± 8 x 5 cm, slightly mobile, bluish, soft, and non-compressible. The mass was pulsatile on palpation and no bruit. The working diagnosis of this patient was AVM. MRI showed there was a punctat or nidus, granular hyperintense in the middle and pedis with a draining vein, and the mass was laying from subcutaneous and extended into muscular layer. Surgical management was performed. Excision of AVM in subcutaneous part was combined with injection of polidocanol 1% in muscular side. Tissue pathology results revealed AVM with no evidence of malignancy. Evaluation wounds after 2 days of operation: there was no bleeding, no signs of infection, pain was reduced. Four weeks after surgery, the patient slowly could bear his full weight on his foot, and the mass and local pain were totally reduced. Length of stay in hospitals was 4 days. This report described an unusual localization of an arteriovenous malformation. Arteriovenous malformation in foot is a challenging malformation that can be successfully managed with excision and sclerosing agents. (FMI 2017;53:228-232)*

**Keywords:** Arteriovenous malformation; sclerotherapy; surgical resection

**Correspondence:** Lusi Rustina, Medical Doctor Program, Mulawarman University, Samarinda, Indonesia.  
Email: lusyrustina@gmail.com

### INTRODUCTION

Vascular malformations are grouped together based on their common embryological origin of having a single endothelial cell lining. Vascular malformations are

estimated as result of developmental errors during embryogenesis, such as abnormal signaling processes that control apoptosis, maturation, and growth of vascular cells. These errors lead to the persistence of vascular plexus cells with a certain degree of differ-

entiation. There are four major categories of vascular malformations based on their flow characteristics: slow-flow (capillary, venous, and lymphatic malformations) and fast-flow (arteriovenous malformation) (Joshua et al 2014).

Arteriovenous malformations (AVM) are defects of the circulatory system that arise during embryonic or fetal development or soon after birth. They are comprised of entangled arteries and veins without capillaries that pass blood directly from arteries to veins. The presence of an AVM disrupts this process, compromising the arteries from carrying oxygen-rich blood away from the heart to the body's cells and compromising the ability of veins to return oxygen-depleted blood to the lungs and heart. Arteriovenous malformation is a rare condition and spontaneous regression is also rare. Arteriovenous malformations may be present throughout a person's life with the origin time spanning from congenital abnormalities to manifestations thereafter from various stimuli such as trauma (Tanya & Lauren 2016).

Diagnosis and management of arteriovenous malformation requires a multidisciplinary approach and includes the knowledge of the pathophysiology of the blood vessels. The incidence of vascular anomalies is rare, and they are mainly localized in the head or upper extremity (Kunze et al 2009). Literature reports of AVM in the extremities have occurred with dermatologic manifestations but even more sparse are literature reports involving manifestations in the foot and ankle (Tanya & Lauren 2016). We reported the case of a 19-year-old boy with arteriovenous high-flow malformation of the foot. Presentations of diagnostic and therapeutic opportunities as well as post surgical clinical follow-up are included.

## CASE REPORT

This is a case report of a 19-year-old Indonesian male presented with a chief complaint a painful mass on his plantar medial right foot that had been present for two weeks and had increased in size. Weight-bearing activities exacerbated the pain. He had no previous treatment other than walking on the outside of his feet to avoid direct contact with the mass. He denied any trauma to the area. The patient reported that mass already appeared since baby but small and painless. Physical examination revealed a large plantar medial mass, with size  $\pm 8 \times 5$  cm approximately, slightly mobile, bluish, soft, and non-compressible. The mass was pulsatile on palpation and no bruit. The cutaneous stain was more erythematous and local warmth (Fig. 1). The patient's remaining pedal neurovascular and musculoskeletal examinations were within normal limits.

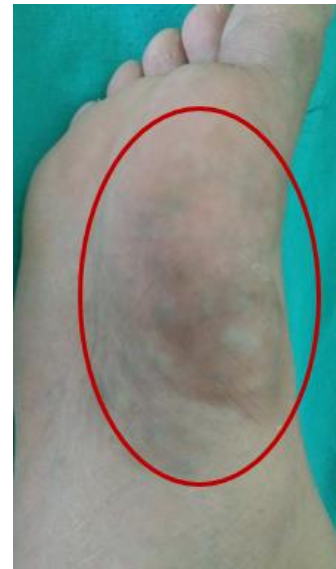

Fig 1. Clinical performance of the mass.

Early diagnosis for this patient was AVM pedis dextra and differential diagnosis was hemangioma. Magnetic resonance imaging (MRI) of the foot was performed and showed arteries of the posterior distal tibialis pedis provide vascularization to the plantar medial, plantar lateral and arcus plantaris, while tibialis anterior give vascularization to artery dorsalis pedis and arcuatus.

MRI also showed puncta or nidus, hyperintense granule in the middle and pedis with draining vein; small round granules/nodules, multiple and middle pedis dextra. The mass was laying from subcutaneous and extended into muscular layer. Differential diagnosis from MRI include Arteriovenous malformations, hemangioma, and varices (Fig. 2).

Surgical management of the malformation was performed by excising the AVM in subcutaneous part then combined by injecting 1% polidocanol into the mass which was located in muscular part. Tissue pathology results revealed AVM with no evidence of malignancy.

## RESULTS

Wound evaluation after 2 days after surgery showed no bleeding, no signs of infection and decreased pain. Three day after surgery, the patient was discharged from hospital. Four weeks after surgery, the patient slowly could bear his full weight on his foot, and the mass and local pain were totally reduced (Fig. 3).

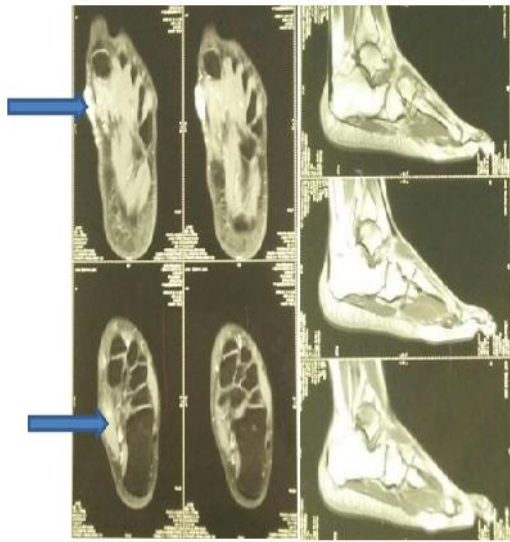


Fig 2. MRI pedis dextra/angiografi with contrast showed a mass in right foot (blue arrow).

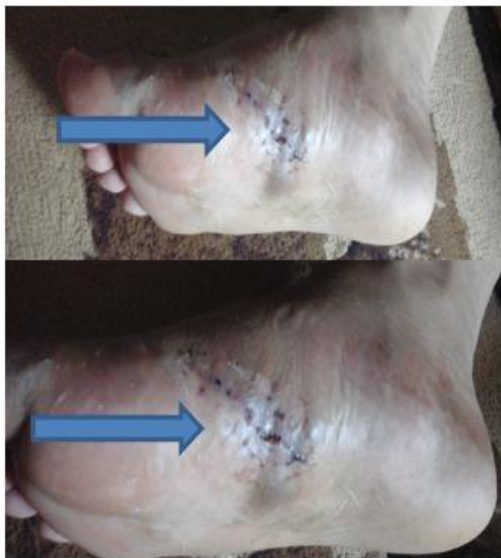

Fig 3. Clinical feature one month after surgery.

## DISCUSSION

Vascular anomalies occur with an incidence of 1-10/100000. They are apparent in 1–2.6% of neonates (Schwartz et al 2006). Cephalic localizations are most common, followed by trunk, lower and upper extremities. Arteriovenous malformations rarely occur in the lower extremities. We can best characterize them by the type of vascular channel, the degree of blood flow and the structures involved. Arteriovenous malformation are frequently associated with additional findings and fall

under the auspices of multiple syndromes (Tanya & Lauren 2016). In rare cases, vascular malformations may be part of syndrome complex, such as Klippel-Trenaunay-Weber and Sturge-Weber syndromes or genetic disorders. Thus, in evaluating these abnormalities, a family history should be performed (Revenu et al 2008).

Arteriovenous malformations (AVM) represent a class of vascular malformations that develop from an identifiable source vessel called the “nidus,” which conducts an abnormal connection of arterial and venous systems (Greene & Orbach 2011). This type of shunt is usually present at birth, but does not become apparent until the first or second decade of life. Arteriovenous malformations may be slightly compressible and pulsatile with a palpable thrill (Lee et al 2004). This type of lesion is most commonly found intracranially and can expand in response to certain stimuli such as trauma or puberty. Clinically, arteriovenous malformations can appear in soft tissues or bone and are typically not accompanied by pain, but rather frequent episodes of bleeding. These lesions have a reliable natural history comprised of four distinct stages: quiescent, growing, symptomatic, and decompensating (Lee et al 2004, Visser et al 2011)

Presenting symptoms include congestive heart failure, embolism, pain, bleeding, and ulceration (Joshua et al 2014). On physical examination, the lesions may appear blue and may feel warm with pulsating and thrill because of the increased blood flow. Lesions tend to grow along with childhood but can enlarge rapidly as a result of thrombosis, infection, or hormonal stimulation (Donnelly et al 2000).

High flow AVMs are characterized by a high blood flow in a direct connection between arteries and veins without capillaries. The Schobinger staging system of arteriovenous malformations includes four grades of severity: dormancy, expansion, destruction and decompensation (Visser et al 2011).

Clinically, if a palpable mass is present, it is generally firm and non-compressible. As we mentioned, one of the distinctive signs indicating the presence of an AVM is an auditory bruit. Other clinical findings include increased warmth to the affected limb and a dermal stain at the site of the mass. Waterson and colleagues stated that a bruit or thrill arises in relatively few extremity cases because the flow is usually through multiple small communications (Tanya & Lauren 2016).

Table 1. Hemangioma and vascular malformations (Pandey et al 2008)

	Hemangioma	Vascular malformations
Types	Superficial, deep, and mixed	Capillary, venous, and lymphatic malformations, arteriovenous malformations
Age	Presents few days after birth	Usually present at birth
Gender	More common in females	No preference
Growth	Usually involve by 5-8 years	Persists throughout life
Hypothyroidism	Can present	None
Effect of steroid	Steroid responsive	Steroid non-responsive
Treatment	Pharmacotherapy is initial choice	Surgery prime modality of treatment except CM (FPDL is used). Other options: sclerotherapy for VM and embolization for AVM

Note: CM=capillary malformation; VM=venous malformation; AVM=arteriovenous malformation; FPDL=flash-lamp pulsed dye laser

Imaging plays an important role in the diagnosis of an AVM, but more so in operative planning. As with other vascular malformations, Ultrasonography (USG) and MRI can identify high flow patterns as well as determine the extent of the lesion. Lesions are often multispatial and hypervascular on color Doppler USG. Magnetic resonance imaging is especially useful in defining the extent of AVMs, and typically shows numerous flow voids and hyperintense signal without an obvious mass.

Unlike other vascular malformations, computerized tomography (CT) can be valuable, especially for bony AVMs. Angiography can also be utilized for defining the feeding and draining vessels prior to sclerotherapy or surgical intervention. Treatment of an AVM is based on the concept of obliteration of the nidus as this is thought to be responsible for the growth of the lesion through recruitment of new vessels from neighboring regions. Sclerotherapy and embolization remain first-line options to allow for safer intraoperative resection with less blood loss. Ligation of feeding vessels should never be done as this leads to rapid recruitment of collaterals and heightens vascularity (Greene & Orbach 2011). When considering resection of an AVM, we should note that the curative action is less frequently useful for these lesions. Therefore, the focus should be aimed to disease control. Indications for intervention include ischemic pain, recurrent ulcerations/bleeding, or perturbed cardiac function. Sclerotherapy is the use of special liquids called sclerosants and specially shaped pieces of metal called coils to make these malformations shrink and relieve the pain. They are usually better treated by a combination of endovascular embolization with liquid adhesives or other embolic agents, with or without surgical excision of the remaining malformation (Lee et al 2004, Visser et al 2011)

The mainstays of management are embolization, sclerotherapy, surgical resection, and reconstruction. Ligation or proximal embolization of feeding vessels should never be done. Such maneuvers deny access for embolization, and result in the rapid recruitment of new vessels from adjacent arteries to supply the nidus. Embolization can be with coils or glue, either accessing the malformation from proximal arterial or retrograde venous approaches. Sclerotherapy is another approach that may be used if there are tortuous arteries or the feeding vessels have been ligated. This involves direct puncture of the nidus during local arterial and venous occlusion (Jennifer & John 2005).

Often complete resection is not possible or would result in severe disfigurement, particularly in a young patient. In these instances, embolization or sclerotherapy may be used to control symptoms, such as pain, bleeding, or congestive heart failure. Typically, embolization provides only transient improvement because of recruitment of new vessels by the nidus. When surgical intervention is undertaken, embolization is done 24 to 72 hours before resection to provide temporary occlusion of the nidus and facilitates the surgical procedure. Extremity lesions may, in certain circumstances, be excised without preoperative embolization. The surgical goal is complete resection, unlike staged resection applicable to slow-flow vascular malformations, to minimize the chances of recurrence. The nidus, and usually involved skin, must be widely excised. If there is any concern about the adequacy of resection, temporary coverage with a split-thickness skin graft can be an interim measure. Combined embolization and surgical resection is most successful for stage I or II well-localized AVMs. Follow-up evaluation is necessary for years with clinical examination supplemented by ultrasonography or MRI. The chances of recurrence are high, and experienced surgeons recognize that a "cure" can only be judged after many years. Interestingly,

recurrence has been observed to involve free flap tissue used to reconstruct a defect, following incomplete excision of an AVM (Jennifer & John 2005).

In this case, a 19 years-old boy presented with a chief complaint of a painful mass on his plantar medial right foot that had been present for two weeks and had increased in size. The patient reported that the mass already appeared since baby but small and painless. AVM is usually present at birth, but does not become apparent until the first or second decade of life. AVM may be part of syndrome complex such as Klippel-Trenaunay-Weber or genetic disorders. A mass may expand beneath the capillary stain, occasionally with rapid enlargement following trauma or during puberty (Jennifer & John 2005). AVM in this case would most likely be Stage I, the expansion phase on the Schobinger staging system. Clinically, the mass was pulsatile, slightly mobile and spongy in nature, bluish, soft, non-compressible, cutaneous stain was more erythematous and local warmth. A bruit was not present in this patient.

## CONCLUSION

This report describes an unusual localization of an arteriovenous malformation. Arteriovenous malformation in foot are a challenging malformation that can be successfully managed with excision and sclerosing agents.

## REFERENCES

Donnelly LF, Adams DM, Bisset GS (2000). Vascular malformations and hemangiomas: a practical approach

- in a multidisciplinary clinic. *American Roentgen Ray Society* 174, 597-608
- Greene AK, Orbach DB (2011). Management of arteriovenous malformations. *Clin Plast Surg* 38, 95-106
- Jennifer M, John B (2005). Current management of hemangiomas and vascular malformations. 0094-1298/05/\$ – see front matter D. Elsevier Inc. doi:10.1016/j.cps.2004.10.001
- Joshua et al (2014). Vascular malformations: a review. *Seminars in Plastic Surgery* 28
- Kunze B, Kluba T, Ernemann U, Miller S (2009). Arteriovenous malformation: an unusual reason for foot pain in children. *The Foot and Ankle Online Journal* 2
- Lee BB, Do YS, Yakes W, Kim DI, Mattassi R, Hyon WS (2004). Management of arteriovenous malformations: a multidisciplinary approach. *J Vasc Surg* 39, 590-600
- Pandey A, Gangopadhyay AN, Upadhyay VD (2008). Evaluation and management of infantile hemangioma: an overview. *Ostomy Wound Manage* 54, 16-29
- Revenu N, Boon LM, Mulliken JB (2008). Parkes Weber syndrome, vein of Galen aneurysmal malformation, and other fast-flow vascular anomalies are caused by RASA1 mutations. *Hum Mutat* 29, 959-965
- Schwartz RA, Lin RL, Wei TJ (2006). Arterial vascular malformations including hemangiomas and lymphangiomas. *eMedicine Pediatrics*
- Tanya MJ, Lauren T (2016). When arteriovenous malformation arises in the foot. *Podiatry J* 29
- Visser A, FitzJohn T, Tan ST (2011). Surgical management of arteriovenous malformation. *J Plast Reconstr Aesthet Surg* 64, 283-291