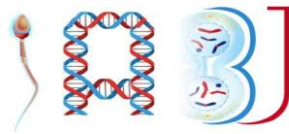



Indonesian Andrology and Biomedical Journal



Original research

The Contribution of Sex Difference on Different Liver Histopathology Between Male and Female Mice After Oral Administration of Caffeine

Muhammad Sholikhuddin Nafi¹, Tri Hartini Yuliawati², Prijati Sri Irawati², Nurina Hasanatuludhhiyah^{2*} 

¹Faculty of Medicine, Universitas Airlangga, Surabaya, Indonesia

²Department of Anatomy, Histology and Pharmacology, Faculty of Medicine, Universitas Airlangga, Surabaya, Indonesia



ARTICLE INFO

Received: September 23, 2021

Accepted: November 23, 2021

Published: December 10, 2021

*) Corresponding author:

E-mail:

nurina-h@fk.unair.ac.id

Keywords:

Caffeine

Liver Histopathology

Sex Difference

This is an open access article under the CC BY-SA license (<https://creativecommons.org/licenses/by-sa/4.0/>)

Abstract

Background: There are several studies reporting the effect of caffeine on liver histopathology, but it remains controversy. The laboratory animal used in those studies were predominantly male, whereas there is contribution of sex difference on different liver reaction to xenobiotic between male and female subject.

Objective: It is necessary to conduct a study to explore the differences between the liver histopathology of male and female mice after oral administration of caffeine.

Methods: This study used 36 mice (*Mus musculus*) that were divided into 4 groups: male & female untreated groups and male & female treated groups which were orally administered with caffeine 0.4 mg / 20 gramBW daily for 30 days. At the end of treatment, mice were euthanized and dissected. Histopathological examination was done to determine the percentage of liver cell death of each group.

Results: The percentage of liver cell death in female treated group was higher than male treated group ($p = 0.0001$). But there was no significant difference of liver cells death between male control and treated group and between female control and treated group.

Conclusion: There was significant difference in liver histopathology between male and female mice after oral administration of caffeine.

Cite this as: Nafi', M.S., Yuliawati, T.H., Irawati, P.S & Hasanatuludhhiyah, N. (2021). The Contribution of Sex Difference On Different Liver Histopathology Between Male and Female Mice After Oral Administration of Caffeine. *Indonesian Andrology and Biomedical Journal*, 2(2):37–41. <http://doi.org/10.20473/iabj.v2i2.162>

1. Introduction

Caffeine is one compound which is frequently consumed by people, whether in the form of drink, food or drug. In last period, market of caffeine products also increased, especially caffeinated drink and dietary supplement.¹ Most source of caffeine is found in some plants such as coffee beans, cocoa, tea leaves and cola nut. In addition, caffeine is a psychoactive drug that is most widely used by people in the world.²

Caffeine is still under discussion whether it has beneficial effects or not in liver. Some studies suggest that caffeine or caffeinated products have effects on liver histopathology. Caffeine and coffee may protect against liver injury induced by diethylnitrosamine (DEN) and thioacetamide (TAA).^{3,4} Caffeine also has potential effect to protect liver from oxidative stress.⁵ However caffeinated drink can damage hepatocytes although the cell damage is reversible.⁶ Coffee containing caffeine when orally administered to male rat could cause histological changes on hepatocytes such as parenchymatous degeneration, hydropic degeneration and necrosis.⁷ Caffeine when administered 10 mg/kg may exacerbate acute liver injury in female mice by interfering A2A adenosine receptors (A2AR)-mediated-tissue-protecting mechanism. Caffeine in serum are sufficiently high to antagonize adenosine signaling through the A2AR on activated mouse immune cells that caused an increase in the serum protein levels of proinflammatory cytokines such as interferon gamma (IFN- γ).⁸

In order to determine the effect of caffeine on liver, the laboratory animal used on previous studies were predominantly male whereas there is contribution of sex differences on different liver reactions to xenobiotics or toxicant. The sex differences in liver toxicity may be produced by physiological differences in the pharmacokinetics and pharmacodynamics phase. Hormonal differences between male and female was also mentioned as a cause of different liver reactions to xenobiotics.⁹ Therefore to determine the effect of caffeine on liver histopathology of male and female mice, the research of determining the difference of liver histopathology between male and female mice after oral administration of caffeine is necessary.

2. Method

Thirty-six mice (*Mus musculus*) BALB/c strain

(male and female) 29.61 \pm 3.79 grams were obtained from the Pharmacology laboratory, Faculty of Medicine, Universitas Airlangga. Animals were given food and drink based on laboratory standard. The subjects were randomized and divided equally into 4 groups: male & female untreated groups and male & female treated groups which were orally administered with caffeine (CSPC Innovation Pharmaceutical, China) 0.4 mg / 20 gramBW daily for 30 days. This dose was selected from the conversion of daily dose of caffeine consumption in human (150–200mg) based on regulation from The National Agency of Drug and Food Control.¹⁰ All solutions were prepared every day to avoid contamination of microorganisms or foreign compounds. Body weight measurement were done during the study to adjust the dose of caffeine administration. At the end of treatment, mice were euthanized and dissected. This study has been approved by the Health Research Ethics Committee in Faculty of Medicine, Universitas Airlangga, Surabaya, based on The Ethical Clearance No. 076/EC/KEPK/FKUA/2015.

The liver of mice were taken fixed in buffer formalin and made into histopathological slides, Haematoxylin Eosin (H&E) staining, using standard methods in Histotechnic Laboratory, Faculty of Medicine, Universitas Airlangga. Histopathological examination was done to determine the percentage of liver cell death which was characterized by pyknotic nucleus by observing on hepatocytes in zone 3 at 6 different central vein that carried out by using a light microscope Olympus CX41 Series with 400x magnification, OptiLab digital camera and graticule viewed by Optilab ® Viewer Software v2.1 (Fig. 1). Statistical analysis software used in this study was SPSS 16.0. The data were analyzed by t-test for independent samples. The results were considered significant if $p < 0.05$.

3. Result

The percentage of liver cell death in male treated group was the least compared to male control group and female groups (control and treatment), while the percentage of liver cell death in female treated group was the highest compared to the female control group and male groups (control and treatment). Statistic analysis showed a significant difference percentage of liver cell death between male and female treated groups.

Percentage of liver cell death in female treated group was higher than male treated group. However when we compared the control and treated group in each sexes, statistic analysis showed that there is no significant difference of liver cells death between male control and treated group and between female control and treated group, although there was a decreasing percentage of liver cell death in male treated group and an increasing percentage of liver cell death in female treated group (Fig.2).

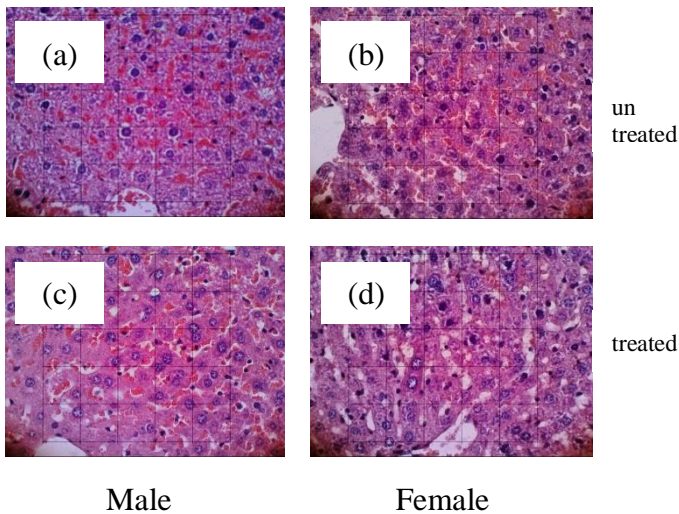
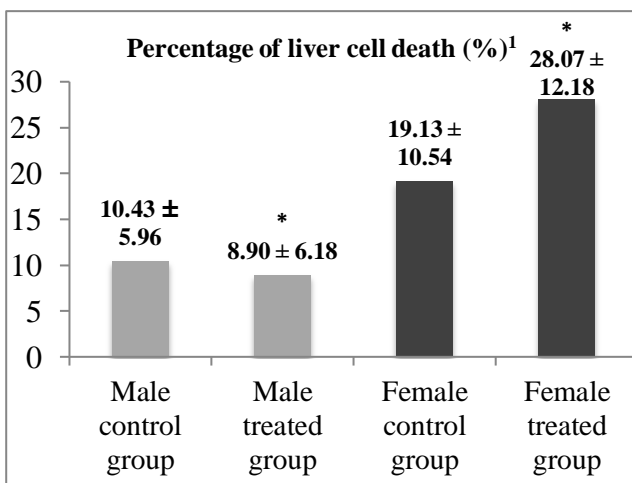


Figure 1. Histological examination of liver death in untreated group and treated group of mice. (a to c) Liver histopathology in untreated group and male treated group showed predominantly normal liver cell characterized with open face type nucleus (40x objective) (d) Liver histopathology in female treated group showed an increasing liver cell death characterized with pyknotic nucleus (40x objective)



1 : Data are mean \pm standart deviation
 : Percentage of liver cell death in male groups
 : Percentage of liver cell death in female groups
 * Significant difference between male and female : treated group (P = 0.001)

Figure 2. Percentage of liver cell death showed significant difference between male and female treated group

4. Discussion

Histopathological liver examination in this study was done by examining on liver cells or hepatocytes around the central vein in zone 3. This zone is far from the hepatic artery perfusion and have an oxygen concentration only 4 – 5 % compared to the zone 1 that have an oxygen concentration as much as 9 – 13 %. Therefore, improvements of liver cell necrosis in zone 3 is slower than zone 1.¹¹ In addition, zone 3 also has higher protein cytochrome P450 than other zones.¹²

The effects of caffeine on the liver still remains controversy. There was a tendency of decreasing percentage of liver cell death in male mice and an increase of percentage of liver cell death in female mice. Caffeine can decrease the levels of malondialdehyde (MDA) and increase the levels of nitric oxide (NO) in the liver of male rat. This means that caffeine may have potential effect to protect against oxidative stress in the liver. However, the effect on the liver depends on the dose, route of administration (oral or injection) and the duration of treatment.⁵ Caffeine was believed to has hepatoprotective effect because it can prevent liver damage induced by DEN by maintaining the integrity of the plasma membrane.³ The accumulation of free radicals that trigger oxidative stress and the decreased of defense membrane integrity were indeed one mechanism that can lead to cell damage.¹³ However caffeine has a prooxidant effect in the liver of rat.¹⁴ Prooxidant referred in previous study was the effect of depletion or antagonism of some antioxidants such as superoxide dismutase, catalase or vitamin A and E. Antioxidants are associated with reduction of free radicals in the body. Free radicals are produced physiologically in cells during the process of respiration and energy production as well as play a role in cell damage.¹³ Caffeine can also trigger intracellular oxidative stress directly.¹⁵ The toxic effect of caffeine is supposed to affect liver cell death based on a study that showed glandular degeneration in the salivary glands after administration of drink containing caffeine.¹⁶ Caffeine significantly worsened the markers of liver cell injury, inflammation, and/or steatosis nonalcoholic steatohepatitis (NASH) lesions in

mice. In the study, serum alanine aminotransferase (ALT) levels, the prevalence of Oil red O-positive areas (reflecting steatosis) and CD45R-positive areas (reflecting lymphocytic infiltration) in the hepatic lobule were significantly higher in the caffeine than in the choline-deficient, L-amino acid-defined, high-fat diet (CDAHFD) group that was new model of NASH.¹⁷ Moreover caffeine can also induce cell apoptosis through a mechanism of direct modulation of cell cycle or induction of p53.¹⁸ In the osteoblast cells which were administered with caffeine (in vitro) can induce apoptosis through the mitochondrial pathway.¹⁵ Immune mechanisms can explain the liver damage after administration of caffeine in female mice. This is caused by an increase of proinflammatory responses by antagonize of A2AR, a receptor that mediate antiinflammation mechanism.⁸

The influence of sex difference on alcoholic liver injury in mice can be observed in some molecular mechanism. Ethanol treatment induced more expression of heat shock protein 27 (HSP27) and HSP70, faster hepatocyte proliferation, higher level of glycogen, and IL-6 signaling pathway activation but less hepatocyte apoptosis and CYP2E1 expression in male mice than female mice.¹⁹ Gender dimorphism affect in liver structure and cell composition include liver fibrosis, alcohol injury and post-hepatectomy regeneration. In concept of transplantation, it may be hypothesized that when deprived with of estrogenic milieu (inherent to transplantation in a male recipient), the highly hepatocellular female liver may start remodeling and the HEP apoptosis may trigger an increased production of pro-inflammatory interleukins. This may sentence the female organ to a poorer outcome in the male recipient.²⁰ Sex difference have also important contribution through the role of fibroblast growth factor 21 (FGF21) in alleviating hepatic injuries associated with a cafeteria diet in young male, but not female mice.²¹

The toxicity difference of drugs among sexes is caused by the differences of pharmacokinetics, pharmacodynamics and hormones.⁹ Pharmacokinetics of caffeine in liver is associated with biotransformation of caffeine to paraxantin by CYP1A2 which is the main route of metabolism of caffeine.²² Several studies reported that CYP1A2 is higher in men than women.¹¹ When caffeine is metabolized rapidly in male, the possibility of liver damage will be less on male mice compared to female mice. Therefore it supports the result of

this study that the percentage of liver cell death is higher in female treated group than male treated group. In addition, pharmacokinetic differences can be due to differences in body composition such as variations in body weight, fat composition and plasma volume.⁹

Hormonal differences between male and female affect different liver histopathology between male and female mice. This is related to the activity of CYP1A2 in the liver. Estrogen can inhibit the activity of CYP1A2.²² In addition, oral contraceptives can reduce the activity of CYP1A2.¹¹ The increasing of sex hormones in women in pregnancy and oral contraceptive users is associated with the decreasing metabolism of caffeine.²³ Therefore the percentage of liver cell death in female treated group is higher than male treated group. Some studies showed that women who are in final stage of pregnancy or in long-term user of oral contraceptives has increased of the half-life of caffeine approximately two times.² This is certainly related to the hormonal situation in women that differ from male.

This research suggests that women are more susceptible to liver damage after oral administration of caffeine. Women have more incidence of liver diseases such as acute liver failure, autoimmune hepatitis, benign lesions in the liver, primary biliary cirrhosis and toxin-mediated hepatotoxicity. Pathophysiology of sex differences in different incidence and outcome of liver disease is still not understood. Many potential mechanisms could affect the result of this study such as the effect of sex hormones on oxidative and metabolic pathways, different gene transcription in response to an injury and sex differences in regulation of immunity.²⁴ Human primary hepatocytes in women are more sensitive to hepatotoxic than men. In previous study, there were significant differences in the variables of mitochondria status, endoplasmic reticulum status, nucleus condensation and plasma membrane permeability between male and female. Different liver toxicity between male and female was suspected due to the different sex genome that can determine the behavior of cell when given a toxicant.⁹

5. Conclusion

According to the research the author concludes that there is different liver histopathology between male and female mice after oral administration of

caffeine. It is necessary to conduct study to explore about contribution factors on different liver histopathology between male and female that administered with caffeine. Therefore in future study, sex differences were expected to be considered as a contribution factor that affect liver reaction to a substance.

References

1. Regina W. Caffeine – Common Ingredient in a Diet and Its Influence on Human Health. *Rocz Panstw Zakl Hig* 2012; 63: 141–142.
2. Goodman LS, Gilman A, Parker K. *Goodman & Gilman's Manual of Pharmacology and Therapeutics*. 10th ed. Medical Book Publisher: Jakarta, 2008.
3. Rezaie A, Pashmforosh M, Haghi Karamallah M, Fazlara A, Haghighat N, Shahriari A. Hepatoprotective effect of caffeine on diethylnitrosamine-induced liver injury in rats. *Bulg J Vet Med* 2014; 17: 183–190.
4. Furtado KS, Prado MG, Aguiar e Silva MA, Dias MC, Rivelli DP, Rodrigues MAM *et al*. Coffee and Caffeine Protect against Liver Injury Induced by Thioacetamide in Male Wistar Rats. *Basic Clin Pharmacol Toxicol* 2012; 111: 339–347.
5. Paşaoğlu H, Ofluoğlu demir FE, Yılmaz Demirtaş C, Hussein A, Paşaoğlu ÖT. The effect of caffeine on oxidative stress in liver and heart tissues of rats. *Turkish J Med Sci* 2011; 41: 665–671.
6. Akande IS, Banjoko OA. Assessment of Biochemical Effect of " Power Horse " Energy Drink on Hepatic, Renal and Histological Functions in Sprague Dawley Rats. *Annu Rev Res Biol* 2011; 1: 45–56.
7. Bhara M. *The Effects of Coffee in Gradual Doses on Liver Histological Appearance of Wistar rat*. Univ. Diponegoro. 2009.
8. Ohta A, Lukashev D, Jackson EK, Fredholm BB, Sitkovsky M. 1,3,7-Trimethylxanthine (Caffeine) May Exacerbate Acute Inflammatory Liver Injury by Weakening the Physiological Immunosuppressive Mechanism. *J Immunol* 2007; 179: 7431–7438.
9. Mennecozzi M, Landesmann B, Palosaari T, Harris G, Whelan M. Sex differences in liver Toxicity-Do female and male human primary hepatocytes react differently to toxicants in vitro? *PLoS One* 2015; 10: 1–23.
10. BPOM. Regulation from Head of The National Agency of Drug and Food Control No. HK.00.05.23.3644. www2.pom.go.id/hukum_perundangan: Indonesia, 2004www2.pom.go.id/3Ehukum_perundangan.
11. Klaassen CD. *Casarett and Doull's Toxicology: The Basic Science of Poisons*. 8th Ed. McGraw-Hill Education: New York, 2013.
12. Tsutsumi M, Lasker JM, Shimizu M, Rosman AS, Lieber CS. The intralobular distribution of ethanol-inducible P450IIE1 in rat and human liver. *Hepatology* 1989; 10: 437–446.
13. Kumar V, Abbas Abul K, Aster Jon C. *Robbins and Cotran Pathologic Basis of Disease*. 9th Ed. Elsevier Inc: Philadelphia, 2015.
14. Onwuka F I EO. The effect of caffeine on lipid peroxidation in the liver and kidney of Wister Albino rats. *J Phyther Pharmacol (2012)-11*, 2012; 9: 01–06.
15. Lu PZ, Lai CY, Wen-Hsiung C. Caffeine induces cell death via activation of apoptotic signal and inactivation of survival signal in human osteoblasts. *Int J Mol Sci* 2008; 9: 698–718.
16. Mubarak R. Effect of Red Bull energy drink on Rats' Submandibular salivary glands (Light and Electron microscopic Study). *J Am Sci* 2012; 2: 32.
17. Erdenetsogt Dungubat, Shiori Watabe, Arisa Togashi-Kumagai, Masato Watanabe, Yasuyuki Kobayashi, Naoki Harada, Ryoichi Yamaji, Toshio Fukusato GL, Takahashi, Badamjav Sevjid YT. Effects of Caffeine and Chlorogenic Acid on Nonalcoholic Steatohepatitis in Mice Induced by Choline Deficient, L-Amino Acid Defined, High-Fat Diet. *Nutrients* 2020; 12: 1, 11.
18. Saiki S, Sasazawa Y, Imamichi Y, Kawajiri S, Fujimaki T, Tanida I *et al*. Caffeine induces apoptosis by enhancement of autophagy via PI3K/Akt/mTOR/p70S6K inhibition. *Autophagy* 2011; 7: 176–187.
19. Li SQ, Wang P, Wang DM, Lu HJ, Li RF, Duan LX *et al*. Molecular mechanism for the influence of gender dimorphism on alcoholic liver injury in mice. *Hum Exp Toxicol* 2019; 38: 65–81.
20. Para O, Crispino P, Barone N, Macis S, Airasca L, Gnerre P *et al*. Sex differences in adverse drug reaction and liver disease. *Ital J Med* 2018; 12: 15–22.
21. Gasparin FRS, Carreño FO, Mewes JM, Gilgioni EH, Pagadigorria CLS, Natali MRM *et al*. Sex differences in the development of hepatic steatosis in cafeteria diet-induced obesity in young mice. *Biochim Biophys Acta - Mol Basis Dis* 2018; 1864: 2495–2509.
22. Gundert-Remy U. Pharmacokinetic and pharmacodynamic effects of caffeine. In: *EFSA STAKEHOLDERS MEETING ON THE SAFETY OF CAFFEINE* Brussels. 2015<https://www.efsa.europa.eu/sites/default/files/event/documentset/150305-p09.pdf>.
23. Tarnopolsky M. *Gender Differences in Metabolism: Practical and Nutritional Implications*. CRC Press: Washington DC, 1998.
24. Guy J, Peters MG. Liver disease in women: The influence of gender on epidemiology, natural history, and patient outcomes. *Gastroenterol Hepatol* 2013; 9: 633–639.