

Case Report

EFFECTIVENESS AND SAFETY OF PROLONGED NEEDLE DECOMPRESSION PROCEDURES IN TENSION PNEUMOTHORAX PATIENTS WITH COVID-19**Mirza Koeshardiandi**^{1a} , **Zulfikar Loka Wicaksana**¹ , **Bambang Pujo Semedi**² , **Yoppie Prim Avidar**² ¹ Department of Anaesthesiology and Reanimation, dr. Soedono General Hospital, Madiun, Indonesia² Departemen of Anesthesiology and Reanimation, Faculty of Medicine, Universitas Airlangga/dr. Soetomo General Academic Hospital, Surabaya, Indonesia^a Corresponding author: mirzakoes@gmail.com**ABSTRACT**

Introduction: Coronavirus disease-19 (COVID-19) has become a pandemic that is still ongoing today. This is a new challenge for health workers in handling emergency cases. Several COVID-19 patients arrived at the hospital with severe respiratory problems. Meanwhile, other pathological conditions causing respiratory failure must also be considered, such as pneumothorax. **Objective:** This study aimed to examine the effective emergency procedures to treat COVID-19 cases with tension pneumothorax. **Case report:** A 45-year-old male patient arrived with a referral letter from a pulmonologist with a diagnosis of simple pneumothorax and pneumonia. The patient also presented a positive SARS COV-2 PCR test result. The patient complained about a worsening of shortness of breath. A symptom of dry cough for 14 days was also reported. Chest radiograph examination subsequently indicated right tension pneumothorax. In the emergency ward, needle decompression procedure connected to the vial containing sterile intravenous fluids was performed. Re-examination of the chest x-ray demonstrated right pulmonary re-expansion. The patient was monitored and after four days, needle decompression was removed and no chest tube was inserted because complete resolution of the lungs had occurred. This case illustrates that tension pneumothorax causes worsening of the patient's condition with COVID-19 diagnosis. In another case of tension pneumothorax in a COVID-19 patient, needle decompression of the 2nd intercostal space and the mid-clavicular line was performed as initial treatment followed by chest tube insertion as definitive treatment. However, in this case, chest tube approach was not carried out because the patient had demonstrated clinical and radiological improvement and a worsening condition had not occurred. **Conclusion:** Prolonged needle decompression connected to a vial containing sterile intravenous fluids as deep as 2 cm from the water surface is an effective procedure in the management of tension pneumothorax even without the installation of a chest tube.

Keywords: COVID-19; Needle decompression; Simple pneumothorax; Tension Pneumothorax; Water sealed drainage.**ABSTRAK**

Pendahuluan: *Coronavirus disease-19* (COVID-19) telah menjadi pandemi yang masih berlangsung hingga saat ini. Hal tersebut menjadi tantangan baru bagi para tenaga kesehatan dalam penanganan kasus kegawatdaruratan. Pasien COVID-19 seringkali datang ke rumah sakit dalam keadaan gangguan pernafasan berat. Sedangkan keadaan patologi lain yang menyebabkan gagal nafas juga harus dipikirkan, salah satunya ialah pneumothorax. **Tujuan:** kami melaporkan kasus pasien terkonfirmasi COVID-19 disertai tension pneumothorax, penanganan kegawatdaruratan dibutuhkan untuk mencegah perburukan. **Laporan kasus:** Seorang laki-laki 45 tahun datang membawa surat rujukan dari dokter spesialis paru dengan diagnosis simple pneumothorax dan pneumonia. Pasien juga membawa hasil pemeriksaan PCR SARS COV-2 positif. Pasien mengeluhkan sesak nafas yang semakin memberat. Sebelumnya, pasien mengeluh batuk kering sejak 14 hari yang lalu. Kemudian dilakukan pemeriksaan foto radiologi thorax dengan hasil tension pneumothorax kanan. Di instalasi gawat darurat, dilakukan needle dekompresi yang dihubungkan dengan botol berisi cairan infus steril. Pemeriksaan foto thorax ulang menunjukkan re-ekspansi pulmonal kanan. Pasien dipantau dan pada hari ke-4 pasca pemasangan dilakukan pelepasan needle dekompresi dan tidak dilakukan pemasangan chest tube karena paru telah mengalami resolusi sempurna. Kasus ini menunjukkan tension pneumothorax yang menyebabkan perburukan kondisi

47

pasien dengan diagnosis utama COVID-19. Pada kasus lain yang telah dilaporkan tension pneumothorax pada pasien COVID19, dilakukan needle decompressi pada Space intercostalis 2 dan garis mid-klavikula sebagai tatalaksana awal yang kemudian diikuti oleh pemasangan chest tube sebagai tatalaksana definitif. Namun pada kasus ini tidak dilakukan pemasangan chest tube karena pasien telah mengalami perbaikan secara klinis dan radiologis serta tidak diikuti perburukan. **Kesimpulan:** Prolonged needle dekompresi yang disambungkan dengan botol berisi cairan infus steril sedalam 2 cm dari permukaan air merupakan prosedur efektif dalam tatalaksana tension pneumothorax walaupun tanpa diikuti pemasangan chest tube.

Kata kunci: COVID-19; *Needle decompression*; *Simple pneumothorax*; *Tension Pneumothorax*; *Water sealed drainage*.

Article info: Received October 21st 2021, Received in revised form October 25th 2021, Accepted January 13th 2022

INTRODUCTION

Coronavirus disease (COVID-19) has been declared a pandemic by the World Health Organization (WHO) and is still ongoing throughout the world today, including in Indonesia. The high number of cases is a challenge for doctors and paramedics in handling emergency cases, such as the use of standardized personal protective equipment when administering drugs to COVID-19 patients (1).

COVID-19 patients generally arrive at the emergency ward with respiratory problems which may lead to respiratory failure and death. Diagnosis and treatment of life-threatening emergency cases must be carried out immediately by medical personnel despite the limitations of physical examination procedures due to the use of standard personal protective equipment, such as auscultation, percussion, palpation in the diagnosis of tension pneumothorax.

The diagnosis of tension pneumothorax in an emergency is established through a medical history and physical examination. However, during a pandemic, such examination is often not feasible, therefore chest radiography is an important procedure that may confirm a clinical diagnosis (2). The radiological examination may be performed to confirm the diagnosis but should not delay the emergency care of a patient with a life-threatening tension pneumothorax. In hemodynamically stable

pneumothorax patients, a chest X-ray is possible to be performed immediately. However, if the patient's hemodynamic condition is unstable and accompanied by an acute respiratory failure, bedside ultrasound examination is the preferred alternative as immediate confirmation of the diagnosis (3).

COVID-19 patients generally experience various respiratory problems, including respiratory failure. However, doctors and medical personnel need to consider other causes of respiratory failure besides SARS-CoV2 infection, such as tension pneumothorax, pleural effusion, and pulmonary embolism.

This study highlights a case of a patient with confirmed COVID-19 with a progressive pneumothorax which progressed to a tension pneumothorax with progressively worsening shortness of breath. In this case, urgent emergency treatment was required for thoracic decompression to prevent further damage and worsening which may lead to death.

CASE REPORT

A 45-year-old male patient consulted a pulmonologist specialist and was diagnosed with simple pneumothorax and pneumonia. The patient was recommended for SARS COV-2 independent PCR examination and was referred to dr. Soedono General Hospital. After three days, the patient was admitted to the emergency ward of dr. Soedono General Hospital with a referral letter from the

pulmonologist. The results of an independent SARS COV-2 PCR examination with a positive result for COVID 19 and a chest X-ray 3 days earlier with radiological readings of a right pneumothorax with lung collapse towards the hilum with pneumonia were also presented (Figure 1).

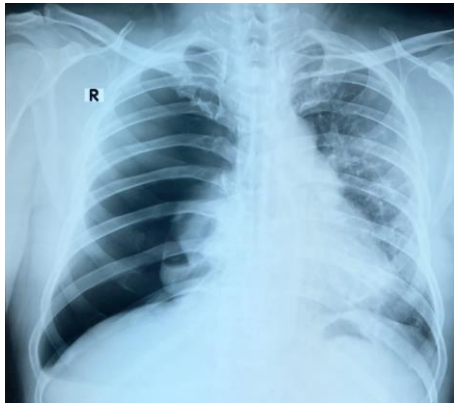


Figure 1. Right pneumothorax with lung collapse towards the hilum with pneumonia.

The patient reported a dry and frequent cough for more than 14 days and shortness of breath for 10 days. 3 days prior to admission to the emergency ward, the conditions worsened while patient was carrying out light activities such as walking few steps. The main complaint was a worsening of shortness of breath. The patient had not indicated symptoms of fever and had been an active smoker since young. The patient only had a history of dyspepsia and had no previous history of other serious illnesses. The patient had no history of chest trauma prior to the diagnosis of pneumothorax. The patient works as an office worker in a paint factory.

In the emergency ward, several medical personnel wore personal protective equipment and resuscitation equipment associated with initial emergency care. Physical examination indicated that the patient was *compos mentis* with normal general appearance. Clinically, the patient demonstrated shortness of breath

with 36 breaths per minute, 94% oxygen saturation without oxygen supplementation, blood pressure of 112/91 mmHg, tachycardia of 119 beats per minute, and body temperature of 36.1°C. Lung auscultation was not performed due to auscultation difficulty while in complete personal protective equipment. However, on percussion, hyper resonance in the right lung, decreased vocal fremitus, and minimal deviation of the trachea to the contralateral direction were detected.

Investigations

Anteroposterior chest radiological examination was performed and the results demonstrated a wide right tension pneumothorax with tracheal deviation and mediastinal shift to the contralateral direction and the left lung was compressed as illustrated in Figure 2.

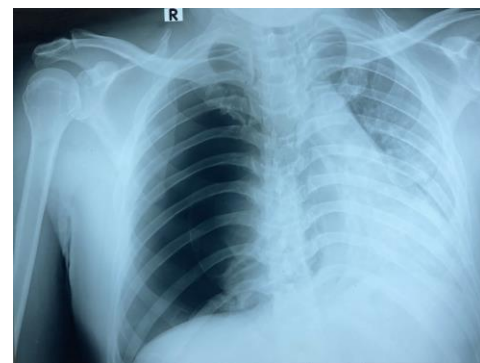


Figure 2. Right Tension Pneumothorax, tracheal deviation, and pneumonia.

The patient's complete blood on arrival at the ER indicated hemoglobin level of 14.5 g/dL, Platelets of 325x103/ μ L, Hematocrit of 44.1%, Leukocyte Count of 8.10x103/ μ L with Eosinophils at 4.9% (normal range 0-3%), Basophils at 1.2% (normal range 0-1%), Neutrophils at 57.6% (normal range 50-62%), Lymphocytes at 27.8% (normal range 25-40%) and monocytes at 8.4% (normal range 3-7%). Neutrophil Lymphocyte Ratio (NLR) was at

2.1 and Absolute Lymphocyte Count (ALC) at 2252.

Table 1. Laboratory Findings and Blood Gas Analysis.

Laboratory parameters	On arrival	Shortly after thoracocentesis	Next day
Hb	14.5	-	14.3
Platelets	325x10 ³	-	316x10 ³
Hematocryte	44.1%	42%	41%
Leukocyte	8.10x10 ³	-	7.72x10 ³
Eosinophils	4.9%	-	4.8%
Basophils	1.2%	-	0.5%
Neutrophils	57.6%	-	61.7%
Lymphocytes	27.8%	-	25.1%
Monocytes	8.4%	-	7.9%
Neutrophil Lymphocyte Ratio (NLR)	2.1	-	2.5
Absolute Lymphocyte Count (ALC)	2252	-	1938
D-dimer	-	-	2771.48
pH	-	7.4	7.36
pCO2	-	45	53
pO2	-	109	179
Na+	-	133	134
K+	-	3.8	3.9
Ca++	-	1.14	1.15
Glucose	-	103	87
Lactate	-	0.7	0.6
SO2	-	98%	100%

Blood gas analysis with arterial blood samples shortly after needle thoracocentesis indicated pH of 7.40, pCO₂ of 45 mmHg, pO₂ of 109 mmHg, Na⁺ of 133 mmol/L, K⁺ of 3.8 mmol/L, Ca⁺⁺ of 1.14 mmol/L, Glucose of 103 mg/dL, Lactate of 0.7 mmol/L, Hematocrit of 42%, and SO₂ of 98%.

The following day, patient's complete blood count was monitored. The results indicated Hemoglobin of 14.3 g/dL, Platelets of 316x10³/uL, Leukocyte Count of 7.72x10³/uL, Eosinophils of 4.8%, Basophils of 0.5%, Neutrophils of 61.7%, Lymphocytes of 25.1%, Monocytes of 7.9%, D-dimer of 2771.48 ng/mL, NLR of 2.5 and ALC of 1938. Blood gas analysis was performed with

arterial blood samples and the results indicated pH of 7.36, pCO₂ of 53 mmHg, pO₂ of 179 mmHg, Na⁺ of 134 mmol/L, K⁺ of 3.9 mmol/L, Ca⁺⁺ of 1.15 mmol/L, Glucose of 87 mg/dL, Lactate of 0.6 mmol/L, Hematocrit of 41%, and SO₂ of 100%.

Differential Diagnosis

Differential diagnosis of respiratory disorders with a history of upper respiratory tract infection in the pandemic era should be considered as COVID-19 until proven otherwise. Tension pneumothorax may occur due to COVID-19 (3). An important differential diagnosis with similar symptoms is pulmonary embolism. Patients with pulmonary embolism generally experience hypoxia, tachycardia, and often worsen if not treated immediately. Pulmonary embolism may also be a complication of COVID-19 causing acute deterioration in patients (4). COVID-19 may cause pulmonary embolism through several possible mechanisms, namely a severe inflammatory response and DIC may occur in COVID-19 patients, resulting in micro and macrovascular pulmonary thrombosis. A local virus-induced inflammatory reaction may also cause damage to the vessel wall (5).

Treatment

Based on clinical physical examination and medical history accompanied by diagnosis confirmation in the form of a chest X-ray, needle decompression was immediately performed for right tension pneumothorax using a size 16 cannula inserted in the 2nd intercostal space and mid-clavicular line. The 16-gauge cannula was subsequently connected using a macro set infusion tube which was connected to a bottle containing sterile infusion fluid at a position 50 cm below the patient and the end of the tube was 2 cm deep from the surface of the

water in the bottle. The outgoing air exited in the form of air bubbles in sterile infusion fluid during the decompression process. In performing the needle decompression procedure, insertion of a chest tube was prepared as the next treatment. However, it was not carried out since the patient experience clinical and radiological improvement. Rigorous evaluation was carried out periodically instead.

Results and Follow-Up

Emergency management of needle thoracocentesis resulted in immediate improvement in the patient which was characterized by re-expansion of the right lung from radiological examination (Figure 3), clinical improvement in the form of increased oxygen saturation to 99-100%, as well as respiratory physiology improvement in the form of decreased respiratory rate and normalization of heart rate. The patient was subsequently admitted to the COVID-19 ward due to a positive PCR result.

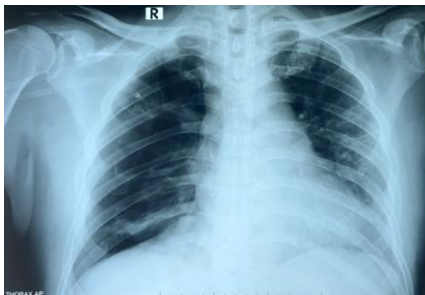

Figure 3. Right pneumothorax improved and pneumonia was minimal

After needle thoracocentesis procedure, the patient was still provided with oxygen supplementation in the form of NRM 10 lpm to support optimal oxygenation. The following day after the admission to the ward, patient's conditions did not deteriorate clinically or radiologically (Fig. 4). Hence, the oxygenation was reduced using a nasal

cannula from 2-5 Lpm. On the 3rd day of treatment, the patient did not use any oxygen supplementation since the capillary oxygen saturation had stabilized and no symptoms related to the respiratory system were detected. On the 4th day of treatment, the needle thoracocentesis in the right intercostal midclavicular line which had been connected to a bottle filled with sterile intravenous fluids was no longer inflated and, radiologically, there was no deterioration (Fig. 5). Therefore, a removal was performed and a chest tube was not installed since the patient had already been in a good condition and the lungs had undergone complete resolution without any respiratory-related symptoms requiring further invasive treatment in the form of a chest tube.

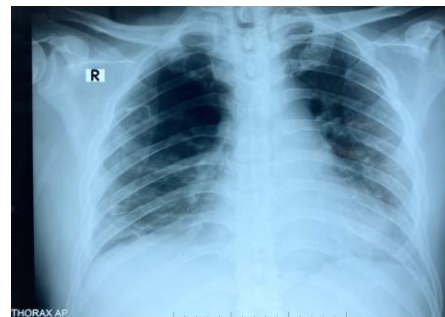


Figure 4. Right pneumothorax improved and pneumonia was minimal

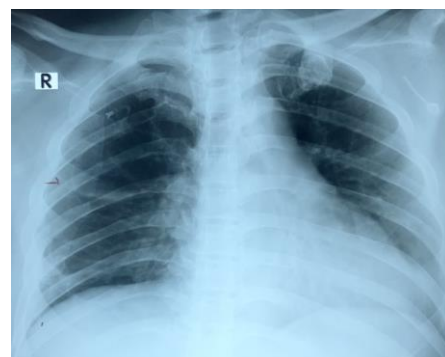

Figure 5. Minimal right pneumothorax

This procedure is not a standard treatment for pneumothorax, but it may be performed considering its effectiveness and the complications of the case. Effectiveness may

be determined by clinical improvement, radiological improvement, and regular close laboratory monitoring. If this approach does not provide immediate clinical, radiological, or laboratory improvement, a chest tube installation must be carried out.

On the 9th day of treatment, a chest X-ray was performed to evaluate the lung condition related to post-needle thoracocentesis in tension pneumothorax. This is necessary to establish an early diagnosis of recurrent pneumothorax. The results of the final chest radiological examination did not indicate a pneumothorax and lung expansion seemed optimal (Figure 6). Based on several considerations, such as clinical parameters, the patient was asymptomatic, whereas laboratory examinations and the SARS COV-2 PCR examination indicated negative results. On the 10th day, the patient was released for outpatient treatment.

In this case, a follow-up of 14 days after discharge was carried out and there were no complaints and symptoms associated with recurrent pneumothorax or other respiratory syndroms. It was reported that the patient was able to continue his usual physical activities.

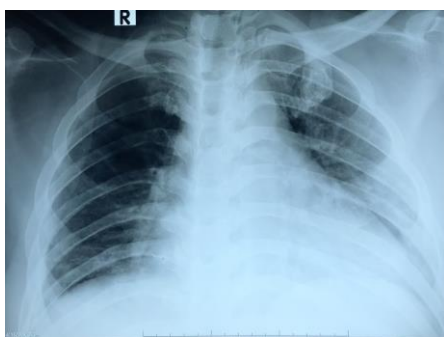


Figure 6. Chest X-ray showed no abnormalities and pneumothorax

DISCUSSION

This case highlights a tension pneumothorax that causes the patient's condition to worsen with COVID-19 primary

diagnosis. Diagnosis of pulmonary pathology due to COVID-19 is very important to direct the appropriate therapy. If correct diagnosis is delivered, it may result in inappropriate treatment and life-threatening consequences. This study could not confirm whether the pneumothorax in this patient was due to COVID-19 infection or whether the two diseases simply coexisted (4).

Pneumothorax is divided into two types, namely primary and secondary. Primary pneumothorax is a pneumothorax that occurs without a clear cause and no other underlying disease. Several risk factors that may increase the occurrence of primary pneumothorax include smoking habits, gender, and family history of pneumothorax. Secondary pneumothorax, on the other hand, occurs due to other lung pathologies. Secondary spontaneous pneumothorax may occur in the presence of COPD, pulmonary tuberculosis, necrotizing pneumonia, and ARDS (6,7).

The prevalence of pneumothorax in COVID-19 patients is 1-2%. ARDS in COVID-19 may lead to complications of spontaneous pneumothorax due to volume- and pressure-related alveolar rupture (8). Histological examination of lung biopsy samples taken from patients who died from COVID-19 revealed desquamation of pneumocytes and formation of hyaline membranes suggestive of ARDS (7). Therefore, structural changes due to SARS-CoV-2 infection may cause secondary spontaneous pneumothorax complications.

The most common symptoms of a pneumothorax are shortness of breath and chest pain that may radiate to the chest or ipsilateral shoulder. Physical examinations generally detect increased respiratory rate, asymmetric chest expansion, decreased tactile fremitus, hyper resonant percussion, and decreased lung breath sounds. Investigations

that may be carried out include a chest X-ray. Chest X-ray may detect that the ipsilateral lung has collapsed and that the mediastinum shifts to the contralateral side (9). If patient is in unstable condition, diagnosis confirmation may be made by ultrasonography (USG), if available (10). If patient is in a stable condition and the diagnosis could not be determined from a chest X-ray, a chest CT scan may be performed. However, this examination is not recommended to be carried out routinely (2).

In another reported case of tension pneumothorax in a COVID-19 patient, needle decompression of the 2nd intercostal space and the mid-clavicular line was performed as initial treatment followed by chest tube insertion as definitive treatment (2). Presently, chest tube is the definitive therapy in pneumothorax cases (6). However, in this case, no chest tube was attached and only a decompression needle was connected to a bottle containing sterile IV fluids as deep as 2 cm from the surface of the water (water seal drainage). This step was selected because the patient had experience clinical and radiological improvement and a worsening did not occur afterwards.

A water shield drainage system was carried out by connecting a needle catheter that has been inserted into the pleural cavity with an infusion set (i.v. line) which on the other end was immersed in a sterile fluid (infusion fluid or 500-1000ml aqua dest) as deep as 2 cm. Sterile fluid was placed ± 60 cm below the puncture hole. The end of the IV line that was immersed into the sterile fluid aimed to keep the pleural cavity at a pressure of ± 2 cm H₂O. When the air pressure in the pleural cavity exceeded 2cm H₂O (tension pneumothorax), the pressure would subsequently be released as bubbles through the system. The distance of 60cm between the

puncture hole and sterile fluid aimed to prevent fluid from entering the pleural cavity during the inspiration phase.

During the pandemic, when treating patients with respiratory failure, there have been tendencies to assume the diagnosis as COVID-19. However, other possible diagnoses that may cause respiratory failure conditions must still be considered. In addition, routine auscultation is difficult to carry out due to concerns regarding the transmission of SARS-CoV-2 infection and the use of personal protective equipment that may limit the examination (4). This condition did not cause delays in providing emergency care to patients with life-threatening tension pneumothorax.

CONCLUSION

In this case, prolonged needle decompression connected to a bottle of sterile intravenous fluids 2 cm from the water surface (water seal drainage) is an effective procedure in the treatment of tension pneumothorax not followed by chest tube insertion.

Evaluation of the effectiveness of this method was carried out through close observation of clinical conditions, radiological and laboratory evaluations regularly. In this case, four days of installation demonstrated improvements. This procedure illustrates good efficacy, although preparation of chest tube insertion equipment as definitive therapy must be available and easily accessible.

REFERENCES

1. Kalantary S, Khadem M, Golbabaie F. Personal Protective Equipment for Protecting Healthcare staff during COVID-19 Outbreak: A Narrative Review. *Adv J Emerg Med* [Internet]. 2020;4(2s):61. Available from:

- <https://fem.tums.ac.ir/index.php/fem/article/view/409>
- Jalota R, Sayad E. Tension Pneumothorax. In: StatPearls. StatPearls Publishing; 2021. of COVID-19. Case Rep Med. 2021;2021.
 - Flower L, Carter JPL, Rosales Lopez J, Henry AM. Tension pneumothorax in a patient with COVID-19. BMJ Case Rep. 2020;13(5):1–4.
 - Scudiero F, Silverio A, Maioc M Di, Russod V, Citrob R, Personenia D, et al. Pulmonary embolism in COVID-19 patients: prevalence, predictors and clinical outcome for. Thromb Res. 2021;198(January):34–9.
 - Zarogoulidis P, Kioumis I, Pitsiou G, Porpodis K, Lampaki S, Papaiwannou A, et al. Pneumothorax: from definition to diagnosis and treatment. J Thorac Dis. 2014;6(4):S372–6 – S376.
 - Spiro JE, Sisovic S, Ockert B, Böcker W, Umar Shahzad M, Han J, Ramtoola MI, Lamprou V, Gupta U. Spontaneous Tension Pneumothorax as a Complication Siebenbürger G. Secondary tension pneumothorax in a COVID-19 pneumonia patient: a case report. Infection [Internet]. Springer Berlin Heidelberg; 2020;48(6):941–4. Available from: <https://doi.org/10.1007/s15010-020-01457-w>
 - Martinelli AW, Ingle T, Newman J, Nadeem I, Jackson K, Lane ND, et al. COVID-19 and pneumothorax: A multicentre retrospective case series. Eur Respir J. 2020;56(5).
 - McKnight CL, Burns B. Pneumothorax. In: StatPearls. StatPearls Publishing; 2021.
 - Wong A, Galiabovitch E, Bhagwat K. Management of primary spontaneous pneumothorax : a review. 2019;89:303–8.