

**Case Report****PRILOCAINE 2% FOR SPINAL ANESTHESIA IN INCARCERATED INGUINAL HERNIA SURGERY WITH CONGESTIVE HEART FAILURE****Mirza Koeshardiandi<sup>1a</sup>** , **Pandhu Mahendra Bisama<sup>1</sup>** , **Dian Muhammad Gibran<sup>1</sup>** <sup>1</sup> Department of Anesthesiology and Reanimation Dr. Soedono General Hospital, Madiun, Indonesia<sup>a</sup> Corresponding author: [mirzakoes@gmail.com](mailto:mirzakoes@gmail.com)**ABSTRACT**

**Introduction:** Congestive heart failure (CHF) is a disease caused by abnormalities in the myocardium. This abnormality reduces the heart's ability to pump blood throughout the body. Anesthetic drugs have a major cardiovascular effect under general and regional anesthesia. **Objective:** This study aims to examine the effect of prilocaine as a subarachnoid block regional anesthetic drug in patients undergoing non-cardiac surgery with comorbid heart failure. **Case Report:** A 59-year-old man came complained of a lump in his left upper groin that had been present since a day before his admission to the hospital. The lump could not be inserted. The patient felt pain in the lump area with a visual analog score (VAS) of 7-8. His blood pressure was 138/84 mmHg, pulse rate was 104 times per minute, respiration rate was 22 times per minute, temperature was 36°C for axillary measurement, oxygen saturation was 92% based on room oxygen, and VAS was 7-8. The abdominal examination revealed a lump in the patient's left upper groin that could not be reinserted, hyperemic, and painful when pressed. With an EF Teich of 17.1%, the echocardiographic examination revealed that the dimensions of the patient's heart chambers (RV and LV dilatation) and LV systolic function had decreased. **Conclusion:** Stable hemodynamics in non-cardiac surgery with a relatively short duration is the main choice for HF patients. Spinal anesthesia with a regimen of 2% prilocaine at a dose of 80 mg plus 0.1 mg morphine resulted in stable hemodynamics and low pain scores in patients with comorbid congestive heart failure undergoing non-cardiac surgery.

**Keywords:** Cardiovascular disorders; Congestive heart failure; Hernia; Prilocaine; Spinal Anesthesia**ABSTRAK**

**Pendahuluan:** Penyakit jantung kongestif (CHF) merupakan penyakit yang disebabkan karena adanya kelainan pada otot miokardium sehingga kemampuan jantung untuk memompa darah ke seluruh tubuh berkurang. Obat – obatan anestesi mayoritas memiliki efek kardiovaskular, baik dalam anestesi umum maupun regional. **Tujuan:** Studi ini bertujuan untuk melihat efek prilokain sebagai obat anestesi regional subarachnoid blok pada pasien yang menjalani operasi non-cardiac dengan komorbid penyakit gagal jantung. **Laporan Kasus:** Seorang laki-laki berusia 59 tahun, datang dengan keluhan muncul benjolan pada lipatan pada kiri sejak 1 hari sebelum masuk rumah sakit, benjolan tidak dapat dimasukkan. Pasien merasa nyeri pada area benjolan dengan nilai visual analog score (VAS) 7-8. Tanda vital menunjukkan tekanan darah 138/84 mmHg, nadi 104 kali per menit reguler, respirasi 22 kali per menit, suhu 36o Celcius pengukuran aksila, saturasi oksigen 92% menggunakan oksigen ruangan, dan nilai Visual Analog Scale (VAS) 7-8. Pemeriksaan abdomen didapatkan benjolan pada lipatan paha kiri pasien yang tidak dapat dimasukkan kembali, hiperemis, dan terasa nyeri saat ditekan. Pemeriksaan ekokardiografi pada ditemukan dimensi ruang jantung RV dan LV dilatasi, fungsi sistolik LV menurun dengan EF Teich 17,1%. **Kesimpulan:** Hemodinamik yang stabil pada operasi non-cardiac yang relatif singkat durasinya menjadi pilihan utama untuk pasien HF. Anestesi spinal dengan regimen prilokain 2% dengan dosis 80mg ditambahkan dengan morfin 0,1mg menghasilkan hemodinamik yang stabil dan skor nyeri yang rendah pada pasien dengan komorbid gagal jantung kongestif dalam operasi non-cardiac.

**Kata kunci:** Gangguan kardiovaskular; Gagal Jantung Kongestif; Hernia; Prilokain; Anestesi Spinal**Article info:** Received: April, 28<sup>th</sup> 2023; Revised: May, 4<sup>th</sup> 2023; Accepted: July, 19<sup>th</sup> 2023; Published: July, 29<sup>th</sup> 2023

## INTRODUCTION

Congestive heart failure (CHF) is a disease caused by abnormalities in the myocardium. This abnormality reduces the heart's ability to pump blood throughout the body. CHF is mainly caused by decreased function of the left ventricle. Patients with CHF have a lower ejection fraction (EF) of less than 50% compared to normal patients. In the hospital, CHF patients with serum urea levels  $>15\text{mmol/L}$ , systolic pressure  $<115\text{ mmHg}$ , serum creatinine  $>2.72\text{ mg/dL}$ , N-terminal pro-brain natriuretic peptide (NT-pro-BNP)  $>986\text{ pg/mL}$ , and a left ventricular EF  $<45\%$  have a high mortality rate (1).

This condition complicates non-cardiac surgeries in CHF patients. Most anesthetic drugs have cardiovascular effects in general and regional anesthesia. Mortality rates during and after surgery for CHF patients increase with the cardiovascular changes often occurring in non-cardiac surgery. A study showed that in CHF patients, the mortality rate reached 8% of the 24,975 patients who underwent surgery (2).

On this occasion, we report the case of a patient with obstructive ileus due to an incarcerated inguinal hernia with comorbid CHF. In this case, the patient must immediately undergo hernioplasty to prevent mortality. Alternative methods and safe anesthetic drugs are needed for these patients to reduce mortality during and after surgery. This report examines the effect of prilocaine as a subarachnoid block regional anesthetic drug in patients with comorbid heart failure undergoing non-cardiac surgery.

## CASE REPORT

A 59-year-old man complained of a lump in his left groin that had been present since a day before his hospital admission. The lump could not be inserted. The patient felt pain

around the lump. He added that he felt weak, nauseous and vomited more than ten times. However, he did not experience any issues with eating and drinking.

The patient had a history of being hospitalized for having a stroke in 2012. At that time, the patient was hospitalized for nine days. The patient also has a history of diabetes mellitus since 2010. However, the patient rarely takes medication, and in 2019, his diabetes mellitus medication was replaced with insulin, injected once a day. The patient had no history of heart disease, kidney disease, or malignancy. The patient stated that his legs had been swollen frequently since the beginning of 2022. However, the patient never felt short of breath, did not feel tired when walking, and did not feel chest pain.

The patient said that in 2015 he had an operation due to a hernia in the same location. The lump reappeared in the left groin in 2017, but the lump was still able to be reinserted. The patient said the lump came out when he was tired or lifting things.

This patient's initial physical examination in the ward revealed a general state of pain and a Glasgow Coma Score (GCS) of E4V5M6. His blood pressure was 138/84 mmHg, pulse was 104 beats per minute regular, fill and lifting strength, respiration was 22 times per minute for the thoracoabdominal type, his temperature was  $36^{\circ}\text{C}$  for the axillary measurements, oxygen saturation was 92% using room oxygen, and VAS 7-8.

On his neck, the jugular venous pressure (JVP) was  $5 + 3\text{ cm H}_2\text{O}$ , the trachea did not deviate, and the neck lymph nodes did not enlarge. The thoracic examination, which included an examination of the lungs and heart, revealed crackles in 1/3 of the patient's right and left lung bases. A cardiac examination revealed a shift in the heart boundaries, indicating an enlarged heart.

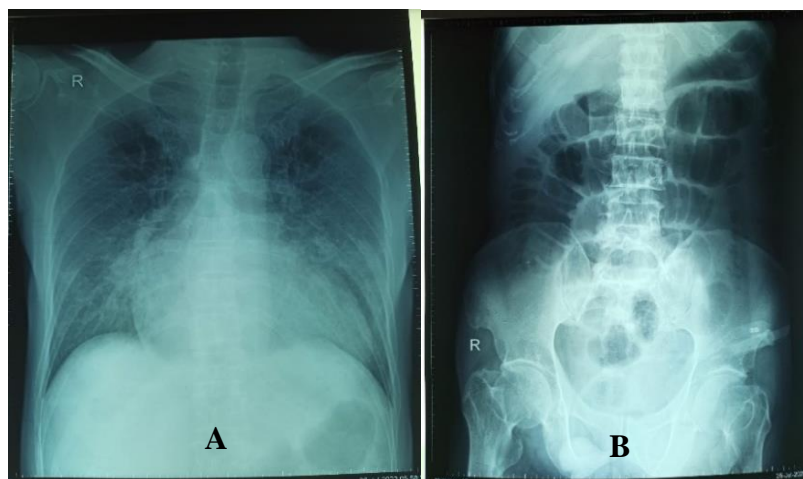
The abdominal examination showed that the abdominal wall looked flat, and no ascites were seen. Percussion of the tympani occurs in all regions of the abdomen. Furthermore, on palpation, the liver and spleen are not palpable. The lump on the patient's left groin could not be put back, was hyperemic, and painful when pressed. An auscultation examination revealed normal peristalsis with bowel sounds of 10 times per minute.

The examination of the patient's extremities showed no edema in the upper and

lower extremities. Acral on all four extremities were warm with a Capillary Refill Time (CRT) of < 2 seconds. He also had a wound on the forefinger of his right toenail.

### ADVANCED EXAMINATION

The patient's chest X-ray showed pulmonary edema and cardiomegaly. On the other hand, a plain X-ray of the abdomen revealed a dilated small intestine and possible obstructive ileus ([Figure 1](#)).



**Figure 1.** A: Chest X-ray; B: Abdominal X-ray

**Table 1.** Laboratory Examination

Laboratory Parameter	Result
Hemoglobin	14.9
Platelet	164x10 <sup>3</sup>
Hematocrit	47.9%
Leukocytes	10.44x10 <sup>3</sup>
Sodium	143
Potassium	4.00
Chloride	101
Blood Glucose	88
Creatinine	1.23
SGOT/SGPT	20/10

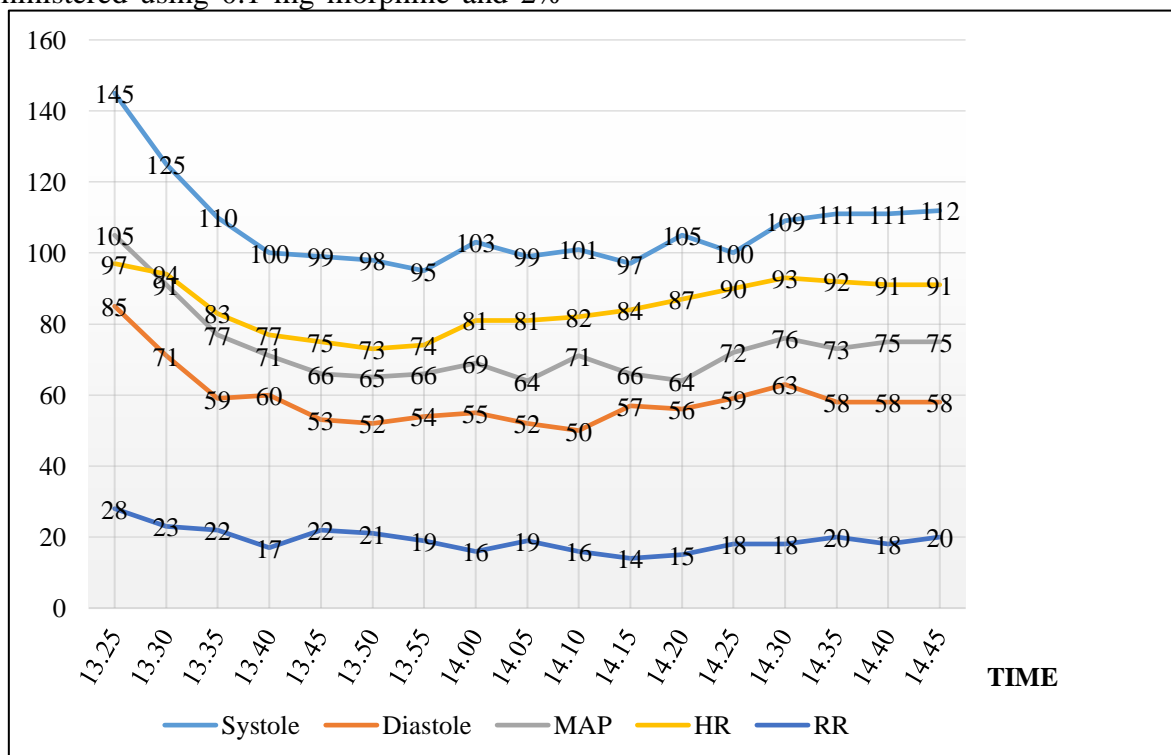
An echocardiographic examination on July 27, 2022, found that the patient had a dilated RV and LV heart chamber dimensions, decreased LV systolic function with a Teich EF

of 17.1%, pseudonormal LV diastolic function, and decreased RV systolic function with a TAPSE of 1.77 cm. The evaluation of the valves revealed mild mitral regurgitation, mild aortic regurgitation, mild tricuspid regurgitation, and trivial pulmonary regurgitation. There was also an eccentric LVH (LVMI = 123.1 g/m<sup>2</sup>), LASEC (+), LVSEC (+), and an apical-septal thrombus with a diameter of 1.63 x 0.77 cm. Moreover, the IAS was intact, the IVS was intact, and the PDA was negative. There was also pulmonary hypertension with a severe probability, and the laboratory examination showed normal blood test results, as shown in [Table 1](#).

## DIAGNOSIS AND THERAPY

The examination results indicated that the patient was diagnosed with an incarcerated inguinal hernia with congestive heart failure. The patient was scheduled for a hernioplasty with spinal anesthesia. Based on the anamnesis data, a physical examination, a laboratory examination, an ECG, a chest X-ray, and echocardiography, the patient was classified as ASA 3 with NYHA III heart failure. The patient was sitting and identifying the 4<sup>th</sup> to 5<sup>th</sup> lumbar intervertebral space at the time of anesthesia. We then performed asepsis and antisepsis. Subsequently, spinal anesthesia was administered using 0.1 mg morphine and 2%

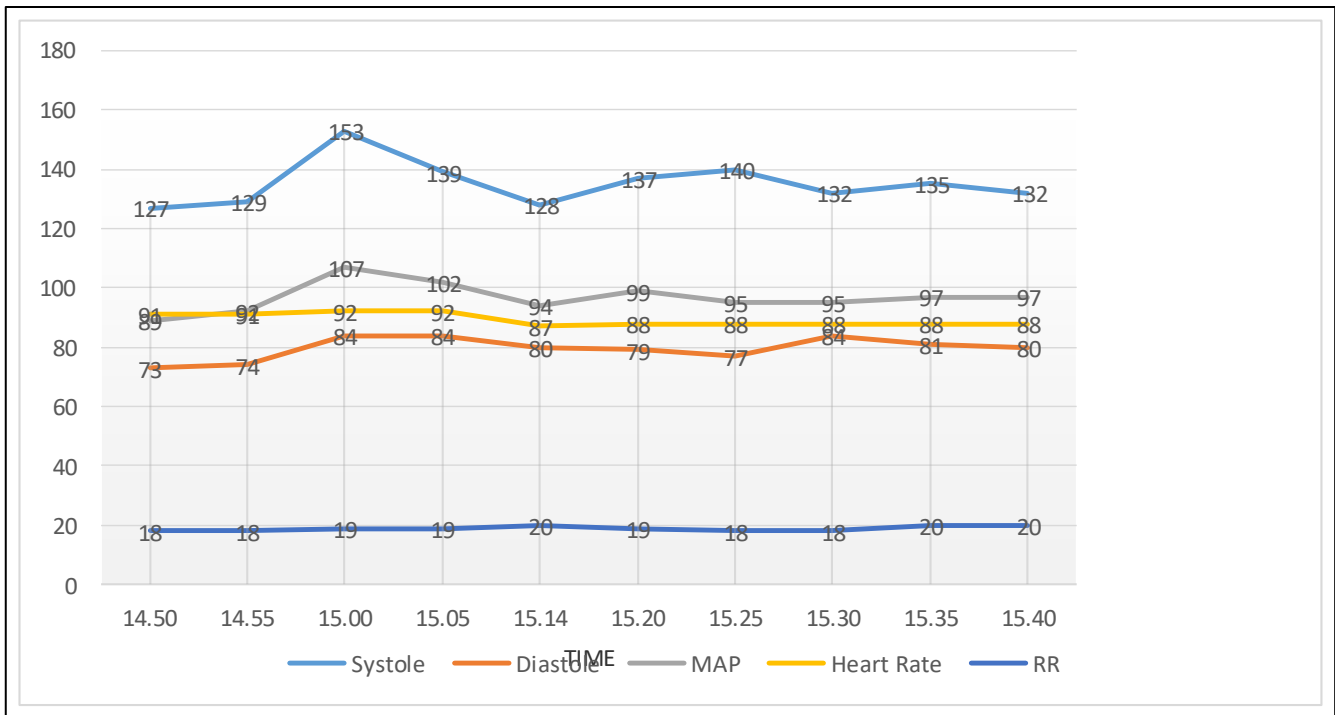
prilocaine 80 mg by intrathecal injection. The sensory block was achieved at a height of T10 at 7 min using a pinprick test and cotton swab evaluation. The respiratory muscles were evaluated by asking the patient if there were any complaints regarding ventilation effort and by observing the patient's breathing pattern. Ten minutes after the intrathecal injection of anesthesia was declared effective, the surgery started. The procedure went smoothly for 76 minutes, with relatively stable hemodynamics and respiratory parameters and no vasopressor injection, inotrope, or other analgesia administered (Figure 2).



**Figure 2.** Hemodynamic Parameters During Surgery

After the operation, the patient was transferred to the recovery room and observed. Patient monitoring showed that the patient could move his legs at 15:05, could move the soles of his feet at 15:30, could move his knee at 15:37, and could move his entire leg at 15:40. The patient's hemodynamic and respiratory

parameters were relatively stable postoperatively. The patient also had a VAS score of 0 from the beginning of the operation to the end of the postoperative observation (Figure 3). After the motor and sensory blocks had completely disappeared, the patient was mobilized.



**Figure 3.** Hemodynamic Parameters After Surgery

## DISCUSSION

A hernia occurs when abdominal tissue or organs come out of the abdominal cavity due to a hole caused by congenital abnormalities, weakness, or abdominal wall abnormalities. Based on anatomical location, hernias most commonly occur in the inguinal area (95%). An acute incarcerated hernia is a hernia type that requires immediate surgery (4). The most common complaint in patients with incarcerated hernias is pain. Patients with incarcerated inguinal hernias must undergo surgery as soon as possible to prevent perforation and adhesion of the incarcerated organ (5).

Cardiovascular dysfunction is a disorder that is often found in preoperative patients undergoing both emergency and elective surgery. Patients with weak cardiac ejection fraction pose a challenge for anesthesiologists for anesthesia induction before surgery. Thus, it is necessary to have a complete preoperative plan and preparation. According to the latest reference, the neuraxial block is the best option

for patients with low ejection fractions. Meanwhile, spinal anesthesia is the best option for patients with cardiovascular disorders undergoing surgery below the umbilicus. Spinal anesthesia can cause hemodynamic fluctuations in the patient, but the type of drug and the dose used can overcome these problems (3).

Although spinal anesthesia has long been considered a safe anesthetic technique, this does not mean it is without risks or side effects. Hypotension, nausea, and vomiting are some side effects that occur during spinal anesthesia, with an incidence ranging from 7 to 42%. Some other side effects of spinal anesthesia, such as severe bradycardia, cardiac arrest, and dysrhythmias, can also occur during the procedure. However, the incidence of these events is not very high (6).

Postganglionic sympathetic nerves are important in controlling heart function and vascular tone. The most important cardiovascular effects are related to the blockade of vasoconstrictor fibers (below T4),

resulting in vascular dilatation and inhibition of cardiac sympathetic fibers, leading to decreased chronotropic and inotropic action on the myocardium (T1–5). The spinal anesthetic blocks produce the peripheral sympathetic and splanchnic fiber block but are limited to the mid-thoracic to lumbar regions (T5-L4). This sympathetic block produces vasodilation in the blocked area with compensatory vasoconstriction of blood vessels in the unblocked area. Circulating catecholamines are released from the adrenal medullary system because increased activity in each unblocked fiber in the splanchnic nerve contributes to increased sympathetic activity below and above the blockade level (7).

Bradycardia during spinal anesthesia is caused by two factors: blockade of the sympathetic nerves to the heart muscles and decreased venous return to the heart. Cardiac muscle fibers exit from T1-T4 such that a sympathetic block at the T1 level can completely block sympathetic outflow to the heart. In addition, this degree of sympathetic block during spinal anesthesia is often associated with peripheral vasodilation and decreased preload. In the absence of an adequate venous return to the heart (preload), sympathetic denervation is estimated to result in only a 10% reduction in heart rate from baseline (8).

Prilocaine is a local anesthetic that belongs to the amide class. Prilocaine has moderate potency and a rapid duration and onset of action (9). Several studies reported that prilocaine causes significantly fewer neurologic symptoms than lidocaine or mepivacaine. Ratsch et al. first compared 10% hyperbaric prilocaine to 0.5% hyperbaric bupivacaine. Eighty-eight patients scheduled for lower extremity surgery with a maximum duration of 45 minutes under spinal anesthesia were randomized to receive 15 mg of hyperbaric

bupivacaine 0.5% or 60 mg of hyperbaric prilocaine 2%. The two groups were comparable in achieving T12 analgesic levels, block intensity, and time of onset of maximum sensory block. T12 analgesic levels were maintained for 60 minutes with prilocaine and 120 minutes with bupivacaine, whereas regression of the motor block took 135 and 210 minutes, respectively. In addition, the time to spontaneous voiding was 306 minutes with prilocaine compared to 405 minutes with bupivacaine. Both study drugs achieved equivalent sensory and motor block quality, providing adequate surgical anesthesia for at least 1 hour. However, 2% hyperbaric prilocaine was superior to 0.5% hyperbaric bupivacaine regarding faster offset, faster time to first spontaneous voiding, faster recovery room, and home release. The use of hyperbaric solutions restricts the block to only the location to be operated. Unilateral spinal anesthesia can also minimize the extent of sympathetic block, resulting in minimal disruption of cardiovascular homeostasis and reducing the incidence of clinically relevant hypotension by 5% to 7% (10).

Using low-dose morphine in combination with an anesthetic regimen for spinal anesthesia can provide optimal analgesic effects and reduce side effects. Research conducted by Koning et al. showed that the use of morphine with bupivacaine can reduce the need for IV opioids and reduce pain scores (11). Another study also suggested that the use of low-dose morphine, of about 0.1 mg morphine, can reduce pain scores after surgery compared to other analgesic regimens (12).

No literature mentions the minimum dose of prilocaine in spinal anesthesia. These studies only state that to avoid the toxic effects of prilocaine, the maximum dose that can be used is 600 mg. In this case, a dose of 2% prilocaine with a dose of 80 mg was used. In patients with

comorbid congestive heart failure, prilocaine 2% at 80 mg plus 0.1 mg morphine produced a stable hemodynamic response and low pain scores during and after surgery.

## CONCLUSION

Stable hemodynamics and thorough patient assessment are crucial in reducing morbidity and mortality during and after surgery, especially for patients with comorbidities such as congestive heart failure. The use of spinal anesthesia with a prilocaine regimen resulted in stable hemodynamics and reduced morbidity and mortality in this patient, compared to other local anesthetic regimens. Further research is needed to determine the effectiveness of prilocaine compared to other local anesthetic regimens. Nevertheless, using a safe anesthetic method and regimen tailored to the patient's comorbidities is essential for reducing mortality during and after surgery.

## Acknowledgment

None

## Conflict of Interest

There is no conflict of interest.

## Funding Disclosure

None

## Authors' Contribution

All authors have contributed to all processes in this research.

## REFERENCES

1. Inamdar AA, Inamdar AC. Heart failure: Diagnosis, management and utilization. *J Clin Med.* 2016; 5(7): 62. doi: 10.3390/jcm5070062. [[PubMed](#)]
2. Faxén UL, Hallqvist L, Benson L, Schrage B, Lund LH, Bell M. Heart failure in patients undergoing elective and emergency noncardiac surgery: still a poorly addressed risk factor. *J Card Fail.* 2020; 26(12): 1034-1042. [[PubMed](#)]
3. Salami OF, Onuoha KM, Uduagbamen PK, Olayinka BA, Alade OA. Anaesthetic management of the elderly with low ejection fraction undergoing non-cardiac surgery. *Res J Health Sci.* 2020; 8(3): 209-213. [[WebPage](#)]
4. Yang XF, Liu JL. Acute incarcerated external abdominal hernia. *Ann Transl Med.* 2014; 2(11): 1-9. doi: 10.3978/j.issn.2305-5839.2014.11.05. [[WebPage](#)]
5. Lee SR. Feasibility of laparoscopic transabdominal preperitoneal hernioplasty for incarcerated inguinal hernia. *J Soc Laparoendosc Surg.* 2021; 25(3). doi: 10.4293/JLS.2021.00053. [[WebPage](#)] [[PubMed](#)]
6. Vahapoglu A, Turkmen U, Gungor H, Koseoglu O. Effects of spinal anaesthesia related complication and demographic distribution on patient satisfaction following caesarean section. *Med Sci Int Med J.* 2019; 0: 1. [[WebPage](#)]
7. Gonçalves Dias RS, Neves Soares JH, Santos e Castro D dos, Albuquerque Gress MAK de, Machado ML, Otero PE, Ascoli FO. Cardiovascular and respiratory effects of lumbosacral epidural bupivacaine in isoflurane-anesthetized dogs: the effects of two volumes of 0.25% solution. *PLoS One.* 2018; 13(4). [[WebPage](#)] [[PubMed](#)]
8. Lairez O, Ferré F, Portet N, et al. Cardiovascular effects of low-dose spinal anaesthesia as a function of age: An observational study using echocardiography. *Anaesth Crit Care Pain Med.* 2015; 34(5): 271-276. doi: 10.1016/j.accpm.2015.02.007. [[PubMed](#)]
9. Manassero A, Fanelli A. Prilocaine hydrochloride 2% hyperbaric solution for intrathecal injection: A clinical review.

- Local Reg Anesth. 2017; 10: 15-24. doi:
10. Boublik J, Gupta R, Bhar S, Atchabahian A. Prilocaine spinal anesthesia for ambulatory surgery: A review of the available studies. *Anaesth Crit Care Pain Med.* 2016; 35(6): 417-421. [[WebPage](#)] [[PubMed](#)]
  11. Ban M, Choi YS, Koo BN. Analgesic effect of intrathecal morphine combined with low-dose bupivacaine on postoperative analgesia after liver resection: A randomized controlled study. *J Pers Med.* 2022; 12(2): 211. doi: 10.3390/jpm12020211. [[WebPage](#)] [[PubMed](#)]
  12. Anabah T, Olufolabi A, Boyd J, George R. Low-dose spinal anaesthesia provides effective labour analgesia and does not limit ambulation. *Southern African Journal of Anaesthesia and Analgesia.* 2015; 21(1): 27-30. [[WebPage](#)]