


Original Research Article

COMPARISON OF AUSCULTATION METHOD VERSUS LUNG ULTRASOUND TECHNIQUE TO EVALUATE THE ACCURACY OF POSITIONING OF LEFT DOUBLE LUMEN TUBE IN PATIENTS UNDERGOING CARDIOTHORACIC SURGERYSwati Agarwal^{1a} , Indu Verma¹, Jai Sharma¹, Nivedita Dagar¹¹ Department of Anesthesia, Sawai Man Singh Medical College and attached group of Hospitals, Jaipur, Rajasthan, India^a Corresponding Author: gargswati441@gmail.com**ABSTRACT**

Introduction: Cardiothoracic surgery is a complex and highly specialized medical field requiring precise surgical techniques and meticulous patient management. One critical aspect of this type of surgery is the accurate placement of the endobronchial double-lumen tube (DLT), which facilitates lung isolation and one-lung ventilation (OLV) during the procedure. Proper positioning of the DLT is essential to ensure adequate oxygenation, prevent complications, and optimize surgical access. **Objective:** This study aimed to compare the accuracy of positioning of the left DLT by the auscultation method versus the lung ultrasound technique in patients undergoing cardiothoracic surgery in both supine and lateral positions. **Material and methods:** A prospective, observational, and cross-sectional study was conducted in a single group of 62 patients based on the eligibility criteria. After general anesthesia, a DLT was inserted and rotated until resistance. Placement was confirmed by auscultation, ultrasound, and fiberoptic bronchoscopy. The evaluation process was done initially in a supine position, followed by a lateral position. **Results:** After insertion of the left DLT, initially evaluated in the supine position, sensitivity and specificity for auscultation were found to be 65.2% and 37.5%, respectively, sensitivity and specificity for ultrasonography were 82.6% and 75%, respectively. The accuracy of lung ultrasound at 80.7% (69.2%-88.6%) was higher than the accuracy of auscultation at 58.1% (45.7%-69.5%). This was followed by evaluation in lateral position, where sensitivity and specificity for auscultation were found to be 76.1% and 25% respectively, sensitivity and specificity for ultrasonography were 95.7% and 62.5%, respectively. The accuracy of lung ultrasound at 87.1% (76.6%-93.3%) was higher than the accuracy of auscultation at 62.9% (50.5%-73.8%). **Conclusion:** Lung ultrasound is a superior method for assessing lung isolation and determining Double Lumen Tube position as compared to auscultation.

Keywords: Auscultation; Double Lumen Tube; Fiberoptic Bronchoscopy; Lung Ultrasound**ABSTRAK**

Pendahuluan: Bedah kardiotoraks merupakan bidang medis yang kompleks dan sangat khusus yang memerlukan teknik bedah yang presisi dan manajemen pasien yang teliti. Salah satu aspek penting dalam bedah kardiotoraks adalah penempatan yang akurat dari endobronkial *double-lumen tube* (DLT) yang memfasilitasi isolasi paru dan ventilasi paru tunggal (OLV) selama prosedur. Penempatan DLT yang tepat sangat penting untuk memastikan oksigenasi yang memadai, mencegah komplikasi, dan mengoptimalkan akses bedah. **Tujuan:** Studi ini bertujuan untuk membandingkan akurasi penempatan DLT kiri dengan metode auskultasi versus teknik ultrasonografi paru pada pasien yang menjalani bedah kardiotoraks dalam posisi supin dan lateral. Studi prospektif, observasional, dan potong lintang yang dilakukan pada satu kelompok yang terdiri dari 62 pasien berdasarkan kriteria kelayakan. Setelah anestesi umum, DLT dimasukkan dan diputar hingga ada resistensi. Penempatan dikonfirmasi dengan auskultasi, ultrasonografi, dan bronkoskopi serat optik. Proses evaluasi dilakukan awalnya dalam posisi supin diikuti dengan posisi lateral. **Hasil:** Hasil menunjukkan bahwa setelah pemasangan DLT kiri, evaluasi awal dalam posisi supin, sensitivitas dan spesifisitas untuk auskultasi adalah 65,2% dan 37,5% masing-masing, dan sensitivitas serta spesifisitas untuk ultrasonografi adalah 82,6% dan 75% masing-masing. Akurasi ultrasonografi paru 80,7% (69,2%-88,6%) lebih tinggi daripada akurasi auskultasi 58,1% (45,7%-69,5%). Evaluasi selanjutnya dalam posisi lateral menunjukkan bahwa sensitivitas dan spesifisitas untuk auskultasi adalah 76,1% dan 25% masing-masing, dan sensitivitas serta spesifisitas untuk ultrasonografi adalah 95,7% dan 62,5% masing-masing. Akurasi ultrasonografi paru 87,1% (76,6%-93,3%) lebih tinggi daripada akurasi auskultasi 62,9% (50,5%-73,8%). **Kesimpulan:**



Ultrasonografi paru adalah metode yang lebih unggul untuk menilai isolasi paru dan menentukan posisi Double Lumen Tube dibandingkan dengan auskultasi.

Kata kunci: Auskultasi; Bronkoskopi serat optic; *Double Lumen Tube*; Ultrasonografi paru

Article info: Received: May 27, 2024; Revised: June 12, 2024; Accepted: July 7, 2024; Published: July 29, 2024

INTRODUCTION

Selective one-lung ventilation is commonly accomplished during thoracic surgery with the use of a double-lumen tube (DLT), most commonly a left-sided DLT. To allow for surgical access to the chest cavity, one-lung ventilation entails breathing into one lung while allowing the other lung to collapse. One lung ventilation serves the protective purpose of preventing the other lung's fluid, such as blood, lavage fluid, malignant or purulent secretions, or other potentially hazardous substances, from harming the first lung. To isolate the lungs, methods such as bronchial blockers, double lumen tubes, and selective endobronchial intubation can be used. Anesthetic treatment in thoracic surgery relies on the correct placement of double-lumen tubes (DLTs), which are commonly employed to create one-lung ventilation. The exact location of the DLTs is critical for effective lung isolation.

Electrical Impedance Tomography (EIT) (1), clinical evaluation by auscultation and observation of chest wall movement, VivaSight DLT (2), lung ultrasound (3), and fiberoptic bronchoscopy (4) are some of the methods that have developed over the years to evaluate DLT installation. The use of lung ultrasonography in airway management has expanded substantially. To determine the distribution of ventilation in different regions, researchers have used indicators from lung ultrasound (LUS), such as lung sliding (LS) and lung pulse (LP), and they have discovered that LUS is a straightforward, non-invasive way to ensure

lung isolation after DLT placement (5,6). This is in addition to the many other approaches that have been developed for confirming DLT positions. There are two main types of techniques: those that look at where the double lumen tube (DLT) is in the airway (e.g., fluoroscopy, fiber-optic bronchoscopy (FOB)) and those that look at how the lungs collapse and breathe (e.g., electrical impedance tomography, computerized analysis of breath sounds using microphones, auscultation, and capnography). The availability of instruments and operator expertise are the two main factors that influence the use of these techniques, which are combined to find the correct placement of DLT. For the visualization of DLTs in the trachea and bronchia, fiber-optic bronchoscopy has been considered the gold standard (7).

Lung ultrasonography is a useful tool for evaluating one-lung ventilation because it clearly and efficiently shows the diaphragm and pleura in motion. This research looks at how well lung ultrasonography and auscultation work for confirming the left DLT position in patients who are having cardiothoracic surgery while lying on their back or on their side.

Identifying how often patients need to be repositioned after going from a supine to a lateral position and keeping track of how long it takes for auscultation and ultrasonography to establish the patient's position are secondary goals. Although there have been numerous studies comparing the efficacy of lung ultrasonography and auscultation in confirming DLT insertion in the supine position, relatively few have examined the results in both positions.



MATERIAL AND METHODS

Following clearance from the S.M.S. Medical College Ethics Committee and registration in Clinical Trials Registry India (CTRI/2023/09/057585) on April 26, 2023, this prospective, observational, and cross-sectional investigation was carried out in the Cardio-Thoracic Operation Theatre at SMS Hospital. Everyone involved, including patients and their relatives, signed an informed consent. After approval, this study included 62 elective patients. In every case, the left-sided DLT was employed, and the tube size was determined by the tracheal diameter estimated from the chest X-ray. Typically, Fr DLT values of 35, 37, and 39 were selected, while 33 and 41 Fr DLT were also utilized in certain instances. Patients must be at least 18 years old and categorized as having an ASA Grade II or III cardiac or thoracic surgery for elective purposes. Patients who have undergone thoracic surgery or have had a tracheostomy are not eligible to participate. The patient's pulmonary function test results are abnormal, and they have a history of pleurodesis, pneumothorax, pleural effusion, or empyema (ASA Grade IV). We found that 86% of USG and 63% of auscultation cases were sensitive when done in the supine position with left DLT. This was based on the assumptions of 80% research power and a 0.05 alpha error. The initial 56 patients needed for the sample size were increased to 62 patients for the current trial, with the expectation of a 10% dropout rate.

Upon entering the operating room, the results of the pre-anesthesia assessment and the nil per oral status of the patients were checked. A variety of standard routine monitors were connected, and baseline parameters such as heart rate (HR), systolic blood pressure (SBP), diastolic blood pressure (DBP), mean arterial pressure (MAP), temperature, and oxygen saturation (SpO₂) were recorded. Under local

anesthesia, we inserted catheters into the femoral artery and internal jugular vein to allow for invasive blood pressure and central venous pressure monitoring. Injections of 0.3 mg/kg of etomidate induced general anesthesia, whereas injections of 1 mg/kg of rocuronium relaxed the muscles. With the patient's height serving as a guide for the depth of DLT insertion, the trachea was intubated using a left double-lumen tube under direct laryngoscopy. After the endobronchial cuff was passed through the vocal cord, the stylet was removed, and the tube was rotated 90° (towards the left side) and advanced until resistance was felt. Inflating the tracheal and bronchial cuffs after intubation allowed us to record the patient's initial depth of insertion. Tracheal intubation was confirmed by an appropriate ETCO₂.

Evaluation in Supine Position

Both approaches started evaluating DLT consecutively immediately after intubation. One point was the meeting point between the midclavicular line and the second intercostal space; another was the midclavicular line and the fifth intercostal space. In the midaxillary line, at comparable intercostal intervals, the other two points were put in the axilla. During the auscultation evaluation, these four places were used to assess the DLT in a supine posture. While lying on one side of the hemithorax, all four sites were auscultated. Shortly after intubation, puffing up the tracheal cuff allowed us to hear patients breathing on either side of the chest. Once the tracheal lumen was pinched and the bronchial cuff was inflated, the patient's left side could be heard breathing while the right side was silent. When we clamped the bronchial lumen, we were able to hear breath sounds on the right side but none on the left side, confirming our previous observations. As a result, the DLT site was auscultated, confirming successful placement. It was necessary to take

three deep breaths while examining each point. Manual ventilation was used to conduct the auscultation technique.

After the auscultation evaluation was completed, we moved on to the USG approach, which involved preparing an ultrasound probe (EVITRON) before intubation. Our investigation utilized a linear probe with a frequency of 12 MHz. The same spots that were fixed during the auscultation were also used for evaluation. During the USG examination, the standard pleural sliding sign was noted on both sides before clamping. After inflating the bronchial cuff and clamping the tracheal lumen, we can see pleural sliding between the shadows of the left ribs, but there is no such evidence on the right. In cases where pleural sliding was present, the M mode revealed a beach sign; in cases where no such sliding was present, the barcode sign was visible. There was thought to be ventilation on one side of the lung if pleural sliding was present, and no ventilation on the other side if no pleural sliding was present.

Following auscultatory and ultrasonographic evaluations, the location of DLT was confirmed using a fiberoptic bronchoscope (FOB). To achieve adequate lung isolation and proper placement of the bronchial cuff, repositioning was performed by FOB.

Evaluation in Lateral Position

The patient was moved from a supine posture to a lateral one because that's how most thoracic procedures are done. The patient was re-evaluated for DLT placement after changing positions using the same steps as when they were supine: auscultation, USG, and FOB.

Statistical Analysis

Tables and figures were used to display the compiled data. To assess nominal and categorical data, the Chi-square test was used to summarize them as percentages and

frequencies. To compare the two approaches, we calculated the means and standard deviations of the continuous variables and ran the numbers through a paired t-test. Using fiberoptic as the gold standard, we computed the sensitivity, specificity, positive and negative predictive value, and diagnostic accuracy, at a 95% confidence interval for both approaches. At a p-value of < 0.05 , statistical significance was considered. We used the statistical program Epi info version 7.2.1.0 to conduct all of our analyses.

RESULTS AND DISCUSSION

This study was done on 62 eligible patients of >18 years of age with ASA Grades II and III undergoing elective cardio-thoracic surgery under general anesthesia after obtaining informed written consent. The study was conducted in a single group in which the placement of the left DLT was assessed using two methods; auscultation and ultrasonography sequentially, one after the other, and final confirmation was done using a fiberoptic bronchoscope in both the supine and lateral positions. No significant differences were found among the general demographic data of patients such as age, height, weight, body mass index, tracheal width, and the type of surgery as shown in [Table 1](#).

Table 1. General Data of Patient Demographics

Patient Demographics	Left DLT N (%) / Mean \pm SD
ASA	
II	40 (64.5)
III	22 (35.5)
Age (years)	42 \pm 15
Gender	
Male	50 (80.6)
Female	12 (19.4)
Height (cm)	161.9 \pm 9.69
Weight (kg)	58.71 \pm 12.15
BMI (kg/m ²)	22.35 \pm 1.01
Tracheal width (cm)	17.19 \pm 2.05

The evaluation time was compared between auscultation and ultrasonography in both the supine and lateral position and it was found that the ultrasonography technique required more time for evaluation as compared to the auscultation method. Furthermore, the evaluation time in the lateral position was slightly longer than in the supine position for both auscultation and ultrasonography, and the results were statistically significant, as shown in [Table 2](#).

Table 2. Comparison of evaluation time by Auscultation and USG

Variable	Auscultation (sec) Mean±SD	USG (sec) Mean±SD	p-Value
Supine Position	99.48 ± 13.65	108.7 ± 13.94	<0.001*
Lateral Position	102.5 ± 16.69	112.7 ± 12.34	<0.001*

*This result based on a paired t-test with p-value < 0.05 means significant.

From the observation of our study as seen in [Figure 1](#), we found that 48.3% of left DLT were found as good placement, and 9.6% were found as bad placement by both auscultation and fibreoptic in the supine position. Similarly, when observed by USG, we found that 61.2% of left DLT were found to be in good placement, and 19.3% were found to be in bad placement by both USG and fibreoptic in the supine position. In the same way, when similar observations were done in lateral position, we found that 56.4% of left DLT were found to be in good placement and 6.4% were found to be in bad placement by both auscultation and fibreoptic. Likewise, when observed by USG in lateral position, we found that 70.9% of left DLTs were found as good placement and 16.1% were found as bad placement by both USG and fibreoptic.

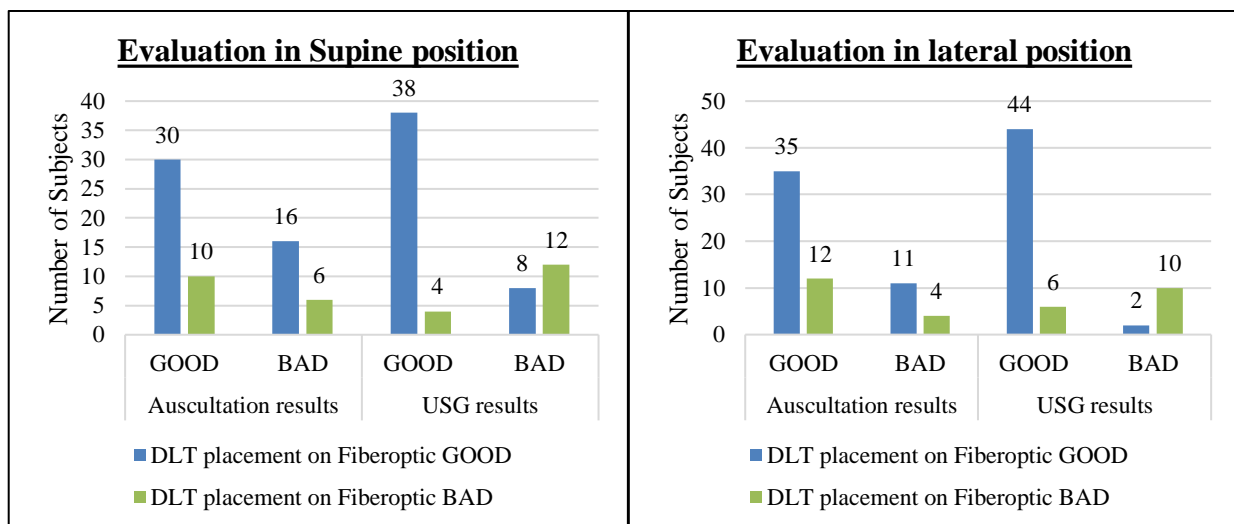


Figure 1. Evaluation in Supine and lateral Position between Auscultation and USG about FOB

From [Table 3](#), it is known that when left-sided DLT was used, in the supine position, sensitivity and specificity for auscultation were 65.2% (50.8%-77.3%) and 37.5% (18.5%-61.4%) respectively, and sensitivity and specificity for ultrasonography were 82.6% (69.3%-90.9%) and 75% (50.5%-89.8%),

respectively. The Positive Predictive Value (PPV) of auscultation was 75% (59.8%- 85.8%) and Negative Predictive Value (NPV) was 27.3% (13.2%- 48.2%). Whereas, the Positive Predictive value of USG was 90.5% (77.9%-96.2%) and the Negative Predictive Value was 60% (38.7%- 78.1%). The accuracy of

ultrasonography at 80.7% (69.2%-88.6%) was higher than the accuracy of auscultation at 58.1% (45.7%-69.5%) in the supine position.

While, left-sided DLT was used, in lateral position, sensitivity and specificity for auscultation were 76.1% (62.1%-86.1%) and 25% (10.2%-49.5%) respectively, and sensitivity and specificity for ultrasonography was 95.7% (85.5%-98.8%) and 62.5% (38.6%-81.5%). The Positive Predictive Value of

auscultation was 74.5% (60.5%- 84.8%) and the Negative Predictive Value was 26.7% (10.9%-52%). Whereas for USG, the Positive Predictive Value was 88% (76.2%-94.4%) and the Negative Predictive Value was 83.3% (55.2%-95.3%). The accuracy of ultrasonography at 87.1% (76.6%-93.3%) was higher than the accuracy of auscultation at 62.9% (50.5%- 73.8%) in the lateral position.

Table 3. Diagnostic parameters of auscultation and USG method for diagnosis of the correct position of DLT

Parameter	Auscultation Supine position	USG Supine position	Auscultation Lateral position	USG lateral position
Sensitivity	65.2% (50.8-77.3)	82.6% (69.3- 90.9)	76.1% (62.1-86.1)	95.7% (85.5- 98.8)
Specificity	37.5% (18.5- 61.4)	75% (50.5- 89.8)	25% (10.2- 49.5)	62.5% (38.6- 81.5)
Positive Predictive Value	75% (59.8- 85.8)	90.5% (77.9- 96.2)	74.5% (60.5- 84.8)	88% (76.2- 94.4)
Negative Predictive Value	27.3% (13.2- 48.2)	60% (38.7- 78.1)	26.7% (10.9- 52)	83.3% (55.2- 95.3)
Diagnostic accuracy	58.1% (45.7- 69.5)	80.7% (69.2- 88.6)	62.9% (50.5- 73.8)	87.1% (76.6- 93.3)

*Data in the table shows the Sensitivity, Specificity, PPV, NPV, and Diagnostic accuracy with the 95% Confidence Interval

From the above observations, we can conclude that lung ultrasound demonstrated higher sensitivity and specificity as compared to auscultation in both the supine and lateral positions.

Furthermore, lung ultrasound had higher PPV and NPV than auscultation. This meant that the positive and negative results from lung ultrasound were more likely to accurately show where the DLT was. Besides this, lung ultrasound also demonstrated significantly higher diagnostic accuracy compared to auscultation in both positions.

If we want to avoid intraoperative hypoxia and accompanying complications during thoracic procedures, we have to make sure that the DLT is properly positioned to allow for one-lung ventilation and sufficient lung separation. Clinical approaches such as auscultation and examination of chest wall motions, as well as electrical impedance tomography, lung ultrasonography, fibreoptic bronchoscopy

(FOB), and other similar techniques, have been employed to verify the location of DLT. To assess the efficacy of DLT in supine and lateral positions, our research compared the auscultation method with a lung ultrasonography methodology.

We found that ultrasonography had higher diagnostic accuracy than auscultation in both the supine and lateral positions of the body. Comparing the transthoracic LUS with clinical methods for left DLT position confirmation in 105 patients, Alvarez-Diaz et al. (6) demonstrated that LUS had better sensitivity (98.6% vs. 84.5%), specificity (52.9% vs. 41.1%), accuracy (83.8% vs. 70.4%), PPV (81.4% vs. 75.0%), and NPV (94.7% vs. 56.0%), similar to our study.

The distribution of ventilation is most often evaluated by auscultation, a non-invasive technique. However, this is frequently subjective and is dependent on factors such as tidal volume, underlying lung tissue



consistency, skin-to-pleura distance, operating room noise level, stethoscope sensitivity, individual hearing acuity, and so on. On top of that, the conductivity of sound from the contralateral side might also confuse auscultating breath sounds on one side of the chest. The results of the study by Liaquat Ali et al. (8) show that auscultation cannot be relied upon to confirm the site of a DLT, in their study, all patients demonstrated proper DLT positioning with appropriate ventilation during auscultation, however only 60% of patients had correct DLT placement and 40% of patients had partially misplaced DLT on fiberoptic; as a result, FOB was required to ensure correct placement. In most cases, FOB is necessary to validate the DLT position because prior research has shown that auscultation is not an accurate procedure.

Recent years have seen increased acceptance of lung USG for endotracheal tube positioning confirmation in critical care situations and its utility in OT airway management in general (9–11). The diaphragm and pleura's motion, which are indirect quantitative and qualitative markers of lung expansion (12), can be seen in real-time with the non-invasive lung USG approach. A hyperechoic line, or "pleural line," depicts the boundary between the chest wall's soft tissue and the ventilated lung in an intercostal ultrasonographic image. Pleural sliding, which manifests as a back-and-forth movement of this pleural line, is instantly apparent at the pleural interface during lung breathing. Pulsatile movement at the pleural interface becomes visible as soon as ventilation is halted; this happens in both right and left selective intubation, but is more common on the left side since the heart is closer and is termed as "lung pulse" sign. Therefore, functional isolation and proper DLT positioning can be presumed if

USG shows a pleural sliding sign on one side and a lung pulse indication on the other part.

Finally, FOB was used to confirm the position of DLT after auscultation and USG had evaluated it. How DLT is positioned and the results are affected by changes in body position as well. Since most thoracic surgeries are performed in the lateral position, and because it is often required to readjust the position of the DLT to prevent the tube displacement while changing positions from supine to lateral, it would be insufficient to simply discuss the evaluation in the supine position. Consequently, we conducted additional research in the lateral position after the evaluation was conducted in the supine position using both methodologies. In both roles, the procedures followed the same pattern.

Additionally, we evaluated the assessment times required to validate the DLT location using both methods and positions. We discovered that auscultation had a significantly quicker evaluation time than ultrasound. Also, both approaches took more time while evaluating in a lateral position. In contrast to Ramsingh et al. (13), whose study recorded an evaluation time of 162 ± 38 seconds for ultrasound, our investigation found a shorter duration. Methodological discrepancies likely explained these variations; Ramsingh evaluated the pleural gliding sign in addition to the cricothyroid membrane and ETT cuff. Because of this, his study's evaluation duration was lengthened.

When compared to ultrasound, our findings showed that auscultation had inferior sensitivity and specificity in both the supine and lateral positions. Ultrasound also outperformed auscultation in terms of diagnostic accuracy in both supine and lateral positions. Ultrasound excelled in comparison to auscultation. Ultrasound makes it easy to see the diaphragmatic excursion, lung pulse, and

pleural sliding sign (14,15). Ultrasound has a higher specificity for verifying the DLT location is accurate, as Po-Kai Wang et al. (16) discovered, which is consistent with our findings. Also useful was the M-mode ultrasound, which shows two signs—the beach sign when pleural sliding is present and the barcode indication when it isn't. Previous research has shown that the lung sliding sign can be used in clinical practice to certify that the left-sided double-lumen tube is properly positioned (17). Ultrasound, on the other hand, is less biased and more objective. Ultrasound could supplant auscultation in DLT positioning.

Repositioning was done if needed after final confirmation using fiberoptic bronchoscopy to establish the exact position. As bronchoscopy allows for direct viewing of the bronchial structure and cuff location, it is useful for patients with abnormal anatomy or challenging airway situations (18). Confirmation via FOB is necessary for both positions since thoracic procedures are typically performed in the lateral position, which increases the risk of dislocating the DLT during position changes. While 5.3% of tubes were found to be dislocated when placed in the lateral decubitus position by auscultation in the study by S M Mireskandari et al., FOB reported a higher number of 10.5% (19). When it concluded that FOB must be routinely and continuously used in modern practice, multiple other researches reached the same conclusion (20).

Therefore, compared to clinical approaches, transthoracic lung ultrasonography is better for confirming DLT location because it is a quick and non-invasive procedure. As a result, when paired with FOB, lung USG is preferable to clinical techniques. Nevertheless, it may not serve as a replacement for FOB, as FOB offers numerous noteworthy benefits over lung ultrasonography. For instance, FOB can

guide the positioning of the right DLT so that the lumen is in line with the right upper lobe's orifice. If DLT has progressed beyond secondary carina, FOB can readily detect it. It is recommended to use FOB when adjusting DLT during surgery.

Our investigation had several limitations. To start, with a sample size of only 62 patients, our study was on the smaller side. Secondly, any patients who needed right DLT were not included in our study; we solely focused on left DLT. Finally, our findings are based on the individuals who were eligible to participate in our study; this may have introduced selection bias as we did not include patients who did not have pleural sliding. So, we don't know what we could have learned from the patients who weren't a part of our study.

CONCLUSION

Our study findings indicate that lung ultrasonography is a more effective tool than auscultation for accurately positioning the left double-lumen tube during elective thoracic surgery, regardless of whether the patient is in a supine or lateral position. This result needs further study which requires a bigger sample size and includes patients with right DLT and tracheostomised patients and patients with pleural pathology whose breath sounds and/or pleural sliding are not obvious.

Acknowledgment

The authors thank the surgical and nursing staff of Cardiothoracic and Vascular Surgery, Sawai Man Singh Medical College.

Conflict of interest

The authors declare there is no conflict of interest.

Funding

This research received no specific grant from any funding agency in the public, commercial, or not-for-profit sectors.

Authors' Contributions

SA, IV, JS, ND: study concept and design, data collection and processing, analysis and interpretation of the data, drafting of the manuscript, revision of the manuscript for important intellectual content, administrative, technical, or material support, Literature search, and study supervision.

REFERENCES

1. Heines SJH, Becher TH, van der Horst ICC, Bergmans DCJJ. Clinical Applicability of Electrical Impedance Tomography in Patient-Tailored Ventilation: A Narrative Review. *Tomography* [Internet]. 2023;9(5):1903–32. [[WebPage](#)]
2. Onifade A, Lemon-Riggs D, Smith A, Pak T, Pruszynski J, Reznik S, et al. Comparing the rate of fiberoptic bronchoscopy use with a video double lumen tube versus a conventional double lumen tube - A randomized controlled trial. *J Thorac Dis* [Internet]. 2020;12(11):6533–41. [[Scopus](#)]
3. Parab SY, Kumar P, Divatia J V, Sharma K. A prospective randomized controlled double-blind study comparing auscultation and lung ultrasonography in the assessment of double lumen tube position in elective thoracic surgeries involving one lung ventilation at a tertiary care cancer institute. *Korean J Anesthesiol* [Internet]. 2018 Sep 12;72(1):24–31. [[WebPage](#)]
4. Nazemroaya B, Kazemi Goraji F, Honarmand A, Jafarpisheh MS. Point-of-care ultrasound and auscultation versus fiberoptic bronchoscope in determining the position of double-lumen tube. *Tehran Univ-Med-J* [Internet]. 2023 Feb 1;80(11):894–902. [[WebPage](#)]
5. Elsabeeny WY, Ibrahim MA, Abed SM, Shehab NN. Role of Lung Ultrasound in Confirmation of Double Lumen Endotracheal Tube Placement for Thoracic Surgeries: A Prospective Diagnostic Accuracy Study. *Anesth Pain Med* [Internet]. 2022;12(5):e132312. [[WebPage](#)]
6. Álvarez-Díaz N, Amador-García I, Fuentes-Hernández M, Dorta-Guerra R. Comparison between transthoracic lung ultrasound and a clinical method in confirming the position of double-lumen tube in thoracic anesthesia. A pilot study. *Revista Española de Anestesiología y Reanimación (English Edition)* [Internet]. 2015;62(6):305–12. [[Science Direct](#)]
7. Anand LK, Singh M, Singh J, Kapoor D. 'Fibreoptic in Tracheal Lumen' (FIT) technique: A novel real-time double-lumen tube placement technique with fiberoptic bronchoscope. *Saudi J Anaesth* [Internet]. 2019;13(4). [[WebPage](#)]
8. Ali L, Mahboob S, Ali U. Left Double Lumen Endotracheal Tube: Bronchoscopic Finding After Confirmation of Correct Position of Tube With Auscultation. *Pakistan Armed Forces Medical Journal* [Internet]. 2020 Jan 27;70(Suppl-1):S15-19. [[WebPage](#)]
9. Sarangi B, Reddy VS, Walimbe A, Oswal JS, Patro SK. Utility of upper airway ultrasound for confirmation of endotracheal tube placement in the pediatric intensive care unit setting. *Journal of Pediatric Critical Care* [Internet]. 2020;7(4). [[WebPage](#)]
10. Shebl E, Said AM. The role of tracheal ultrasonography in confirming endotracheal tube placement in respiratory intensive-care unit patients. *Egypt J Chest*



- Dis Tuberc [Internet]. 2019;68(3).
[WebPage]
11. Chen WT, Wang MY, Jiang TT, Tang M, Ye QH, Wang HY, et al. Transtracheal ultrasound for confirmation of endotracheal tube placement in the intensive care unit: a systematic review and meta-analysis. *Eur Rev Med Pharmacol Sci.* 2022 Jul;26:8224–33. [PubMed]
 12. Yamaguchi Y, Moharir A, Burrier C, Nomura T, Tobias J. Point-of-Care Lung Ultrasound to Evaluate Lung Isolation During One-Lung Ventilation in Children: Narrative Review. *Medical Devices: Evidence and Research.* 2020 Nov 17;13:385–9. [PubMed]
 13. Ramsingh D, Frank E, Haughton R, Schilling J, Gimenez KM, Banh E, et al. Auscultation versus Point-of-care Ultrasound to Determine Endotracheal versus Bronchial Intubation: A Diagnostic Accuracy Study. *Anesthesiology* [Internet]. 2016 May 1;124(5):1012–20. [WebPage]
 14. Bhoil R, Ahluwalia A, Chopra R, Surya M, Bhoil S. Signs and lines in lung ultrasound. *J Ultrason.* 2021 Aug 16;21:e225–33. [PubMed]
 15. Kabil A, Sobh E, Elsaed M, Hassanin H, Yousef I, Eltrawy H, et al. Diaphragmatic excursion by ultrasound: reference values for the normal population; a cross-sectional study in Egypt. *Multidiscip Respir Med.* 2022 Jun 1;17. [PubMed]
 16. Wang PK, Lin TY, Su IM, Chang KV, Wu WT, Özçakar L. Preoperative lung ultrasound for confirming the double-lumen endotracheal tube position for one-lung ventilation: A systematic review and meta-analysis. *Heliyon* [Internet]. 2023;9(4):e15458. [Science Direct]
 17. Bernard N, Ender J, Turton E. P08-8 - The use of lung-ultrasound to confirm correct placement of left sided double lumen tubes. *J Cardiothorac Vasc Anesth* [Internet]. 2018;32:S97–8. [Science Direct]
 18. Ngamjarus C. n4Studies: Sample Size Calculation for an Epidemiological Study on a Smart Device. *Siriraj Med J* [Internet]. 2016 Jun 9;68(3):160–70. [WebPage]
 19. Mireskandari SM, Darabi G, Rafieian S, Jafarzadeh A, Samadi S, Karvandian K, et al. Double-lumen Tube Position Confirmation with Fiberoptic Bronchoscope after Turning Patients into Lateral Position: Is It Necessary? *Journal of Iranian Medical Council* [Internet]. 2022;5(1):178–84. [WebPage]
 20. Lim J, Kim IY, Byun SH. The Effect of Fiberoptic Bronchoscopy-guided Technique for Placement of a Left-sided Double-lumen Tube on the Intubation Performance Compared with the Conventional Method Using a Macintosh Laryngoscope. *The Open Anesthesia Journal.* 2020 Jul;14:115–22. [WebPage]