

The Effect of Combination of Soy Milk and Calcium in Orthodontic Tooth Movements on Female Rats With Estrogen Deficiency

Vanda Ramadhani, Ida bagus Narmada, Thalca Hamid
Departement of Orthodontics, Faculty of Dental Medicine
Universitas Airlangga
Surabaya – Indonesia

ABSTRACT

Background: Orthodontic treatments in elderly patients are influenced by hormonal changes and their effects on the process and prognosis of the treatment. Estrogen deficiency in the post-menopausal period results in bone loss. The process of bone remodeling during Orthodontic treatment for elderly patients is also influenced by the balance of resorption and bone formation processes. **Purpose:** This study aimed to determine the effect of soymilk combination calcium on orthodontic tooth movement in female rats with estrogen deficiency. **Methods:** Twenty rats were divided into 5 groups with 4 samples for each group. All samples were performed bilateral ovariectomy. The control group (K) was observed on day 0, P1 group was observed on day 7, P2 group was observed on day 14, P3 group was observed on day 7, and P4 group was observed on day 14. NiTi closed coil spring was placed between the incisor and maxillary molars to move the molars toward the mesial. Osterix and ALP expression were analyzed using SPSS program. **Results:** The results showed that the highest number of osteoblasts, Osterix and ALP expression was found from the group soy milk and calcium intake in 14 days observation (P4) with a mean \pm SD Osterix: 15.75 ± 0.2600 , and ALP with a value of $12.60 \pm 1,220$. **Conclusion:** Soy milk combination calcium has a very good effect to balance the hormonal condition and bone remodelling for elderly patient or menopause, maintaining bone stability and density during orthodontic treatment.

Keywords: Orthodontic Tooth Movement, Ovariectomy, Osterix, ALP, Soy milk combination calcium

Correspondence: Ida Bagus Narmada, Departement of Orthodontics, Faculty of Dental Medicine, Universitas Airlangga, Jl. Prof. Dr. Moestopo No. 47, Surabaya 60132 – Indonesia, Phone: +62315030255 Email: ida-b-n@fkg.unair.ac.id

INTRODUCTION

Accelerating orthodontic tooth movement can significantly reduce the treatment duration and risks of side effects (e.g. oral hygiene problems, carious lesions, root resorption, and open gingival embrasure). The rate of Orthodontic tooth movement is mainly determined by the remodeling of tissues surrounding the root, which is under the control of molecular mechanism regulating cellular behavior in the alveolar bone and periodontal ligament.¹ A survey by Yoonji (2017) showed that periodontal problems became a major complaint in elderly patients (aged 40 and above) in line with the rate of bone remodeling and a different psychological profile from younger. Elderly patients do not only concern with the aesthetics of their teeth, but also the functional ability to keep teeth longer in the oral cavity.²

Orthodontic treatments in elderly patients are affected by hormonal changes and their

effects on the process and prognosis of the treatment. Sex hormones can affect bone remodeling. Estrogen is known as a regulator in women. Estrogen and progesterone deficiencies in the post-menopausal period result in bone loss. In Orthodontic treatment, increased bone remodeling induced by a deficiency of these hormones promotes a good progress in tooth movement.^{3,4}

Ovariectomy (Ovx) causes a decreased concentration of estrogen in blood circulation. Ovariectomy in rats is intended to be used as an animal model of estrogen deficiency whose condition resembles menopausal women. Ovariectomy is a good model to describe the postmenopausal condition. At the time of menopause or post ovariectomy, the ovaries stop producing estrogen, and it results in a decreased estrogen.⁵

The process of bone remodeling during Orthodontic treatment in elderly patients is

also influenced by the balance of resorption and bone formation, a resorption process that is greater than bone formation will result in osteoporosis of the bone.⁶ Bone density depends on the amount of calcium, phosphorus, and minerals contained in the bone.⁷ Calcium cannot be produced by the body, so it is important for human beings to consume foods that contain calcium.⁸

Soy milk is a good source of calcium and phosphorus for bone formation. Isoflavone in soybeans can increase the number of osteoblasts which accelerates the process of calcium and phosphorus mineral deposits in the bone matrix.⁹ Estrogen also influences bone metabolism, especially the calcification process, the presence of estrogenic isoflavones can affect calcification process.¹⁰ Calcium intake can also be obtained by consuming calcium supplements such as calcium carbonate, which is commonly used for calcium deficiency treatment or prevention of osteoporosis.¹¹ The combination of soy milk and calcium is expected to reduce the risk of osteoporosis considering that estrogen levels decrease during orthodontic treatment in elderly patients.^{12,13}

Orthodontic tooth movement can be measured and evaluated using an appropriate biomarker. Alveolar bone remodeling biomarkers consist of bone formation markers and bone resorption markers. Biomarkers discussed in this study are related to the process of bone formation, two of them are Alkaline Phosphatase (ALP) and Osterix (Osx).¹⁴ Alkaline Phosphatase (ALP) is a glycoprotein enzyme that involves in the formation of minerals in tissues such as bone and cementum. ALP is important for bone mineralization and cartilage calcification process.¹⁵ ALP enzymes in serum and bone are used as markers for bone metabolism. During orthodontic treatment, acid phosphatase and alkaline phosphatase in human gingival crevicular fluid correlate with the duration of orthodontic pressure.¹⁶ The GCF ALP activity during orthodontic treatment is related to the length of treatment and the type of force imposed on the periodontium tissue, both in the area of pressure and in the area of traction by

orthodontic tooth movement.¹⁷

Osterix (Osx) is an important transcription factor in the differentiation of preosteoblasts and preosteoblasts and bone development. Osterix regulates the formation and secretion of matrices such as cementum, dentin, and alveolar bone which are expressed in osteoblasts of alveolar bone tissue.¹⁸ Osterix has been extensively studied in cementoblasts and osteoblasts on the cementum surface and alveolar bone. Besides being needed in the differentiation process of osteoblasts and bone formation, osterix is also needed in the process of regulation of the expression of osteoblast genes such as OPN, osteocalcin, and bone sialoprotein.¹⁹

The purpose of this study was to determine the effect of combination of soy milk and calcium on Orthodontic tooth movement in female rats with estrogen deficiency. This research is expected to be able to explain the differences between the administration of soy milk alone and soy milk combined to the bone remodeling process. This can be seen from the expression of Osterix and Alkaline phosphatase in female rats with estrogen deficiency at 7 and 14 day observations.

MATERIALS AND METHODS

This was an experimental laboratory analytic research. The research design was Post Test Only Control Group Design. This research was conducted at the Laboratory of Embryology at the Faculty of Veterinary Medicine, Universitas Airlangga, Surabaya. The research period was March to May 2018. The Research has passed an ethical test performed by The Faculty of Dental Medicine, Universitas Airlangga (No. 237/HRECC. FODM/X/2017).

Twenty Female Wistar rats aged 16-20 weeks weighed 200-250 grams were randomly divided into 5 groups with 4 samples for each group. Control group (K), ovariectomy rats were observed on day 0, P1 group ovariectomy rats with orthodontic tooth movement, soy milk intake in 7 days observation. P2 group consisted of ovariectomy rats, orthodontic tooth movements, soy milk intake in 14 days observation. P3 group consisted of ovariectomy rats, orthodontic tooth movements and soy milk combination calcium intake in 7 days observation, P4 group

consisted of ovariectomy rats, orthodontic tooth movement and soy milk combination calcium intake in 14 days observation.

Measurement of estrogen hormone levels were done by ELISA Test before the ovariectomy and after rat termination. ELISA test utilized ELISA Kit by collecting a 1.5 cc blood samples from each rat according to the group before ovariectomy from orbitalis vein. The blood samples were collected directly from the rats' heart veins that have been terminated. All study subjects (20 samples) were anesthetized. Intermuscular anesthesia was injected in a form of solution consisting of ketamine (100 mg/kg BW) and xylazine dose (5 mg / kg BW). After that a bilateral ovariectomy procedure was performed in all sample groups. Postoperative therapy is given vet-oxy antibiotics at a dose of 60-80 mg / kgBW / day for 3 days with administration once a day. Recovery period for 18 days after ovariectomy. After 18 days of recovery, wistar rats were given soy milk intake through a syringe with a dose of 0.033 ml / BB every morning and evening in the P1 and P2 treatment groups. Soy milk through a syringe procedure with a dose of 0.033 ml / BW every morning and evening, and calcium carbonate (CaCO₃) as much as 18 mg /BW/ day were given in the treatment group P3 and P4. The authors used Melilea soy milk.

Ni-Ti closed coil spring (Ortho technology, 6 mm long) is placed between the maxillary central incisors to move the molars toward the mesial. This device was fixed using 0.07 stainless steel ligature wire mounted around the maxillary central incisor through a hole made with round bur on the distocervical side just above the gingival papilla, then the strength of Ni-Ti closed coil spring was measured using a tension gauge to produce 10 grams power. In 7 days and 14 days after combination of soy milk and calcium intake, the rats were then sacrificed to collect the tissues. Then, tissues preparations were observed with immunohistochemical staining and results of the calculations of ALP and Osterix expression were analyzed using SPSS program.

RESULTS

Histopathological examination was performed to determine the expression of Osterix and Alkaline Phosphatase in the

maxillary female rats. Data for each sample were assessed semiquantitatively according to the modified Remmele method, where the Remmele scale index (Immuno Reactive Score / IRS) was the result of multiplying the percentage of immunoreactive cells with color intensity scores in immunoreactive cells. The data for each sample was the average value of observed IRS. The Ten View Fields (LP) was different at 100x and 400x magnification. Osterix and Alkaline phosphatase expressions were obtained through immunohistochemical staining.²⁰

Immunohistochemical staining of Osterix Expression

Figure 1 shows 400x microscopic magnification image. Osterix expression in osteoblast cells is pointed by white arrows. Osterix plays a main role in bone formation and bone homeostasis process. Osterix reactivity is detected in periodontal ligament cells from the alveolar region tension area and cuboidal cells on the surface of a newly formed alveolar bone and on both sides of the cementum.

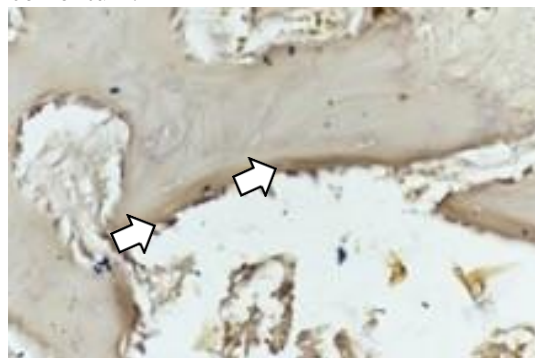


Figure 1. Description of Osterix (Osx) expression in osteoblast cell (Immunohistochemical staining 400x, Nikon Eclipse C1)

Figure 2 shows the expression of osterix in osteoblast cells in alveolar bone and cementum. Osteoblast differentiation is a multi-step process where mesenchymal cells differentiate into osteoblast lineage cells including osteocytes. Osterix (Osx) is an osteoblast-specific transcription factor which activates a repertoire of genes during the differentiation of preosteoblasts into mature osteoblasts and osteocytes. Osterix plays a well-established essential role in the genetic program of bone formation and in bone homeostasis.

Figure 3 shows osterix expression as signified by brown chromogenic immunohistochemical staining. During tooth movement, bone remodeling occurs on both sides, tension side and compression side. Figure 3 also indicates that osterix may play an important role of differentiation and osteoblasts and cementoblasts matrix formation during bone tissue remodeling in tension side.

Osterix expression was also observed in Figure 4, specifically in the periodontal and cementum ligaments of the wistar rat. Osterix expression on wistar rats was marked by brown chromogen (arrow). In bone formation process, osteoblasts will turn into osteocytes and some of the others will present on the surface of periosteal or endosteal bone with flat characteristic and several rectangular shaped osteoblasts.

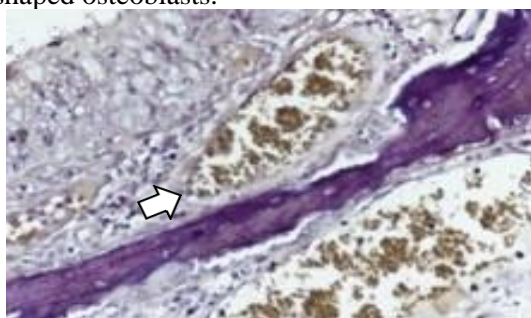


Figure 2. The arrow indicates OST expression in osteoblast cells (Immunohistochemical staining 400x400x, Nikon eclipse C1).

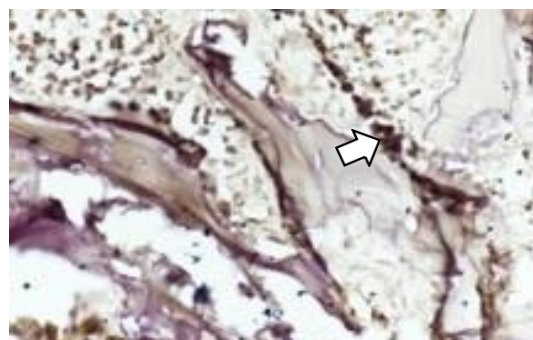


Figure 3. OST expression in osteoblast cells marked by the presence of brown chromogen (immunohistochemical staining 400x, Nikon Eclipse, C1).

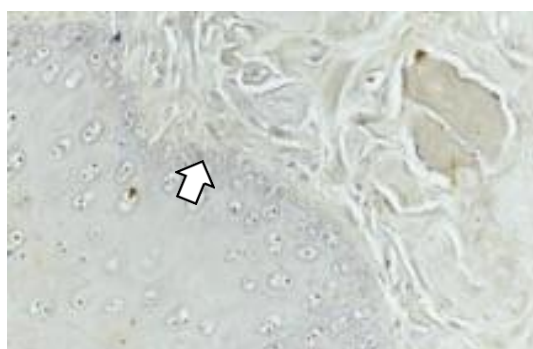


Figure 4. Osterix (OST) expression in periodontal ligament and cementum by the presence of brown chromogen (arrow)(Immunohistochemical staining 400x, Nikon Eclipse C1).

Elisa Test of Estrogen Level before and after Ovariectomy

Table 1. The mean Estrogen level before and after Ovariectomy

Group	Before Ovx (pg/ml)	After Ovx (pg/ml)	P (Sig)
K	20.96 ± 2.04	7.93 ± 3.20	0.01
P1	20.42 ± 1.09	9.24 ± 3.00	
P2	19.83 ± 2.31	11.39 ± 2.11	
P3	19.57 ± 2.20	12.53 ± 1.36	
P4	18.94 ± 2.08	12.87 ± 1.50	

Notes:

K: Control group, ovariectomy, observation on day 0

P1: Treatment group 1, ovariectomy, orthodontic tooth movement, and soy milk intake, observation on day 7

P2: Treatment group 2, ovariectomy, orthodontic tooth movement and soy milk intake, observation on day 14

P3: Treatment group 3, ovariectomy, orthodontic tooth movement, and soy milk combination calcium intake, observation on day 7

P4: Treatment group 4, ovariectomy, orthodontic tooth movement and soy milk combination calcium, observation on day 14

Table 1 showed that there were differences in estrogen levels before and after ovariectomy. After ovariectomy, there was a significant decrease in all groups, but, the lowest estrogen levels decrease was observed

on the control group (K group), the group was not treated with soy milk or calcium. There was a estrogen levels decrease in treatment groups, but it was balanced by providing soy milk and calcium after 7 and 14 days.

Osterix (OST) expression

Table 2. Calculation of Osterix Expression

Group	Mean ± SD	p (Sig.)
K	5.450 ± 0.7550	0.001
P1	6.000 ± 0.5657	
P2	8.500 ± 1.0893	
P3	14.00 ± 1.6300	
P4	15.75 ± 0.2600	

Table 2 shows that the highest osterix expression value was in treatment group 4 (P4), then lowest in the control group (K). From the homogeneity test using Levene test, the value of $p = 0.611$ ($p > 0.05$) shows that the variance of the data group was homogeneous. The results of the normality test using the Kolmogorov-Smirnov test showed that all data were normally distributed with a value of $p = 0.477$ ($p > 0.05$). Different tests using Oneway ANOVA were obtained (Table 3), the significance value of osterix was 0.001 ($p < 0.05$), which means that there were significant differences between the five groups (there were differences in osterix expression between the five groups).

Based on the results of LSD tests performed on osterix expressions according to Table 4, it can be concluded that there were differences in osterix expression between group P4 with the control group, group P1, and P2. But, there were no significant differences with the P3 group. The P3 group was different in osterix expression with the control group, P1 and P2 groups. But there were no significant differences with the P4 group. The P2 group was significantly different to all the other groups. P1 group was significantly different to the other groups except with the control group. The control and other groups were significantly different except with group P1.

Table 3. One Way ANOVA Test of Osterix Expression

	Sum of Square	df	Mean square	F	Sig.
Between Groups	21.140	2	10.57	15.27	0.001
Within Groups	6.230	9	0.692		
Total	27.370	11			

Table 4. LSD Test of Osterix Expression

Group	Group of Comparison	Sig.
K	P1	0.374
	P2	0.001*
	P3	0.010*
	P4	0.015*
P1	K	0.374
	P2	0.002*
	P3	0.012*
	P4	0.022*
P2	K	0.001*
	P1	0.002*
	P3	0.006*
	P4	0.017*
P3	K	0.010*
	P1	0.012*
	P2	0.006*
	P4	0.232*
P4	K	0.015*
	P1	0.022*
	P2	0.017*
	P3	0.232*

Immunohistochemical staining of ALP Expression

Alkaline Phosphatase (ALP) is a glycoprotein enzyme that contributes to the formation of minerals in tissues such as bone and cementum. ALP is important for bone mineralization and cartilage calcification process. The enzyme is mostly produced by gingival crevicular fluid (Neutrophils), although it is also produced by cells such as fibroblasts, osteoblasts, and osteoclasts. Figure 5 shows the osterix expression as marked by brown chromogenic immunohistochemical staining.

Alkaline Phosphatase is a glycoprotein and membrane bound enzyme. In periodontal tissues, alkaline phosphatase is an important enzyme for the remodeling cycle of periodontal ligament, cementum, and bone homeostasis. During orthodontic treatment, acid phosphatase and alkaline phosphatase in

human gingival crevicular fluid correlate with the duration of orthodontic pressure. In Figure 6, at 400x microscopic magnification, osterix expression in osteoblast cells is pointed by white arrows.

ALP is indicated by the brownish (dark brown) to golden yellow color as a result from an enzymatic reaction between peroxidase and DAB (Subtraction Peroxidase Enzyme), which follows immunological reactions between antigen and ALP monoclonal antibody antihuman antibodies. Figure 7 shows the osterix expression as marked by brown chromogenic immunohistochemical staining. Figure 8 shows the number of osteoblasts that is indicated by quantitative immunohistochemical (IHC) staining at 400x microscopic magnification. Highest activity of ALP was found in areas related to mineralization, adjacent to the alveolar bone and cementum.

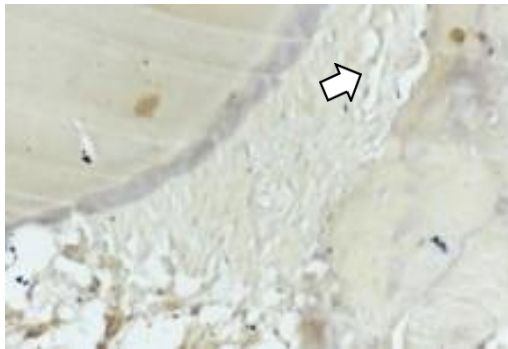


Figure 5. Description of ALP expression in ligament periodontal tissue (Immunohistochemical staining 400x, Nikon eclipse C1).

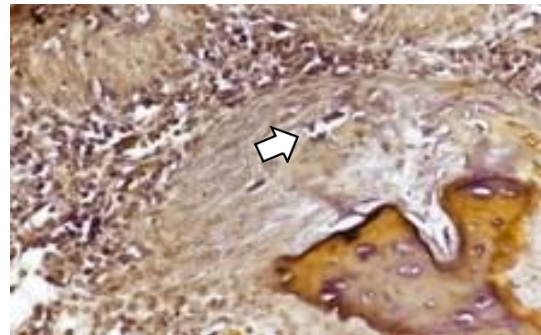


Figure 6. The arrow shows the presence of ALP expression (Immunohistochemical staining 400x, Nikon eclipse C1)

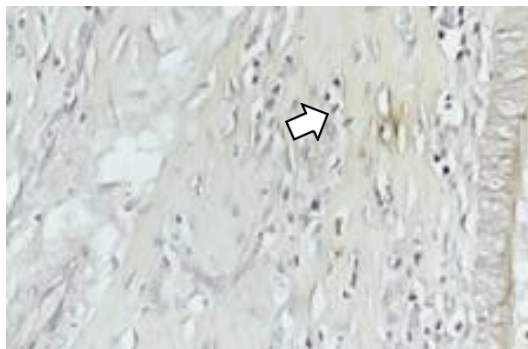


Figure 7. ALP expression in ligament periodontal tissue was marked by the presence of brown chromogen (Immunohistochemical staining 400x, Nikon Eclipse C1)

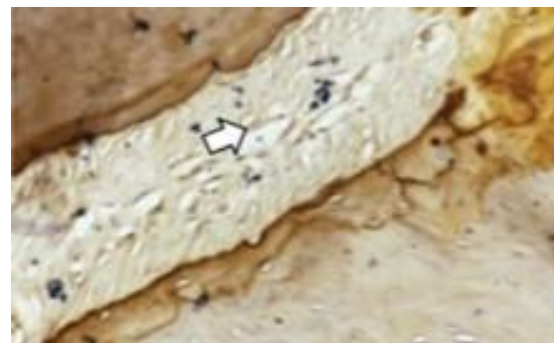


Figure 8. ALP expression in periodontal ligament tissue (Immunohistochemical staining 400x, Nikon Eclipse C1)

Alkaline Phosphatase (ALP) expression

Table 5. Calculation of Alkaline Phosphatase Expression

Group	Mean \pm SD	p (Sig.)
K	3.950 \pm 1.6683	0.017
P1	6.500 \pm 1.8938	
P2	7.900 \pm 0.9557	
P3	10.25 \pm 0.2400	
P4	12.60 \pm 1.220	

The results in table 5 shows the highest expression value of ALP in the treatment group 4 (P4) with a value (12.60 \pm 1.220) and the lowest average seen in the control group (K) with a value (3.950 \pm 1.6683). The homogeneity test using Levene test showed homogeneous data variance with a value of $p = 0.485$ ($p > 0.05$), and the results of the normality test using the Kolmogorov-Smirnov test showed all data were normally distributed

with a p value = 0.995 ($p > 0.05$). Different tests using Oneway ANOVA showed the significance value of ALP was 0.017 ($p < 0.05$). It means that there were significant differences between the three groups (there were differences in ALP expression between the three groups) (Table 6). The results in Table 6 shows that the comparison between groups that were significantly different (there are differences in ALP expression), among

others, the control group and the other groups. Then, the P1 group was significantly different from the other groups except the P2 group. The P3 and P4 groups also significantly different from the other groups. The results in Table 7 shows that the comparison between the groups that were significantly different (there were differences in ALP expression), among others, the control group and the other groups. Then the P1 group was significantly different from the other groups except the P2 group. The P3 and P4 groups also significantly different from the other groups.

The results of this study indicated that combination of soy milk and calcium intake in rats after ovariectomy procedure increased the number of osteoblast as observed from of osterix and alkaline phosphatase expression, which gradually increased per different

treatment and duration of observation. The gradual increase was observed in the control group, which had the lowest subsequent osterix and ALP expression in the K group. The P1 group after 7 days of soy milk intake also showed a slight increase in osterix and ALP expression followed by P2 after 14 days of soy milk intake also showed an increase significant than the two previous groups. In the P3 group who were given calcium combination soy milk for 7 days showed a higher number of osteoblasts and osterix and ALP expressions than the previous three groups. A significant increase was seen in treatment group 4 (P4), the group with calcium combination soy milk with observation on day 14, where the value of osterix and ALP expression was the highest compared to the othergroups.

Table 6. One Way ANOVA Test of Alkaline Phosphatase Expression

	Sum of Square	df	Mean square	F	Sig.
Between Groups	32.087	2	16.043	6.608	0.017
Within Groups	21.850	9	2.428		
Total	53.937	11			

Table 7. LSD Test of Alkaline Phosphatase Expression

Group	Group of Comparison	Sig.
K	P1	0.004*
	P2	0.006*
	P3	0.013*
	P4	0.020*
P1	K	0.004*
	P2	0.236
	P3	0.002*
	P4	0.012*
P2	K	0.006*
	P1	0.236
	P3	0.034*
	P4	0.021*
P3	K	0.013*
	P1	0.002*
	P2	0.034*
	P4	0.015*
P4	K	0.020*
	P1	0.012*
	P2	0.021*
	P3	0.015*

DISCUSSION

This research was carried out by activating the orthodontic force during estrogen deficiency conditions so that the estrogen hormone levels were expected to fall below normal conditions. Force was given by applying of 10gr / mm for 7 days using closed coil spring. There were five groups namely treatment group 1 with giving soy milk and observations on day 7 (K1), treatment group 2 with giving soy milk and observing on day 14 (K2), treatment group 3 with giving a combination of soy milk and calcium and observation on day 7 (K3), treatment group 4 with giving a combination of soy milk and calcium and observations on day 14 (K4), as well as the control group without administration of soy milk or calcium observation day 0 (K). The five groups were examined on osterix expression (OST) and Alkaline phosphatase (ALP).

The biological response to orthodontic tooth movement is associated with the application of mechanical forces to the crown of a tooth and determines the occurrence of two zones in the periodontal ligament: the compression area and the tension area. Chemical changes in the periodontal ligament blood flow stimulate the release of local molecular cells that induce cell differentiation and stimulation of osteoblast and osteoclast cells.²¹

The results of this study indicated that in estrogen (menopause) deficiency conditions, as in the group with soy milk combination calcium (K3) and (K4), the number of osteoblasts, osterix expression and alkaline phosphatase (ALP) expression was higher than the other three groups. Decrement of estrogen levels in menopausal conditions can affect tooth movement due to orthodontic forces. As estrogen levels decrease with menopausal conditions (estrogen deficiency), tooth movement will increase due to the process of osteoclastogenesis that forms osteoclast cells that resorb bone. Estrogen is a hormone that is known to inhibit osteoclast activity directly or indirectly. Estrogen directly inhibits bone remodeling by reducing osteogenesis. Estrogen can also work indirectly in osteoclasts by increasing calcitonin production. Increased calcitonin secretion by estrogen will inhibit the action of osteoclasts in bone resorption.²³

In this study, the highest number of osteoblasts was found in the treatment group 4 (P4) observation of the 14th day, and the lowest in the control group (K) observation day 0. This increase in the number of osteoblasts was caused by an increase in estrogen after administration of soy milk and calcium. Soy milk is known to contain isoflavones which are flavonoid subclass phytoestrogens found significantly in soybeans. The benefits of soy isoflavones on bones can increase bone formation by osteoblasts.

Isoflavone compounds have also been shown to have hormonal effects, especially estrogenic effects. This estrogenic effect is related to the structure of isoflavones which can be transformed into equol, where equol has a phenolic structure similar to the hormone estrogen. Considering the hormone estrogen also influences bone metabolism, especially the calcification process, the presence of estrogenic isoflavones can affect the process of calcification. Isoflavones can protect against osteoporosis in bones.²⁴

Melilea soy milk in this study was selected without any personal interests of the author and aim to minimize the bias during the experiments due to the procedure of making non-homogeneous soy milk every day, so that the doses and freshness of soy milk was maintained according to the manufacturer's instructions. In addition, the superiority of Melilea soy milk which is imported soybeans from China, and its quality of imported soybeans which is better than local soybeans, which produce soy milk without any unpleasant taste so that it is better to consume.

Calcium carbonate as one of the most common calcium preparations, which contains 40% elemental calcium also aimed at preventing and treating osteoporosis and calcium deficiency. The combination of calcium in this study was aimed to compare the formation of osteoblasts in soy milk intake alone and soy milk with combination calcium results were different or not. Calcium supplements aims to provide calcium needs for patients who do not consume enough calcium from their dietary sources.

The results of this study indicated that soy milk combination calcium in rats that have been ovariectomy (estrogen deficiency) had an effect on increasing the number of osteoblasts which can be seen from the increase in osterix

expression values and the expression of ALP with immunohistochemical staining. The results showed that the highest number of osteoblasts was in the group with calcium combination soy milk on day 14 (P4). A combination of soy milk and calcium turned out to provide better results even though it was not significantly different compared to soy milk alone (P3 group).

However, when compared to the duration of the observation, there was a significant difference between the various treatment and the length of observation for 7 days compared to the observation period of 14 day. The observation of 14 days showed an increase in the number of osteoblasts which was more than 7 days. This was due to the gradual increase of the hormone estrogen after administration of soy milk for 7 and 14 days. The addition of calcium in of soy milk intake helps the process of bone calcification and stimulates the activity of osteoblasts more than soy milk intake alone, thus providing a balance between the resorption process and bone tissue apposition during bone remodeling after the ovariectomy procedure.

In conclusion, consumption of adequate doses of soy milk combination calcium in elderly patient or menopause condition is very good for balancing hormonal conditions. Soy milk combination calcium can balance the process of bone remodeling, maintain bone stability and density during orthodontic treatment. That could be potentially good alternative of phytoestrogen to prevent osteoporosis and gain optimal tooth movement during Orthodontic treatment. If the bone remodeling process is balanced during Orthodontic treatment, so Orthodontic treatment can be shortened.

REFERENCES

- Huang H, William R, Kyrkanides S. Accelerated Orthodontics Tooth Movement: Molecular Mechanism. *American Journal of Orthodontics and Dentofacial Orthopedics*. 2014; 146 :620-32.
- Yoonji K. Study on The Perception of Orthodontic Treatment According to Age: A Questionnaire Survey. *The Korean journal of Orthodontics*. 2017; 47 (4):215-221.
- Seifi M, Ezzati B, Saedi S, Hedayati M. The effect of Ovariectomy and Orchiectomy on Orthodontic Tooth Movement and Root Resorption in Wistar Rats. *Dent Shiraz Univ Med Sci*. 2015; 16(4):302-309.
- Sihombing I, Wangko S, Kalangi S.J.R. Peran Estrogen pada Remodeling Tulang. *Jurnal Biomedik*. 2012; 4 (3):18-28.
- Mackie MA, Danaei M, Habibagahi S, Tanide S, Najvani ND, Montazeri A, Mostafa. Effect of Ovariectomy on Orthodontic Tooth Movement in Rats. *Journal of Islamic Dental Association of IRAN*. 2016; 28 (3):86-91.
- Susilo GS, Amtha R, Roeslan BO, Kusnoto J. The differences of Orthodontic Tooth Movement on Menstrual and Ovulation cycle. *Dental Journal (Majalah Kedokteran Gigi)*. 2014; 47(4): 177-180.
- Macari S, Duffles L.F, Queiroz-Junior C.M, Madeira M.F, Dias G.J, Teixeira M.M, Szawka RE, Silva TA . Estrogen regulates Bone resorption an cytokyne production in the maxillae of female mice. *Archive of Oral Biology*. 2015; 60 (2): 333-41.
- Suryono, Khomsan A, Setiawan B, Martianto D, Sukandar D. Pengaruh Pemberian Susu terhadap Kadar Kalsium Darah dan Kepadatan Tulang Remaja Pria. *Jurnal Gizi & Pangan*. 2007; 31:1.
- Shahi M, Peymani A, Sahmani M. Regulation of Bone Metabolism. *Reports of Biochemistry & Molecular Biology*. 2017; 5(2): 73-82. 9.
- C. Castelo-Branco and Cancelo Hidalgo MJ. Isoflavones: Effects on Bone Health. *CLIMACTERIC*. 2011;14:204-211.
- Jackson, *et al*. Calcium Plus Vitamin D Supplementation and The Risk of Fractures. *New England Journal of Medicine*. 2006 ; 234(7):669-83.
- Atun S. Potensi Senyawa Isoflavon dan derivatnya dari Kedelai (*Glycine Max. L*) serta manfaatnya untuk Kesehatan. Seminar Nasional Penelitian, Pendidikan dan Penerapan MIPA. 2009. Fakultas MIPA: Universitas Negeri Yogyakarta.
- Wiliani B.H, Sirajuddin. Hubungan Antara Asupan Phytoestrogen dengan Kadar Estradiol pada Wanita Lanjut Usia. *Media Gizi Pangan*. 2010; 2:8-15.
- Ariffin SHZ, Yamamoto Z, Abidin IZZ, Wahab RMA, Ariffin ZZ. Cellular and Molecular Changes in Orthodontic Tooth Movement. *The Scientific World Journal*. 2011; 11: 1788- 1803.
- Farahani M, Safavi SM, Dianat O, Tusi SK, Younessian F. Acid and Alkaline Phosphatase Levels in GCF during Orthodontic Tooth Movement. (*J Dent Shiraz Univ Med Sci*). 2015 ;16 (3): 237-245.
- Alfaqeeh SA, Anil S. Gingival Crevicular Fluid Flow Rate and Alkaline Phosphatase Level as Potential Marker of Active Tooth Movement. *Oral Health and Dental Management*. 2014; 13:(2).

17. Perinetti G, *et al.* Alkaline Phosphatase Activity in Gingival Crevicular Fluid during Human Orthodontic Tooth Movement. *American Journal of Orthodontics and Dentofacial Orthopedics.* 2002; 122 (5) : 548-556.
18. Sinha KM and Zhou X. Genetic and Molecular Control of Osterix in Skeletal Formation. (*Journal of Cellular Biochemistry*). 2013; 114(5): 975–984.
19. Kim JY, Byung I, Jue SS, Park JH, Shin JW. Localization of osteopontin and osterix in periodontal tissue during orthodontic tooth movement in rats. *Angle Orthodontist.* 2012; 82 (1) : 107-114.
20. Nowak M, Madej JA, Dziegeil P. Intensity of Cox 2 expression in Cell of Soft Tissue Fibrosarcomas in Dog As Related to Grade of Tumor malignation. *Bull Vet inst Pulawy.* 2007; 51: 275-279.
21. Proffit, WR. 2007. *Contemporary Orthodontics.* Fourth Edition. Mosby. St. Louis Missouri.
22. Trailokya A., Srivastava A., Bhole M., Zalte N. Calcium and Calcium Salts. *Journal of The Association of Physicians of India.* 2017; 65(2):100-103.
23. Derek S, Kalangi S, Wangko S. Kerja osteoklas pada perombakan tulang. *BIK Biomed.* 2007; 3: 97-107.
24. Setyorini A, Suandi IKG, Sidiartha IGL, Suryawan WB. Pencegahan Osteoporosis dengan Suplementasi Kalsium dan Vitamin D pada Penggunaan Kortikosteroid Jangka Panjang. *Sari Pediatri.* 2009; 11(1): 32-38.