

Case Report

Use of Removable Partial Denture in Child with Papillon-Lefevre Syndrome: Case Report

Tania Saskianti, Karina Ramadhani, Aulia Nuur Ainayah, Ardianti Maartrina Dewi
Department of Pediatric Dentistry,
Faculty of Dental Medicine, Universitas Airlangga
Surabaya - Indonesia

ABSTRACT

Background: Papillon-Levefre Syndrome (PLS) is a rare genetic disorder with prevalence of 1-4 cases per millions of birth, characterized by the presence of palmar-plantar hyperkeratosis and rapid periodontal destruction of both the primary and secondary dentition. **Purpose:** This clinical report described such a rare condition with special attention on its diagnostic characterization, various treatment options and Prosthodontic rehabilitation. **Case:** Five years-old boy accompanied by his mother came to Pediatric Dentistry Specialist Clinic, Universitas Airlangga Dental Hospital - Surabaya with the chief complaint of gradually loss of upper and lower teeth since the patient was 3 years old. **Case Management:** Removable partial denture was chosen because it was considered as an appliance that can recover the function of mastication, speech and aesthetic patient. Removable partial denture was designed to replace 51, 52, 53, 54, 55, 61, 62, 63, 64, 65, 72, 73, 74, 75, 82, 83, 84 and 85 with retention on 16, 26, 36 and 46, and anterior bite riser on 31 and 41. **Conclusion.** Removable partial denture is the treatment of choice for children with PLS who are still in the growth period because it can recover mastication and aesthetic functions, have a good aesthetic, and easy maintenance that could done by the child.

Keywords: Papillon-Lefevre syndrome; Palmoplantar keratoderma; prosthetic rehabilitation.

Correspondence: Tania Saskianti. Department of Pediatric Dentistry, Faculty of Dental Medicine, Universitas Airlangga, Jalan Mayjend. Prof. Dr. Moestopo No. 47, Surabaya-60132, Indonesia. E-mail: tania-s@fkg.unair.ac.id

INTRODUCTION

Papillon-Levefre Syndrome (PLS) is a rare autosomal recessive genetic disorder with a prevalence of 1-4 cases per million of births. Characterized by palmar-plantar hyperkeratosis. Oral manifestation is aggressive periodontitis leading to premature loss of deciduous and permanent teeth at the very young age.¹ The development and eruption of primary dentition is frequently associated with gingivitis and periodontitis. The classic treatment regime for such periodontal condition is seems to be unresponsive and often leads to the premature exfoliation of primary dentition. The gingival and periodontal pathologies usually disappear until the permanent teeth erupt and typically being reappeared with the eruption of permanent dentition resulting into complete or partial edentulousness. The condition reduces the quality of mastication, speech and aesthetic functions of the patient. Generally the patient consults dentist first

because of premature teeth loss and associated problems. This clinical report described such a rare condition with special attention on its diagnostic characterization, various treatment options and Prosthodontic rehabilitation.

CASE

Five years-old boy accompanied by his mother came to Pediatric Dentistry Specialist Clinic, Universitas Airlangga Dental Hospital - Surabaya with the chief complaint of gradually loss of upper and lower teeth since the patient was 3 years old (Figure 1). Patient often get ridiculed from his surrounding and unable to eat properly, hence the patient showed enthusiastic desire to received treatment. The characteristics of patient with PLS on intra oral clinical examination (Figure 2), radiological examination (Figure 3), and extra oral examination (Figure 4).

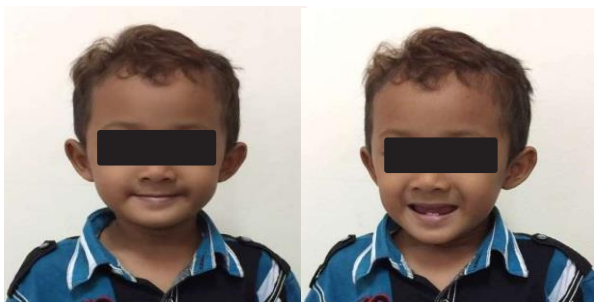

Figure 1. Pre-treatment frontal view. Low vertical dimension (denture face appearance).

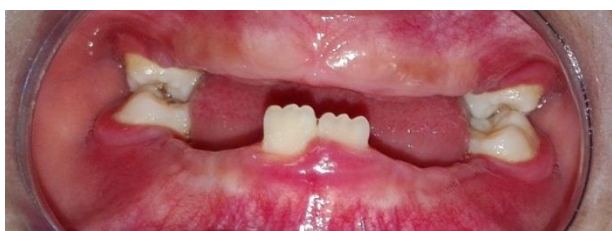

Figure 2. Intra oral photo. Premature loss of all deciduous teeth. Early eruption of 16, 26, 31, 36, 41 and 46..

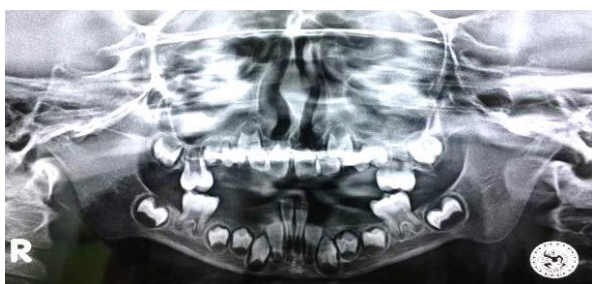

Figure 3. Panoramic radiographic. Permanent tooth buds were complete.

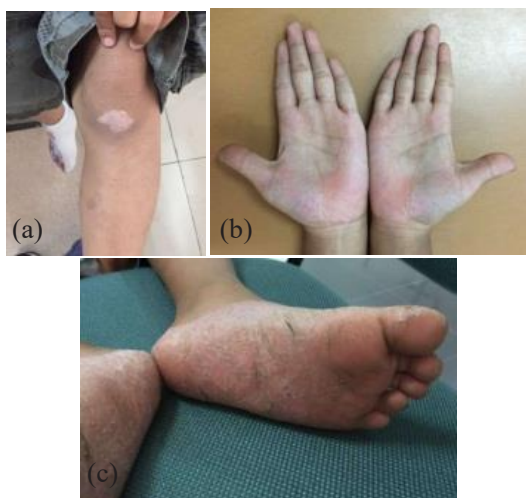

Figure 4. Hyperkeratosis on the knees (a), palms (b) and soles (c).

CASE MANAGEMENT

Removable partial denture was chosen because it was considered as an appliance that can recover the function of mastication, speech and aesthetic patient. Removable partial denture was designed to replace 51, 52, 53, 54, 55, 61, 62, 63, 64, 65, 72, 73, 74, 75, 82, 83, 84 and 85 with retention on 16, 26, 36 and 46, and anterior bite riser on 31 and 41. First control (five months after insertion) patient came with good general condition, the removable partial denture rarely used because its discomfort in speech and soreness. Due to intra oral examination, lower right lateral incisor teeth begin to erupt. Repair the partial denture to the lateral lower left incisor was being done and also rebasing in region 73, 74, 75 (outer fissure lower jaw bite), then referred the patient to pediatrician in the patient area of residence for comprehensive treatment. The patient feels more comfortable with the new appliance (Figure 8) Patient and parent are again given education of how to use and care of removable partial denture appliances as well as instructions to maintain oral hygiene.

DISCUSSION

Papillon-Lefevre syndrome (PLS) was first described by two French physicians, Papillon and Lefevre, in 1924.² PLS was caused by a chromosome disorder of 11q14.1-q

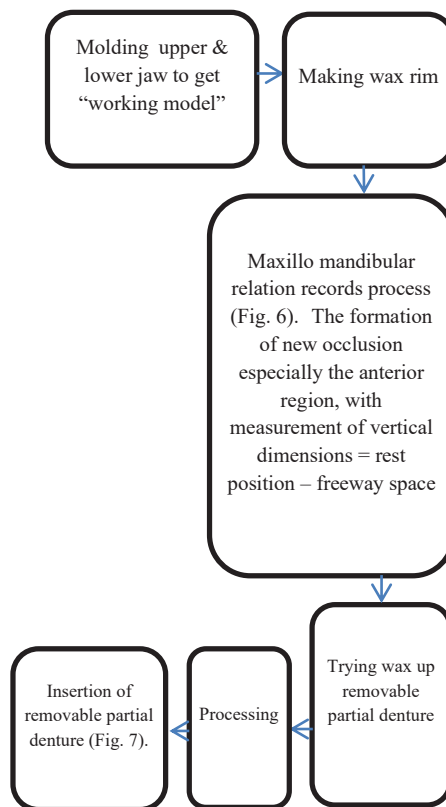


Figure 5. The working procedure of making removable partial denture.

14.3, involving a CTSC gene mutation.^{3,4} In general, the three factors play a role in the initiation and development of PLS are: genetic, immune system, and microbes. PLS is a progressive disorder. The features of dental patognomonis in patient with PLS include hypermobility, drifting, migration and tooth loss without any root resorption. In this case the patient does not have significant periodontal abnormalities (Phase 3) and it's during in a period of growth, so the management of this case was chosen to making a denture. From the radiology examination it was known that the total number of permanent tooth buds was complete, but because this disorder has repetitive characteristics, then the possible cycle of manifestation / cycle of damage will re-occur, so further control of care is needed so that the teeth are expected to survive in the oral cavity for longer. Vitamin A (etretinate, isotretinoin, and acitretin) have been found to help reduce chronic inflammation of the gingiva, thus reducing tooth loss in some patients with Papillon-Lefevre Syndrome. In this case, the referral letter has been addressed

to the pediatrician in the patient's area of residence for comprehensive treatment, but the response still not received. Genetic counseling may be beneficial for affected individuals and families. Psychosocial support is also recommended for the whole family.⁵ A multidisciplinary approach involving teams of dermatologists, pediatricians and pediatric dentists is essential for the comprehensive treatment of patient with PLS.¹ Removable partial denture is the treatment of choice for children with PLS who are still in the growth period because it can recover mastication and aesthetic functions, have a good aesthetic, and easy maintenance that could done by the child. The nature of PLS has been described with special focus on its characterization, diagnosis and management of dental complications. As the PLS debilitates patient socially, psychologically and physically, the oral rehabilitation in such patients can improve the patient's appearance, masticatory efficiency and minimize the onset of emotional and psychological problems often experienced by these patients.

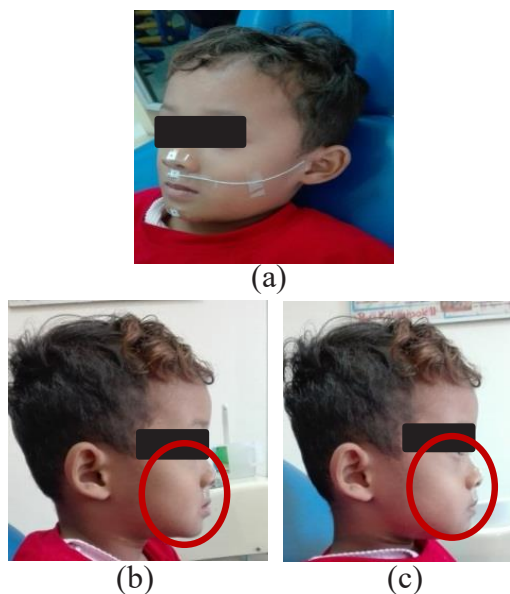


Figure 6. Photo of maxillo-mandibular relation records process. (a) Measurement of vertical dimensions. (b) Photo before attempted wax rim. (c) Photo after attempted wax rim.

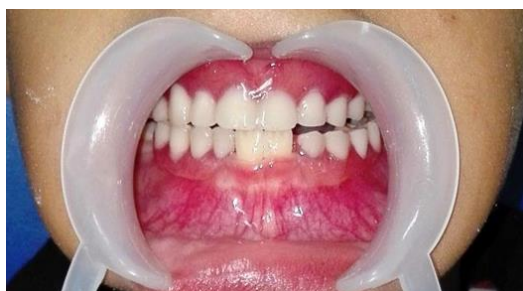

Figure 7. Photo insertion of removable partial denture appliance.

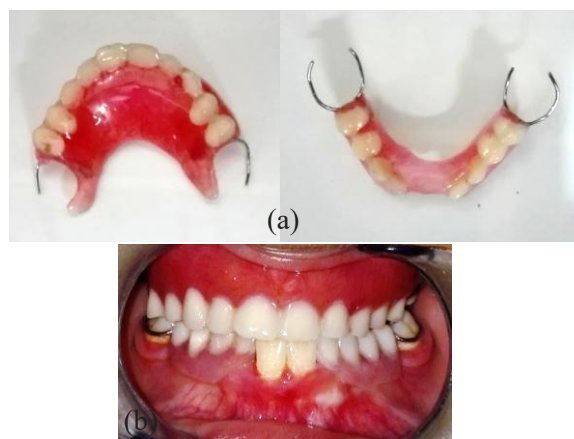


Figure 8. (a) Photo of removable partial denture appliance. (b) Photo insertion of removable partial denture after repair dan rebasing.

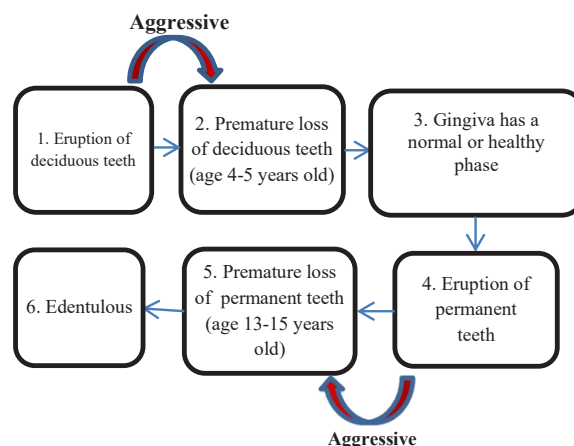


Figure 9. Cycle of clinical manifestations of PLS in the oral cavity.

Prosthodontic rehabilitation is a specialty job involving initial replacement with complete or partial denture with future consideration for implant-supported or retained definitive prosthesis. Considering the poor alveolar bone support and socioeconomic reasons, removable prosthetic replacement was executed as it would achieve patient's esthetic and functional demands immediately. Therefore, accurate diagnosis, perfect treatment planning and suitable prosthodontic rehabilitation of such unfortunate individuals can improve their oral functioning, appearance, self-confidence and minimize the onset of emotional and psychological problem.

CONCLUSION

Removable partial denture is the treatment of choice for children with PLS who are still in the growth period because it can recover mastication and aesthetic functions, have a good aesthetic, and easy maintenance that could done by the child.

REFERENCES

1. Sreeramulu B, Shyam NDVN, Ajay P, Suman P. Papillon Lefèvre syndrome: Clinical presentation and management options. Vol. 7, Clinical, Cosmetic and Investigational Dentistry. Dove Medical Press Ltd; 2015. p. 75–81.
2. B S, S H, K S, MD S, G K. The Prosthodontic Management of a Young Edentulous Patient With the Papillon Lefevre Syndrome-A Rare Case Report. J Clin DIAGNOSTIC Res. 2012;6(10).
3. Wani AA, Devkar N, Patole MS, Shouche YS. Description of Two New Cathepsin C Gene Mutations in Patients With Papillon-Lefèvre Syndrome. J Periodontol. 2006 Feb;77(2):233–7.
4. James WD (William D, Elston DM, Berger TG, Andrews GC. Andrews' Diseases of the skin : clinical dermatology. Saunders Elsevier; 2011. 910 p.
5. Papillon Lefèvre Syndrome - NORD (National Organization for Rare Disorders) [Internet]. NORD (National Organization for Rare Disorders). Available from: <https://rarediseases.org/rare-diseases/papillon-lefevre-syndrome/>