

Orthodontic Interceptive Treatment on Obstructive Sleep Apnea Cases

Ida Bagus Narmada, Ervina R Winoto, Ailsa Marvalodya Hakim

Department of Orthodontics, Faculty of Dental Medicine, Universitas Airlangga, Surabaya, Indonesia

ABSTRACT

Background: Obstructive sleep apnea (OSA) is a breathing disorder that occurs during sleep and results in decreased or complete cessation of airflow despite attempts to breathe. Specific populations, such as children with certain craniofacial or other genetic syndromes and who are obese have a higher prevalence of OSA than the general population. Craniofacial abnormalities are one of the causes of OSA in the upper airway. Craniofacial morphologies that may predispose to OSA include retrognathia, anterior open bite, midface deficiency, and lower hyoid position. Therefore, interceptive orthodontic treatment in children is needed as one of the treatment options that can be chosen. **Purpose:** this study aimed to describe the interceptive orthodontic treatments and their effects on OSA cases in children. **Review:** Interceptive orthodontic treatment has various types depending on how the dentocraniofacial abnormality occurs. Orthodontic treatment aims to reduce the severity of OSA through maxillary and mandibular expansion, thereby increasing air space and airflow. **Conclusion:** Interceptive orthodontic treatment in pediatric OSA cases include; Rapid Maxillary Expansion, Twin-block, Propulsor Universal Light appliance, Planas appliance modified, Fränkel-II appliance, and BioAJustax oral appliance.

Keywords: obstructive sleep apnea; orthodontic treatment; craniofacial abnormalities; medicine; dentistry

Correspondence: Ida bagus Narmada, Department of Orthodontics, Faculty of Dental Medicine, Universitas Airlangga. Jl. Mayjen Prof. Dr. Moestopo 47 Surabaya, 60132 Indonesia. Email: ida-b-n@fkg.unair.ac.id

INTRODUCTION

Obstructive sleep apnea (OSA) is a sleep disordered breathing and results in decreased or complete cessation of airflow despite attempts to breathe. The majority of people with OSA often pause and snore loudly when airflow is reduced or blocked. The patient will then make choking, grunting, or gasping sounds during sleep, then caused the soft tissue behind the throat to collapse and block the upper airway.¹ The incidence of OSA in the pediatric population in the United States is approximately 2%. Most of the children are about 2-8 years old, due to the relative size of the adenoid tonsil. OSA is more common in men than women.² Specific groups, such as children with certain craniofacial, genetic syndromes, and obese have a higher prevalence of OSA.³ In Indonesia, incidence of snoring in children aged 5-13 years was 31.6% in children aged 5-13 years in the form of habitual snoring by 5.2% and occasional snoring by 26.4%.⁴

Craniofacial abnormalities are one of the causes of OSA in the upper airway. Changes of the position, size, and geometry of the mandible and tongue can cause the retropalatal region thickened and make it the most common site of obstruction in pediatric airways.² Craniofacial morphologies that can predispose to OSA are retrognathism, midface deficiency, anterior open bite, and lower hyoid position.³

Based on the various factors that cause OSA, current care management focuses on a multidisciplinary approach, one of which is orthodontics. Orthodontic treatment aims to reduce the severity of OSA through maxillary and mandibular expansion, thereby increasing air space and increasing airflow. Polysomnographic clinical evidence after orthodontic treatment shows that orthodontic therapy improves airway patency.⁵ Orthodontic treatment consists of two types, namely preventive and interceptive. In cases of obstructive sleep apnea (OSA) due to dentocraniofacial abnormalities in children with alternating teeth, interceptive orthodontic treatment is required. Interceptive orthodontic treatment itself has various types depending on how the dentocraniofacial abnormality occurs.⁶

This study aimed to describe the interceptive orthodontic treatments and their effects on OSA cases in children. Thus, in this narrative review, will discuss about the interceptive orthodontic treatments and their effects on OSA cases in children.

METHOD

This article is a narrative review, scientific published literatures and extracted data from several databases which are PubMed, AJODO, and The Angle Orthodontist were

extracted. The inclusion criteria in this study were research, case reports, and randomized controlled trials literature. The literature must contain cases of obstructive sleep apnea in children aged 6-12 years or during mixed dentition and undergoing interceptive orthodontic treatment. Literature should be in English. Meanwhile, the exclusion criteria in this study were literature with the type of review and in languages other than English. There is no limitation of when the article was published. The keywords used in this study were “pediatric sleep apnea”, “pediatric sleep disordered breathing” and “interceptive orthodontic”, “malocclusion correction”, “myofunctional therapy”, “mandibular advancement device”, “functional appliance”. After searching from databases and other literature sources using the keywords, a total of 660 literatures were obtained. Only 12 literatures included in this review after the author read the full paper based on inclusion and exclusion criteria (Figure 1).

RESULT

Various data have been collected from 12 included literatures, such as authors, year of publication, sample size, sex, and age. Study characteristic are presented in Table 1.

Orthodontic appliances assessed were: RME (Rapid Maxillary Expansion), Twin-block, Propulsor Universal

Light appliance, Planas appliance modified, Fränkel-II appliance, and BioAJustax oral appliance. After using orthodontic appliances above, evaluation were obtained by several methods: PSG (polysomnography), home sleep studies, cephalometric analysis, and pharyngometry.

The main outcomes evaluated were: apnea hypoapnea index (AHI), ODI (oxygen desaturation index), nadir oxygen saturation, snoring time, average oxygen saturation, length of vertical airways, nasal airway, airway volume, and MCA (upper airway minimal cross-sectional area) after with or without non-orthodontic treatments. These outcomes, treatments, and evaluation methods are presented in Table 2.

RME, Twin-block, Propulsor Universal Light appliance, Planas appliance modified, Fränkel-II appliance, and BioAJustax oral appliance accompanied with or without non-orthodontic treatments could reduce AHI.⁵⁻¹⁴ RME, Twin-block, and Fränkel-II appliance increase oxygen saturation and even reduce the incidence of desaturation during sleep.^{5,6,8,10-12} Twin-block orthodontic treatment reduces snoring time.¹² RME orthodontic treatment reduces the length of the vertical airways.⁵ RME orthodontic treatment improved the nasal airway.⁹ BioAJustax appliance increased airway volume (V) and MCA on pharyngometry examination.¹⁵ Twin-block does not show a positive correlation with AHI, snoring intensity, and oxygen desaturation.¹⁶

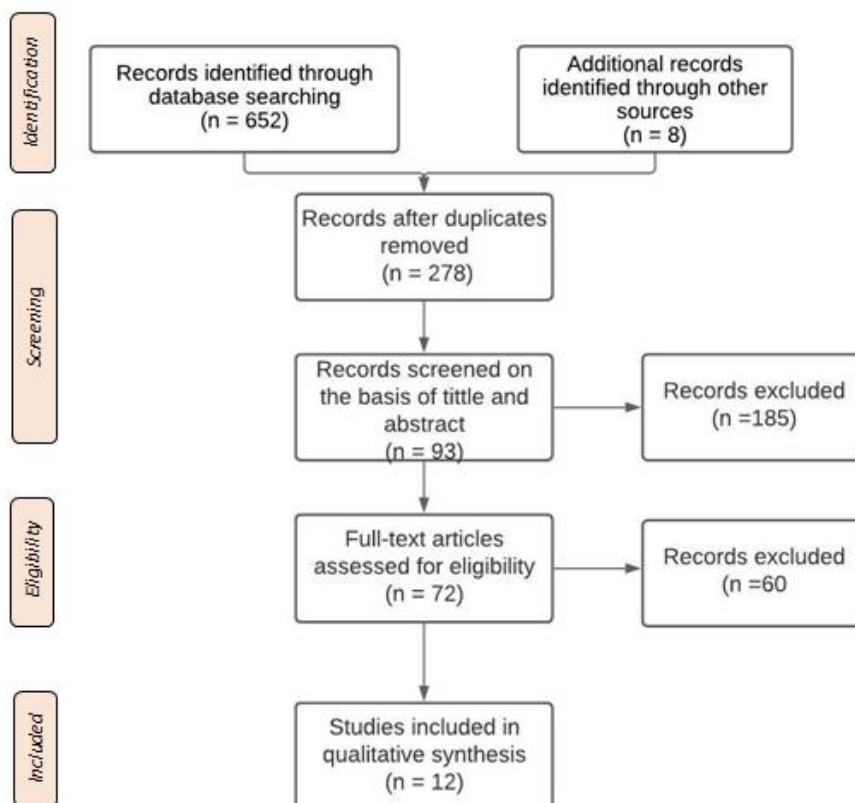


Figure 1. PRISMA Flowchart Diagram.

Table 1. Sample characteristic in the study.

Author, year of publication	Sample size	Sex	Age
(Pirelli et al., 2004) ⁶	31	Male (n = 19) Female (n = 12)	6 - 12 years
(Rose & Schessl, 2006) ⁷	2	Male (n = 1) Female (n = 1)	6 years 6 months 8 years
(Kim, 2014) ⁸	1	Male (n = 1)	11 years
(Taddei et al., 2015) ⁵	60 (30 patients, 30 controls)	Male (n = 24) Female (n = 36)	8 - 10 years
(Jackson, 2016) ⁹	1	Male (n = 1)	11 years 11 months
(Machado-Júnior et al., 2016) ¹⁰	14 (8 patients, 6 controls)	Male (n = 5) Female (n = 9)	Controls: Mean = 8.13 years Patients: Mean = 8.39 years
(Danut Radescu et al., 2017) ¹¹	1	Female (n = 1)	8 years
(Gracco et al., 2018) ¹²	1	Female (n = 1)	8 years
(Idris et al., 2018) ¹³	16	Male (n = 13) Male (n = 3)	8 - 12 years
(Alexander et al., 2019) ¹⁴	2	Female (n = 2)	9 years
(Bignotti et al., 2019) ¹⁵	1	Male (n = 1)	12 years
(Nunes et al., 2019) ¹⁶	40 (24 patients, 16 controls)	-	6 - 9 years

Table 2. Treatments, Evaluation, and Outcomes

Author, year of publication	Treatment(s)	Evaluation methods	Outcomes
(Pirelli et al., 2004) ⁶	RME	PSG and posteroanterior cephalograms	AHI less than 1 event per hour in all cases. RME impacted the nasal cavity, with a mean increase in nasal piriform opening of 1.3 ± 0.3 mm.
(Rose & Schessl, 2006) ⁷	Case 1 RME followed by Fränkel-II appliance	PSG	Case 1: Rhythmic and normal breathing pattern at night is more than 90%, minimum oxygen saturation is 88%, SaO2 and average oxygen saturation is 96% SaO2.
	Case 2 Fränkel-II appliance		Case 2: Improved cardiorespiratory parameters with less apnea and oxygen desaturation.
(Kim, 2014) ⁸	RME	PSG	AHI is 3.9 and minimum oxygen saturation during sleep (SaO2 @nadir) is 93%.
(Taddei et al., 2015) ⁵	RME Hyrax screw and Propulsor Universal Light appliance	Home sleep studies, cephalometric analysis	Decrease in the AHI value in both groups. The frequency of subjects with an ODI greater than 5 was reduced by about 25% after RME and further decreased to 5% after PUL appliance compared to the control group. The mean value of vertical upper airway length decreased after RME.
(Jackson, 2016) ⁹	Haas palatal expander on fixed edgewise appliances followed by Arnold mandibular expander and mandibular advancement surgery	PSG	Final AHI is 4.6. Mean of oxyhemoglobin saturation was 97% through wakefulness, 98% through REM, and 96% through non-REM.
(Machado-Júnior et al., 2016) ¹⁰	Planas Appliance Modified	PSG	Decrease in AHI one year after using the device compared to the group without device. AHI 1 (before) 1.66, AHI 2 (after) 0.30.
(Danut Radescu et al., 2017) ¹¹	RME followed by Twin-block	PSG	Increase in AHI from 2.6 to 10.2 episodes/hour. Increase in snoring time from 4.2 to 51.3 events/hour and ODI had a significant variable change from 3.2 to 10.8 events/hour.
(Gracco et al., 2018) ¹²	RME, epiglottoplasty, and reduction of the tongue base at the same time	PSG	AHI decreased from 21.8 episodes/hour at baseline to 0.6 episodes/hour. Mean oxygen saturation from 96.5% to 98.1%. Incidence of oxygen desaturation from 23.4 episodes/hour to 1 episode/hour.
(Idris et al., 2018) ¹³	Twin-Block dan and Sham Mandibular Advancement Splint (MAS)	PSG and sleep study scoring	Twin-Block decrease 37% in AHI compared to Sham MAS. Twin-Block snoring time was 46.3 minutes shorter than Sham device. Increase in oxygen saturation from the use of Twin-block when compared to Sham MAS.
(Alexander et al., 2019) ¹⁴	RME with CPAP, adenotonsilectomy, and myofunctional rehabilitation program with total care for 12 months	Home sleep study	AHI in patient A is 1.1 and in patient B is 1.0
(Bignotti et al., 2019) ¹⁵	Tonsillectomy followed by twin-block	PSG	AHI is 0.7/hour with total apnea equal to 0 and total hypoapnea 2. The mean oxygen saturation was 96%, nadir was 50 and ODI was 3.2.
(Nunes et al., 2019) ¹⁶	BioAJustax oral appliance	Pharyngometry dan cephalometric	Airway volume (V) and MCA increases significantly in the treatment group, while a significant decrease in MCA and V occurred in the controls

DISCUSSION

There are a wide variety of therapeutic options available for children with OSA. While the mainstay of therapy for this disease includes CPAP and adenoid tonsil surgery. There are also a variety of other treatments, surgical and non-surgical, depends on the patient's age and underlying clinical condition. OSA must be treated as early as possible because research conducted by Ingo et al stated that as subjects get older, the severity of OSA increased, indicated by increase in AHI.¹⁷ Craniofacial abnormalities are one of the causes of OSA in the upper airway. Changes in the size, position, and geometry of the mandible and tongue can cause thickening of the retropalatal region which is the most common site of obstruction in pediatric patients. 92% of OSA patients benefit from oral appliance treatment that improves the AHI index and OSA symptoms.¹⁸

Rapid Maxillary Expansion (RME) is an oral appliance to treat children with narrowed maxillary arches. An instrument is placed in the oral cavity and worn during night. The appliance connects to the posterior teeth and applies lateral pressure on the maxilla to reopen the midpalatal suture so the lateral diameter of the hard palate increased.¹⁹ Haas expander and Hyrax expander are the most known in the literature. Haas type acrylic plate is located on the lateral palate wall to improve orthopedic response and better distribution of forces. Hyrax expander has no acrylic plate, makes it more hygienic and prevents soft tissue irritation due to food accumulation.²⁰

RME has been found to be able to reduce AHI in children with OSA. In addition, a study conducted by Taddei et al., 2015 revealed that RME can reduce the length of the vertical airways. Patients with OSA have longer airways. Upper airway geometry affects the character of airflow, resistance, and obstruction. Previous studies have revealed that longer airways have significantly less negative closing pressures, and are therefore more prone to collapse.⁵ So it can be interpreted that RME is the right treatment for OSA cases. Research conducted by Pirelli et al., 2004 also revealed that RME can improve the nasal airway by opening nasal piriformis.⁶

Functional appliance has been widely trusted as one of the orthodontic treatment options in cases of children with OSA.²¹ Functional appliance works by placing the mandible forward, stretching the muscles and the soft tissues, creating a force that is transmitted to the teeth. In addition, the soft tissues surrounding the teeth also change. This leads to tooth movement, formation of new occlusal relationships and reduction of overjet.²² Mandibular Advancement Device (MAD) is used for the treatment of snoring, mild to moderate OSA, and for patients with severe OSA who cannot tolerate CPAP. MAD works by advancing the mandible thereby increasing the pharyngeal airway, pulling the tongue forward and increasing the tone of the palatal muscles, and reducing airway obstruction.

Twin-block appliance is one of the functional appliances used in cases of class II malocclusion. The upper and lower sections are aligned using a posterior bite block with an

interlocking bite plane, which positions the mandible forward. The reactivation of this tool is relatively easy.²³ Research conducted by Idris et al., 2018 and Bignotti et al., 2019 indicates that this device is an option for OSA therapy in children by reducing AHI.^{13,15} Research conducted by Danut Rădescu et al., 2017 showed a negative correlation with the use of twin blocks.¹¹ After using twin block for 12 months, the AHI increased from 2.6 to 10.2 events/hour of sleep. The previous apnea-hyperpnea incidence rate was 34 events/hour of sleep and increased to 81 events/hour at bedtime. Snoring time increased from 4.2 to 51.3 events/hour. ODI increased from 3.2 to 10.8 events/hour. This can occur due to the posterior rotation of the mandible.

The Fränkel appliance is the only fully tissue-born functional appliance. Fränkel appliance has several versions designed to treat different types of malocclusion. Like other functional appliances, this tool works by positioning the mandible forward. This tool is quite difficult to use, expensive, and difficult to repair. As a result, it is currently used less frequently.²³ The Fränkel appliance has labial and buccal pads to keep the lips and cheeks away from the teeth. This makes the dental arches especially maxilla to develop when soft tissue strength is removed.²²

Research conducted by Rose et al., 2006 used the Fränkel-II appliance as a treatment for children with OSA. The Fränkel-II appliance advances the mandible anteriorly, thereby expanding the pharyngeal space and displacing the surrounding soft tissue anteriorly. The Fränkel-II appliance prevents pharyngeal collapse. One of the advantages of this device's construction is the anchorage located on the oral vestibule, thus, this tool does not limit the oral cavity and the tongue can occupy the available space.⁷

The Modified Planas Appliance used in the research conducted by Machado Junior et al., 2016 was in the form of acrylic plates on the upper and lower jaws with Cofin springs and bite planes on the occlusal and anti-labial parts on the vestibule. This tool is used to advance the mandible by correcting the position of the tongue and lips. This tool is proven to be able to reduce AHI one year after using the device in patients with OSA. The advantage of Planas Appliance is the treatment efficacy does not require perfect compliance.²⁴

Research conducted by Nunes Jr et al., 2019 using of the BioAJustax appliance in patients with OSA succeeded in increasing airway volume (V) and MCA of treatment group.¹⁶ MCA or upper airway minimal cross-sectional area can be a benchmark to see the risk of OSA in children. The higher the MCA value, the lower the severity of OSA.²⁵ The oropharyngeal volume, oropharyngeal airway MCA, and AP and lateral airway length in the cross-sectional area of OSA patients were significantly lower than in normal individuals. This results in obstruction and changes in the shape of the pharynx in OSA patients, making them more prone to collapse.²⁶ Therefore, the use of the BioAJustax appliance can be an option for interceptive orthodontics in OSA patients. The BioAJustax appliance consists of an acrylic plate with a palatal opening, a screw for active maxillary expansion, and a Hawley vestibular arch. Lip bumper

installed to enhance lip contact. Bite guides are placed behind the upper incisors to position the lower incisors more anteriorly. The limitation of this narrative review is the limited number of orthodontic appliances used, so it is not possible to know the effect of all available interceptive orthodontic appliances when used as a treatment option for pediatric OSA. Therefore, further research is needed.

CONCLUSION

RME, Twin-block, Propulsor Universal Light appliance, Planas Modified appliance, Fränkel-II appliance, and BioAJustax appliance could be used as orthodontic interceptive treatment in OSA cases. Beside decreased in Polysomnography parameters (AHI, nadir oxygen saturation, snoring time, average oxygen saturation, and ODI), they could affect in reducing the length of the vertical airways, opening nasal piriformis, and increasing airway volume (V) and MCA on pharyngometry. Therefore, further research about the effect of functional orthodontics appliance in pediatric with OSA is still needed.

ACKNOWLEDGEMENT

The author would like to thank Orthodontics Department, Faculty of Dental Medicine, Universitas Airlangga for kind help and support.

REFERENCES

1. Arnold J, Sunilkumar M, Krishna V, Yoganand S, Kumar M, Shanmugapriyan D. Obstructive Sleep Apnea. *J Pharm Bioallied Sci.* 2017;9(Suppl 1):S26.
2. Gulotta G, Iannella G, Vicini C, Polimeni A, Greco A, de Vincentiis M, et al. Risk Factors for Obstructive Sleep Apnea Syndrome in Children: State of the Art. *Int J Environ Res Public Heal* 2019;16(18):3235.
3. Behrents RG, Shelgikar AV, Conley RS, Flores-Mir C, Hans M, Levine M, McNamara JA, Palomo JM, Pliska B, Stockstill JW, Wise J, Murphy S, Nagel NJ, Hittner J. Obstructive sleep apnea and orthodontics: An American Association of Orthodontists White Paper. *Am J Orthod Dentofacial Orthop.* 2019 Jul;156(1):13-28.e1.
4. Supriyatno B, Said M, Hermani B, Sjarir DR, Sastroasmoro S. Risk factors of obstructive sleep apnea syndrome in obese early adolescents: a prediction model using scoring system. *Acta Med Indones.* 2010 Jul;42(3):152-7.
5. Taddei M, Alkhamis N, Tagariello T, D'Alessandro G, Mariucci EM, Piana G. Effects of rapid maxillary expansion and mandibular advancement on upper airways in Marfan's syndrome children: a home sleep study and cephalometric evaluation. *Sleep Breath.* 2015;19(4):1213-20.
6. Pirelli P, Saponara M, Guilleminault C. Rapid maxillary expansion in children with obstructive sleep apnea syndrome. *Sleep.* 2004;27(4):761-6.
7. Rose E, Schessl J. Kieferorthopädische Maßnahmen bei der Behandlung obstruktiver Schlafatmungsstörungen bei Kindern. *J Orofac Orthop.* 2006;67(1):58-67.
8. Kim M. Orthodontic Treatment with Rapid Maxillary Expansion for Treating a Boy with Severe Obstructive Sleep Apnea. *Sleep Med Res.* 2014 J;5(1):33-6.
9. Jackson GW. Orthodontic and Orthognathic Surgical Treatment of a Pediatric OSA Patient. *Case Rep Dent.* 2016;2016:1-7.
10. Machado-Júnior AJ, Signorelli LG, Zancanella E, Crespo AN. Randomized controlled study of a mandibular advancement appliance for the treatment of obstructive sleep apnea in children: A pilot study. *Med Oral Patol Oral Cir Bucal.* 2016;21(4):e403.
11. Danut Radescu O, Albu S, Baciut M, Bran S, Codruta Coman A, Sever Bechir E, et al. Results in the Treatment with Twin Block Polymeric Appliance of the Retrognathic Mandible in Sleep Apnea Patients [Internet]. [cited 2021 Jun 15]. Available from: <http://www.revmaterialeplastice.ro>
12. Gracco A, Bruno G, De Stefani A, Marchese Ragona R, Mazzoleni S, Stellini E. Combined Orthodontic and Surgical Treatment in a 8-Years-Old Patient Affected By Severe Obstructive Sleep Apnea: A Case-Report. *J Clin Pediatr Dent.* 2018;42(1):79-84.
13. Idris G, Galland B, Robertson CJ, Gray A, Farella M. Mandibular advancement appliances for sleep-disordered breathing in children: A randomized crossover clinical trial. *J Dent.* 2018;71:9-17.
14. Alexander N, Boota A, Hooks K, White JR. Rapid Maxillary Expansion and Adenotonsillectomy in 9-Year-Old Twins With Pediatric Obstructive Sleep Apnea Syndrome: An Interdisciplinary Effort. *J Am Osteopath Assoc.* 2019;119(2):126-34.
15. Bignotti D, De Stefani AD, Mezzofranco L, Bruno G, Gracco A. Multidisciplinary approach in a 12-year-old patient affected by severe obstructive sleep apnea: A case-report. *Sleep Med Res.* 2019;10(2):103-7.
16. Nunes WR, Gozal D, Di Francesco RC. Cephalometric and Pharyngometric Evaluation in Snoring Children with Sleep-Disordered Breathing and Adenotonsillar Hypertrophy under an Orthodontic or Orthopedic Treatment. *J Child Sci.* 2019;9(1):E68-74.
17. Fietze I, Laharnar N, Obst A, Ewert R, Felix SB, Garcia C, et al. Prevalence and association analysis of obstructive sleep apnea with gender and age differences – Results of SHIP-Trend. *J Sleep Res.* 2019;28(5):e12770.
18. Ilea A, Timuş D, Höpken J, Andrei V, Băbţan AM, Petrescu NB, et al. Oral appliance therapy in obstructive sleep apnea and snoring - systematic review and new directions of development. *Cranio.* 2021;39(6):472-83.
19. Cielo CM, Gungor A. Treatment Options for Pediatric Obstructive Sleep Apnea. *Curr Probl Pediatr Adolesc Health Care.* 2016;46(1):27-33.

20. Weissheimer A, De Menezes LME, Mezomo M, Dias DM, De Lima EMS, Rizzato SMD. Immediate effects of rapid maxillary expansion with Haas-type and hyrax-type expanders: a randomized clinical trial. *Am J Orthod Dentofacial Orthop.* 2011;140(3):366–76.
21. Lin H, Xiong H, Ji C, Wang C, Li Y, An Y, et al. Upper airway lengthening caused by weight increase in obstructive sleep apnea patients. *Respir Res.* 2020;21(1):1–10.
22. Dibiase AT, Cobourne MT, Lee RT. The use of functional appliances in contemporary orthodontic practice. *Br Dent J* 2015 2183. 2015;218(3):123–8.
23. Mitchell L. *An Introduction to Orthodontics*, In: *European Journal of Orthodontics*. Pub: Oxford University Press, Oxford. 2013. 4th ed. https://www.researchgate.net/publication/275133808_An_introduction_to_orthodontics
24. Charavet C, Le Gall M, Albert A, Bruwier A, Leroy S. Patient compliance and orthodontic treatment efficacy of Planas functional appliances with TheraMon microsensors. *Angle Orthod.* 2019 J;89(1): 117–22.
25. Chousangsuntorn K, Bhongmakapat T, Apirakkittikul N, Sungkarat W, Supakul N, Laothamatas J. Upper Airway Areas, Volumes, and Linear Measurements Determined on Computed Tomography During Different Phases of Respiration Predict the Presence of Severe Obstructive Sleep Apnea. 2018; Available from: <https://doi.org/10.1016/j.joms.2017.11.041>
26. Tikku T, Khanna R, Sachan K, Agarwal A, Srivastava K, Lal A. Dimensional and volumetric analysis of the oropharyngeal region in obstructive sleep apnea patients: A cone beam computed tomography study. *Dent Res J (Isfahan).* 2016;13(5):396.