

Indonesian Journal of Tropical and Infectious Disease

Vol. 5. No. 3 September–December 2014

Research Report

UPDATE MANAGEMENT CONCURRENT INFECTION BETWEEN DENGUE VIRAL AND SALMONELLA

Dyah Wikanesthi¹, Desiana W Sari¹, Eva Chilvia¹, Oedojo Soedirham¹, Lely Kurniasari¹, Soegeng Soegijanto^{1,2}

¹ Soerya Hospital, Sidoarjo

² Indonesian-Japan Collaborative Research Center for Emerging and re-Emerging Infectious Disease, Institute of Tropical Disease, Universitas Airlangga, Surabaya, Indonesia

ABSTRACT

Since Januari 2013, Soerya Hospital has found many cases with positive result of IgM Salmonella along with NS1 or IgM & IgG Dengue. The clinical manifestations mostly are high fever, headache, vomiting, malaise and plasma leakage. Some of them with convulsion and unconsciousness. Therefore in order to get well of care management, this clinical phenomena should be studied carefully. The aim of this research is to get update management concurrent Dengue Viral and Salmonella infection. Observational study had been done, since Januari 2013 until Juli 2013. Purposive sampling in 30 case of concurrent Dengue Viral and Salmonella infection compared with 30 case of Dengue Viral infection alone. Diagnosis has published based on WHO 2011 criteria. By using anti vomiting drug, anti pyretic, anti convulsion and antibiotic for Salmonella infection and rehidration using Ringer Acetate, combining Ringer Asetat and Dextrose 5% or combining Ringer Asetat Saline 0,225% or solution of Dextrose 5% and Saline 0,45 during 4–5 days hospitalization. The result show that all cases were recovered and got well. There is no significant different between concurrent Dengue Viral and Salmonella infection compared with Dengue Viral infection alone. Some cases showed that length time to stay in hospital become 1–2 days longer. It was due to delayed getting antibiotic for Salmonella infection. All cases had got first drugs accurately in a clinical manifestation that has been daily showed. It was as a problem solving for saving all the cases.

Key words: concurrent infection, dengue viral infection, Salmonella infection, care, NS1

ABSTRAK

Sejak Januari 2013, Rumah Sakit Soerya menemukan banyak kasus pasien positif IgM Salmonella dengan NS1 atau IgM & IgG Dengue. Manifestasi klinis yang tampak ialah demam tinggi, pusing, mual, tidak enak badan, dan pecahnya plasma. Beberapa di antara mereka ada yang mengalami gangguan hebat dan ada yang tidak. Oleh karena itu untuk mendapatkan perawatan yang baik maka fenomena ini perlu dipelajari dengan teliti. Tujuan dari penelitian ini ialah untuk mendapatkan pembaharuan manajemen virus dengue dan infeksi Salmonella. Observasi telah dilakukan sejak Januari 2013 hingga Juli 2013. Sampel purposive pada 30 kasus virus Dengue dan infeksi Salmonella yang dibandingkan dengan 30 kasus infeksi virus dengue saja. Diagnosa telah dipublikasikan oleh criteria WHO tahun 2011. Menggunakan obat anti mual, anti penurunan suhu tubuh, anti konvulsi (tidak enak badan), dan antibiotic untuk infeksi salmonella dan rehidrasi menggunakan Ringer Asetat Saline 0,225% atau larutan Dextrose 5% dan Saline 0,45 selama 4–5 hari di rumah sakit. Hasil penelitian menunjukkan bahwa semua kasus akan dipulihkan dan sembuh. Tidak ada perbedaan yang signifikan antara virus dengue dan infeksi salmonella yang dibandingkan dengan infeksi virus dengue saja. Beberapa kasus menunjukkan bahwa waktu untuk di rumah sakit menjadi 1–2 hari lebih lama. Hal itu akan tertunda jika mengkonsumsi antibiotic untuk infeksi salmonella. Semua kasus telah mendapatkan obat pertama pada manifestasi klinik yang mana ditunjukkan sehari-hari. Hal tersebut merupakan solusi untuk semua kasus.

Kata kunci: infeksi konkuren, infeksi viral dengue, infeksi Salmonella, perawatan, NS1

INTRODUCTION

On 2013 there are many cases dengue viral concurrent with Salmonella infection. Some of them showed a duration of clinical manifestation more longer than usual (see Fig. 2 and 3).

Why this event occur, it might be due to late coming as the second infection occur. Before discussing this event, we want to discussed a natural cause of Dengue Viral Infection and Salmonella infection.

Dengue Viral Infection are usually shown a clinical manifestation of fever as saddle back phenomena and followed by vomiting attack and headache.^{1,2,3,4}

Salmonella infection as usually shown the duration of infection need more time until four weeks, if the patient don't get early antibiotic for bacterial of Salmonella, patient showed clinical manifestation of gastritis, abdominal pain and concurrent with vomiting.

In the past one decade, coincident cases rare to be concern by pediatrics, but in 2013 at Soerya Hospital has found more than 100 cases in 1 year. We thought why these case could happen and getting many more, these are the global changes season and population changes. In early rainy season, we found that DVI cases was increased in order to summer season. When the rainy season prolonged, it could cause many problem in environment such as worsening hygiene individu and environment, it could cause increased salmonella infection cases. That's why many cases coincident DVI and Salmonella infection.

MATERIALS AND METHODS

Observational study had been done, since Januari 2013 until Juli 2013. Purposive sampling in 30 case of concurent Dengue Viral and Salmonella infection compared with 30 case of Dengue Viral infection alone. Diagnosis has published based on WHO 2011 criteria.

THE RESULT

Clinical manifestation of DVI patients including:^{1,2,3,4,5}

- Fever: acute onset, high and continuous, lasting 2–7 days in most cases
- Any of the following haemorrhagic manifestations including a positive tourniquet test (the most common), petechiae, purpura (at venepuncture sites), ecchymosis, epistaxis, gum bleeding and haematemesis and or melena
- Enlargement of the liver (hepatomegaly) is observed at some stage of the illness in 90–98%
- Shock, manifested by tachycardia, poor tissue perfusion with weak pulse and narrowed pulse pressure (20 mmHg or less) or hypotension with the presence of cold, clammy skin and or restlessness.

Clinical manifestation of Concurrent DVI with Salmonella infection patients including:

- Fever
- Nausea
- Vomitting
- Diarrhea and abdominal pain
- Epistaksis

These are clinical manifestations from 30 patients that we were observed in Soerya Hospital and 30 patients concurrent DVI with Salmonella infection.

Table 1. Clinical Manifestation DVI patients and Concurrent DVI with Salmonella infection.

SYMPTOMS	DVI patients	DVI + Salmonella infection
Fever	100%	100%
Nausea	62%	83%
Vomitting	40%	63%
Diarrhea	6%	20%
Abdominal pain	36%	73%
Epistaksis	2%	-

By using anti vomiting drug, anti pyretic, anti convulsion and antibiotic for Salmonella infection and rehydration using Ringer Acetate, combining Ringer Asetat and Dextrose 5% or combining Ringer Asetat Saline 0,225% or solution of Dextrose 5% and Saline 0,45 during 4-5 days hospitalization. The result show that all cases were recovered and got well. There is no significant different between concurent Dengue Viral and Salmonella infection compared with Dengue Viral infection alone. Some cases showed that length time to stay in hospital become 1–2 days longer. It was due to delayed getting antibiotic for Salmonella infection.

DISCUSSION

Concurrent infection of Dengue Viral Infection (DVI) and Salmonella in children. It is 2 kind of diseases that infect a child in a same time. How to know that these cases were caused by 2 agents (viral and bacteria), is we did anamnese, examined these patients and we used laboratory test (NS1 and IgM Salmonella) to support our diagnosa.

It is very difficult for us to know whether DVI or salmonella infection that first infect to these children. We might try to study by identifying the agents that correlate with symptoms.

We had analysed that concurrent DVI and Salmonella infections patients may stay longer in the hospital, than patient with single infection, especially if they came late to the hospital.

There are the figure of length of stay patients with Dengue Viral Infection (DVI) compared with concurrent DVI and Salmonella infection.

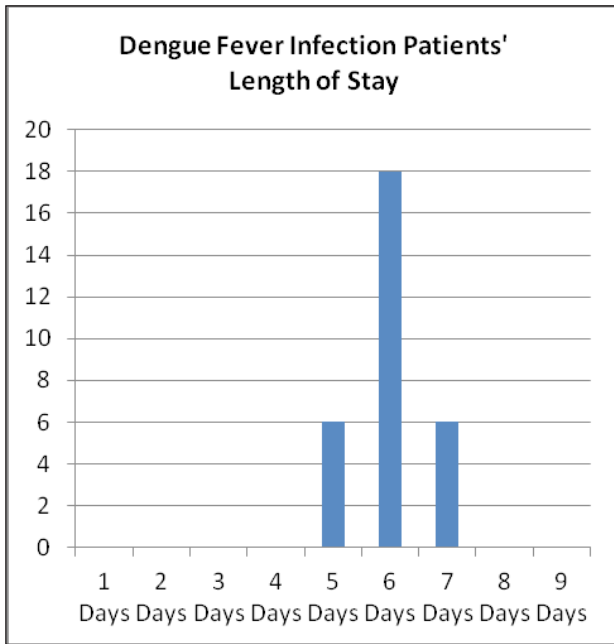


Figure 1. Length of Stay DVI Patients.

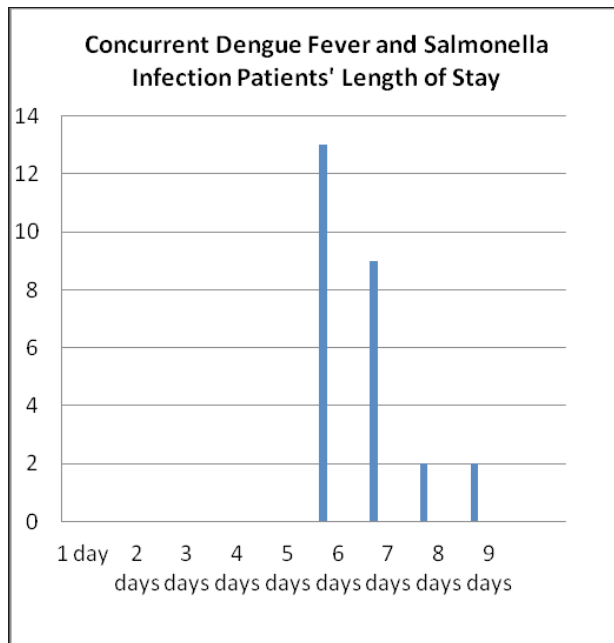


Figure 2. Length of Stay Concurrent DVI and Salmonella Infection Patients.

From the figure 1 and 2 we know that patients with NS1 positive, stayed 5–6 days in the hospital. But the patients with concurrent DVI and Salmonella infection might stay longer (7–9 days) in the hospital. But in average they stayed for about 6 days in the hospital because we could diagnose the disease early and give therapy to them.

PROBLEM SOLVING

We try to study which one disease come first by doing observational study about clinical manifestation and symptom that occur,^{5,6,7} these are:

1. High fever (high fever curve)

From the curve, we know that there was a different fever pattern of DVI patient and Concurrent Infection patients. DVI patients had a high fever in early day they admitted in the hospital, and then slowly go down in couple days.⁷ Concurrent DVI and Salmonella infection had an irregular fever pattern.

2. Vomitting
3. Nausea
4. Abdominal pain
5. Diarrhea
6. Epistaksis

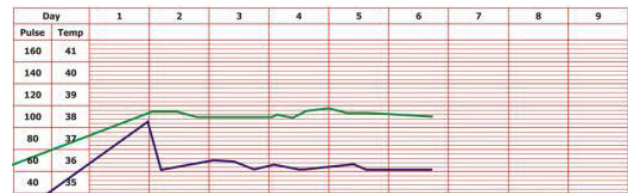


Figure 3. Body's temperature of DVI patients (purple line) and heart rate (green line).

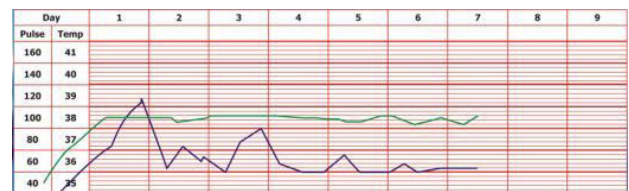


Figure 4. Body's temperature of concurrent DVI and Salmonella infection patients (purple line) and heart rate (green line).

TREATMENT

We use some drugs to these patients, such as:

1. Crystalloid fluid
We had use Ringer Acetate as a resuscitation fluid, because of its metabolism in muscle, not in liver so that it will not aggravate liver function.⁸
2. Metoclopramide or Ondansetron
To solved the clinical manifestation of vomiting due to gastritis that can be given by oral or intravenous.

Based on the problem that had been occur in concurrent infection dengue virus and salmonella. The patient should be care in the hospital by giving infusion base on the age and body weight of cases, such as:

1. Anti pyretic drop, per drop dossage 4-8 hours for high fever.

2. Anti convulsing drop such as dilantin, dosage is 5 mg/kgBB/24 hours giving per drip.
3. Some cases who showed frequently vomiting try to give anti vomiting by drip per infusion such as ondancetron.

Beside this event, many cases showed plasma leaked with could be identified by increasing hematocrit and decreasing trombocyte. The patient look pale of the face, foot and hands feel cold, high rate pulse of hand.^{5,6} For this case should be using cristaloid solution. Such ringer acetat, physiology sollution in 1–2 hours. If the condition of case still worse, give colloid solution. If the patient show bleeding such epistaxis, haematemesis or melena, please give blood transfusion from their own blood family transfusion.^{5,6,7,8}

Please awarness using ringer lactat could cause liver damage, so please choose ringer acetate, because ringer lactat metabolism in liver can make trouble of liver physiology and induce DIC. But if we use ringer acetat that metabolism in muscle.

CONCLUSION

All cases had got first drugs accurately in a clinical manifestation that has been daily showed. It was as a problem solving for saving all the cases.

REFERENCES

1. Academy of Medicine Malaysia Ministry of Health. Clinical Practice guidelines; dengue infection in adults. Dengue consensus 2003.
2. Gubler D. Dengue and dengue hemorrhagic fever. *Clin Microbiol Rev* 1998; 11; 480–96.
3. Wang S, He R, Patarapotikul, J et al., 1995. Antibody-Enhanced Binding of Dengue Virus to Human Platelets. *J. Virology*. October 213: page: 1254–1257.
4. World Health Organization. Dengue Guideline for Diagnosis, Treatment, Prevention, and Control. Geneva. 2009.
5. PT Otsuka. Guidance of Infus Solution. Revision edition VIII. 2003.
6. Shu. P, Huang J Current advances in dengue diagnosis. *Clin Diag Immunol* 2004; 11: 642–50.
7. Srichaikul T, Nimmannitya S. Haematology in Dengue and Dengue Haemorrhagic Fever. *Baillieres Best Pract Res Clin Haematol* 2000; 13(2): 261–76.
8. Kurane I, Enis FA. Immunopathogenesis of dengue virus infection. In: D.J. Gubler DJ. Kun G (ed). *Dengue and dengue haemorrhagic fever*. Wallingfird UK: Cab International, 2002: 273–90.