

Indonesian Journal of Tropical and Infectious Disease

Vol. 9 No. 2 May–August 2021

Review Article

The 'black fungus' Co-Infection in COVID-19 Patients : A Review

Jessica Novia¹, Friska Wilda², Alius Cahyadi^{3*}, Marcella Adisuhanto³

¹ Marianum Halilulik Hospital, Belu, East Nusa Tenggara

² Panti Wilasa Citarum Hospital, Semarang

³ Department of Internal Medicine, School of Medicine and Health Sciences, Atma Jaya Catholic University of Indonesia, Jakarta

Received: 11st June 2021; Revised: 24th June 2021; Accepted: 20th July 2021

ABSTRACT

Mucormycosis is one type of fungal disease, associated with a poor prognosis if not promptly diagnosed and managed because its highly aggressive tendency. Although it is a rare disease, a rapid increase in cases of mucormycosis associated with COVID-19 is being reported. Mostly, risk factors for this disease are uncontrolled diabetes mellitus, other immunosuppressive conditions and corticosteroid therapy. Immune dysfunction, lung pathology and corticosteroid therapy in COVID-19 patients making it more susceptible to develop fungal infection including mucormycosis. The combination of steroid therapy and underlying diabetes mellitus in COVID-19 also can augment immunosuppression and hyperglycemia. Control of hyperglycemia, early treatment with liposomal amphotericin B, and surgery are three important factors in mucormycosis therapy that essential for successful management. However, in this COVID-19 pandemic situation, that management strategies are compromised. First, hyperglycemia can be aggravated by glucocorticoid, therapy that used widely for COVID-19 especially in severe case. Second, patients with ARDS and multiorgan dysfunction can prevent timely diagnostic for imaging and other testing, so appropriate therapy that should be given will be delayed. Last, the essential service in hospital such surgery in this pandemic era reduced significantly to prevent the spread of COVID-19. This review was created with the aim mucormycosis co-infection can be considered in patients with COVID-19, especially with known risk factor. Prompt and rapid diagnosis are important for effective therapy and decreasing case fatality rate. The use of steroid in mild cases, utilization of higher doses of steroid and drugs that targeting immune pathway should be avoided.

Keywords: Mucormycosis; Black Fungus; Coronavirus; COVID-19

ABSTRAK

Mucormycosis merupakan salah satu penyakit infeksi jamur dengan tingkat penularan yang tinggi. Jika tidak segera didiagnosis dan diterapi, maka berhubungan dengan prognosis yang buruk. Walaupun penyakit ini jarang ditemukan, tetapi data penelitian terbaru melaporkan peningkatan signifikan kejadian mucormycosis pada pasien COVID-19. Umumnya, penyakit diabetes melitus yang tidak terkontrol, kondisi immunosupresif lain dan terapi kortikosteroid merupakan faktor risiko terjadinya mucormycosis. Disfungsi sistem imun, kelainan patologi paru dan terapi kortikosteroid pada pasien COVID-19 membuat pasien lebih berisiko untuk mengalami infeksi sekunder termasuk mucormycosis. Kombinasi terapi steroid dan adanya komorbid diabetes melitus pada COVID-19 juga lebih meningkatkan kondisi immunosupresi dan hiperglikemia. Kontrol hiperglikemia, pengobatan awal dengan liposomal amfoterisin B, dan pembedahan adalah tiga aspek penting dalam terapi mucormycosis yang merupakan faktor penentu keberhasilan penatalaksanaannya. Walaupun demikian, dalam situasi pandemi COVID-19 ini, strategi penatalaksanaan tersebut sulit tercapai. Pertama, kondisi hiperglikemia dapat diperburuk dengan glukokortikoid, yang merupakan terapi yang digunakan secara luas untuk COVID-19 terutama pada kasus berat. Kedua, pasien dengan ARDS dan disfungsi multiorgan dapat membuat uji diagnosis seperti pencitraan dan tes lainnya menjadi terlambat dilakukan sehingga diagnosis dan terapi pasien akan tertunda. Terakhir, di era pandemi

* Corresponding Author:
alius.cahyadi@atmajaya.ac.id

ini pelayanan di rumah sakit yang memerlukan tindakan, termasuk operasi berkurang secara signifikan untuk mencegah penyebaran COVID-19 lebih luas. Tujuan penulisan artikel ini adalah agar koinfeksi mucormycosis dapat dipertimbangkan pada pasien dengan COVID-19, terutama dengan faktor risiko yang berkaitan. Diagnosis yang cepat dan tepat penting untuk terapi yang efektif dan dapat menurunkan angka kematian. Penggunaan steroid pada kasus ringan, penggunaan steroid dosis tinggi dan obat-obatan yang menargetkan jalur imunologi harus dihindari.

Kata kunci: Mucormycosis; Jamur Hitam; Coronavirus; COVID-19

How to Cite: Jessica N., Friska W., Alius C., Marcella A. The 'black fungus' Co-Infection in COVID-19 Patients : A Review. Indonesian Journal of Tropical and Infectious Disease, 9(2), 126–136.

INTRODUCTION

Bacterial and fungal secondary infections are particularly vulnerable to occur in patients with severe acute respiratory syndrome coronavirus-2 (SARS-CoV-2).¹ While several treatment options have been evaluated, none except systemic glucocorticoids have been shown to improve survival in coronavirus disease of 2019 (COVID-19). Steroids therapy like a double-edged sword that is recommended and frequently given for the treatment of COVID-19 but making patients more vulnerable to secondary bacterial and invasive fungal infections.^{2,3} Mucormycosis, the "Black Fungus", is increasing among COVID-19 patients, as uncontrolled diabetes mellitus (DM) and the use of steroids during COVID-19 treatment are risk factors for mucormycosis.^{4,5} Mucormycosis is a rare disease, but the unique pandemic conditions make it easier for fungi to infect COVID-19 patients which can lead to high morbidity and mortality. Mucormycosis mortality rate is around 54%, but rates varies for each individual depends on underlying conditions, body site affected, and type of fungus.⁶ The diagnosis of mucormycosis could be done by histopathological or culture examinations; which takes a long time about 10 days after symptoms/signs presentation while the disease tends to spread rapidly throughout the body.⁷ Globally, COVID-19 associated mucormycosis highest cases that estimated more than 4000 people infected has been reported in India.⁸ Recently, due to increasing number of COVID-19 cases, we have seen a rapid increase in cases of mucormycosis that attacks a person's sinuses, lungs, and brain.

In this review, we would like to summarize recent data concerning mucormycosis co-infection in COVID-19 patients, epidemiology, pathogenesis and treatments. Mucormycosis disease progression is rapid and have angioinvasive nature, so a prompt diagnosis and treatment should be started as soon as possible to reduce the mortality.

MUCORMYCOSIS

Mucormycosis, formerly known as zygomycosis is a fungal disease caused by a group of molds called mucormycetes. These diseases are most often caused by a fungus that is found in soil and decaying vegetation, usually inhaled by humans from the air. There are various ways a person can contract mucormycosis such as by spores inhalation, food containing spores consumption, and spores-contaminated wound.^{9–11} This infection is mostly attacking immunocompromised individuals or taking medicines that weakened their immune system. The most common fungal species that result in mucormycosis are the *Rhizopus* species and *Mucor* species.⁶

DISCUSSION

Epidemiology

Globally, mucormycosis prevalence around 10,000 cases in the world except India and after merging with India to become 910,000 cases globally. Mucormycosis found in tropical and subtropical climates, such as Indonesia. Indonesia is a tropical country, warm and

humid, with numerous environmental fungi. Unfortunately, the prevalence in some developing countries, including Indonesia, are still unclear because the cases remain undiagnosed due to difficulty in collecting tissue samples and limited facilities of mycology laboratories.¹² The etiologic agents mostly are *Rhizopus* spp., *Mucor* spp., and *Lichtheimia* (formerly *Absidia* and *Mycocladius*) spp. Genera of other mucorales such as *Rhizomucor*, *Saksenaia*, *Cunninghamella*, and *Apophysomyces* are less common.¹³

Clinical Manifestation of Mucormycosis

Mucormycosis have six major clinical form based on clinical manifestation and anatomic position of the invasion including rhinocerebral, pulmonary, cutaneous, gastrointestinal, disseminated and unusual form such as endocarditis, osteomyelitis, peritonitis and renal infection.¹⁴ The initial symptoms of mucormycosis are non-specific.

The most common form is rhinocerebral mucormycosis. Presentation usually begins with pain and numbness in the eyes and face, followed by conjunctival suffusion and blurred vision. Fever does not occur in almost 50% of cases. Mostly, leukocytosis may occur. If it is not properly dealt, it could spread to the ethmoid sinus into the orbit caused damage to the function of extraocular muscle and proptosis with chemosis. In initial phase of the infected area appears normal and the concomitant progression of the disease becomes erythema with or without edema, then appears purplish and lastly formed eschar blackish necrotic tissue (Figure 1). Infection may also extend to the mouth and cause the formation of a necrotic ulcer on the palate. This finding indicates that the disease has spread.¹⁵

Pulmonary mucormycosis patients usually present with high-grade fever ($>38^{\circ}\text{C}$) and non-productive cough. Less common symptoms such as pleuritic chest pain and dyspnea. In rare circumstances, can present in endobronchial tree and causing airway obstruction. Cutaneous mucormycosis can classified as localized if affect skin and subcutaneous tissue, or deep extension if invades deeper to muscle, tendon or bone.

Typical presentation is necrotic eschar with erythema and induration in surrounding skin. Gastrointestinal mucormycosis is less common type and hard to diagnose in living patients. Most affected organ is stomach followed by colon and ileum. The presentation usually nonspecific such as neutropenic fever and hematochezia. If severe, this disease can invade blood vessels in bowel and resulting in perforation, peritonitis, hemorrhage and sepsis. Disseminated mucormycosis occur when spreading hematogenously to other organs. Commonly, site of spread is brain, but also can found in liver, spleen, heart and other organ. The presentation may vary according to location and degree of tissue invasion in that affected organ.¹⁴

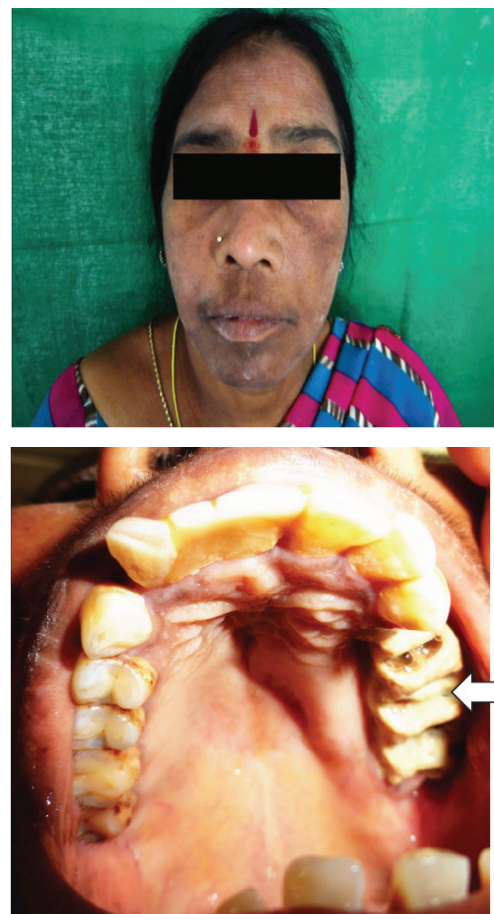

Fig. 1. Clinical presentations of rhinocerebral mucormycosis. (a) Extraoral examination reveals swelling in the left side of the face just below the eye; (b) Intraoral examination reveals necrotic bone with pus discharge in relation to left maxilla (white arrow).¹⁶

obtain permission from the original publisher

Diagnosis

The diagnostic pathway was designed by the European Confederation of Medical Mycology and the Mycoses Study Group Education and Research Consortium (ECMM/MSGERC) consensus. The ability in diagnosing mucormycosis basically depends on the well-trained staffs, techniques and imaging types, and mycological and histological investigations. A prompt referral to the highest care level was recommended for patients with suspected mucormycosis.¹³

Diagnostic for mucormycosis such as radiologic features is nonspecific and have wide range of types. The most common features that can be identified for pulmonary mucormycosis are presence of nodules, consolidations, reverse halo sign, large perilesional halo (Figure 2) and cavitation. Reverse halo sign characterized by peripheral consolidation with central ground glass and large perilesional halo characterized by ground-glass halo around lesion that very extensive and bigger than the lesion itself.^{17,18}

In rhinocerebral mucormycosis, sinus involvement usually occurs and must be identified in radiologic findings. The most common

paranasal sinus involved are maxillary, ethmoid and sphenoid. Mucosal thickening and bone erosion in imaging also the common features. Signal characteristics and contrast enhancement can be seen in CT scan, Most common form is mild enhancement. Less common, non-enhancing and heterogenous pattern can also be found. If the imaging present with non-enhancing opacification of sinuses, presence of retro antral, facial and orbital fat stranding and hypodense soft tissue extension indicated aggressive infection. (Figure 3). Lastly, imaging must identify extra sinus extension such as orbit and face.¹⁹

Histopathological examination for mucormycosis is important but not always reliable to differentiate with *Aspergillus*. Mucorales have primitive coenocytic hyphae which are fragile because of lack of regular hyphae-septations. They make aggressive tissue grinding can render fragile fungal elements become non-viable. The important differentiation between Mucorales and *Aspergillus* is on their hypha type. Mucorales hypha have wide diameter and non-septate while *Aspergillus* hypha is narrower and have many septation.^{20,21}

Imaging

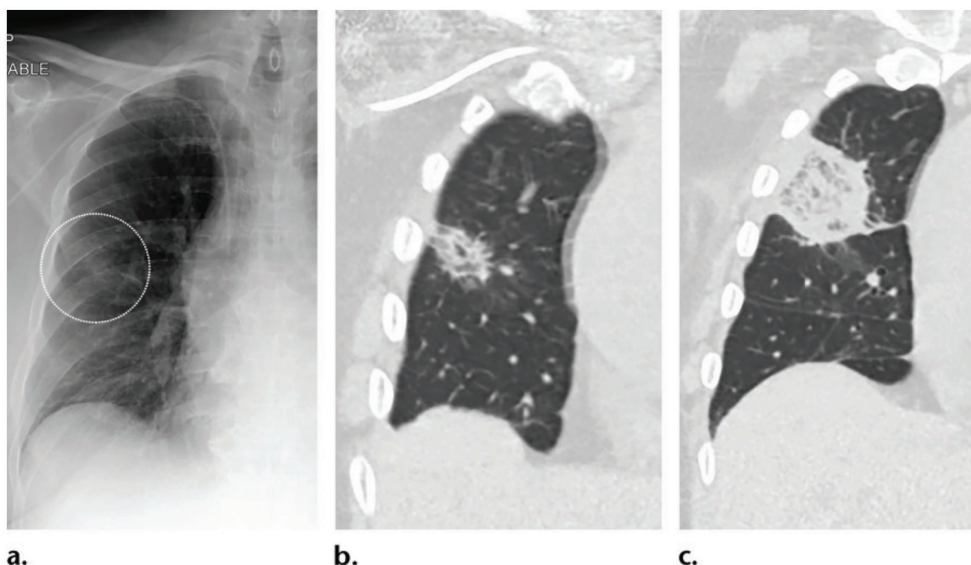


Fig. 2 (a) Frontal radiograph of the right lung shows a faint area of ground-glass opacity (dotted circle); (b) Coronal CT image obtained an area of nodular ground-glass opacity; (c) Coronal CT image shows enlargement of the lesion with development of the reverse halo sign.²²

obtain permission from the author

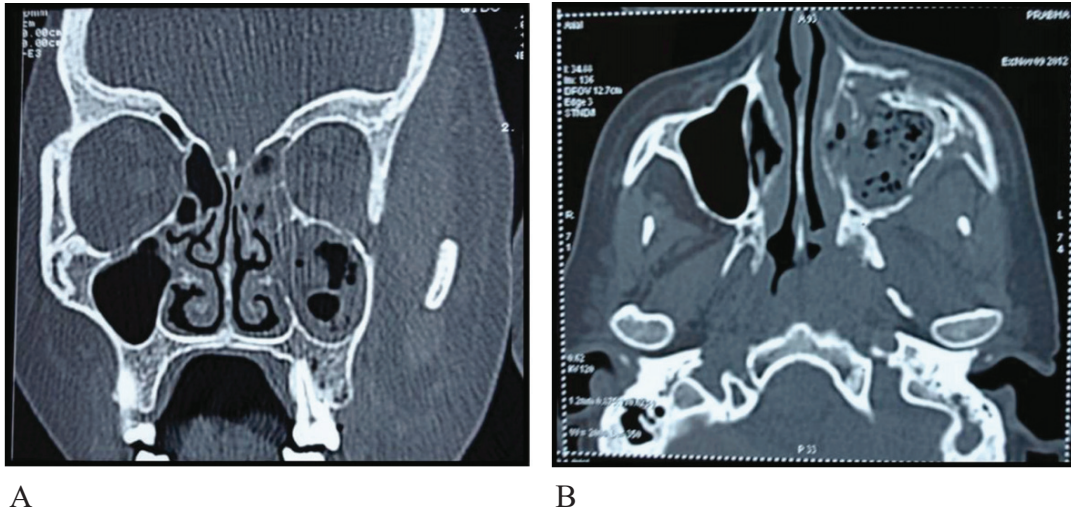


Fig. 3 (a) Coronal view of CT showing involvement of left maxillary sinus, nasal conchae, and ethmoidal sinus extending up to frontal sinus; (b) Axial view of CT showing destruction of posterior, medial, and anterior walls of left maxillary sinus.¹⁶
obtain permission from the original publisher

Histopathology in Mucormycosis

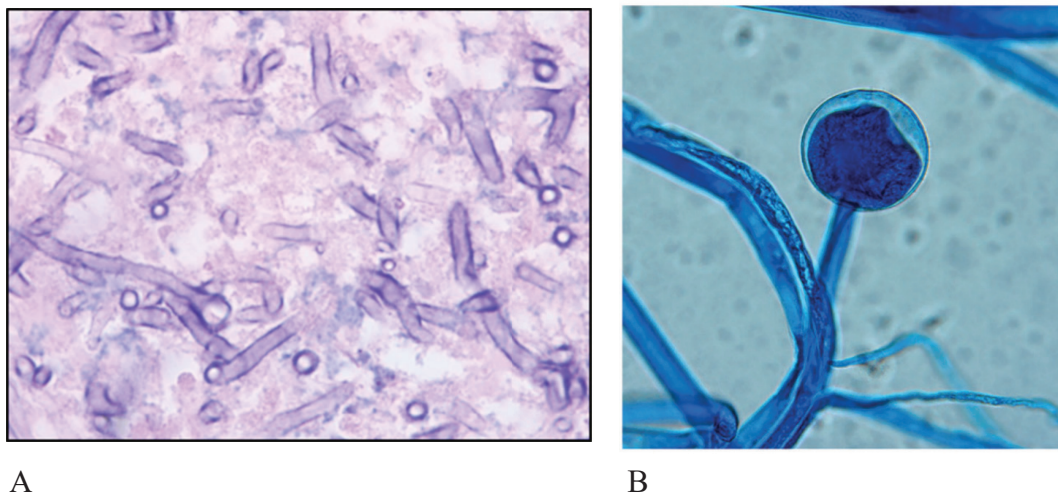


Fig. 4. Structure of *Mucor*. (a) Mucorales are irregular hyphae with wide width (6 to 25-micron diameter) are non-septate or sparsely septate, ribbon-like; (b) High-power photomicrograph shows a spherical structure called the sporangium. (Lactophenol cotton blue stain).^{22,23}
obtain permission from the original publisher

Culture and Microscopy

Culture is highly recommended for identification of fungal genus and species.⁷ It should be noted that culture does not always work for several reasons, including improper sampling and incorrect sample treatment before the examination. In fact, only 15-25% of cases are positive.²⁴

Treatment

A multimodal approach is needed in the management of mucormycosis, such as discontinuation of risk factors, early administration of antifungal therapy with optimal doses, and surgical intervention. Treatment should be started immediately if the diagnosis is suspected because the disease tends to spread rapidly throughout the

body, although the exact diagnosis has not been confirmed.¹³

Prophylaxis

Posaconazole delayed-release tablets are recommended for neutropenic patients or those with graft versus host disease.⁷

First-line antifungal monotherapy

Daily doses of liposomal amphotericin B ranged 5-10 mg/kg for any patients and ≤ 5 mg/kg if renal toxicity develops. In Central Nervous System (CNS) involvement, use of amphotericin B lipid complex 5 mg/kg per day. Treatment duration given usually weeks to months, depending on each patients condition . If the immune defect is resolved, such as well-controlled diabetes and resolved neutropenia, immunosuppressant can be tapered or stopped, therapy can be continued until resolution of signs and symptoms of infection, and substantial radiographical improvement.⁷ At the fourth week, the overall response rate was 36%, while in the twelfth week, the overall response was 45%.¹³

First-line antifungal combination monotherapy

There are no definitive data to guide the use of antifungal combination therapy.⁷

Antifungal salvage treatment

Daily Isavuconazole 200mg (after six doses of 200 mg q8h) and Posaconazole delayed-release tablets at a dose of 200 mg q6h or infusions are strongly supported as salvage treatment.^{7,13}

Surgery

Aggressive surgery is often required not only on necrotic tissue but also on surrounding tissue that appears healthy because the Mucorales grow so rapidly.⁷

THE LINK BETWEEN MUCORMYCOSIS CO-INFECTION COVID-19

As previously stated that mucormycosis is mainly attacking immunocompromised patients,

although possibly found in immunocompetent individuals.^{25,26} Generally, mucormycosis does not pose a serious threat to healthy individuals because immune system mainly polymorphonuclear cells can destroy the spores and hyphae.²⁶⁻²⁸ When patients are exposed to SARS-CoV-2, the virus will target the immune system. The relationship between COVID-19 and mucormycosis is the state of weakened of patients' immune responses, with reduced numbers of T lymphocytes, CD4+, and CD8+ T cells and medical treatment with a steroid to reduce inflammation.²⁹

One of the major risk factors that increasing morbidities and mortalities in COVID-19 associated with mucormycosis, is diabetes mellitus.³⁰⁻³² In patients with diabetes, *Rhizopus* is the most commonly found fungus. The reason which allows them to survive in high acid and glucose are an enzyme properties and ketone reductase.³³ Treatment pathway for patient with COVID-19 with mucormycosis co-infection including both diseases therapy. Therapy requires surgical debridement, antifungal treatment and stabilization of risk factor.⁸

Diabetic ketoacidosis (DKA) often occurs in severe infections, such as in COVID-19. Therefore, it is not surprising that patients with COVID-19 are more likely to develop mucormycosis because acidic conditions make mucorales species easier to grow.³⁴ Research suggests SARS-CoV-2 induces damage of pancreatic islets resulting in acute diabetes and DKA.³⁵ Another explanation for why the diabetogenic state occurs in patients with severe COVID-19 is due to cytokine storms that increase insulin resistance and high expression of angiotensin-converting enzyme 2 receptors in pancreatic islets. Increased serum ferritin levels in severe COVID-19 also one of the possible roles of blood acidosis for mucormycosis susceptibility.^{34,36-38}

It has been proven that by administration of systemic corticosteroids could cut down death rates in COVID-19 patients on invasive mechanical ventilation.^{39,40} According to the European Organization for Research and Treatment of Cancer and the Mycoses Study Group Education and Research Consortium

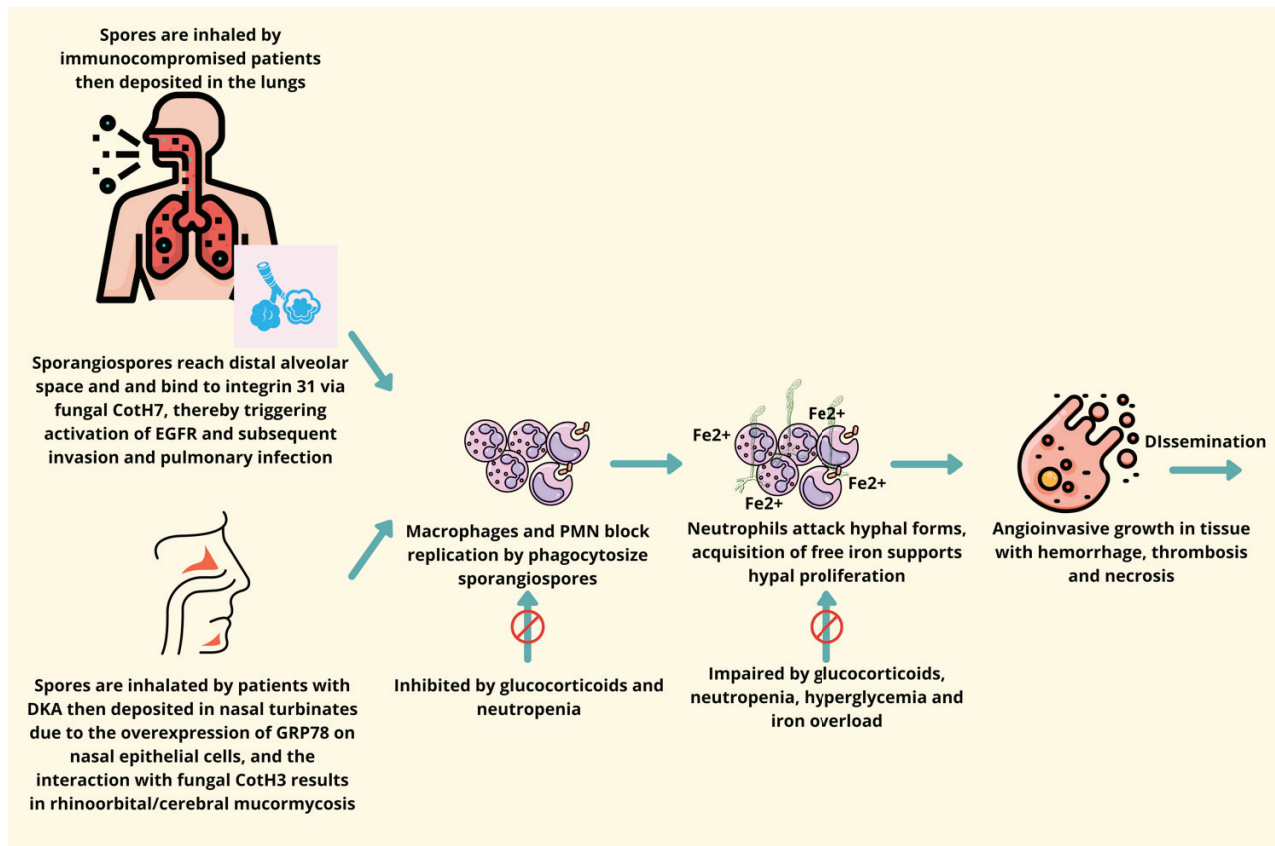


Fig. 5 Pathogenesis of Mucormycosis^{44,45}

(EORTC/MSGERC) consensus, long term corticosteroids at a therapeutic dose of ≥ 0.3 mg/kg for at most three weeks in the past 60 days is considered a risk factor for invasive fungal diseases.^{41,42} The use of corticosteroids can also increase blood glucose levels to hyperglycemia even though the individual is healthy, causing the condition called corticosteroid-induced diabetes. This corticosteroid and the diabetogenic state later can cause immunosuppression and hyperglycemia, increasing the growth of fungal infections, including mucormycosis (figure 5).^{3,5,43}

Iron acquisition is a critical step that occurs in severe COVID-19. Members of the class Zygomycetes are the only fungus identified that stores iron in ferritins. The problem is tissue damage can occur in high ferritin levels. High ferritin levels lead to excess intracellular iron that generates reactive oxygen species. Ferritin synthesis and downregulate iron export can also occur due to severe infection and DKA.^{46–50}

The resultant tissue damage leads to the release of free iron into the circulation, which further exacerbates the mucormycosis process.⁵¹

“Endothelialitis” in patients with severe COVID-19 is also one of the associations between COVID-19 and mucormycosis.^{52,53} Important initial steps of mucormycosis are endothelial adhesion and penetration.⁷ In addition, acidemic states, and hyperglycemia induce the endothelial receptor glucose-regulated protein (GRP 78) and the mucorales adhesin spore coat protein homologs (CotH), creating a “perfect storm” for increased adhesion and penetration of mucorales to the endothelium.⁵⁴

Based on the available literature regarding mucormycosis co-infection COVID-19, there were six studies reporting 28 patients that have reported rhino-orbito-cerebral mucormycosis. It is important to remember that mucormycosis can occur at any time after a COVID-19 infection, either during the hospital stay, or a few days to weeks after discharge. Therefore, all physicians

could be more aware of these side effects of the kinds of treatment patients are given and how could patients be more aware of what they could face because of the medicine that they are taking, especially if having underlying conditions. They should knowledgeable about the red flag symptoms of invasive mucormycosis.^{11,29,55–58}

Alekseyev, et al presented a 41-year-old man with a history of type 1 diabetes mellitus (T1DM), COVID-19 pneumonia and rhinocerebral mucormycosis. He was treated with steroids and hydroxychloroquine before, as the recommended regional COVID-19 practice guideline at the time. For his diabetic ketoacidosis (DKA) treated with intravenous fluids and an intravenous insulin, cefepime and amphotericin B IV, along with three surgical debridements for the rhinocerebral mucormycosis. The patient successfully discharged and continued the treatment at home.⁵⁹

Another study by *Kanwar* et al, they presented 56-year-old man with COVID-19 and underlying end-stage renal disease. This patients also developed mucormycosis as a complication of COVID-19. He received a five-day therapy of methylprednisone, one dose of tocilizumab, and one unit of convalescent plasma. At first hospital admission, blood cultures collected were negative for bacterial and fungal organisms. He was discharged home seven days later but five days later he was readmitted because shortness of breath. Polymerase chain reaction (PCR) examination for COVID-19 was positive again and chest radiograph showed increasing density and pleural effusion. He was started on empiric intravenous (IV) vancomycin and piperacillin-tazobactam. Sputum sample was collected and showed filamentous fungal elements on fungal stain that was suspected from Mucorales group because non-septate hyphae. Empiric amphotericin B was started and antibacterial medications were discontinued, unfortunately the patient developed cardiac arrest and died the following day.⁶⁰

Maini et al, reported a 38-year-old man with COVID-19 confirmed, no history of diabetes or

other condition. He was monitored in ICU and started on remdesivir IV, methylprednisolone IV and dexamethasone. After 12 days of treatment, the glycated hemoglobin (HbA1C) level was 12.3%. Eighteen days later, the patient complaint of swelling and pain in his left eye, then underwent MRI scan and histopathologic examination from sinus sample. Patient was then diagnosed as sino-orbital mucormycosis. Medical treatment was changed into amphotericin B and patient was going into surgical debridement. After a total of 38 days of hospitalization, he was discharged and continued treatment at home.⁶¹

CONCLUSION

In COVID-19, due to immune system dysregulation, diabetogenic state, endothelialitis, and the widespread use of steroids as therapy against COVID-19 may lead to the development/exacerbation of pre-existing fungal diseases. Physicians should be aware of the development/exacerbation of pre-existing fungal infection among COVID-19 patients, especially if rhino-orbital-cerebral presentations are noted. A multidisciplinary approach should include the recognition of host factors, assessment of clinical manifestations, use of appropriate imaging modalities, histology and microbiology with any appropriate surgical consultation and treatment. The use of steroids should be monitored to achieve a therapeutic effect at the lowest dose and shortest durations to lower the risk of development/exacerbation of pre-existing fungal infection.

ACKNOWLEDGEMENTS

The authors deliver gratitude to all institution which support this research.

CONFLICT OF INTEREST

The authors declare that they have no conflict of interest.

REFERENCES

1. Clancy CJ, Schwartz IS, Kula B, Nguyen MH. Bacterial Superinfections Among Persons With Coronavirus Disease 2019: A Comprehensive Review of Data From Postmortem Studies. *Open Forum Infect Dis*. 2021;8(3).
2. Arastehfar A, Carvalho A, van de Veerdonk FL, Jenks JD, Koehler P, Krause R, et al. COVID-19 associated pulmonary aspergillosis (CAPA)—from immunology to treatment. *J Fungi*. 2020;6(2):1–17.
3. Ardi P, Daie-Ghazvini R, Hashemi SJ, Salehi MR, Bakhshi H, Rafat Z, et al. Study on invasive aspergillosis using galactomannan enzyme immunoassay and determining antifungal drug susceptibility among hospitalized patients with hematologic malignancies or candidates for organ transplantation. *Microb Pathog*. 2020 Oct;147:104382.
4. Garg D, Muthu V, Sehgal IS, Ramachandran R, Kaur H, Bhalla A, et al. Coronavirus Disease (Covid-19) Associated Mucormycosis (CAM): Case Report and Systematic Review of Literature. *Mycopathologia*. 2021;2.
5. Lionakis MS, Kontoyiannis DP. Glucocorticoids and invasive fungal infections. Vol. 362, *Lancet*. Elsevier B.V.; 2003. p. 1828–38.
6. Roden MM, Zaoutis TE, Buchanan WL, Knudsen TA, Sarkisova TA, Schaufele RL, et al. Epidemiology and outcome of zygomycosis: A review of 929 reported cases. *Clin Infect Dis*. 2005;41(5):634–53.
7. Cornely OA, Alastruey-Izquierdo A, Arenz D, Chen SCA, Dannaoui E, Hochhegger B, et al. Global guideline for the diagnosis and management of mucormycosis: an initiative of the European Confederation of Medical Mycology in cooperation with the Mycoses Study Group Education and Research Consortium. *Lancet Infect Dis*. 2019;19(12):e405–21.
8. WHO. Epidemiological Alert: COVID-19 associated Mucormycosis . *Pan Am Heal Organ* . 2021; Available from: https://iris.paho.org/bitstream/handle/10665.2/54284/EpiUpdate11June2021_eng.pdf?sequence=1&isAllowed=y
9. Mucormycosis | Fungal Diseases | CDC.
10. Richardson M. The ecology of the zygomycetes and its impact on environmental exposure. *Clin*
11. Werthman-Ehrenreich A. Mucormycosis with orbital compartment syndrome in a patient with COVID-19. *Am J Emerg Med*. 2021 Apr;42:264.e5-264.e8.
12. Prakash H, Chakrabarti A. Global epidemiology of mucormycosis. *J Fungi*. 2019;5(1).
13. Skiada A, Lass-Floerl C, Klimko N, Ibrahim A, Roilides E, Petrikkos G. Challenges in the diagnosis and treatment of mucormycosis. *Med Mycol*. 2018;56:S93–101.
14. Petrikkos G, Skiada A, Lortholary O, Roilides E, Walsh TJ, Kontoyiannis DP. Epidemiology and clinical manifestations of mucormycosis. *Clin Infect Dis [Internet]*. 2012 Feb 1 [cited 2021 May 30];54(SUPPL. 1):S23–34. Available from: https://academic.oup.com/cid/article/54/suppl_1/S23/284492
15. ASI. BS. Mucormycosis | Harrison's Principles of Internal Medicine, 19e | AccessMedicine | McGraw-Hill Medical. 2015. 1350–53 p.
16. Garlapati K, Chavva S, Vaddeswarupu RM, Surampudi J. Case Report Fulminant Mucormycosis Involving Paranasal Sinuses: A Rare Case Report. 2014;
17. Peng M, Meng H, Sun Y, Xiao Y, Zhang H, Lv K, et al. Clinical features of pulmonary mucormycosis in patients with different immune status. *J Thorac Dis [Internet]*. 2019 Dec 1 [cited 2021 May 31];11(12):5042–52. Available from: [/pmc/articles/PMC6988080/](https://pubmed.ncbi.nlm.nih.gov/34088080/)
18. Hammer MM, Madan R, Hatabu H. Pulmonary mucormycosis: Radiologic features at presentation and over time. *Am J Roentgenol*. 2018 Apr;210(4):742–7.
19. Therakathu J, Prabhu S, Irodi A, Sudhakar SV, Yadav VK, Rupa V. Imaging features of rhinocerebral mucormycosis: A study of 43 patients. *Egypt J Radiol Nucl Med*. 2018 Jun;49(2):447–52.
20. Skiada A, Lass-Floerl C, Klimko N, Ibrahim A, Roilides E, Petrikkos G. Challenges in the diagnosis and treatment of mucormycosis [Internet]. Vol. 56, *Medical Mycology*. Oxford University Press; 2018 [cited 2021 May 31]. p. S93–101. Available from: https://academic.oup.com/mmy/article/56/suppl_1/S93/4925966
21. Kimura M, Nishimura K, Enoki E, Chikugo T, Maenishi O. Chlamyospores of *Rhizopus microsporus* var. *rhizopodiformis* in Tissue of Pulmonary Mucormycosis.
22. R A, A Y, H S, ND P, PJ L, EM H. Pulmonary Mucormycosis: Risk Factors, Radiologic Findings, and Pathologic Correlation. *Radiographics*. 2020 May;40(3):656–66.
23. Mekki SO, Hassan AA, Falemban A, Alkotani N, Alsharif SM, Haron A, et al. Pulmonary Mucormycosis: A Case Report of a Rare Infection with Potential Diagnostic Problems. *Case Rep Pathol*. 2020 Jan;2020:1–4.
24. Lass-Flörl C. Zygomycosis: Conventional laboratory diagnosis. *Clin Microbiol Infect*. 2009;15(SUPPL. 5):60–5.
25. Spellberg B, Ibrahim AS, Chin-Hong PV, Kontoyiannis DP, Morris MI, Perfect JR, et al. The deferasirox-AmBisome therapy for mucormycosis (Defeat Mucor) study: A randomized, double-blinded, placebo-controlled trial. *J Antimicrob Chemother*. 2012;67(3):715–22.
26. Riley TT, Muzny CA, Swiatlo E, Legendre DP. Breaking the Mold: A Review of Mucormycosis and Current Pharmacological Treatment Options. Vol. 50, *Annals of Pharmacotherapy*. SAGE Publications Inc.; 2016. p. 747–57.

27. Ferguson BJ. Mucormycosis of the nose and paranasal sinuses. *Otolaryngol Clin North Am.* 2000 Apr;33(2):349–65.
28. Greenberg RN, Scott LJ, Vaughn HH, Ribes JA. Zygomycosis (mucormycosis): Emerging clinical importance and new treatments. Vol. 17, *Current Opinion in Infectious Diseases.* Curr Opin Infect Dis; 2004. p. 517–25.
29. Mehta S, Pandey A. Rhino-Orbital Mucormycosis Associated With COVID-19. *Cureus.* 2020;12(9):10–4.
30. Garg D, Muthu V, Sehgal IS, Ramachandran R, Kaur H, Bhalla A, et al. Coronavirus Disease (Covid-19) Associated Mucormycosis (CAM): Case Report and Systematic Review of Literature. *Mycopathologia.* 2021;186(2):289–98.
31. Lansbury LE, Rodrigo C, Leonardi-Bee J, Nguyen-Van-Tam J, Lim WS. Corticosteroids as adjunctive therapy in the treatment of influenza: An updated cochrane systematic review and meta-analysis. *Crit Care Med.* 2020;E98–106.
32. Afroze SN, Korlepara R, Rao GV, Madala J. Mucormycosis in a diabetic patient: A case report with an insight into its pathophysiology. *Contemp Clin Dent.* 2017 Oct;8(4):662–6.
33. Nagao K, Ota T, Tanikawa A, Takae Y, Mori T, Udagawa SI, et al. Genetic identification and detection of human pathogenic *Rhizopus* species, a major mucormycosis agent, by multiplex PCR based on internal transcribed spacer region of rRNA gene. *J Dermatol Sci.* 2005 Jul;39(1):23–31.
34. Spellberg B, Edwards J, Ibrahim A. Novel perspectives on mucormycosis: Pathophysiology, presentation, and management. Vol. 18, *Clinical Microbiology Reviews.* 2005. p. 556–69.
35. Yang JK, Lin SS, Ji XJ, Guo LM. Binding of SARS coronavirus to its receptor damages islets and causes acute diabetes. *Acta Diabetol.* 2010;47(3):193–9.
36. Tan L, Wang Q, Zhang D, Ding J, Huang Q, Tang YQ, et al. Lymphopenia predicts disease severity of COVID-19: a descriptive and predictive study. *Signal Transduct Target Ther.* 2020;5(1):16–8.
37. Rammaert B, Lanternier F, Poirée S, Kania R, Lortholary O. Diabetes and mucormycosis: A complex interplay. Vol. 38, *Diabetes and Metabolism.* Elsevier Masson; 2012. 38(3):193–204.
38. Balasopoulou A, Kokkinos P, Pagoulatos D, Plotas P, Makri OE, Georgakopoulos CD, et al. Symposium Recent advances and challenges in the management of retinoblastoma Globe - saving Treatments. *BMC Ophthalmol.* 2017;17(1):1.
39. Sterne JAC, Murthy S, Diaz J V., Slutsky AS, Villar J, Angus DC, et al. Association between Administration of Systemic Corticosteroids and Mortality among Critically Ill Patients with COVID-19: A Meta-analysis. *JAMA - J Am Med Assoc.* 2020;324(13):1330–41.
40. Dexamethasone in Hospitalized Patients with Covid-19. *N Engl J Med.* 2021;384(8):693–704. Peter Donnelly J, Chen SC, Kauffman CA, Steinbach WJ, Baddley JW, Verweij PE, *et al.* Revision and update of the consensus definitions of invasive fungal disease from the european organization for research and treatment of cancer and the mycoses study group education and research consortium. *Clin Infect Dis.* 2020;71(6):1367–76.
41. Song Y, Zhang M, Yin L, Wang K, Zhou Y, Zhou M, et al. COVID-19 treatment: close to a cure? A rapid review of pharmacotherapies for the novel coronavirus (SARS-CoV-2). Vol. 56, *International Journal of Antimicrobial Agents.* Elsevier B.V.; 2020.
42. Aljehani M, Alahmadi H, Alshamani M. Case Report A Case Report of Complete Resolution of Auricular Mucormycosis in an 18-Month-Old Diabetic Child. 2021;
43. Alqarihi A, Gebremariam T, Gu Y, Swidergall M, Alkhazraji S, Soliman SSM, et al. GRP78 and integrins play different roles in host cell invasion during mucormycosis. *MBio.* 2020;11(3).
44. Lewis RE, Kontoyiannis DP. Epidemiology and treatment of mucormycosis. *Future Microbiology.* 2013;8(9):1163–75.
45. Perricone C, Bartoloni E, Bursi R, Cafaro G, Guidelli GM, Shoenfeld Y, et al. COVID-19 as part of the hyperferritinemic syndromes: the role of iron depletion therapy. *Immunol Res.* 2020;68(4):213–24.
46. De Locht M, Boelaert JR, Schneider YJ. Iron uptake from ferrioxamine and from ferrirhizoferrin by germinating spores of *rhizopus microsporus*. *Biochem Pharmacol.* 1994;47(10):1843–50.
47. Maertens J, Demuynck H, Verbeke EK, Zachée P, Verhoef GEG, Vandenberghe P, et al. Mucormycosis in allogeneic bone marrow transplant recipients: Report of five cases and review of the role of iron overload in the pathogenesis. *Bone Marrow Transplant.* 1999;24(3):307–12.
48. Cardoso F, Senkus E, Costa A, Papadopoulos E, Aapro M, André F, et al. 4th ESO-ESMO international consensus guidelines for advanced breast cancer (ABC 4). *Ann Oncol.* 2018;29(8):1634–57.
49. Boelaert JR, De Locht M, Van Cutsem J, Kerrels V, Cantinieaux B, Verdonck A, et al. Mucormycosis during deferoxamine therapy is a siderophore-mediated infection: In vitro and in vivo animal studies. *J Clin Invest.* 1993;91(5):1979–86.
50. Edeas M, Saleh J, Peyssonnaud C. Iron: Innocent bystander or vicious culprit in COVID-19 pathogenesis? *Int J Infect Dis.* 2020;97:303–5.
51. Ackermann M, Verleden SE, Kuehnel M, Haverich A, Welte T, Laenger F, et al. Pulmonary Vascular Endothelialitis, Thrombosis, and Angiogenesis in Covid-19. *N Engl J Med.* 2020 Jul;383(2):120–8.
52. Varga Z, Flammer AJ, Steiger P, Haberecker M, Andermatt R, Zinkernagel AS, et al. Endothelial cell

- infection and endotheliitis in COVID-19. *Lancet*. 2020;395(10234):1417–8.
53. Sabirli R, Koseler A, Goren T, Turkcuer I, Kurt O. High GRP78 levels in Covid-19 infection: A case-control study. *Life Sci*. 2021;265(October 2020):118781.
54. Moorthy A, Gaikwad R, Krishna S, Hegde R, Tripathi KK, Kale PG, et al. SARS-CoV-2, Uncontrolled Diabetes and Corticosteroids—An Unholy Trinity in Invasive Fungal Infections of the Maxillofacial Region? A Retrospective, Multi-centric Analysis. *J Maxillofac Oral Surg*. 2021;2.
55. Sarkar S, Gokhale T, Choudhury S, Deb A. COVID-19 and orbital mucormycosis. Vol. 69, *Indian Journal of Ophthalmology*. Wolters Kluwer Medknow Publications; 2021. p. 1002–4.
56. Waizel-Haiat S, Guerrero-Paz JA, Sanchez-Hurtado L, Calleja-Alarcon S, Romero-Gutierrez L. A Case of Fatal Rhino-Orbital Mucormycosis Associated With New Onset Diabetic Ketoacidosis and COVID-19. *Cureus*. 2021 Feb;13(2).
57. Mekonnen ZK, Ashraf DC, Jankowski T, Grob SR, Vagefi MR, Kersten RC, et al. Acute Invasive Rhino-Orbital Mucormycosis in a Patient with COVID-19-Associated Acute Respiratory Distress Syndrome. *Ophthal Plast Reconstr Surg*. 2021;37(2):E40–2.
58. Alekseyev K, Didenko L, Chaudhry B. Rhinocerebral Mucormycosis and COVID-19 Pneumonia. *J Med Cases [Internet]*. 2021 [cited 2021 May 31];12(3):85–9. Available from: [/pmc/articles/PMC8040444/](https://pubmed.ncbi.nlm.nih.gov/3484444/)
59. Kanwar A, Jordan A, Olewiler S, Wehberg K, Cortes M, Jackson BR. A Fatal Case of *Rhizopus azygosporus* Pneumonia Following COVID-19. *J Fungi [Internet]*. 2021 [cited 2021 May 31];7:174. Available from: <https://doi.org/10.3390/jof7030174>
60. Maini A, Tomar G, Khanna D, Kini Y, Mehta H, Bhagyasree V. Sino-orbital mucormycosis in a COVID-19 patient: A case report. *Int J Surg Case Rep*. 2021 May 1;82:105957.