



Research Article

Effect of Maggot Flour (*Hermetia illucens* larvae) on Histopathology of Koi Carp (*Cyprinus carpio*) Muscles and Gills Infected with *Edwardsiella tarda*

Hengki Pradana* , Arief Prajitno, and Maftuch

Study Program of Magister Aquaculture, Faculty of Fisheries and Marine, Brawijaya University, Malang, East Java, 65145. Indonesia



ARTICLE INFO

Received: March 24, 2022
Accepted: April 24, 2022
Published: May 12, 2022
Available online: August 30, 2022

*) Corresponding author:
E-mail: pradana.hengky@gmail.com

Keywords:

Fish Disease
Aquaculture
Parasite
Protein

This is an open access article under the CC BY-NC-SA license (<https://creativecommons.org/licenses/by-nc-sa/4.0/>)

Abstract

The problem that fishes farmers often face is disease. Maggot contains a high protein which ranges from 41-42%. Besides that, maggot also has a good effect on increasing the body resistance of fish. While the maggot provision fulfills nutritional need, it's also expected to boost immunity against bacterial disease. One of which is *Edwardsiella tarda*, known to infect koi carp (*Cyprinus carpio*). Feeding of maggot flour at different doses, namely A (25%), B (50%), C (75%), and D (100%) was carried out to determine its effect on the histopathology of the muscles and gills of *C. carpio* infected with *E. tarda*. Water quality during the study obtained an average value, namely the temperature ranging from 26-27.5°C, pH 6.5-8.1, and DO 5.2-8 mg/L. Fish infected with *E. tarda* showed several clinical symptoms, including rapid operculum movement, irregular and slow swimming, and bleeding on the skin. The results of the histopathological analysis showed that in muscle and gill tissue, treatment C (75%) showed the lowest damage value among other treatments with an average score of necrosis 0.93, hyaline degeneration 1.33, and Edema 1.27. Average score of gill tissue damage was 0.9 fusion, 1.3 congestion, 0.9 hyperplasia. Based on this, the provision of maggot flour can be used to prevent infection of *E. tarda* against *C. carpio*.

Cite this as: Pradana, H., Prajitno, A., & Maftuch. (2022). Effect of Maggot Flour (*Hermetia illucens* larvae) on Histopathology of Koi carp (*Cyprinus carpio*) Muscles and Gills Infected with *Edwardsiella tarda*. *Jurnal Ilmiah Perikanan dan Kelautan*, 14(2):246-259. <http://doi.org/10.20473/jipk.v14i2.34532>

1. Introduction

Koi carp is one of many ornamental fish known for its beautiful shape and body color giving it high economic value. In general, indicators of beauty of koi carp and other ornamental fish can be seen from the brilliant color, physical shape and completeness, behavior, and health conditions (Andriani et al., 2019). The increasing market demand for koi carp encourages fish cultivators to improve their cultivation system towards intensive. But on the other hand, this cultivation system creates a new problem: disease (Arindita et al., 2014).

Losses caused by disease are often abysmal, which causes fish farmers to be reluctant to continue their business. According to Prajitno (2007), disease in fish in natural conditions can rise due to interactions between the host, pathogenic bodies, and environmental conditions. The bacterium *E. tarda* is one of the bacteria often found infecting freshwater fish and this bacterium is even included in the HPIK (Quarantine Fish Disease Pest) list. Bacterial infection of *E. tarda* can cause a decrease in productivity in cultured fish and can cause losses for fish farmers (Andayani et al., 2017).

E. tarda is a gram-negative bacteria measuring 1x2-3 µm with a bent rod shape and has flagella to move. *E. tarda* does not form spores or capsules and is a facultative anaerobe (Park et al., 2012). This bacterium is a pathogen that can cause edwardsiellosis disease resulting in mass death in various populations and age groups. *E. tarda* is often found to infect various freshwater and marine fish types, including *C. carpio*, tilapia, mullet eel, salmon, catfish, trout, and flounder (Mohanthy and Sahoo, 2007).

The use of chemicals for medicines containing antibiotics to control fish disease without taking account of time of application, type, and dosage according to standards could leave chemical residue in the product. For example, in 1992, Indonesian frozen shrimp fishery products contained tetracycline antibiotic residues and in 2001 Indonesian shrimp fishery products exported to Europe contained chloramphenicol and nitrofurans residues (Akbar and Fran, 2013). In addition, uncontrolled use of antibiotics can cause bacterial resistance and pollution to the environment, killing cultivated organisms (Sarjito et al., 2013). Therefore, other alternatives are needed to overcome these problems by using natural ingredients (Afifah et al., 2014). The use of natural ingredients is the right step because natural ingredients in addition to functioning as antioxidants (Silvia et al., 2016) can also increase fish immunity to environmental

changes (Subryana et al., 2020). So far, this ingredient has not shown any adverse side effects compared to antibiotics. Harlystiarini et al. (2020) stated that one of the natural ingredients that are environmentally friendly and can be used to increase the immune response of fish is maggot.

Maggot (*Hermetia illucens*) has several advantages, among others, maggot has a chewy texture and has the ability to produce natural enzymes that can enhance the digestion of fish to feed. Maggot is a source of protein that can be an alternative fish feed (Diener et al., 2009). According to Cicilia and Susila (2018), maggot contains a fairly high protein, ranging from 41-42%, besides that, maggot also has a good effect on increasing fish endurance. In addition to meeting the nutritional needs of fish, the provision of maggot is also expected to increase the fish's immune system from infection with bacterial diseases.

Histopathological observation is a method used to analyze fish tissue infected with disease. Diagnosing the disease is the right first step to determine the presence or absence of infection, at this stage there are several things that need to be considered, namely clinical signs which include behavior, external and internal characteristics, and histological changes (Asniatih et al., 2013). Histopathological observations can be carried out on organs that have important functions in the body such as muscles that function in moving certain body parts (Kilawati and Arfiati, 2017) and gills which are the main respiratory organs in fish (Saputra et al., 2013).

The use of maggot on fish has so far been widely applied but with the aim of still focusing on growth, while the provision of maggot to overcome disease problems has not been done much. Therefore, in this study, I wanted to find out how big the effect of maggot if it is used to increase body resistance and treatment of fish infected with *E. tarda* bacteria because it has not been done before. So, it is necessary to research efforts on the effect of feeding with the addition of *Hermetia illucens* Larvae flour on the histopathology of the muscles, gills, spleen, and liver of koi carp that were challenged by *E. tarda* bacteria.

This study aimed to determine the optimal dose and analyze the effect of feeding the formulation of maggot flour (*H. illucens*) in preventing *E. tarda* bacterial infection, which was observed based on the histopathological picture of the muscles and gill tissue.

2. Materials and Methods

This research was conducted in April - September 2021 at the Laboratory of Fish Disease and Health, Faculty of Fisheries and Marine Sciences, Brawijaya University Malang, Chemistry Laboratory, Faculty of Chemistry, UIN Malang, and the Juanda Fish Quarantine Center, Surabaya.

2.1 Research Design

The design used in this study was a completely randomized design (CRD). Sastrosupadi (2000) explained that a completely randomized design was used in experiments that had uniform media or experimental conditions so that the environment where the test animals were kept was in the same condition. This study observed the effect of feeding the maggot flour formulation on the histopathology of the muscles and gills of koi carp infected with *E. tarda* bacteria. In this research, there are 4 treatments, two controls and 3 replications. With the treatment of feeding maggot (*Hermetia illucens*) with a treatment dose of A 25%, B 50%, C 75%, D 100% and infected with *E. tarda* bacteria then the positive control treatment was given by feeding 0% maggot flour without being infected with *E. tarda* bacteria while the negative controls were fish fed with 0% maggot flour and infected with *E. tarda* bacteria.

2.2 Process of Obtaining *H. illucens*

Maggot was obtained from the Bahrul Magh-firoh Islamic boarding school in Malang, East Java, in the form of frozen maggot. Then the maggot is dried for two days; on the first day, the maggot is dried in an open room to remove the freezing effect and reduce the water content of the maggot. The next day, the maggots were oven-dried at 60°C for 6 hours until the maggots were completely dry. After drying, the maggot is processed into flour.

2.3 Koi Carp (*C. carpio*)

Koi carp were obtained from the Punten Fish Seed Center, Batu City, East Java, Indonesia. The experimental fish were previously acclimatized before being used for research. The selected fish should be uniform with a size of 10-12 cm and a weight of 25-28 grams. This study kept koi carp in an aquarium (30x30x40 cm). Each aquarium was filled with ten fish kept for 35 days with treatment feeding. During rearing, the fish are fed twice a day.

2.4 *Edwardsiella tarda*

The bacteria *E. tarda* was obtained from Balai Uji Standar Karantina Ikan, Pengendalian Mutu dan

Keamanan Hasil Perikanan, Jakarta. With an initial density of 10¹³ (NCIMB 2056), then *E. tarda* was re-cultured on TSA (Tryptic Soy Agar) media, then to get the desired density *E. tarda* was diluted on TSB (Tryptic Soy Broth) media.

2.5 Infection of *E. tarda* in Koi Fish

Bacterial infection of *E. tarda* in koi fish was carried out on day 30 by immersing the fish in an aquarium containing bacteria with a density of 10⁷ for 36 hours (according to the results of LC₅₀).

2.6 Spectrophotometry Fourier Transform Infrared (FTIR) Analysis

FTIR analysis was carried out to identify organic compounds contained in maggot. At this stage it was carried out at the Compound Laboratory of the State Islamic University of Malang, East Java, Indonesia.

2.7 Lethal Concentration (LC₅₀) of *E. tarda*

E. tarda bacteria were obtained from the Standard Test of Fish Quarantine, Quality Control and Safety of Fishery Products, Jakarta. With an initial density of 10¹³ cells/ml. LC₅₀ was carried out with bacterial densities of 10⁶, 10⁷, 10⁸, 10⁹ cells/ml. The LC50 pathogenicity test refers to the Dragsted-Behrens method (Hubbert, 1980).

2.8 Histopathology Analysis

Histopathological analysis was carried out according to the method described by Susanto (2008), the percentage of damage to each field of view was calculated based on the number of damaged cells (Table 1), using the formula:

$$\text{Damage Percentage} = \frac{\text{Total of damage Cell}}{\text{Total of Analysis Cell}} \times 100\%$$

Table 1. Percentage of scoring

Score	Damage Percentage (%)
1	0-5
2	6-25
3	26-50
4	>50

Observation of histopathological parameters was carried out on muscle and gill organs. Organ sam-

ples were taken from each treated fish on day 35. The tissue preparation process included: fixation, trimming, processing, insertion, coarse cutting, fine cutting, and staining (Baladrat *et al.*, 2022). Histopathological observations were carried out at the Juanda Class I Fish Quarantine Center, Surabaya. East Java.

2.9 Water Quality

Observations of water quality in temperature, pH, and DO were carried out every day at 08.00 and 16.00. During the observation, the water in the aquarium was changed every day by as much as 50% to remove the remaining feed and dirt that settled at the bottom.

2.10 Data Analysis

One Way ANOVA (Analysis of Variance) test was used to analyze the data. Then to find out the real difference between treatments, a multiple comparison test (Tukey's) was used using the SPSS V.16 application (SPSS, Chicago, IL, USA).

3. Results and Discussion

3.1 Spectrophotometry Fourier Transform Infrared (FTIR) Analysis

Based on the observations of the FTIR spectrophotometer, several frequencies were obtained which showed the type of bond and compound (Figure 1 and Table 2).

Table 2. The result of FTIR analysis

Frequency (Dachriyanus, 2004)	IR (cm ⁻¹)	Absorption	Functional group	Group
3000 - 3750		3415,304	Gugus O-H	Fenol
		3290,053	Gugus O-H	Fenol
2700 - 3000		2922,599	Gugus C-H	Alkana
		2951,679	Gugus C-H	Alkana
1500 - 1675		1541,527	Gugus C=C	Aroma-
1300 - 1475		1465,649	Gugus C-H	Alkana
		1418,869	Gugus C-H	Alkana
1020 - 1300		1264,421	Gugus C-O	Ester
		1073,758	Gugus C-O	Ester
		1028,352	Gugus C-O	Ester
650 - 900		872,773	C-H	Aroma-
		668,57	C-H	Aroma-
400 - 650		596,238	C-H	Alkana

The results of the FTIR spectrophotometer observation on maggot flour found the presence of O-H bonds at wave number 3415.304 cm⁻¹, at wave number 1541,527 it showed C=C bonds, C-H bonds were found at wave number 1465,649, then C-O bonds were shown at numbers 1264.421 to number 1028.352 based on research by Parubak (2013), which states that the presence of hydroxyl groups OH, C=C, C=O aromatic, and aliphatic CH indicates the presence of flavonoid compounds. From this statement, it can be interpreted that maggot flour contains phenol type compounds and their derivative compounds (Table 2).

3.2 Feed Formulation

Maggot flour feed was formulated by adapting research from Azizah (2019), using four treatments with a different percentages of maggot flour (Table 3). This formulation was adjusted according to the results of the proximate test of each ingredient used (Table 4).

3.3 Water Quality

The results of daily water quality observations in each aquarium showed average values, namely temperatures ranging from 26 to 27.5°C, pH 6.5 to 8.1, and DO 5.2 to 8 mg/L. This value is still within limits for koi fish to grow optimally. According to Utami *et al.* (2019), koi fish can grow in a temperature range of 20°C to 30°C. The optimum pH for optimum growth of ornamental fish ranges from 6 to 8.5 (Nuwansi *et al.*, 2021). Koi fish can tolerate DO ranging from 2 to 8 mg/L (Sutiana *et al.*, 2017).

3.4 Clinical Symptoms

The observation of clinical symptoms showed that koi fish infected with *E. tarda* showed several clinical signs, including fast operculum movements, irregular and slow swimming, and bleeding on the skin. Meanwhile, other sources said that goldfish and rainbow celebes infected with *E. tarda* showed clinical symptoms in decreased appetite (Figure 2), reduced reaction to stimuli, slow swimming, and lesions on the tail and fins (Narwiyani and Kurniasih, 2011).

3.5 Lethal Concentration (LD50) of *E. tarda*

It can be seen that the bacteria *E. tarda* with a density of 10⁷ cells/ml can cause the death of koi carp as much as 50% of the total population within 72 hours (Table 5). So that in this study, the density of bacteria used was 10⁷ cells/ml.

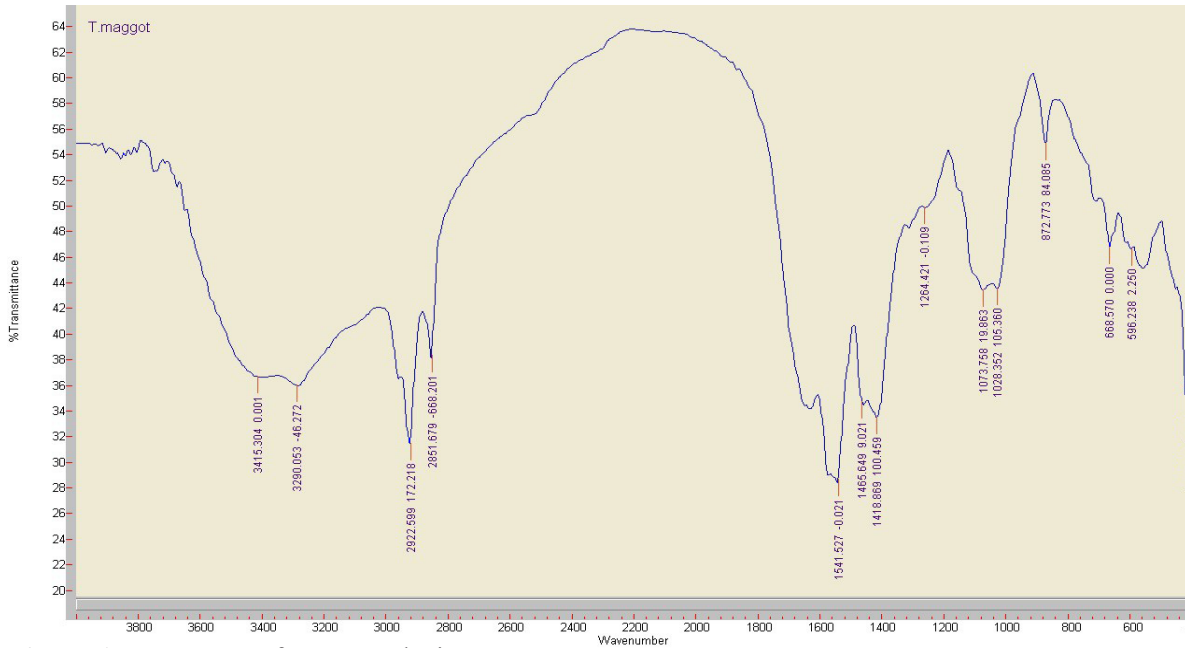


Figure 1. Frequency of FTIR analysis

Table 3. Food formulation

Type of Ingridients (%)	Treatments				
	A 25%	B 50%	C 75%	D 100%	Kontrol 0%
Fish meal	22,50	15,00	7,50	0,00	30,00
Soy meal	27,00	27,00	27,00	27,00	27,00
Maggot meal	7,68	15,35	23,03	30,71	0,00
Cassava meal	13,00	13,00	13,00	13,00	13,00
Bran meal	15,00	15,00	15,00	15,00	15,00
Tapioca	8,72	9,35	9,97	10,69	8,00
Fish oil	4,00	2,30	1,50	0,60	4,00
Vit & Mineral MIX	3,00	3,00	3,00	3,00	3,00
Jumlah (%)	100,00	100,00	100,00	100,00	100,00
Total (%)	30,48	30,48	30,48	30,48	30,48
Energy (kkal/g)	2900	2900	2900	2900	2900



Figure 2. Infected koi carp *E. tarda*

Table 4. Composition of feed ingredients

Type of In- gredients	Dry Matter (%)	Ash (%)	Protein (%)	Crude Fiber (%)	Fat (%)
Fish meal	92.92	51.16	18.23	6.48	7.96
Soy meal	91.97	5.35	36.42	4.07	23.49
Maggot meal	87.91	10	37.62	9.14	12.75
Cassava meal	87.73	3.66	2.33	4.24	0.59
Bran meal	91.36	17.75	6.83	30.68	4.74
Tapioca	91.59	0.05	0.14	0.8	0.04

Table 5. Lethal concentration 50% *E. tarda* (LC50)

Hour	Number of live koi carp			
	10 ⁶	10 ⁷	10 ⁸	10 ⁹
24	10	10	9	9
48	10	9	8	7
72	8	5	4	2
	80%	50%	40%	20%

Table 6. Average field of view in necrosis scoring in koi carp muscle tissue

Treat- ment	Test			Total	Average ± SD
	1	2	3		
A	2.6	3.4	3.2	9.2	3.07± 0.416
B	2.6	2	3	7.6	2.53± 0.503
C	1	0.6	1.2	2.8	0.93± 0.306
D	2.2	2.6	2	6.8	2.27±0.306
K-	3	3.6	3.2	9.8	3.27± 0.306
K+	0.4	0.8	0.6	1.8	0.60±0.200
Total				38	

Note: Value 1 = Light (0 - 5% damage); Value 2 = Moderate (damage 6 - 25%); Value 3 = Heavy (26 - 50% damage); Value 4 = Very heavy (damage > 50%)

3.6 Muscle Histopathology

Based on the results of this study, the histological condition of *C. carpio muscle* after infection with *E. tarda* showed different conditions in each treatment. The picture of carp muscle tissue in the negative control treatment or healthy fish showed normal tissue conditions, which was indicated by the appearance of a tight tissue structure without any cavities. Likewise, the position of striated muscles and smooth muscles looks regular without any damage. The difference between the muscle tissue of negative control fish (K-) and positive control fish (K+) is apparent (Figure 3 and Figure 4). In the picture of the positive control tissue, the muscle structure is intact and regular, it is indicated by the striated muscles that are still close to each other. In contrast to the picture of negative control tissue, which showed tissue damage, such as edema, hyaline degeneration, and necrosis. Likewise, the condition of the muscle tissue description in treatments A, B, C, and D also found the same damage in the form of necrosis, hyaline degeneration, and edema with different percentages of damage between treatments.

3.6.1 Necrosis

Necrosis is the death of cells or tissue that results in the tissue being no longer intact or abnormal. Necrosis can be caused by the presence of biological agents such as bacteria, resulting in cell changes (Austin and Zhang, 2006).

Treatment with feeding maggot flour formulations with different doses showed a significantly different effect on muscle tissue necrosis of koi carp (Table 6). Where the mean score of the lowest muscle tissue damage score was obtained in treatment C at a dose of 75% maggot flour with an average score of 0.9, which is the closest to the score for muscle tissue damage in positive control fish. However, at a higher dose in treatment D with a dose of 100% maggot flour, the average value of the koi carp muscle tissue damage score increased. So, the best dose that can prevent more severe muscle tissue damage is treatment C. Maggot contains flavonoid compounds that can improve fish immune system (Rejeki et al., 2018). However, giving maggot in higher doses will have a bad impact on fish because maggot contains high amount of chitin. Fish do not have chitinase enzymes, so feed containing chitin will be difficult for fish to digest (Wulandari et al., 2021).

3.6.2 Hyaline degeneration

Hyaline degeneration is a degeneration associated with the metabolism of various hyaline protein materials. In general, hyaline degeneration is a change in cells or extracellular spaces that show a homogeneous, bright, and pink appearance with Hematoxylin Eosin staining and causes the striated muscle fibers to disappear. Hyalinated muscle fibers become more fragile than fibers that remain intact (Takashima and Hibiya, 1995).

age damage after negative control is treatment A (25%) with a value of 3.13. while the lowest average of hyaline degeneration damage after positive control was obtained in treatment C (75%) with an average value of 1.33. However, at 100% maggot flour percentage (treatment D) the average score seems to have increased. This indicates that the given percentage has reached its optimum point to prevent koi carp from being infected with

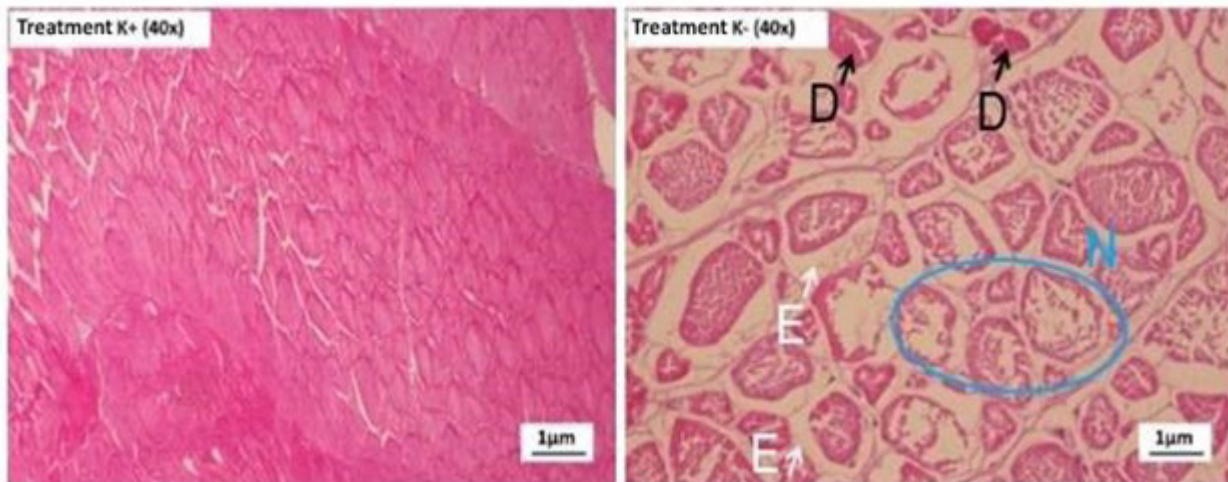


Figure 3. Muscle histology of *C. carpio* (K+) without *E. tarda* infection. (K-) *C. carpio* infected with *E. tarda*. D = hyaline degeneration. N = Necrosis. E = Edema

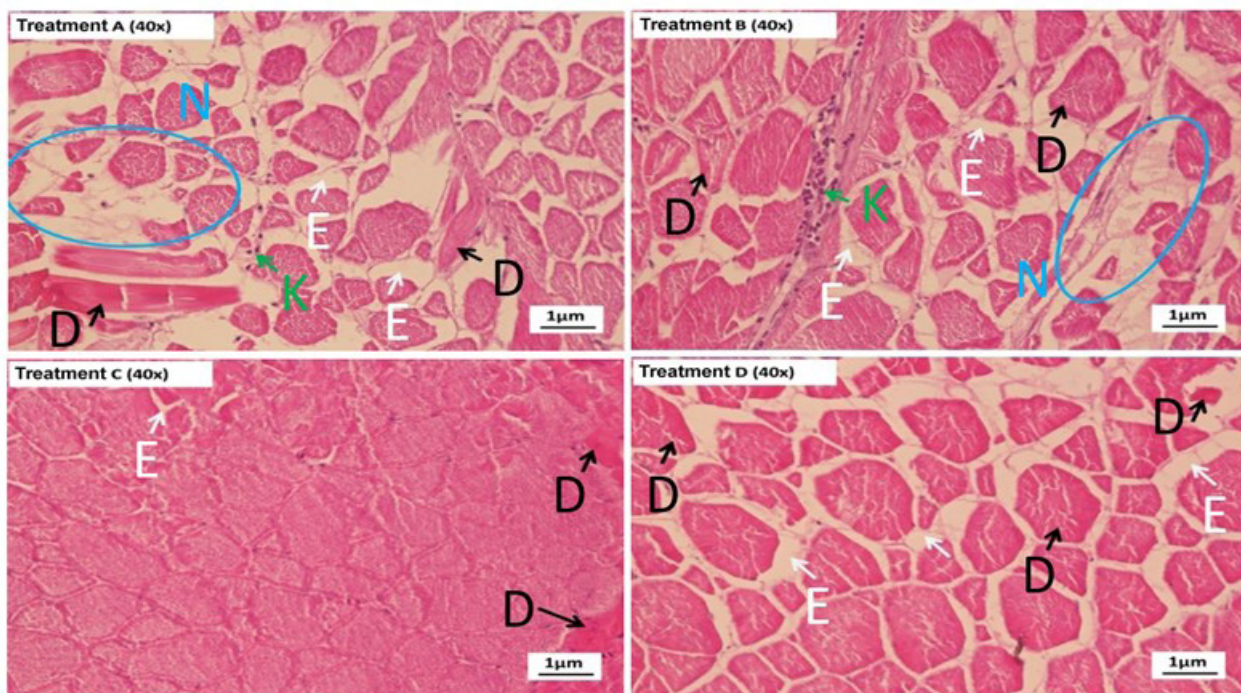


Figure 4. Histology of *C. carpio* muscle after feeding with maggot flour and infected with *E. tarda*. (A) 25%, (B) 50%, (C) 75%, (D) 100%. D = hyaline degeneration. N = Necrosis. E = Edema. K = Congestion

Based on histopathological analysis, it was shown that feeding treatment with maggot flour had an effect on the damage to hyaline degeneration of muscle tissue (Table 7). Where the results of the highest aver-

E. tarda bacteria. So that the percentage of maggot flour that is higher than the optimum percentage will actually cause muscle tissue damage. This is presumably because maggot contains secondary metabolites that can

be toxic to koi carp when given in high doses.

Secondary metabolite compounds are compounds that do not play a direct role in the growth, development, and reproduction of living things. However, usually these compounds play a role in the body's defense, because in general secondary metabolites have toxic properties for animals (Kusbiantoro and Purwaningrum, 2018).

3.6.3 Edema

Edema is an abnormal accumulation of fluid in body cavities or in the interstitial spaces of tissues and organs that can cause swelling. This condition can be associated with the presence of chemicals, viruses, bacteria, and parasitic diseases. Mechanical damage or disease can predispose fish to further infection, because edematous provides a good medium for bacterial growth (Priosoeryanto et al., 2010).

Tissue damage in treatment C had the lowest scoring value compared to other treatments with an average value of 1.27. Treatment C was the closest to the positive control value (Table 8). Meanwhile, the highest tissue damage after negative control was shown in treatment A with an average score of 3.13. The score of edemas in the koi carp muscle was seen to decrease with the increase in the percentage of maggot given, but in treatment D, the addition of 100% maggot flour, the average value again increased.

Differences in the histopathological picture of muscle tissue in each treatment occurred due to feeding with different doses of maggot flour, the scoring results showed that differences in feeding with different doses of maggot affected the level of muscle tissue damage in koi carp infected with *E. tarda* bacteria. This is because maggot contains ingredients that can improve the fish's immune system, according to a statement from Priyadi et al. (2009), that maggot contains complete amino acids needed by fish in the formation of the immune system including histidine, arginine, alanine, glycine, and several other types. According to McDonald et al. (2010), amino acids play a role in the formation of the immune system or antibodies. While the amino acids that play a role in increasing immunity include arginine, histidine, and glutamine.

3.7 Gill Histopathology

Based on the results of the study, the condition of the gills of the positive control koi carp showed normal tissue conditions, which was indicated by the appearance of a tight tissue structure without cavities (Figure 5).

Table 7. Average field of view scoring of hyaline degeneration in muscle tissue *C. carpio*

Treat- ment	Test			Total	Average ± SD
	1	2	3		
A	2.8	3.4	3.2	9.4	3.13±0.306
B	3	3.4	2.8	9.2	3.07±0.306
C	1	1.6	1.4	4	1.33±0.306
D	2.2	2.8	2.4	7.4	2.47±0.306
K-	4	3.8	3.4	11.2	3.73±0.306
K+	0.4	1	0.6	2	0.67±0.306
Total				43.2	

Table 8. Average field of view scoring edema in koi carp muscle tissue

Treat- ment	Test			Total	Average ± SD
	1	2	3		
A	3.2	3.4	2.8	9.4	3.13±0.30 6
B	2.8	3	2.4	8.2	2.73±0.30 6
C	1	1.6	1.2	3.8	1.27±0.30 6
D	2.4	1.8	2.2	6.4	2.13±0.30 6
K-	3.6	3.2	3	9.8	3.27±0.30 6
K+	0.4	0.2	0.8	1.4	0.47±0.30 6
Total				39	

Table 9. Average field of view of fusion scoring on networks

Treat- ment	Test			Total	Average
	1	2	3		
A	3	2.6	2.8	8.4	2.8± 0.2
B	2.6	2	2.4	7	2.3±0.30 6
C	0.8	1.2	0.6	2.6	0.9±0.306
D	1.8	1.4	2.4	5.6	1.9±0.503
K-	3.6	3.8	3.8	11.2	3.7±0.115
K+	0.2	0.2	0.4	0.8	0.3±0.115
Total				35.6	

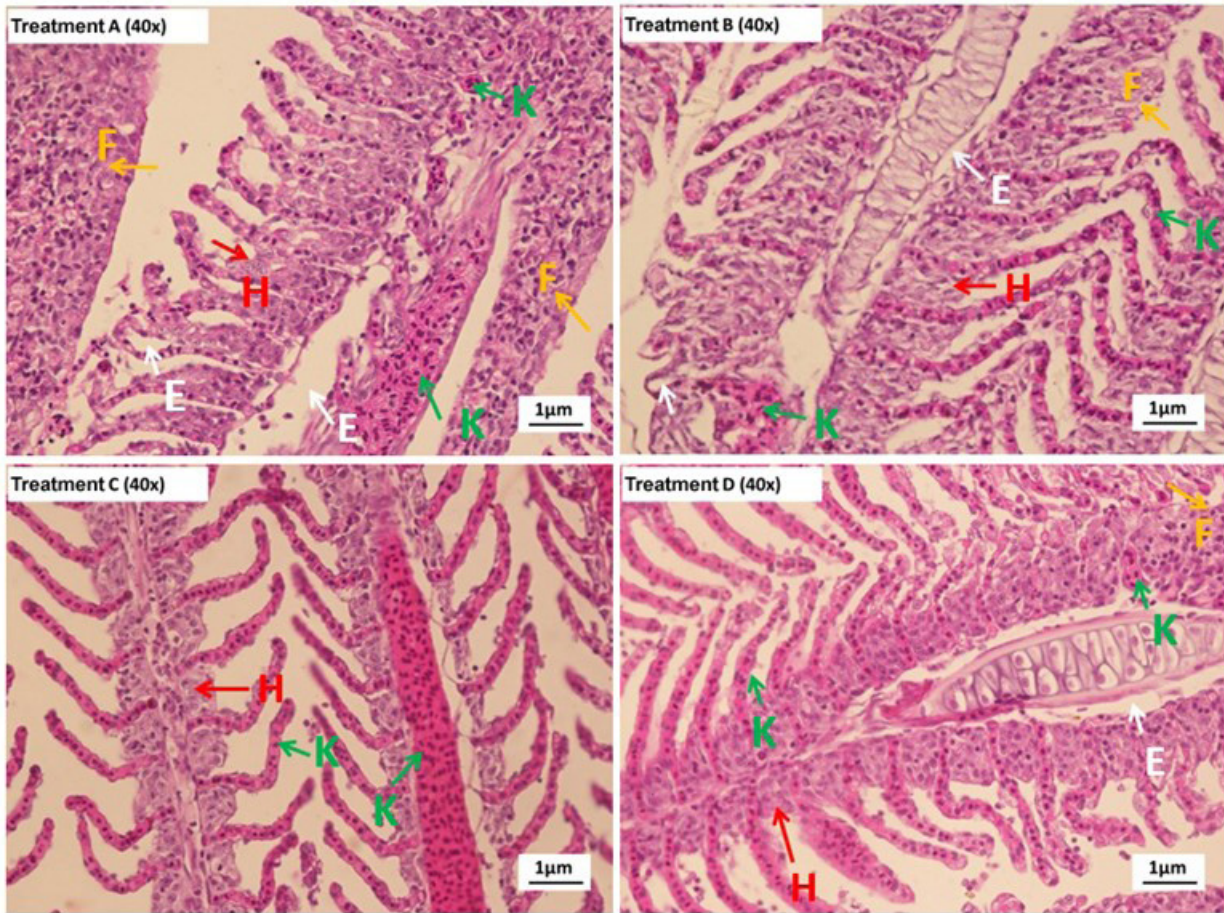


Figure 5. Histology of muscle *C. carpio* (K+) without *E. tarda* infection. (K-) *C. carpio* infected with *E. tarda*. K = Congestion. F = Fusion. N = Necrosis

Table 10. Average field of view congestion scoring on *C. carpio* gill tissue

Treatment	Test			Total	Average
	1	2	3		
A	2.8	3.2	3.4	9.4	3.1±0.306
B	3	2.8	3.2	9	3.0±0.2
C	1.6	1	1.2	3.8	1.3± 0.306
D	2	2.6	2.2	6.8	2.3± 0.306
K-	4	3.8	3.4	11.2	3.7± 0.306
K+	0.4	0.2	0.4	1	0.3± 0.115
Total				41,2	

Table 11. Mean field of view scoring hyperplasia in gill tissue

Treatment	Test			Total	Average
	1	2	3		
A	2.6	3.2	2.8	8.6	2.9± 0.306
B	2.6	2.4	2	7	2.3± 0.306
C	1.2	1	0.6	2.8	0.9± 0.306
D	1.6	2.2	2	5.8	1.9± 0.306
K-	3.8	3.6	3.2	10.6	3.5± 0.306
K+	0.6	0.2	0.4	1.2	0.4± 0.2
Total				36	

In addition, the position of the primary lamella and secondary lamella looks regular without any damage. It can be seen that there is a difference between the gill tissue of positive control (the gills of fish that are not infected with bacteria) and the gills of fish tha

are infected with bacteria (Figure 6). In the gill tissue structure of negative control fish and treatments A, B, C, and D, it appears that there was damage, including fusion, congestion, hyperplasia, and necrosis. In contrast to the case of negative control fish, the structure

of the gill tissue in positive control fish showed that the lamellae were close to each other. This indicates that the structure of the gill tissue in positive control fish is still intact and in order.

The condition of the gills of the positive control koi carp showed normal tissue conditions, which was indicated by the appearance of a tight tissue structure without cavities. In addition, the position of the primary lamella and secondary lamella looks regular without any damage. Meanwhile, in the gill tissue structure of

negative control fish, it appears that there is damage that occurs, including fusion, congestion, hyperplasia, and necrosis.

3.7.1 Fusion

Lamella fusion can occur as a result of swelling of the host cells. These conditions can result in impaired lamella function in terms of the oxygen uptake process. This will make it difficult for fish to breathe and the oxygen content in the blood will decrease (Sukarni et al., 2012).

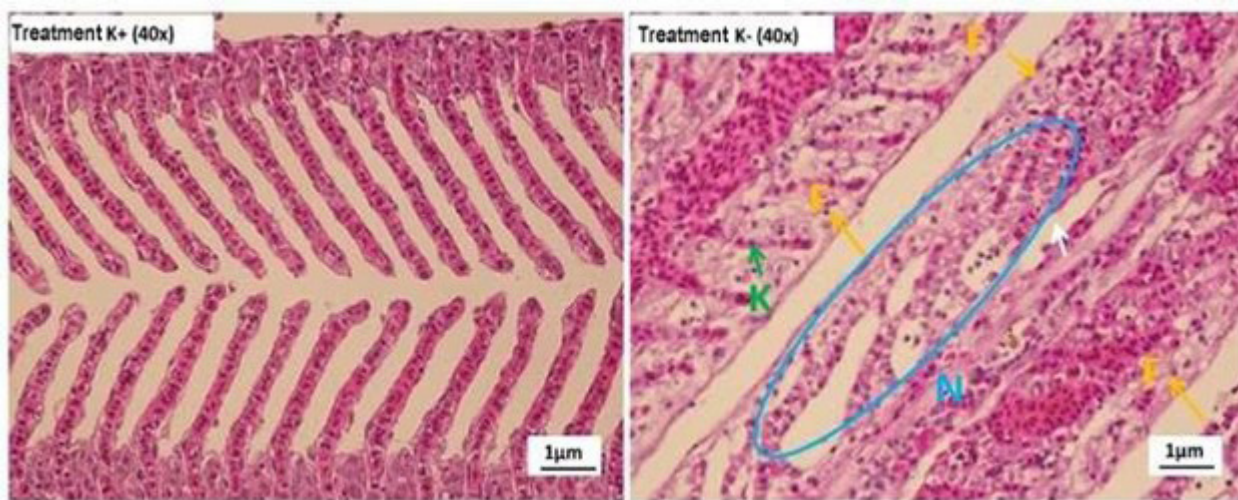


Figure 6. Histology of *C. carpio* muscle after feeding with maggot flour and infected with *E. tarda*. (A) 25%, (B) 50%, (C) 75%, (D) 100%. F = Fusion. K = Congestion. E = Edema. H = hyperplasia

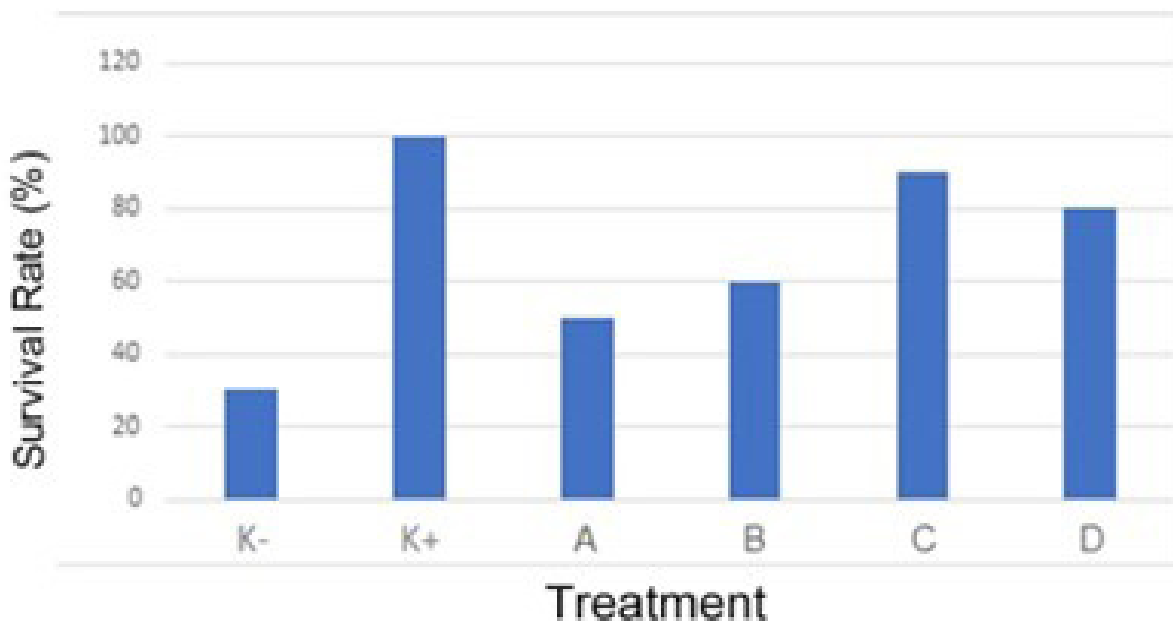


Figure 7. Survival rate

Based on data presented above, it can be seen that the koi carp fed with the formulation feed of 75% maggot showed the lowest scoring result with the average score of 0.9 (Table 9). Thus, treatment C is the closest treatment to positive control fish and is included in the criteria for mild damage. While the highest scoring value was obtained in treatment A by feeding 25% maggot formulation with an average score of 2.8 based on the scoring results indicate that the higher the dose of maggot flour given, the lower the tissue damage. According to Jasmanidar (2009), high doses can increase the defense mechanism of fish, while low doses are less effective in treating fish that have been infected with bacteria.

3.7.2 Congestion

Congestion is a condition in which the volume of blood increases due to the dilation of small blood vessels. This situation occurs due to an inflammatory reaction and organ damage, where this congestion will show a red color change depending on the degree of oxygenation of the blood. In addition, congestion is also the first pathological symptom of tissue damage and there is an increase in the amount of blood in the blood vessels so that the blood capillaries appear dilated (Ratnawati *et al.*, 2013).

The best treatment was obtained in treatment C (75%) with the lowest average score of 1.3, this value is the lowest value after positive control and included in the criteria for minor damage (Table 10). While the highest score is shown in treatment A (25%) with a mean score of 3.1 which is classified as severe damage criteria. Based on this explanation, it is suspected that feeding the maggot flour formulation can prevent more severe gill tissue damage due to *E. tarda bacterial infection*. this is related to the statement of Raharjo *et al.* (2016), maggot has a high protein content ranging from 45-52%, in addition to containing high protein, maggot is also useful for increasing the fish's immune system.

3.7.3 Hyperplasia

Hyperplasia can occur due to the number of cells that are damaged or necrotic, resulting in cell proliferation to replace damaged cells. Hyperplasia is a chronic reaction due to irritation by the presence of foreign materials. So that hyperplasia damage will appear if the fish are in a continuously polluted environment (Rennika *et al.*, 2013).

It can be seen that the mean of necrosis damage to the gill tissue of koi carp is the lowest and close to

positive control is shown in treatment C (75%) with an average score of 0.9 which indicates that tissue damage that occurs in treatment C (75%) is in the mild damage category, where this value is closest to the positive control value as a picture of healthy fish tissue (Table 11). Meanwhile, treatment A (25%) was the treatment with the highest level of tissue damage with an average score of 2.9. It can be concluded that the high dose of maggot flour given can affect the low damage to *C. carpio* gill hyperplasia. This is in accordance with the statement put forward by Harmita and Radji (2008), The dose and number of dose groups must be sufficient, so that the best dose or dose that can cause toxic effects can be obtained.

3.8 Survival Rate

The results of the measurement of survival rate for 35 days of koi carp maintenance showed the value of each treatment, namely treatment A by 50%, treatment B by 60%, treatment C by 90%, and Treatment D by 80%. And in the control treatment, each value was obtained, namely the positive control of 100% and the negative control of 30% (Figure 7). Based on this, treatment C had the highest survival rate closest to the positive control value. At the same time, the lowest value was found in treatment A which was closest to the negative control value.

4. Conclusions

Based on the observations made, it can be concluded that treatment C with a dose of 75% maggot is the best treatment, with the lowest average value of damage to both muscle tissue and gills. Addition of maggot flour in feed can be used to prevent *E. tarda* infection of Koi carp.

Acknowledgment

This research was funded by the Research Grant for Professors of Brawijaya University, Malang, Indonesia. The author would also like to thank MbK Febi, Mas Andhang, MbK Titin Yuniastutik, and Mr. Udin who have provided technical assistance during their studies at the Faculty of Fisheries and Marine Sciences, Brawijaya University, Malang, East Java, Indonesia.

Author's Contribution

All authors have contributed to the final manuscript. The contributions of each author are as follows, Prof. Arief and Prof. Maftuch who has directed and

guided the implementation of this research; Hengki Pradana collected data, compiled manuscripts, compiled drawings, compiled main conceptual ideas and critically revised articles. All authors discussed the results and contributed to the final manuscript.

Conflict of Interest

The authors declare that they have no competing interests.

Funding Information

This research was funded by the Research Grant for Professors of Brawijaya University, Malang, Indonesia.

References

- Afifah, B., Abdulgani, N., & Mahasri, G. (2014). Efektifitas perendaman benih ikan mas (*Cyprinus carpio L.*) dalam larutan perasan daun api-api (*Avicennia marina*) terhadap penurunan jumlah *Trichodina sp.* *Jurnal Sains dan Seni Pomits*, 3(2):58-62.
- Akbar, J., & Fran, S. (2013). Manajemen kesehatan ikan. Banjarmasin: P3AI Universitas Lambung Mangkurat Banjarmasin.
- Andayani, S., Suprastyani, H., Gumala, G. D. A., Oktafa, U., Fatikah, N. M., Wahyudi, M., Farida, A., & Pratama, R. (2017). Pengaruh pemberian bakteri *Lactobacillus plantarum* terhadap histopatologi dan hematologi ikan patin jambal (*Pangasius djambal*) yang diinfeksi bakteri *Edwardsiella tarda*. *Journal of Fisheries and Marine Science*, 1(4):31-38.
- Andriani, Y., Wulandari, A. P., Pratama, R. I., & Zidni, I. (2019). Peningkatan kualitas ikan koi (*Cyprinus carpio*) di kelompok PBC fish farm di Kecamatan Cisaat, Sukabumi. *Jurnal Ilmiah Pengabdian kepada Masyarakat*, 5(1):33-38.
- Arindita, C., Sarjito, & Prayitno, S. B. (2014). Pengaruh penambahan serbuk lidah buaya (*Aloe vera*) dalam pakan terhadap kelulushidupan dan profil darah ikan mas (*Cyprinus carpio*) yang diinfeksi bakteri *Aeromonas hydrophila*. *Journal of Aquaculture Management and Technology*, 3(3):66-75.
- Asniatih, Idris, M., & Sabilu, K. (2013). Studi histopatologi pada ikan lele dumbo (*Clarias gariepinus*) yang terinfeksi bakteri *Aeromonas hydrophila*. *Jurnal Mina Laut Indonesia*, 3(12):13-21.
- Austin, B., & Zhang, X. H. (2006). *Vibrio harveyi*: a significant pathogen of marine vertebrates and invertebrates. *Letters in Applied Microbiology*, 43(2):119-124.
- Azizah, A. A., Ekawati, A. W., & Nursyam, H. (2019). Potential protein source from black soldier fly (*Hermetia Illucens*) larvae as a substitution for fish meal in feed formulation of common carp (*Cyprinus Carpio*). *International Journal of Scientific & Technology Research*, 8(11):1497-1501.
- Baladrat, N. K., Nurhudah, M., & Utari, H. B. (2022). Immune response of white shrimp (*Litopenaeus vannamei*) to different density and IMNV challenge. *Jurnal Ilmiah Perikanan dan Kelautan*, 14(1):83-92.
- Cicilia, A. P., & Susila, N. (2018). Potensi ampas tahu terhadap produksi maggot (*Hermetia illucens*) sebagai sumber protein pakan ikan. *Jurnal Anterior*, 18(1):40-47.
- Dachriyanus. (2004). Analisis struktur senyawa organik secara spektroskopi. Padang: Lembaga Pengembangan Teknologi Informasi dan Komunikasi (LPTIK) Universitas Andalas.
- Diener, S., Zurbrügg, C., & Tockner, K. (2009). Conversion of organic material by BSF larvae—establishing optimal feeding rates. *Waste Management & Research: The Journal for a Sustainable Circular Economy*, 27(6):603-610.
- Harlystiarini, Mutia, R., Wibawan, I. W. T., & Astuti, D. A. (2020). Immune responses and egg productions of quails fed rations supplemented with larvae meal of black soldier fly (*Hermetia illucens*). *Tropical Animal Science Journal*, 43(1):43-49.
- Harmita, & Radji, M. (2008). Buku ajar analisis hayati (3rd ed.). Jakarta: EGC.
- Hubbert, J. J. (1980). Bioassay. Dubuque: Kendal/Hunt Pub. Co.
- Jasmanidar, Y. (2009). Penggunaan ekstrak Gracilaria

- Verrucosa untuk meningkatkan sistem ketahanan udang vaname *Litopenaeus vannamei*. Thesis. Bogor: Institut Pertanian Bogor.
- Kilawati, Y., & Arfiati, D. (2017). *Iktiologi modern*. Malang: Universitas Brawijaya Press.
- Kusbiantoro, D., & Purwaningrum, Y. (2018). Pemanfaatan kandungan metabolit sekunder pada tanaman kunyit dalam mendukung peningkatan pendapatan masyarakat. *Jurnal Kultivasi*, 17(1):544-549.
- McDonald, P., Edwards, R. A., Greenhalgh, J. F. D., Morgan, C. A., Sinclair, L. A., & Wilkinson, R. G., (2010). *Animal nutrition* (7th ed.). New York: Longman.
- Mohanty, B. R., & Sahoo, P. K. (2007). Edwardsiellosis in fish: A brief review. *Journal of Biosciences*, 32(7):1331-1344.
- Narwiyani, S., & Kurniasih. (2011). Perbandingan patogenesitas, *Edwardsiella tarda* pada ikan mas koki (*Charassius auratus*) dan ikan celes rainbow (*Telmatherina celebensis*). *Jurnal Riset Akuakultur*, 6(2):291-301.
- Nuwansi, K, K, T., Verma, A. K., Chandrakant, M. H., Prabhath, G. P. W. A., & Peter, R. M. (2021). Optimization of stocking density of koi carp (*Cyprinus carpio* var. *koi*) with gotukola (*Centella asiatica*) in an aquaponic system using phytoremediated aquaculture wastewater. *Aquaculture*, 532:735993.
- Park, S. B., Aoki, T., & Jung, T. S. (2012). Pathogenesis of and strategies for preventing *Edwardsiella tarda* infection in fish. *Veterinary Research*, 43(67):1-11.
- Parubak, A. S. (2013). Senyawa flavonoid yang bersifat antibakteri dari akway (*Drimys beccariana*. Gibbs). *Chem. Prog*, 6(1):34-37.
- Prajitno, A. (2007). *Penyakit ikan-udang bakteri*. Malang: UM Press.
- Priosoeryanto, B. P., Ersa, I. M., Tiuria, R., & Handayani, S. U. (2010). Gambaran histopatologi insang, usus dan otot ikan mujair (*Oreochromis mossambicus*) yang berasal dari daerah Ciampoa, Bogor. *Hemera Zoa*, 2(1):1-8.
- Priyadi, A., Azwar, Z. I., Subamia, I. W., & Hem, S. (2009). Pemanfaatan maggot sebagai pengganti tepung ikan dalam pakan buatan untuk benih ikan balashark (*Balanthiocheilus melanopterus* Bleeker). *Jurnal Riset Akuakultur*, 4(3):367-375.
- Raharjo, E. I., Rachimi, & Arief, M. (2016). Penggunaan ampas tahu dan kotoran ayam untuk meningkatkan produksi maggot (*Hermetia illucens*). *Jurnal Ruaya*, 4(1):33-38.
- Ratnawati, A., Purwaningsih, U., & Kurniasih. (2013). Histopatologis dugaan *Edwardsiella tarda* sebagai penyebab kematian ikan mas koki (*Carassius auratus*): Postulat Koch. *Jurnal Sain Veteriner*, 31(1):55-60.
- Rejeki, M, S., Sasanti, A. D., & Ferdinand, H. T. (2018). Pemanfaatan tepung paci-paci (*Leucas lanudulaefolia*) untuk mengobati infeksi *Aeromonas hydrophila* pada ikan patin (*Pangasius* sp.). *Jurnal Akuakultur Rawa Indonesia*, 6(2):165-176.
- Rennika, Aunurohim, & Abdulgani, N. (2013). Konsentrasi dan lama pemaparan senyawa organik dan inorganik pada jaringan insang ikan mujair (*Oreochromis mossambicus*) pada kondisi *Sub Lethal*. *Jurnal Sains dan Seni Pomits*, 2(2):132-137.
- Saputra, H. M., Marusin, N., & Santoso, P. (2013). Struktur histologis insang dan kadar hemoglobin ikan asang (*Osteochilus hasseltii* C.V) di Danau Singkarak dan Maninjau, Sumatera Barat. *Jurnal Biologi Universitas Andalas*, 2(2):138-144.
- Sarjito, Prayitno, S. B., & Haditomo, A. H. C. (2013). *Pengantar parasit and penyakit ikan*. Semarang: UPT UNDIP Press Semarang.
- Sastrosupadi, A. (2000). *Rancangan percobaan praktis bidang pertanian*. Yogyakarta: Kanisius.
- Silvia, D., Katharina, K., Hartono, S. A., Anastasia, V., & Susanto, Y. (2016). Pengumpulan data base sumber antioksidan alami alternatif berbasis pangan lokal di Indonesia. *Surya Octagon Interdisciplinary Journal of Technology*, 1(2):181-198.
- Subryana, N., Wardiyanto, & Susanti, O. (2020). Peng-

- gunaan ekstrak daun kelor *Moringa oleifera* (Lam, 1785) untuk meningkatkan imunitas non spesifik benih ikan nila *Oreochromis niloticus* (Linnaeus, 1758) yang diinfeksi *Aeromonas hydrophila*. *Journal of Aquaculture and Fish Health*, 9(3):194-203.
- Sukarni, Maftuch, & Nursyam, H. (2012). Kajian penggunaan ciprofloxacin terhadap histologi insang dan hati ikan botia (*Botia macracanthus*, Bleeker) yang diinfeksi bakteri *Aeromonas hydrophila*. *The Journal of Experimental Life Science*, 2(1):6-12.
- Susanto, D. (2008). Gambaran histopatologi organ insang, otot, dan usus ikan mas (*Cyprinus carpio*) di Desa Cibanteng. Thesis. Bogor: Institut Pertanian Bogor.
- Sutiana, Erlangga, & Zulfikar. (2017). Pengaruh dosis hormon rGH dan tiroksin dalam pakan terhadap pertumbuhan dan kelangsungan hidup benih ikan koi (*Cyprinus carpio*, L). *Acta Aquatica*, 4(2):76-82.
- Takashima, F., & Hibiya, T. (1995). An atlas of fish histology normal and pathological features (2nd ed.). Tokyo: Kodansha.
- Utami, T. S. B., Hasan, Z., Syamsuddin, M. L., & Hamdani, H. (2019). Fitoremediasi limbah budidaya ikan koi (*Cyprinus carpio*) dengan beberapa tanaman sayuran dalam sistem resirkulasi akuaponik. *Jurnal Perikanan dan Kelautan*, X(2):81-88.
- Wulandari, A., Adelina, & Suharman, I. (2021). Potensi pemanfaatan silase maggot (*Hermetia illucens*) sebagai sumber protein pengganti tepung ikan dalam pakan untuk meningkatkan kinerja pertumbuhan ikan baung (*Hemibagrus nemurus*). *Berkala Perikanan Terubuk*, 49(1):852-863.