

Haemoplasmosis in A Hypoalbuminemic Cat: A Case Report

Putu Devi Jayanti^{1*}, I Wayan Nico Fajar Gunawan¹,
Soedarmanto Indarjulianto²

¹Laboratory of Clinical Diagnosis, Clinical Pathology and Veterinary Radiology, Faculty of Veterinary Medicine, Udayana University, Denpasar, Bali, Indonesia, ²Department of Internal Medicine, Faculty of Veterinary Medicine, Universitas Gadjah Mada, Yogyakarta, Indonesia.

*Corresponding author: putudevijayanti@unud.ac.id

Abstract

Haemoplasmosis is a bacterial infection in erythrocytes caused by *Mycoplasma sp.* This study aimed to report methods of diagnosis, therapy, and evaluation of therapy in cats with haemoplasmosis. The cat showed decreased appetite, conjunctivitis, presence of mucoid mucus on the eyes and nose, gum anemia with a capillary refill time of more than 2 seconds, high temperature, and weakness. Skin and hair examination reported infestations of *Ctenocephalides felis* and *Lynxacarus sp.* on the hair. Routine hematologic examination showed normochromic normocytic anemia, leukocytosis, neutrophilia, eosinophilia, lymphocytosis, monocytosis, and hypoalbuminemia. A blood test examination observed *Mycoplasma sp.* in erythrocyte cells so the cat was diagnosed with haemoplasmosis. Treatment was performed using Oxytetracycline long-acting at 20 mg/kg BW intramuscularly for 2 weeks and revealed support to recovery during the treatment period.

Keywords: anemia, cat, *Ctenocephalides felis*, haemoplasmosis, *Mycoplasma sp.*

Received: 22 February 2023

Revised: 13 March 2023

Accepted: 6 May 2023

INTRODUCTION

Haemoplasmosis or hemotropic mycoplasmas is a bacterial infection of cat erythrocytes caused by *Mycoplasma sp.* and is one of the causes of anemia in cats (Torkan *et al.*, 2013). *Mycoplasma sp.* is a bacteria that infects the blood and is called hemotropic mycoplasma or haemoplasma (Korman *et al.*, 2012; Senthil *et al.*, 2014). Haemotropic mycoplasma is a pleomorphic bacterium that infects erythrocytes by attaching to the surface of cells (Santos *et al.*, 2013; Fernandes *et al.*, 2022). *Mycoplasma sp.* is a species of haemotropic mycoplasma that was previously classified as a rickettsiae organism because it is an obligate parasite, small in size, attached to erythrocytes, and transmitted by arthropods (Tasker, 2010). *Mycoplasma sp.* infection is an acute disease that often causes hemolytic anemia in immunocompetent cats or what is often called feline infectious anemia (FIA) (Barker and Tasker, 2013; Barker, 2019).

Transmission of *Mycoplasma sp.* can occur through flea bites, vertical transmission, blood transfusions, and direct contact from infected to healthy cats (Senthil *et al.*, 2014).

Ctenocephalides felis infestation is a potential vector for transmitting infections in cats (Tasker, 2020). Male cats with the rearing method released freely in the environment have a higher risk of being infected with *Mycoplasma sp.* (Silaghi *et al.*, 2014).

Cats infected with *Mycoplasma sp.* are often characterized by weakness and fever. Some infected cats will show pica symptoms which are characterized by the habit of eating non-food items including feces to increase their body's mineral needs (Senthil *et al.*, 2014). Pica symptoms arise because anemia causes hypoxia in the liver, resulting in impaired liver function which causes cats nutritional deficiencies (Wulansari *et al.*, 2014). Mazaheri *et al.*, (2014) reported that cats infected with *Mycoplasma sp.* show clinical symptoms such as weakness, anorexia, and increased body temperature. On physical examination, the mucosa was observed to be pale to jaundice. On routine hematological examination, anemia was observed. On blood smear examination, it was observed that haemoplasma organisms were attached to the peripheral part of the erythrocytes. *Mycoplasma sp.* can cause death in infected cats if not treated

immediately (Senthil *et al.*, 2014). *Mycoplasma sp.* is ring-shaped cocci with small sizes (0,5–1,0 µm) or rods (Vedyaykin *et al.*, 2019), sometimes forming short chains consisting of 3–6 organisms (Sykes, 2010). Cats infected with *Mycoplasma sp.* produce moderate to severe anemia. Infected cats generally show fluctuations in organisms during the infection period with a dramatic decrease in hematocrit (Lappin, 2018).

The incidence of haemoplasmosis infection has been widely reported in several countries. Haemoplasmosis cases in Bangkok were reported positive in as many as 38,05% of 473 samples in semi-domestic cats (Do *et al.*, 2020). Sarvani *et al.* (2018) reported that 17,2% of 373 cats were infected with one or more haemoplasm species in Northern Serbia. Haemoplasmosis cases in Brazil were reported as positive in as many as 21,40% of 369 samples (Santos *et al.*, 2014). Do *et al.* (2020) stated that the prevalence of haemoplasma infection is generally higher in tropical countries because it supports the development of arthropods as vectors of transmission. The incidence of this disease in Indonesia has not been widely reported. The study was reported on haemoplasma infection in a mixed cat with hypoalbuminemia in Yogyakarta.

MATERIALS AND METHODS

Samples

A male mixbreed cat, 2 years old, weighing 3 kg, cream hair color, has been castrated and evaluated at the Clinic of the Department of Internal Medicine, Faculty of Veterinary Medicine, Universitas Gadjah Mada. Based on the anamnesis revealed that the cat is thin, there is a runny nose and eyes, sneezing frequently, hair loss, and decreased appetite.

Physical and Laboratory Examination

Physical examination was carried out to determine abnormalities that occurred in the case cat through systematic inspection, palpation, auscultation, and percussion. Laboratory examinations consist of routine hematology and blood chemistry examinations as well as blood smear examinations which aim to confirm the

diagnosis of the disease and consider the management therapy.

Diagnosis and Prognosis

Based on the history, clinical symptoms, results of routine hematological examination, albumin and total plasma protein levels, and blood smear examination, the cat was diagnosed as suffering from *Mycoplasma sp.* infection with fausta prognosis.

Therapy

Cats were administered long-acting Oxytetracycline injection therapy (Sanbe, Indonesia) (dose of 20 mg/kg BW intramuscularly, with repetition every 3 days for 2 weeks), Ivermectin injection (Merial Saude Animal Ltda., Brazil) (dose of 0,024 mg/kg BW subcutaneous), Dexamethasone sodium phosphate (dose of 1 mg/kg orally for 7 days), Hematodin injection (Romindo, Indonesia) (dose of 10 mg/kg BW intramuscularly), Chlorpheniramine maleate (dose of 2 mg/kg orally for 7 days), Cendoxitrol eye drops (Cendo, Indonesia) (dose of 1 drop), and infusion of 20% human serum albumin (CSL Behring GmbH, Germany). Cats were treated with 20% human serum albumin infusion to improve the condition from hypoalbuminemia.

RESULTS AND DISCUSSION

The results of the physical examination are presented in Table 1 and Table 2. Based on the lymph node evaluation, revealed that mandibular, retropharyngeal, and parotid lymph nodes were swollen. Pain responses were observed when palpating the neck and head. We also reported a cat with a body condition scoring level 1.

Based on the routine hematology examination using a Hematology Analyzer machine (Licare CC-3200, PT. Aerocom Global Sejahtera, West Jakarta, Indonesia) showed that the cat had normochromic normocytic anemia, leukocytosis, neutrophilia, eosinophilia, lymphocytosis, and monocytosis.

Based on the albumin and total plasma protein levels showed that the cat had

hypoalbuminemia (Table 3). The results of the blood test showed that the cat was infected with *Mycoplasma sp.* and the formation of Howell's jolly bodies, anulocytes, and neutrophils was observed (Figure 1). On the seventh day, another blood test was performed and the revealed that the infection was *Mycoplasma sp.* had decreased (Figure 2). However, therapy was continued to ensure negative results on the further blood test.

Based on the physical examination showed clinical symptoms in the form of anemic conjunctiva, conjunctivitis, mucoid discharge in the eyes and nose, anemic gums with capillary refill time (CRT) of more than 2 seconds, fever, weakness, and decreased appetite. Similar clinical signs were also reported by Torkan *et al.*, (2013) which included weakness, depression, anorexia, decreased body weight, intermittent fever, pale mucous membranes, as well as anemia to jaundice and splenomegaly. Clinical signs are generally less pathognomonic and depend on the stage of the disease and the rate of development of anemia in infected animals (Torkan *et al.*, 2013). On the skin and hair observation, *C. felis* and *Lynxacarus sp.* infestation were found. *C. felis* infestation in cats can act as a haemoplasma vector (Tasker *et al.*, 2018; Do *et al.*, 2020). The blood evaluation indicates that the cat has chronic inflammation due to bacterial and parasitic infections, which is followed by anemia (O'Rourke, 2022).

Jabbar and Amery (2020) reported that cats suffering from haemoplasmosis showed normochromic normocytic anemia. Anemia is a condition where the number of erythrocytes, hemoglobin, or both in the blood circulation decreases (Damian *et al.*, 2021). Anemia can be caused by infectious or non-infectious agents (Utama *et al.*, 2008). Ikram *et al.* (2012) declared that normochromic normocytic anemia occurs due to depression of erythropoiesis which can be caused by chronic inflammation, nephritis with uremia, endocrine deficiency, neoplasia, bone marrow hypoplasia due to blood parasites, and acute bleeding (Salasia and Hariono, 2010). Fernandes *et al.* (2022) declared that *Mycoplasma sp.* is a pleomorphic bacterium that attaches to the surface of red blood cells, causing hemolytic anemia by inhibiting extravascular erythrocytes

via the mononuclear phagocyte system and intravascular lysis in various pathways, either through direct damage to the cell membrane, and increased osmotic fragility (Wulansari *et al.*, 2014). This statement is supported by Santos *et al.* (2013) which states that parasites attach to the erythrocyte membrane, causing hemolysis and anemia due to intermittent parasitemia.

On blood smear examination, the formation of *Mycoplasma sp.*, Howell's jolly bodies, neutrophils, and anulocytes were observed. *Mycoplasma sp.* infestation on a blood smear it appears as a small organism with dark stains on the periphery of the cells (Sykes and Tasker, 2013; Senthil *et al.*, 2014). Howell's jolly bodies are core remains that will appear in the form of refractile objects, either singly or in groups. Howell's jolly bodies generally appear as bluish spherical or round formations and will increase in anemic conditions. Anulocyte formation was observed as a result of low hemoglobin content, which is characterized by the appearance of a large pale area in the middle of the erythrocyte (Salasia and Hariono, 2010). Farres *et al.* (2015) stated that the formation of Howell's jolly bodies appears when there is an increase in the erythropoiesis process.

Mycoplasma sp. infection is associated with the occurrence of regenerative anemia (Bergmann *et al.*, 2016) and hemolytic anemia during the acute phase of infection (Tasker, 2010). Regenerative anemia generally develops after blood loss or hemolysis of red blood cells (Ishak *et al.*, 2007). Hemolytic anemia is related to the process of massive destruction or shortening of the lifespan of erythrocytes by various diseases including blood parasites, bacterial, and viral infections, chemical agents, plant poison intoxication, and metabolic diseases. In blood parasitic infections, inclusions or parasites are generally observed in erythrocytes, namely infections by anaplasma and haemoplasma (Salasia and Hariono, 2010; Tasker, 2010). A similar statement was declared by Dharmawan (2002) that hemolytic anemia can be caused by leptospira bacteria, parasites anaplasma, haemoplasma, and trypanosoma, as well as metabolic consequences. Based on this analysis,

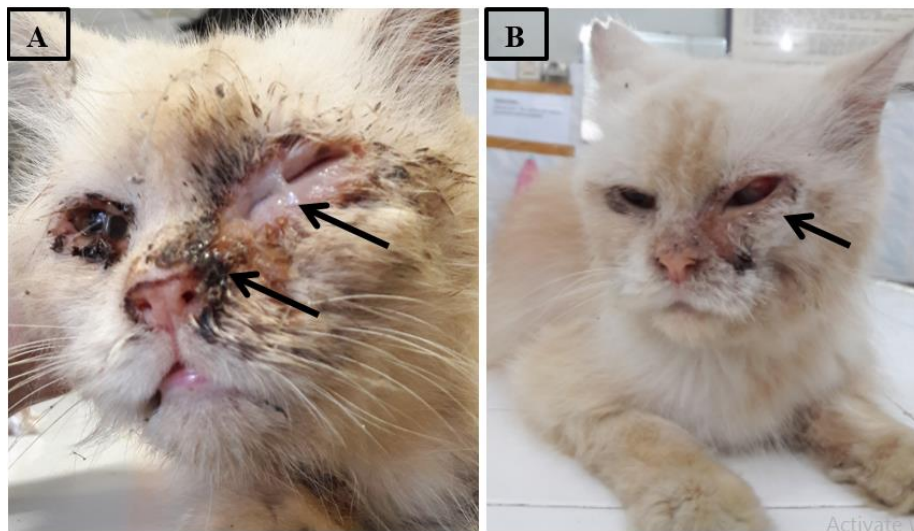


Figure 1. (A) Cat signals before therapy. Conjunctivitis, anemic mucosa, and eye and nose discharge were reported. (B) Cat signals at 7 days after therapy. It was reported that the cat's conjunctiva improved.

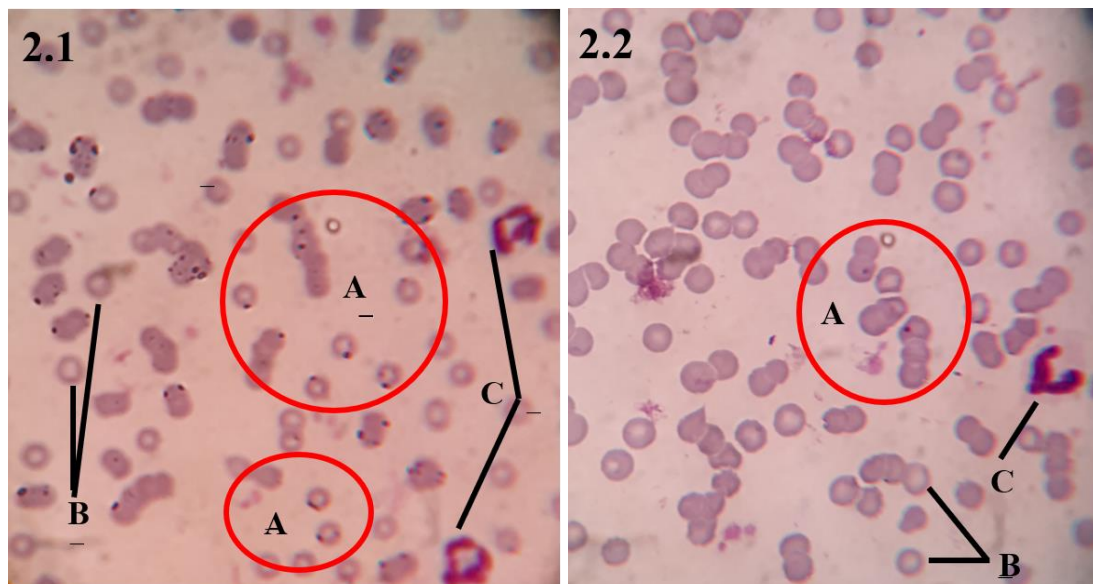


Figure 2. (2.1) Blood smear examination before therapy and (2.2) at 7 days after therapy. (A) *Mycoplasma sp.* infection in erythrocytes characterized by the formation of Howell's jolly bodies (red circles), (B) Anulocyte, (C) Neutrophils (1000x magnification).

Table 1. Praesens status data

Evaluation	Results	Reference*	Information
Rectal temperature (°C)	39,3	37,8–39,5	Normal
Heartbeat frequency (times/minute)	152	130–140	Increase
Pulsus frequency (times/minute)	156	130–140	Increase
Respiratory frequency (times/minute)	24	20–30	Normal
Capillary refill time (CRT)	> 2 seconds	< 2 seconds	Increase

*Reference: (Plumb, 2008).

Table 2. Physical examination report

Evaluation	Results
Body weight	3,1 kg
Heart rhythm	Regular
Respiratory rhythm	Regular
Eye mucosa	The left eye mucosa was red; The right eye mucosa was pale pink; Reported mucoid discharge, especially in the left eye
Eye pupil response	Normal
Nose	Mucopurulent discharge was reported
Ear	Found <i>Otodectes sp.</i>
Gums/tongue/teeth	Pale gums; no ulcers were found
Skin turgor	Dehydration
Skin and hair	<i>Ctenocephalides sp.</i> and <i>Lyncaxarus sp.</i> were found

Table 3. Evaluation of routine hematology, albumin levels, and total protein

Variables	Value	Interpretation	Reference*
Hemoglobin (g/dL)	6,4	Decrease	8,6–16,0
Hematocrit (%)	20,1	Decrease	28,0–47,0
Leukocytes ($10^3/\text{mm}^3$)	42,1	Increase	3,7–20,5
Platelets ($10^6/\text{IU}$)	419	Normal	160–660
Erythrocytes ($10^6/\text{IU}$)	4,35	Decrease	5,8–11,0
MCV (fL)	46,2	Normal	37,7–50,0
MCH (pg)	14,7	Normal	12,3–17,2
MCHC (%)	31,8	Normal	31,1–36,0
Albumin (g/dL)	2,6	Decrease	2,8–3,9
Total rotein (g/dL)	7,9	Normal	5,9–8,4
Leukocyte Differential			
Neutrophils ($10^3/\text{mm}^3$)	28,8	Increase	1,3–15,7
Basophil ($10^3/\text{mm}^3$)	0,0	Normal	0,0–0,1
Eosinophils ($10^3/\text{mm}^3$)	1,7	Increase	0,0–0,8
Lymphocytes ($10^3/\text{mm}^3$)	8,7	Increase	1,0–7,9
Monocytes ($10^3/\text{mm}^3$)	2,9	Increase	0,0–0,9

*Reference: (Plumb, 2008).

the presence of *Mycoplasma sp.*, neutrophils, Howell's jolly bodies, and anulocytes were observed, so the cat, in this case, was strongly suspected of haemoplasmosis infection.

Therapy with tetracycline and fluoroquinolone antibiotics is effective in reducing the number of *Mycoplasma sp.* organisms in the blood. In this case, the cat was treated with long-acting oxytetracycline at a dose of 20 mg/kg BW intramuscularly and repeated every 3 days for 2 weeks. Ameldev and Tresamol (2017) reported that Oxytetracycline hydrochloride at a dose of 25 mg/kg BW intramuscularly repeated 3 days for 7 days and subcutaneously for 2 weeks is effective as a therapy for haemoplasmosis infection. Administration of Doxycycline (dose of 10 mg/kg

BW orally) is generally preferred as long-term therapy for up to 8 weeks in cats suffering from haemoplasmosis. Administration of Doxycycline has been reported to produce side effects in the form of vomiting, irritation of the esophageal and stomach mucosa (Affolter *et al.*, 2017). Senthil *et al.* (2014) reported that administering Doxycycline at a dose of 5–10 mg/kg BW and vitamin B12 at a dose of 50 mg/kg BW for 7 days improves cat condition. Pradofloxacin preparations have similar effects to doxycycline but Pradofloxacin is more effective given as long-term therapy than Doxycycline (Sykes and Blondeau, 2014; Tasker *et al.*, 2018). Enrofloxacin at a dose of 5 mg/kg BW for 14 days can be given if Doxycycline cannot be tolerated (White and Reine, 2009). Tasker (2010) declared

that anemia caused by infection with *Mycoplasma sp.* occurs due to immunomediation therefore corticosteroids are recommended as supportive therapy. The combination of steroid preparations and Doxycycline is effectively used as therapy for *Mycoplasma sp.* infections in cats (Tasker, 2010). Sykes (2013) reported that Marbofloxacin was effective as a therapy for *Mycoplasma sp.* infection and does not cause retinal degeneration.

Human serum albumin 20% is a commercial human serum albumin with a solution containing 200 g/dL of total human plasma protein, where 100 ml of the solution contains at least 19,2 g/dL of human albumin (CCPI, 2008). Human serum albumin solution helps bind free fatty acids, helps the efficacy of administering drug and electrolyte therapy, and helps the process of eliminating free radicals at the site of inflammation (Jayanti *et al.*, 2019; Bihari *et al.*, 2020). Infusion of 20% human serum albumin is an effective supportive therapy used to increase plasma albumin levels so that it can support the causative and symptomatic therapy process (Vigano *et al.*, 2010; Merthayasa *et al.*, 2019). The dose of 20% human serum albumin was derived from the calculations used in Hackner's (2012) study as follows, Albumin deficit = $10 \times (\text{target albumin level} - \text{albumin level}) \times \text{BW} \times 0,3$.

Human serum albumin 20% is diluted with sodium chloride 0,9% in a ratio of 1: 9. Human serum albumin 20% infusion is given intravenously in a single dose over 4–6 hours. Blood sampling was carried out after infusion of 20% human serum albumin and showed an increase in plasma albumin levels. Similar results were reported by Jayanti *et al.* (2019) who declared that human serum albumin infusion is safe for use in cats and is effective in increasing plasma albumin levels. The application of albumin therapy in hypoalbuminemic animals aims to increase drug and electrolyte delivery, as well as the potential for free radical scavenging processes at the site of inflammation (Mazzaferro *et al.*, 2002; Horvathy *et al.*, 2017).

After the recovery period, cats improving from haemoplasmosis are latent carriers of *Mycoplasma sp.* (Sykes, 2010; Vergara *et al.*, 2016). To avoid the recurrence of infection or

horizontal spread of infection, education is carried out for owners to overcome ectoparasite infestations, maintain the cleanliness and health of pets, and clean the environment (Tasker, 2010; Islami *et al.*, 2018). Rearing methods that are not released into the environment can prevent transmission of infection (Do *et al.*, 2020). Before carrying out a blood transfusion, cats must be screened again to prevent accidental transmission from asymptomatic carrier cats (Tasker *et al.*, 2018; Purnomo *et al.*, 2022).

CONCLUSION

The diagnosis of haemoplasmosis infection in cats can be confirmed based on a decrease in erythrocyte and hematocrit levels. In addition, the blood smear examination revealed the presence of *Mycoplasma sp.* Administration of dose of 20% human albumin plasma infusion therapy was effective in increasing plasma albumin levels and its compatible with cats. Administration of long-acting Oxytetracycline at a dose of 20 mg/kg BW intramuscularly for 2 weeks reported an improvisation during recover period. It is necessary to monitor and evaluate health reports during the recovery period. It is recommended to implement good maintenance management by ensuring the cleanliness of the maintenance environment.

ACKNOWLEDGEMENTS

The author would like to thank the Kuningan Veterinary Clinic, Yogyakarta, and the Veterinary Internal Medicine Laboratory, Faculty of Veterinary Medicine, Universitas Gadjah Mada.

REFERENCES

- Affolter, K., Samowitz, W., Boynton, K., & Kelly, E. D. (2017). Doxycycline-induced gastrointestinal injury. *Human Pathology*, 66, 212–215.
- Ameldev, P., & Tresamol, P. V. (2017). Molecular detection and therapeutic

- management of feline mycoplasmosis. *IOSR Journal of Agriculture and Veterinary Science*, 10(2), 83–86.
- Barker, E. N. (2019). Update on feline hemoplasmosis. *Veterinary Clinic: Small Animal Practice*, 49(4), 733–743.
- Barker, E. N., & Tasker, S. (2013). Haemoplasmas: lesson learnt from cats. *New Zealand Veterinary Journal*, 61(14), 184–192.
- Bergmann, M., Englert, T., Stuetzer, B., Hawley, J. R., Lappin, M. R., & Hartmann, K. (2016). Risk factors of different hemoplasma species infections in cats. *BMC Veterinary Research*, 13(1), 1–6.
- Bihari, S., Bannard-Smith, J., & Bellomo, R. (2020). Albumin as a drug: its biological effects beyond volume expansion. *Critical Care and Resuscitation*, 22(3), 257–265.
- CCPI. (2008). Human Albumin 20% Behring. PEI, 1–7.
- Damian, M. T., Vulturar, R., Login, C. C., Damian, L., Chis, A., & Bojan, A. (2021). Anemia in sports: a narrative review. *Life*, 11(9), 987–991.
- Dharmawan, N. S. (2002). Pengantar Patologi Klinik Veteriner Hematologi Klinik. 2nd edition. Pelawa Sari, pp: 28–31.
- Do, T., Kamyngkird, K., Bui, L. K., & Inpankaew, T. (2020). Genetic characterization and risk factors for feline hemoplasma infection in semi-domesticated cats in Bangkok, Thailand. *Veterinary World*, 13(5), 975.
- Farres, J., Llacuna, L., Martin-Caballero, J., Martinez, C., Lozano, J. J., Ampurdanes, C., & Yelamos, J. (2015). PARP-2 sustains erythropoiesis in mice by limiting replicative stress in erythroid progenitors. *Cell Death & Differentiation*, 22(7), 1144–1157.
- Fernandes, A. J., Elshafie, N. O., Kmetiuk, L. B., Ullmann, L. S., Brandao, A. P. D., Haisi, A., & Dos Santos, A. P. (2022). Hemotropic mycoplasmas (hemoplasmas) in wild boars, hunting dogs, and hunters from two Brazilian regions. *Transboundary and Emerging Diseases*, 69(2), 908–912.
- Hackner, S. G. (2012). Plasma and Albumin Transfusion: Indications and Controversis. Cornell University Veterinary Specialists, 1–5.
- Horvathy, D. B., Simon, M., Schwarz, C. M., Masteling, M., Vacz, G., Hornyak, I., & Lacza, Z. (2017). Serum albumin as a local therapeutic agent in cell therapy and tissue engineering. *Biofactors*, 43(3), 315–330.
- Ikram, N., Baqai, H. Z., & Hassan, K. (2012). Anemia of Chronic Diseases. *Journal of Islamabad Medical & Dental College*, 1(2), 89–92.
- Ishak, A. M., Radecki, S., & Lappin, M. R. (2007). Prevalence of *Mycoplasma haemofelis*, ‘Candidatus *Mycoplasma haemominutum*’, Bartonella species, Ehrlichia species, and *Anaplasma phagocytophilum* DNA in the Blood of Cats with Anemia. *Journal of Feline Medicine and Surgery*, 9(1), 1–7.
- Islami, D. N., Dewi, C. M. S., Triana, N. M., & Purnama, M. T. E. (2018). Laporan Kasus: Otitis Eksterna dan Auricular Hematoma (Othematoma) pada Anjing Samoyed. *Jurnal Medik Veteriner*, 1(3), 80–86.
- Jabbar, S. L., & Amery, M. A. A. (2020). Diagnostic study of Hemoplasmosis in Cats in Basrah City-Iraq. *Basrah Journal of Veterinary Research*, 19(3), 48–55.

- Jayanti, P. D., Merthayasa, J. D., Indarjulianto, S., Sari, A. N., Setiawan, D. C. B., & Wijayanti, A. D. (2019). Reaksi Transfusi pada Kucing Hipoalbuminemia yang Diinfus dengan Human Serum Albumin 20%. *Acta Veterinaria Indonesiana*, 7(1), 11–16.
- Korman, R. M., Ceron, J. J., Knowles, T. G., Barker, E. N., Eckersall, P. D., & Tasker, S. (2012). Acute Phase Response to *Mycoplasma haemofelis* and ‘Candidatus *Mycoplasma haemominutum*’ Infection in FIV-infected and Non-FIV-infected Cats. *The Veterinary Journal*, 193, 433–438.
- Lappin, M. R. (2018). Update on flea and tick associated diseases of cats. *Veterinary Parasitology*, 254, 26–29.
- Mazaheri, N. F. R., Vahedi, S. M., & Mohammadkhan, F. (2014). Haemotropic mycoplasmas (haemoplasmas): a review. *International Journal of Advanced Biological and Biomedical Research*, 2(5), 1484–1503.
- Mazzaferro, E. M., Rudloff, E., & Kirby, R. (2002). The Role of Albumin Replacement in the Critically Ill Veterinary Patient. *Journal of Veterinary Emergency and Critical Care*, 12(2), 113–124.
- Merthayasa, J. D., Jayanti, P. D., Indarjulianto, S., Permana, R. H., Destinanda, N. L., & Wijayanti, A. D. (2019). Pengaruh Pemberian Serum Albumin Manusia terhadap Kadar Albumin dalam Darah pada Anjing dengan Status Hipoalbuminemia. *Jurnal Sain Veteriner*, 37(3), 34–40.
- O’Rourke, L. G. (2022). Nonclinical Evaluation of Compound-Related Cytopenias. In Brooks, M.B., Harr, K.E., Seelig, D.M., Wardrop, K.J., Weiss, D.J. (Ed) *Schalm’s Veterinary Hematology*. USA: WB Saunders Co, pp: 100–107.
- Plumb, D. C. (2008). *Plumb’s Veterinary Drug Handbook* 6th edition. Blackwell Publishing.
- Purnomo, A., Hartiningsih, Budhi, S., Adji, D., Anggraeni, D., Anggoro, D., Widyarini, S., Chhetri, S., & Purnama, M. T. E. (2022). Radiographic and Histological Evaluation in Canine Femur after Implantation of 304 Stainless-steel-based Plate. *Pharmacognosy Journal*, 14(4).
- Salasia, S. I. O., & Hariono, B. (2010). Patologi Klinis Veteriner Kasus Patologi Klinis. Samudra Biru, pp: 33–34.
- Santos, A. P. D., Conrado, F. D. O., Messick, J. B., Biondo, A. W., Oliveira, S. T. D., Guimaraes, A. M. S., & Gonzales, F. H. D. (2014). Hemoplasma prevalence and hematological abnormalities associated with infection in three different cat populations from Southern Brazil. *Revista Brasileira de Parasitologia Veterinaria*, 23, 428–434.
- Santos, L. C., Cubillia, M. P., de Moraes, W., Cubas, Z. S., Oliveira, M. J., Estrada, M., & Biondo, A. W. (2013). Hemotropic mycoplasma in a free-ranging black howler monkey (*Alouatta caraya*) in Brazil. *Journal of Wildlife Diseases*, 49(3), 728–731.
- Sarvani, E., Tasker, S., Kovacevic-Filipovic, M., Francuski-Andric, J., Andric, N., Aquino, L., & Papasouliotis, K. (2018). Prevalence and risk factor analysis for feline haemoplasmas in cats from Northern Serbia, with molecular subtyping of feline immunodeficiency virus. *Journal of Feline Medicine and Surgery Open Reports*, 4(1), 1–10.
- Senthil, N. R., Nagarajan, K., Padmanath, K., Subapriya, S., Vairamuthu, S., Tilagar, M. B., & Thirunavukkarasu. (2014). A Rare Case Study on Feline Mycoplasmosis. *International Journal of Advanced Veterinary Science and Technology*, 3(1), 106–108.

- Silaghi, C., Knaus, M., Rapti, D., Kusi, I., Shukullari, E., Hamel, D., & Rehbein, S. (2014). Survey of *Toxoplasma gondii* and *Neospora caninum*, haemotropic mycoplasmas and other arthropod-borne pathogens in cats from Albania. *Parasites & Vectors*, 7(1), 1–10.
- Sykes, J. E. (2010). Feline hemotropic mycoplasma. *Journal of Veterinary Emergency and Critical Care*, 20(1), 62–69.
- Sykes, J. E., & Blondeau, J. M. (2014). Pradofloxacin: a novel veterinary fluoroquinolone for treatment of bacterial infections in cats. *The Veterinary Journal*, 201(2), 207–214.
- Sykes, J. E., & Tasker, S. (2013). Hemoplasma infections. Canine and Feline Infectious Diseases, 1st edition. Elsevier Health Sciences, pp: 390–398.
- Tasker, S. (2010). Haemotropic Mycoplasma. *Journal of Feline Medicine and Surgery*, 12, 369–381.
- Tasker, S. (2020). Hemotropic mycoplasma. *Clinical Small Animal Internal Medicine*, 927–930.
- Tasker, S., Hofmann-Lehmann, R., Belak, S., Frymus, T., Addie, D. D., Pennisi, M. G., & Mostl, K. (2018). Haemoplasmosis in cats: European guidelines from the ABCD on prevention and management. *Journal of Feline Medicine and Surgery*, 20(3), 256–261.
- Torkan, S., Aldavood, S. J., Rafie, S. M., Hejazi, H., Shirani, D., & Momtaz, H. (2013). Prevalence and risk factor analysis of *Haemobartonella felis* in cats using direct blood smear and PCR assay. *Comparative Clinical Pathology*, 22, 1103–1109.
- Utama, I. H., Sugiyarto, Kendran, A. A. S., Apsari, I. A. P., Suarsana, I. N., Erawan, I. G. M. K., Adi, A. A. A. M., Winaya, I. B. O., & Hayashi, Y. (2008). Blood Smear Evaluation of Bali Ducks Sampled from Traditional Farming Systems in Bali. *Jurnal Veteriner*, 9(4), 188–191.
- Vedyaykin, A. D., Ponomareva, E. V., Khodorkovskii, M. A., Borchsenius, S. N., & Vishnyakov, I. E. (2019). Mechanisms of bacterial cell division. *Microbiology*, 88, 245–260.
- Vergara, R. W., Galleguillos, F. M., Jaramillo, M. G., Almosny, N. R. P., Martinez, P. A., Behne, P. G., & Muller, A. (2016). Prevalence, risk factor analysis, and hematological findings of hemoplasma infection in domestic cats from Valdivia, Southern Chile. *Comparative Immunology, Microbiology and Infectious Diseases*, 46, 20–26.
- Vigano, F., Perissinotto, L., & Bosco, V. R. F. (2010). Administration of 5% Human Serum Albumin in Critically Ill Small Animal Patients with Hypoalbuminemia: 418 Dogs and 170 Cats (1994-2008). *Journal of Veterinary Emergency and Critical Care*, 20(2), 237–243.
- White, C., & Reine, N. (2009). Feline Nonregenerative Anemia: Diagnosis and Treatment. *Compendium Vet*, 31(7), 1–11.
- Wulansari, R., Soesatyoratih, R. R., & Suryono. (2014). Kejadian dan Terapi Babesiosis dengan Clindamysin pada Kucing. *Jurnal Veteriner*, 15(3), 431–435.
