

# Pathology Anatomy and Hemolymph Profile of Spiny Lobster (*Panulirus homarus*) Infested by *Octolasmis* sp. on Bottom Cage

Sadida Anindya Bahtiar<sup>1</sup>, Gunanti Mahasri<sup>2</sup>, Mohammad Faizal Ulkhaq<sup>3\*</sup>

<sup>1</sup>Bachelor Program of Aquaculture, Faculty of Health, Medicine and Life Sciences, Universitas Airlangga, Banyuwangi, Indonesia, <sup>2</sup>Department of Aquaculture, Faculty of Fisheries and Marine, Universitas Airlangga, Surabaya, Indonesia, <sup>3</sup>Department of Health and Life Sciences, Faculty of Health, Medicine and Life Sciences, Universitas Airlangga, Banyuwangi, Indonesia.

\*Corresponding author: [m-faizalulkhaq@fpk.unair.ac.id](mailto:m-faizalulkhaq@fpk.unair.ac.id)

## Abstract

Spiny lobster, a fishery commodity with important economic value, is often infested by *Octolasmis* sp. on their bodies, which causes stress conditions that lead to death. This study aimed to determine the anatomical pathology and hemolymph profile of spiny lobster infested with *Octolasmis* sp. in bottom cages. The method used was an observation, where 30 lobsters (weight  $112.44 \pm 24.63$  g) were carried out in June–July 2022 at the Pesona Bahari Wongsorejo, Banyuwangi. Hemolymph profile and anatomical pathology data were analyzed, respectively, using the Independent T-Test and Kruskal-Wallis test ( $\alpha = 95\%$ ). The results based on scoring data showed a very significant difference between infected and healthy lobsters ( $p < 0.01$ ), characterized by the occurrence of tail flakes, lesions on the carapace, gill melanization, and the appearance of ulcers on the ventral abdomen. A very significant change occurred in the hemolymph profile of infected lobsters compared to healthy lobsters ( $p < 0.01$ ). Total hemocyte count increased with high concentrations of granular cells, respectively  $22.1\text{--}37.8 \times 10^6$  cells/mL and 63.75–64.5%, along with lobster damage, while hyaline cells decreased. This study showed that there was a change in anatomic pathology and hemolymph profile between infected and healthy lobsters.

Keywords: ectoparasite, *Octolasmis* sp., *Panulirus homarus*, spiny lobster

Received: 11 May 2023

Revised: 19 December 2023

Accepted: 5 February 2024

## INTRODUCTION

Spiny lobster (*Panulirus homarus*) is a fishery commodity that has potential resources in almost all Indonesian waters and has important economic value (Amula and Wijaya, 2019). During the lobster cultivation process, diseases from the *Octolasmis* sp. often infest the lobster's body, which causes stress conditions that lead to death, thereby reducing production rates. Diseases in spiny lobster cultivation are still an obstacle in the enlargement phase. The impact of disease attacks on lobsters has a significant effect on the decline in aquaculture lobster production, reaching 50% in Vietnam. The high mortality of larvae from natural catches of 40–60% during the nursery period is one of the factors constraining lobster cultivation (Huong *et al.*, 2014; Petersen *et al.*, 2014; Ranjan *et al.*, 2017).

*Octolasmis* sp. is one of the crustacean parasites that infest lobsters. According to Sarjito

*et al.* (2016), the impact of ectoparasite infestation on crustaceans can cause organs to be damaged. The appearance of damage in an organism's body can cause disturbances in the lobster growth process and a decrease in the host's immune system, making it easier for bacteria and viruses to cause secondary infections (Darwis, 2016). Clinical symptoms of lobsters infested by *Octolasmis* sp. are characterized by the attachment of organisms in the form of white sprouts, melanization of the gills, and the presence of fibers at the base of the carapace. Damage in the form of gill alterations leads the spiny lobster to have difficulties breathing (Sarjito *et al.*, 2016; Herlinawati *et al.*, 2017; Rokhmani and Bambang, 2020).

High levels of infection can cause changes in anatomical pathological conditions and can extend to affect the gills, mouth, and body surfaces, so prompt follow-up is required. The appearance of lesions on the body surface can also

cause the infected host to become susceptible to secondary pathogens. Attachment to the gill tissue often results in hypertrophy of the gills and fusion of the secondary lamellae, thereby reducing the surface area for respiration. An infestation that is quite severe will block the movement of the gill holder (scaphognathite) so that it interferes with the respiratory system (Wibowo *et al.*, 2021; Nur and Yusnaini, 2016; Rostika *et al.*, 2021). The increasing number of barnacles could cause death due to interruptions to the respiration system. *Octolasmis* sp. infestation can reduce lobster respiration because it can reduce the surface area of the gill lamellae, causing a deficiency in oxygen and nutrient absorption from water. *Octolasmis* sp. is suspected to be a factor that triggers stress and causes death with a high level of infestation. *Octolasmis* sp. infestation is a stressor that holds stressors, having an impact on the immune function and hemolymph biochemistry of lobsters. The enzymes involved in immunity and *Octolasmis* sp. infestation can affect the hemolymph characteristics both in plasma and hemocytes (Coates and Söderhäll, 2021; Prastowo *et al.*, 2022).

The observation of hemolymph profile parameters in spiny lobsters infested with *Octolasmis* sp. from previous studies has not been carried out. So it is necessary to investigate the anatomical pathology and hemolymph profile of lobsters infested with *Octolasmis* sp. in bottom cages so that the level of tissue damage and changes that occur can be used as a reference in the early detection of ectoparasite in spiny lobsters to prevent or treat lobster aquaculture. The purpose of this study was to determine the anatomical pathology and hemolymph profile of spiny lobster infested with *Octolasmis* sp. in bottom cages.

## MATERIALS AND METHODS

### Ethical Approval

This study was carried out under oversight and approved by the Faculty of Health, Medicine and Life Sciences, Universitas Airlangga No. 33/UN3.1.16/2022).

### Study Period and Location

This study was performed in the bottom cage of Pesona Bahari Wongsorejo Fish Farm Group at Banyuwangi. The preparation and examination samples were conducted in June–July 2022 at the Instrument and Anatomical Laboratory of the School of Health and Life Sciences, Universitas Airlangga, Banyuwangi.

### Samples

The total lobster taken from the cage was 10% of the population of lobsters and weighed  $112.44 \pm 24.63$  g.

### Anatomical Pathology Examination

Examination was carried out on all organs both outside and inside the lobster body by preparing and observing changes in shape, color, and consistency (Saptiani *et al.*, 2016). An anatomical pathology examination was carried out by observing clinical symptoms and morphological changes in lobsters covering the body surface from the eyes to the tail, walking legs, swimming legs, and gills (Gunawan, 2022). Anatomical pathology examinations were distinguished based on their location and severity of damage to the body of the spiny lobster (Table 1) (Gunawan, 2022).

### Total Hemocyte Count (THC)

Lobster hemolymph was taken in the ventral portion between the fourth and fifth walking legs by using a 1 mm syringe that is coated with EDTA as an anticoagulant (Atherley *et al.*, 2020; Haryanti *et al.*, 2017). The calculation of hemocytes was done by Hertika *et al.* (2021) using a light microscope with 400× magnification.

$$\text{THC (cell/mL)} = \frac{\text{Total cell} \times 5 \times 10^4 \times \text{Dilution Factor}}{10}$$

$$\text{Dilution Factor (mL)} = \frac{\text{Blood volume (mL)} + \text{Diluent volume (mL)}}{\text{Blood volume (mL)}}$$

### Differential Hemocyte count (DHC)

The hemocyte of the lobster was dripped on the object glass and smeared with Giemsa staining. The cell was identified and differentiated by type and percentage of hemocyte

cells, according to Wahjuningrum *et al.* (2022). A total of 100 cells were calculated, and then a percentage of each type was identified.

$$\text{DHC (\%)} = \frac{\text{Total differentiated hemocytes}}{\text{Total hemocytes counted}} \times 100$$

### Data Analysis

Hemolymph profiles containing THC and DHC data were analyzed using the Independent-T test. On the other hand, anatomical pathologic change data was analyzed using the Kruskal-Wallis test. IBM SPSS Statistics 25 was used for verification of the collected data.

## RESULTS AND DISCUSSION

### Anatomical Pathologic Scoring in Lobster

The result showed that anatomical pathological changes in spiny lobster infested with *Octolasmis* sp. vary greatly in the bottom cage of Pesona Bahari Wongsorejo Fish Farm Group at Banyuwangi. The changes in spiny lobster are just like flakes on the tail, lesions on the carapace, ulcers on the body, and gill melanization (Figure 1).

Following the study, Gunawan (2022) mentioned that the changes that occur due to *Octolasmis* sp. infestation include melanosis in the internal organs, the carapace is damaged, there are spots and infestations due to *Octolasmis* sp., lesions on the tail, and blackening of the ventral abdomen/necrosis. The severe *Octolasmis* sp. infestation will spread to the surface of the body. Overall, the occurrence of changes in the tissue in the body of the lobster is the cause of a decrease in the survival and quality of the cultivated lobster, which has an impact on the low productivity of the lobster culture. Tissue damage that occurs causes physiological disturbances in the body of the organism, thereby reducing the survival rate (Wu *et al.*, 2008).

Based on the results of anatomical pathology scoring, 30 samples of spiny lobster infested with *Octolasmis* sp. showed 18 individuals with a score of 0, a score of 1 totaling 4 individuals, scores of 2 and 3 each for 1 individual, and a score of 4 as many as 6 individuals. A score of 0 indicates that the spiny lobster is in normal

condition, and no pathological changes in the anatomy of the lobster's body are found. Lobsters that are found to have streaks on the tail indicate mild damage with a score of 1. Lobsters that experience moderate damage have a score of 2, indicated by the presence of chips on the tail accompanied by changes in the form of lesions on the carapace/ventral abdomen. Gunawan (2022) stated that a score of 2 indicates quite severe damage. While scores 3 and 4 indicate severe and very severe damage. Lobsters with a score of 3 showed scaliness on the tail, lesions on the carapace, and melanization of the gills. Damage that occurs on score 4 shows the appearance of a flaky tail, lesions on the carapace, and melanization of the gills, accompanied by ulcers on the body of the lobster. Meanwhile, based on the results of the analysis using the Kruskal Wallis test on SPSS 25, it showed a probability value of 0.000 ( $p < 0.01$ ), so the anatomical pathology scoring data on lobsters differed significantly across all sample observations. The results of anatomical pathology scoring in lobsters can be seen in Table 2.

The study by Nur and Yusnaini (2018) describes that the infestation of *Octolasmis* sp. in lobsters is associated with clinical signs like tail fin erosion and milky disease. This disease can lead to mineral thinness or shell weakness, making the lobsters more vulnerable to pathogen infections and resulting in lesions. Necrosis in the hepatopancreas, gills, uropods, and telson of lobsters infested with *Octolasmis* sp. can result in respiratory impairment, tail erosion, and stress-related effects (Atherley *et al.*, 2020; Prastowo *et al.*, 2022). Histopathological examination reveals various pathological signs that occur, including hemorrhage, tubular epithelial cell vacuolization, cell necrosis, and mineralization in uropod, telson, gill, and hepatopancreas tissue (Nur and Yusnaini, 2018). Erosion of the exoskeleton is largely due to the chitinolytic activity of microorganisms. Lesions occur due to the loss of the outer cuticle layer, which does not contain chitin and can occur through lipolytic microbial activity, predatory or cannibalistic attacks, chemical toxicity, or abrasive activity of sediment or affected body parts. Lesion development and

**Table 1.** Scoring the clinical symptoms of *Octolasmis* sp. infested in lobsters (Gunawan, 2022)

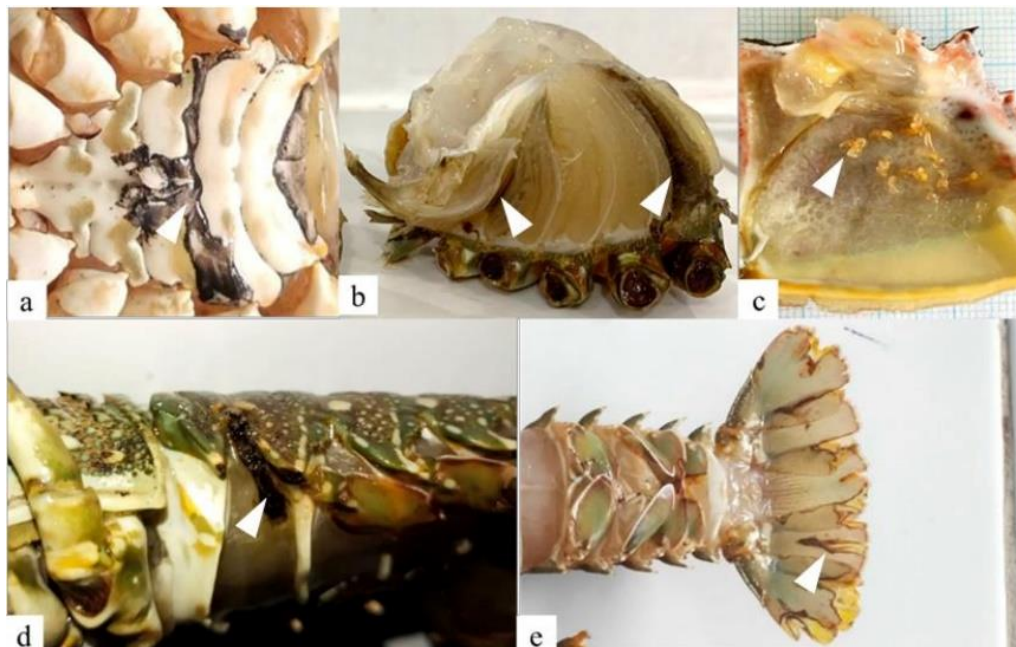
| Score | Description   |
|-------|---|
| 0     | There is no damage on both sides of the lobster, it is an undamaged level   |
| 1     | There is chipping on the lobster tail, it is a mild damage level  |
| 2     | There is chipping on the tail and lesions on the lobster carapace, it is a moderate damage level  |
| 3     | There is chipping on the tail, lesions on the lobster carapace, and melanization on the lobster gills, it is a serious level of damage                      |
| 4     | There is chipping on the tail, lesions on the lobster carapace, ulcers on the body, and melanization of the lobster gills, it is a very severe damage level |

**Table 2.** Anatomical pathology changes in spiny lobster

| Samples    | Damaged Categories   | Score |
|------------|--|-------|
| 18 lobster | no damage  | 0     |
| 4 lobster  | chipping on the lobster tail   | 1     |
| 1 lobster  | chipping on the lobster tail<br>lesions on the lobster carapace  | 2     |
| 1 lobster  | chipping on the lobster tail<br>lesions on the lobster carapace<br>melanization on the lobster gills                       | 3     |
| 6 lobster  | chipping on the lobster tail<br>lesions on the lobster carapace<br>melanization on the lobster gills<br>ulcers on the body | 4     |

**Table 3.** Hemolymph profile of spiny lobster infested with *Octolasmis* sp. using a bottom cage system

| Lobster category | Sample | THC ( $\times 10^6$ cell/mL) | Hyaline (%)        | Semi-granular (%)  | Granular (%)       |
|------------------|--------|------------------------------|--------------------|--------------------|--------------------|
| Normal           | 18     | 8.722 <sup>a</sup>           | 64.89 <sup>c</sup> | 26.50 <sup>e</sup> | 8.61 <sup>g</sup>  |
| Damaged          | 12     | 32.583 <sup>b</sup>          | 17.58 <sup>d</sup> | 18.17 <sup>f</sup> | 64.25 <sup>h</sup> |



**Figure 1.** Changes in the anatomical morphology of the bodies of lobsters infested with *Octolasmis* sp. Description: a) lesions on the ventral abdomen; b) melanization of the gills; c) *Octolasmis* sp. infestation; d) ulcers; and e) flaky tail.



shedding of ground particles mostly occur through the release of extracellular chitinase from epibiotic microorganisms (Joseph and Ravichandran, 2012).

Melanization of gills in spiny lobster infested with ectoparasite *Octolasmis* sp. showed a darker gill color change. Melanization forms a dark-colored membrane under the formation of the new epidermis. Melanin is a response of the polyphenol oxidase enzyme to melanin precursors and antimicrobial compounds. Melanin synthesis is associated with the formation of the cuticle. Melanin formation is involved in wound healing and sealing reactions, where massive deposition of melanin occurs at the wound site to seal the wound and prevent further blood loss (Sugumaran and Barek, 2016). Circulating hemocytes aggregate over the wound to form a scab, and the aggregation of hemocytes around wound sites is advantageous for repair (Huang *et al.*, 2016; Fikri *et al.*, 2022). Hemolymph that clumps and becomes darker consists of hemocytes and necrotic cell debris (Atherley *et al.*, 2020). Furthermore, in the study of Syahidah and Owens (2020), the activation of the pro-phenoloxidase enzyme induces the production of phenoloxidase (PO), which functions in the melanization process. Melanization is an important component of the body's defense system, including the innate immune system of invertebrates and the main defense as well as wound healing (Fikri *et al.*, 2023).

The occurrence of *Octolasmis* sp. infestations is caused by several things, such as the presence of a suitable host, the availability of oxygen and nutrients in the form of sufficient plankton, as well as conditions that are safe from predators (Yusgita *et al.*, 2019). *Octolasmis* sp. have been reported to have low specificity regarding host use, occurring in a variety of host species, which should be advantageous, since the availability of hard substrate is often a constraint for sessile organisms. Coral reefs become an important habitat for a diverse range of marine organisms, including *Octolasmis* sp. and its associated host species (Silva-Inácio *et al.*, 2016). The habitat of lobster can be influenced by the

hard substrate in tropical sea waters. The hiding habit of lobsters benefits *Octolasmis* sp., so they can reproduce faster by releasing cyprid larvae into the water (Yusgita *et al.*, 2019). Cyprid larvae swim freely in the water in search of suitable hosts and use their six pairs of reciprocating thoracic appendages and two anterior antennules during settlement (Yap *et al.*, 2023). High infestations of *Octolasmis* sp. on spiny lobsters were also found to affect the efficiency of gaseous exchange in the gills (Atherley *et al.*, 2020).

### Hemolymph Profile in Spiny Lobster

Hemocytes in lobster hemolymph play an important role in the immune system, as they are the lobster's body's defense system responsible for detecting foreign particles and disease agents, encapsulation, phagocytosis, and reducing toxic substances (Liu *et al.*, 2021). In crustaceans, the number of circulating hemocytes changes rapidly in response to different stimuli. The study showed that adjustment between the sessile and circulating pools of hemocytes may be the major route for the rapid regulation of circulating hemocytes in crustaceans, which can be altered by pathogen infection (Zheng *et al.*, 2021).

Different superscripts in the same column showed very significant differences ( $p < 0.01$ ). The calculation of the average value of total hemocyte cells (THC) shows an increase in the number of cells in diseased lobsters. It can be seen that the normal number of hemocyte cells in 18 lobsters is  $8.722 \pm 1.4 \times 10^6$  cells/mL, while diseased lobsters that have a score of 1–4 have a value of  $32.583 \pm 14.1 \times 10^6$  cells/mL. The THC of all 30 lobsters examined ranged from 6–59  $\times 10^6$  cells/mL, with an average of  $8.7 \times 10^6$  cells/mL for normal lobsters and  $33 \times 10^6$  cells/mL for infected samples. This value showed a very significant difference (independent T-test,  $p < 0.01$ ) with total lobster hemocytes that had not been damaged. The THC value in healthy lobsters was  $8.7 \pm 3.8 \times 10^6$  cells/mL (Table 3). The high value of THC in lobsters indicates that lobsters experience stress conditions due to environmental conditions outside of optimal conditions. Changes in environmental conditions can cause stress on the spiny lobster, affecting the immune response

through marked changes in the total concentration of THC (Subhan *et al.*, 2018; Rivaie *et al.*, 2023). The crustacean immune system is a nonspecific, innate system with responses including clotting, recognition of foreign particles, phagocytosis, melanization, and cytotoxicity mediated by the functions of circulating hemocytes (Melillo *et al.*, 2018; Safira *et al.*, 2022).

Several disturbance that occurs in lobster, such as clotting, recognition of foreign particles, phagocytosis, melanization and cytotoxicity, nutrition, weather, stress, or a range of other factors, can affect the number of hemocytes (Day *et al.*, 2019; Zakwan *et al.*, 2023). *Octolasmis* sp. predilection for gill chambers will disrupt the host's respiratory system and worsen the lobster's physiological health condition (Atherley *et al.*, 2020; Li *et al.*, 2014).

Based on the results of the study, it was shown that *Octolasmis* sp. infestation on lobster gill chambers with a score of 1 has caused a significant stress impact when compared to normal lobsters, as well as lobsters with a score of 4. This condition indicates that the higher the level of damage experienced by the lobster, the higher the concentration of THC in the lobster's body. The higher the THC value, the worse the condition of the lobster due to stress. In accordance with the study of Adiyana *et al.* (2015), the number of hemocytes in hemolymph shows a reaction to environmental stressors of disease, so it becomes an indicator of the health status of crustaceans. A higher stress level indicates a greater THC value compared to lobsters that experience a lower stress level. Stress in lobsters is characterized by changes in the amount of THC concentration, PO activity, and phagocytic activity. The high number of hemocytes in hemolymph causes the body's inability to respond, thus causing a reverse effect to become an immunosuppressor that can reduce the immune system (Ekawati *et al.*, 2012; Djai *et al.*, 2017).

Based on the observations of DHC lobsters infested with *Octolasmis* sp. in the basic cage culture system, there was a change in the concentration of hemocyte cell types based on each level of damage. The results of calculations

under conditions of damaged lobster showed that the type of hemocyte cells was dominated by granular cells at 64.25%, followed by hyaline cells at 17.58%, and semi-granular cells at 18.17%. Spiny lobsters that were damaged by *Octolasmis* sp. infestation showed an increase in the number of granular cells, accompanied by a decrease in the concentration of hyaline and semi-granular cells. Increasing the THC value can increase granular cells, which can stimulate ProPO activation to produce phenoloxidase activity so that they can defend against pathogen infections. The load number of PO in hemocytes also affected melanization in the skin (Cerenius and Soderhall, 2021). Granular cells have antibacterial protein compounds that play a role in blocking the entry of pathogenic bacteria into the crustacean body (Hauton, 2012; Jannah *et al.*, 2018; Abdi *et al.*, 2022) Furthermore, granular cells also produce esterase, reactive oxygen species (ROS), and nitric oxide (NO) as active compounds to combat the pathogen infection (Xian *et al.*, 2017; Safira *et al.*, 2023).

The dominance of granular cells in the hemolymph of spiny lobster, which suffered damage, occurred as a form of defense of the lobster body against *Octolasmis* sp. infestation. The response to stress and immune system activity can be characterized by the emergence of a predominance of two types of granular cells and a decrease in hyaline cells (Day *et al.*, 2019). The exchange, which involves a decrease in hyaline cells and an increase in granular cells, shifts immune function from hyaline cell-mediated phagocytosis to a focused response in the granular pro-PO system (Hisyam *et al.*, 2023). The high activity of pro-PO indicates that the granular cell type is a storage site for PO precursors and a mediator in the activation process. In addition, the number of hyaline cells in the lobsters' hemolymph demonstrates phagocytic capabilities (Day *et al.*, 2019).

The decrease in the concentration of hyaline cells in the hemolymph of spiny lobsters infested with *Octolasmis* sp. is due to the activity of these cells in overcoming the attack of pathogens. Hyaline cells are the first cells to play a role when there is a pathogen attack, so these cells do not

develop into semi-granular cells, and a decrease in the number of cells in hemocytes is seen (Ekawati *et al.*, 2012). Hyaline cells are cells at an intermediate stage in the stage of differentiation from semi-granular phagocytic cells and the second sub-type of development of semi-granular cells into granular cells (Hidayah *et al.*, 2020). The differentiation process can continue to be mediated by hemolymph-releasing factors so that it can explain the relationship between changes in cells and the functional role of phagocytosis in pro-PO (Day *et al.*, 2019; Kenconoajati *et al.*, 2023).

The decrease in the number of semi-granular cells seen in this study was due to the production of granular cells in the PO defense system (Prastika *et al.*, 2020). Semi-granular cells are the mature form of hyaline cells. Semi-granular cells function in the encapsulation process and few in the phagocytosis process (Ekawati *et al.*, 2012). Several factors are released as part of the activation of the function of the PO system to aggregate semi-granulocytes against foreign cells, generate nodules, and encapsulate cells so that they will be destroyed through the production of cytotoxic quinones and melanin (Day *et al.*, 2019). The melanin formed by activation of the Pro-PO cascade is used to produce nodules and encapsulate foreign cells (Charles and Killian, 2015).

## CONCLUSION

The anatomical pathology and hemolymph profile of spiny lobster infested with *Octolasmis* sp. in bottom cages showed very significant differences from normal lobsters. Alterations in anatomical pathology that occur in the form of lesions on the carapace, flaky tail, ulcers on the ventral abdomen, and melanization of the gills. Changes in hemolymph profile in the form of an increase in the amount of THC compared with normal spiny lobster and a decrease in the number of hyaline cells and semi-granular cells, while the number of granular cells increased.

## ACKNOWLEDGEMENTS

The authors would like to thank the Teaching Farm, Faculty of Health, Medicine and Life Sciences, Universitas Airlangga, for all the equipment.

## AUTHORS' CONTRIBUTIONS

MFU: Conceptualization and drafted the manuscript. GM and MFU: Validation, supervision, and formal analysis. ASB and MFU: Performed sample evaluation. GM and MFU: Performed the statistical analysis and the preparation of tables and figures. All authors have read, reviewed, and approved the final manuscript.

## COMPETING INTERESTS

The authors declare that they have no competing interests.

## REFERENCES

- Abdi, R., Setyowati, D. N., & Mukhlis, A. (2022). Pengaruh Penambahan Ekstrak Daun Jeruju (*Acanthus ilicifolius*) Dengan Dosis Berbeda Pada Pakan Terhadap Sistem Imun Udang Vaname (*Litopenaeus vannamei*) Yang Diinfeksi *Vibrio parahaemolyticus*. *Jurnal Perikanan*, 12(1), 33–44.
- Adiyana, K., Supriyono, E., Pamungkas, A., & Thesiana, L. (2015) Evaluasi Penggunaan Sistem Jaring Terhadap Respons Produksi Pendederan Juvenil Lobster Pasir (*Panulirus homarus*) Menggunakan Teknologi Resirkulasi. *Jurnal Kelautan Nasional*, 10(3), 139–150.
- Amula, N., & Wijaya, D. (2019). Estimasi Potensi dan Tingkat Pemanfaatan Sumber Daya Lobster Pasir (*Panulirus homarus*) di Perairan Prigi Kabupaten Trenggalek. *Jurnal Penelitian Perikanan Indonesia*, 25(3): 169–178.

- Atherley, N. A. M., Freeman, M. A., & Dennis, M. M. (2020) Post-mortem examination of the Caribbean spiny lobster (*Panulirus argus*, Latreille 1804) and pathology in a fishery of the Lesser Antilles. *Journal of Invertebrate Pathology*, 175(107453), 1–14.
- Bower, S. M. (2006). Fish diseases and disorders. Canada: Protozoan and Metazoan Infections Parasitic Diseases of Shellfish (CABI), pp: 466–677.
- Cerenius, L., & Söderhäll K. (2021). Immune properties of invertebrate phenoloxidases, *Developmental & Comparative Immunology*, 122, 104098.
- Charles, H. M. & Killian, K. A. (2015). Response of the insect immune system to three different immune challenges. *Journal of Insect Physiology*, 81, 97–108.
- Coates, C. J., & Söderhäll, K. (2021). The stress–immunity axis in shellfish. *Journal of Invertebrate Pathology*, 186, 1–14.
- Darwis. (2006). Kajian Parasit Pada Kepiting Bakau (*Scylla serrata*) Di Wilayah Perairan Bakau Tarakan Kalimantan Timur. [Disertasi]. Sekolah Pasca Sarjana. Universitas Gajah Mada. Hal: 50.
- Day, R. D., Fitzgibbon, Q. P., & Gardner, C. (2019). The impact of holding stressors on the immune function and haemolymph biochemistry of Southern Rock Lobsters (*Jasus edwardsii*). *Fish and Shellfish Immunology*, 89, 660–671.
- Djai, S., Supriyono, E., Nirmala, K., & Adiyana, K. (2017). Respons *Total Hemocyte Count* Dan Kadar Gukosa *Hemolymph* Lobster Pasir *Panulirus homarus* Terhadap Rasio *Shelter*. *Jurnal Ilmu dan Teknologi Kelautan Tropis*, 9(1), 125–133.
- Ekawati, A. W., Nursyam, H., Widjayanto, E., & Marsoedi. (2012). Diatomae *Chaetoceros ceratosporum* dalam Formula Pakan Meningkatkan Respon Imun Seluler Udang Windu (*Penaeus monodon* Fab.). *The Journal of Experimental Life Science*, 2(1), 20–28.
- Fikri, F., Wardhana, D. K., Purnomo, A., Khairani, S., Chhetri, S., & Purnama, M. T. E. (2022). Aerolysin gene characterization and antimicrobial resistance profile of *Aeromonas hydrophila* isolated from milkfish (*Chanos chanos*) in Gresik, Indonesia. *Veterinary World*, 15(7), 1759.
- Fikri, F., Purnomo, A., Chhetri, S., & Purnama, M. T. E. (2023). Sea Cucumber-Based Hydroxyapatite-Chitosan Ameliorate Serum Liver Enzymes and Cytokine Levels in Albino Rats with Femoral Bone Defect. *Indian Veterinary Journal*, 100(7), 23-26.
- Gunawan, A. H. (2022). Korelasi parameter kimia air, derajat infestasi dan gejala klinis ektoparasit pada lobster (*Panurilus* sp.) di keramba perairan laut Trenggalek dan Banyuwangi, Jawa Timur. [Skripsi]. Fakultas Perikanan dan Kelautan. Universitas Airlangga. Hal: 43–56.
- Haryanti, Sembiring, S. B. M., Sudewi, Widiastuti, Z., Giri, N. A., & Ketut, S. (2017). Respons Imunitas Benih Lobster, *Panulirus homarus* dengan Penggunaan Probiotik Pada Pakan Moist. *Jurnal Riset Akuakultur*, 12(1), 85–97.
- Hauton, C. (2012). The scope of the crustacean immune system for disease control. *Journal of Invertebrate Pathology*, 110(2), 251–260.
- Herlinawati, A., Sarjito, & Alfabetian, H. (2017). Infestasi *Octolasmis* pada kepiting bakau (*Scylla serrata*) hasil budidaya dari desa Surodadi, Kabupaten Demak, Jawa Tengah. *Journal of Aquaculture Management and Technology*, 6(4), 11–19.



- Hertika, A. M. S., Supriatna, Darmawan, A., Nugroho, B. A., Handoko, A. D., Qurniawatri, A. Y., & Ranita, A. P. (2021). Profil Hemosit Susuh Kura (*Sulcospira testudinaria*) dalam Rangka Mengevaluasi Kualitas Perairan Wilayah Konservasi Badher Bank, Desa Tawangrejo, Kecamatan Binangun, Kabupaten Blitar. *Journal of Fisheries and Marine Research*, 5(1), 106–118.
- Hidayah, N., Puspita, R., & Mujahidah, M. (2020). Effect of *Curcuma domestica* Val Extract on Body Weight, Total of Eosinofils and Basofils in Laying Hens Infected with *Salmonella pullorum*. *Jurnal Medik Veteriner*, 3(2), 230–235.
- Hisyam, M. A. M., Yuniarti, W. M., Theresia, S. W., Yudaniayanti, I. S., Lukiswanto, B. S., Sudjarwo, S. A., & Widiyatno, T. V. (2023). The Efficacy of Madeira Vine Leaf Extract Combined with Turmeric Rhizome Extract Gel Topically on Second-Degree Burn Wound in Albino Rats. *Jurnal Medik Veteriner*, 6(3), 402–409.
- Huang W., Zhang, J., Yang, B., Beerntsen, B.T., Song, H., & Ling E. (2016). DNA duplication is essential for the repair of gastrointestinal perforation in the insect midgut. *Scientific Reports*, 6(19142), 1–10.
- Huong, L. L., Thi, V. L., Thai, T. H., Jones, C., Sang, H. M., Kien, N. T., Bich, N. T. K., Kim, H. P. T., An, K. N., Trung, D. H., Huu, T. P., & Tan, H. D. (2014). Comparative assessment of manufactured pellet feed and traditional trash fish feed on production of tropical rock lobster (*Panulirus ornatus*) and environmental effects in sea-cage culture in Vietnam. *Proceedings of the International Lobster Aquaculture Symposium*, pp: 68–81.
- Jannah, M., Junaidi, M., Setyowati, D. N., & Azhar, F. (2018). Pengaruh Pemberian *Lactobacillus* sp. Dengan Dosis Yang Berbeda Terhadap Sistem Imun Udang Vaname (*Litopenaeus vannamei*) Yang Diinfeksi Bakteri *Vibrio parahaemolyticus*. *Jurnal Kelautan*, 11(2), 140–150.
- Joseph, F. R. S., & Ravichandran, S. (2012). Shell Diseases of Branchyuran Crabs. *Journal of Biological Sciences*, 12(3), 117–127.
- Kenconojati, H., Ulkhaq, M. F., Azhar, M. H., & Rukmana, N. R. (2023). Vibriocidal Activity of Ethanol Extract of Moringa Leaves and Its Effect on the Growth of Pacific White Shrimp. *Jurnal Medik Veterinar*, 6(1), 75–81.
- Lavilla-Pitogo, C. R., & De La Pena, L. D. (2004). Diseases in Farmed Mud Crabs *Scylla* spp.: Diagnosis, Prevention, and Control. Philippines: Aquaculture Department Southeast Asian Fisheries Development Center, pp: 46–48.
- Li, H. X., Ma, L. S., Yan, Y., Yang, C. P., & Lin, C. X. (2014). First Records Of The Epizoic Barnacle *Octolasmis rullata* (Cirripedia: Thoracica: Poecilasmatedae) On The Swimming Crab *Portunus sanguinolentus* (Decapoda: Portunidae). *Biology*, 34(1), 76–81.
- Liu, M. J., Liu, S., & Liu, H. P. (2021). Recent insights into hematopoiesis in crustaceans. *Fish and Shellfish Immunology Reports*, 2(100040), 1–10.
- Melillo, D., Marino, R., Italiani, P., & Boraschi, D. (2018). Innate Immune Memory in Invertebrate Metazoans: A Critical Appraisal. *Frontier in Immunology*, 9, 1915.
- Nur, Indriyani., & Yusnaini. (2016). Parasitic and Fungal Identification in Bamboo Lobster *Panulirus versicolour* and Ornate Lobster *P. ornatus* Cultures. *World Academy of Science, Engineering and Technology International Journal of Biotechnology and Bioengineering*, 14(12), 1.

- Nur, Indriyani, & Yusnaini. (2018). Parasites and histopathology of infected spiny lobster *Panulirus* spp. cultured in outer of Kendari Bay, Indonesia. *Aquaculture, Aquarium, Conservation & Legislation - International Journal of the Bioflux Society*, 11(1), 108–117.
- Petersen, E. H., Jones, C., & Priyambodo, B. (2014). Bioeconomics of Spiny Lobster Farming in Indonesia. *Asian Journal of Agriculture and Development*, 10(1), 25–39.
- Prastika, D. D., Setiawan, B., Saputro, A. L., Yudaniyanti, I. S., Wibawati, P. A., & Fikri, F. (2020). Effect of Shrimp Chitosan Topically on Collagen Density as Excision Wound Healing Parameter in Albino Rats. *Jurnal Medik Veteriner*, 3(1), 101–107.
- Prastowo, B. W., Penataseputro, T., & Evan, Y. (2022). Necrosis Incidence on The Tail Fin of Sand Lobster (*Panulirus homarus*) Reared Using Recirculating Aquaculture System (RAS). *11th International and National Seminar on Fisheries and Marine Science: IOP Conf. Series: Earth and Environmental Science*, 1118, 1–10.
- Ranjan, R., Muktha, M., Ghosh, S., Gopalakrishnan, A., Gopakumar, G., & Joseph, I. (Eds.). (2017). Prioritized Species for Mariculture in India. Kochi: ICAR-CMFRI, pp: 215–220.
- Rivaie, A. R., Adiputra, Y. T., Setyawan, A., & Putro, D. H. (2023). Effect of different diets on growth performance, a physiological response, and behavior of spiny lobster *Panulirus homarus* (Linnaeus, 1758). *Jurnal Kelautan Tropis*, 26(2), 301–314.
- Rokhmani, & Bambang, H. B. (2020). Diversitas Ektoparasit Pada Crustacea Hasil Tangkapan Estuaria Segara Anakan Cilacap Jawa Tengah. *Prosiding Seminar Nasional dan Call for Papers*, pp: 30–40.
- Rostika, R., Ihsan, Y. N., Supriadi, D., Permana, R., Purnama, M. I. C., & Nurfaizi, R. (2021). Control of Ectoparasites *Octolasmis* sp. in Young Lobsters (*Panulirus horamus*) using KMNO<sub>4</sub> and Herbal Liquid Containing Tamarind Eggplant. *International Conference on Fisheries and Aquaculture*, Sri Lanka, 19–20 August 2021, pp: 43–45.
- Safira, A., Rani, C. A. M., Puspitasari, R. A., Ayuningtyas, A. K. P., Mahendra, Y. A., Purnomo, A., Fikri, F., Chhetri, S., & Purnama, M. T. E. (2022). Amino Acid and Proximate Analysis of Type-1 Collagen from Sea Cucumber and Tilapia-Skin and its Potential Application as Artificial Tendon. *Pharmacognosy Journal*, 14(4).
- Safira, A., Rani, C. A. M., Fikri, F., Purnomo, A., Khairani, S., Chhetri, S., Maslamama, S. T., & Purnama, M. T. E. (2023). Hydroxyapatite-chitosan composites derived from sea cucumbers and shrimp shells ameliorate femoral bone defects in an albino rat model. *Veterinary World*, 16(5).
- Saptiani, G., Pebrianto, C. A., Hardi, E. H., & Agustina. (2016). Kerentanan Udag Windu (*Panaeus monodon*) Terhadap *Vibrio harveyi* pada Berbagai Stadia Molt dan Osmolaritas. *Jurnal Perikanan UGM*, 8(1), 19–25.
- Sarjito, Haditomo, A. H. C., Desrina, Ferinandika, F. B., Setyaningsih, L., & Prayitno, S. B. (2016). Ectoparasites and Vibrios Associated with Fattening Cultured Mud Crabs [*Scylla serrata* (Forsskal, 1775)] From Pemalang Coast, Indonesia. *Jurnal Sciences and Engineering*, 78(4), 207–214.
- Shields, J. D. (2011). Diseases of spiny lobsters: A review. *Journal of Invertebrate Pathology*, 106(1), 79–91.
- Silva-Inácio, L. M. da., Machado, G. B. de O., Fortuna, M. D., Sanches, F. H. C., & Costa, T. M. (2016). Infestation by the epibiont

- Octolasmis lowei in a portunid crab assemblage from a subtropical coast. *Nauplius*, 24, 1–8.
- Smith, V. J., Brown, J. H., & Hauton, C. (2003). Immunostimulation in crustaceans: does it really protect against infection?. *Fish & Shellfish Immunology*, 15(1), 71–90.
- Subhan, R. Y., Supriyono, E., Widanarni, & Daniel, D. (2018). Grow-out of spiny lobster *Panulirus* sp. with high stocking density in controlled tanks. *Jurnal Akuakultur Indonesia*, 17(1), 53–60.
- Sugumaran, M., & Barek, H. (2016). Critical Analysis of the Melanogenic Pathway in Insects and Higher Animals. *International Journal of Molecular Sciences*, 17(10), 1–24.
- Syahidah, D., & Owens, L. (2020). Histopathology Of Mixed Infections In Redclaw Crayfish (*Cherax quadricarinatus*) Tissues. *Journal of Fisheries and Marine Research*, 4(2), 207–213.
- Wahjuningrum, D., Effendi, I., Hadiroseyani, Y., Budiardi, T., Diatin, I., Setiawati, M., Hastuti, Y. P., Sudrajat, A. O., Yonvitner, Nuryati, S., & Utami, P. (2022). Health status of spiny lobster *Panulirus homarus* with sub-mersible net cage system in the different depths at kepulauan seribu, DKI Jakarta. *Jurnal Akuakultur Indonesia*, 21(1), 68–80.
- Wibowo, R. H., Darwis, W., Sipriyadi, Susianti, N., Purbianto, K. A., Gustriana, Rosianti, N., Medani, D. I., & Wulandari, G. D. (2021). Identification of Pathogenic Bacteria on Spiny Lobster (*Panulirus homarus*) at Quality Control and Fishery Product Safety Agency (BKIPM) of Bengkulu. *Advances in Biological Sciences Research*, 14, 493–499.
- Wu, J., Chen, H., & Huang, D. (2008). Histopathological and Biochemical Evidence of Hepatopancreatic Toxicity Caused Cadmium and Zinc in the White Shrimp, *Litopenaeus vannamei*. *Chemosphere*, 73(7), 1019–1026.
- Xian, J. Zhang X, Wang D, Li J, Zheng P, Lu Y. (2017). Various cellular responses of different shrimp haemocyte subpopulations to lipopolysaccharide stimulation. *Fish & Shellfish Immunology*, 69, 195–199.
- Yap, F. C., Chen, H. N., & Chan, B. K. K. (2023). Host specificity and adaptive evolution in settlement behaviour of coral-associated barnacle larvae (Cirripedia: Pyrgomatidae). *Scientific Reports*, 13(9668), 1–13.
- Yusgita, L., Kismiyati, Subekti, S., Wulansari, P. D., & Amiin, M. K. (2019). Identification and prevalence of the ectoparasite *Octolasmis* in sand lobster (*Panulirus homarus*) and bamboo lobster (*Panulirus versicolor*) in Floating Net Cages in Sape, Bima Regency, West Nusa Tenggara Province, Indonesia. *Proceeding IOP Conf. Series: Earth and Environmental Science* 236, 1–6.
- Zakwan, M., Sutriana, A., Nurliana, Ammar, M., & Novianti, A. N. (2023). Toxicity Test of Flavonoid Compounds from Ethyl Acetate Extract of Malacca Leaves with Brine Shrimp Lethality Test. *Jurnal Medik Veteriner*, 6(3), 15–19.
- Zheng, Z., Li, F., Li, H., Zhu, K., Xu, L., & Yang, F. (2021). Rapid regulation of hemocyte homeostasis in crayfish and its manipulation by viral infection. *Fish Shellfish Immunology Reports*, 2(100035), 1–9.

\*\*\*