

# The Efficacy of Madeira Vine Leaf Extract Combined with Turmeric Rhizome Extract Gel Topically on Second-Degree Burn Wound in Albino Rats

Mirza Atikah Madarina Hisyam<sup>1</sup>, Wiwik Misaco Yuniarti<sup>1\*</sup>,  
Sis Wisnuarti Theresia<sup>2</sup>, Ira Sari Yudaniayanti<sup>1</sup>,  
Bambang Sektiari Lukiswanto<sup>1</sup>, Sri Agus Sudjarwo<sup>3</sup>,  
Thomas Valentinus Widiyatno<sup>4</sup>

<sup>1</sup>Department of Veterinary Clinic, Faculty of Veterinary Medicine, Universitas Airlangga, Surabaya, Indonesia, <sup>2</sup>Bachelor Program of Veterinary Medicine, Faculty of Veterinary Medicine, Universitas Airlangga, Surabaya, Indonesia, <sup>3</sup>Department of Basic Veterinary Medicine, Faculty of Veterinary Medicine, Universitas Airlangga, Surabaya, Indonesia, <sup>4</sup>Department of Veterinary Pathology, Faculty of Veterinary Medicine, Universitas Airlangga, Surabaya, Indonesia.

\*Corresponding author: [wiwik-m-y@fkh.unair.ac.id](mailto:wiwik-m-y@fkh.unair.ac.id)

## Abstract

Burns is now considered one of the most destructive forms of trauma affecting humans and animals. This study aimed to determine the effect of Madeira vine leaf extract combined with 2% Turmeric rhizome extract (MVLTR) gel administered topically on second-degree burn wound in albino rats based on the number of fibroblasts. A total of 25 male rats weighed 200–300 grams were divided into five groups i.e. (C-) was normal skin, (C+) was burn and treated using 1% silver sulfadiazine, (T1) was burn and treated using 1.25% MVLTR gel, (T2) was burn and treated using 2.5% MVLTR gel, and (T3) was burn and treated using 5% MVLTR gel. The burn wound was performed on the right gluteus of rats, and the therapy was applied twice a day topically, starting after the burn wounds were made. Skin samples were collected on day 15. The histopathological examination was performed by counting fibroblast cells and then analyzed using One-way ANOVA, continued with the Duncan test. Based on the results showed that the C- group was significantly different compared to C+, T1, T2, and T3 groups. C+ had a significant difference with the T1 and T3 groups, meanwhile not significantly different from the T2 group. T2 was not significantly different from the C+ and T3 groups. In conclusion, MVLTR gel at 5% concentration has the potential to be an effective treatment for second-degree burns, as indicated by the increased number of fibroblasts.

Keywords: burn wound, health, Madeira vine leaf, turmeric rhizome

Received: 10 June 2023

Revised: 25 October 2023

Accepted: 27 November 2023

## INTRODUCTION

Burns is now considered one of the most destructive forms of trauma affecting humans and animals. According to the World Health Organization (WHO), Global Burden Disease estimates for 2017, just over 25:180.000 people died from burns, and more than 2.5 million people in America were wounded. There are various causes of thermal trauma, including fire, hot liquids, hot solids, radiation, chemicals, and electricity. In general, the most common cases of burn wounds come from hot liquids and flame burns (Jeschke *et al.*, 2020).

Traditional herbal medicine always becomes an interesting answer when it comes to finding

new alternatives to chemical medicine. The WHO has recently defined traditional herbal medicine as one of the therapeutic practices that have been in existence. Some of the herbal products have been tested and showed moderate efficacy with no toxicity (Prastika *et al.*, 2020;). Herbal plants and herbs have been widely used in wound healing of burned injuries (Karimi *et al.*, 2013). Herbal plants and herbs usually have saponins, flavonoids, tannins, and alkaloids as active substances to help the healing process (Astuti *et al.*, 2011). One of the herbal herbs that have been reviewed to help speed up the wound healing process is Turmeric. Turmeric has been used as a spice, in medicine, and for coloring and flavoring food since ancient times in Asian countries. In



previous studies have found a natural product that is believed to be the key substance from Turmeric, and it comes from the rhizomes. It is known as Curcumin (Sasidharan *et al.*, 2010; Hewlings and Kalman, 2017; Xu *et al.*, 2018).

Various studies have also shown that Curcumin's application on wounds enhances epithelial regeneration and increases fibroblast proliferation and vascular density (Sidhu *et al.*, 1998; Thangapazham *et al.*, 2013). Despite its reported benefits, one of the major problems with using Curcumin by itself is its poor bioavailability, water solubility, and instability, which greatly limited its further applications (Anand *et al.*, 2007; Li *et al.*, 2012). Traditional herbal medicine will be easier to use with the gel base because it has a high level of water. Gel bases have a shorter deployment time, preventing wound infection. Both Madeira vine leaves and Turmeric's rhizome present substances that can speed up the wound healing process. However, Madeira vine leaf is more commonly used in burn treatment and Turmeric rhizome is more common to be used in wound treatment. This study aimed to evaluate the effect of application gel of Madeira vine leaf (*Anredera cordifolia* (Ten.) *steenis*) extract combined with Turmeric rhizome (*Curcuma longa*) extract (MVLTR) on the number of fibroblasts as one of the wound healing factors on second-degree burn wound.

## MATERIALS AND METHODS

### Ethical Approval

This study was approved by the Universitas Airlangga Animal Care and Use Committee (ACUC) No 2.KE.026.02.2019.

### Study Period and Location

This study was conducted from October 2018 to January 2019 in the Faculty of Veterinary Medicine, Universitas Airlangga. The histological preparation was conducted in the Laboratory of Pathology.

### Extract Procedure

Madreia Vine leaf and Turmeric rhizome that had been obtained from Dukuh Kupang

village, Dukuh Pakis Sub-district, Surabaya City, were washed, drained, cut into small pieces, and then dried by aerating and carried in an oven with a temperature of 40°C until dry. The dried Madeira Vine leaves, and Turmeric rhizome was grind until they become powder. The powder was then macerated and evaporated using a Rotary evaporator to produce a gel of MVLTR.

### Animals

The animals in this study experiment were albino rats, Wistar strain, weighed 200–300 gram and in healthy condition. The minimum number for each treatment group was five replications. A total of 25 rats used in this study experiment i.e. (C-) was normal skin, (C+) was burn and treated using 1% silver sulfadiazine, (T1) was burn and treated using 1.25% MVLTR gel, (T2) was burn and treated using 2.5% MVLTR gel, and (T3) was burn and treated using 5% MVLTR gel.

The rats were anesthetized using the combined Ketamine and Xylazine (100 mg/kg BW and 5 mg/kg BW) with intramuscular injection. The gluteal dexter of rats was shaved and smeared with Alcohol 70%. Then, the modified thermostat was heated first until it reached 85°C for around 15 minutes. After that, the modified thermostat to the shaved area for 5 seconds with a vertical position to form a deep second-degree burn wound.

After 14 days of treatment, experiment animals were sacrificed with an overdose anesthetic on the next day, Ketamine 90 mg/kg combined with Xylazine 10 mg/kg intraperitoneally was used as the anesthetic as they were known to have no vital functions depressed (Zandieh *et al.*, 2003), and the burn areas of the skin were removed for histological studies. The sample size was 1 cm x 1 cm and stored into 10% formalin before being made into histological preparations.

The histological skin slide was stained with HE. The histological skin slide was seen with the microscope at 100x magnification at first to confirm the healing point area, then five fields of view of the skin histological slide were seen using a microscope at 400x magnification and an Optilab. The number of fibroblasts was counted

from five fields of view per treatment groups per repetitions using the Image Raster application. The data showed an average number of fibroblasts in each treatment groups.

### Data Analysis

The average data of fibroblast number for each treatment was analyzed using the Statistic Product Service Solution (SPSS) 20.0 program with ANOVA and the Duncan method to evaluate the significant value between treatments with the significant differences value  $p < 0.05$  (Bewick *et al.*, 2004).

## RESULTS AND DISCUSSION

Based on result, it can be reported that C- was significantly different ( $p < 0.05$ ) from C+, T1, T2, and T3 groups. C+ was significantly different ( $p < 0.05$ ) from T1 and T3 groups and not significantly different ( $p > 0.05$ ) from T2 group. Meanwhile, T2 was not significantly different ( $p > 0.05$ ) from C+ and T3 groups (Table 1).

This results indicate, in healthy skin, fibroblast is not needed because the collagen is already mature and strong, and no damage stimulates the activation of fibroblast. In T1 group showed the second low number of fibroblasts. This might be caused by the amount of water in this ointment, which makes the wound's humidity too high and could not heal properly. Humidity is one of the conditions that affect the wound healing process (Figure 1).

Burn wounds can be classified in several ways, but mostly they're classified according to the depth and thickness of the damaged skin. There are first-degree burns, also known as epithelial burns, and second-degree burns, divided into two types, superficial second-degree burns and deep second-degree burns. Last is third-degree burns (Tiwari *et al.*, 2012). A second-degree burn is the most common burn wound case that happens in the general population (Church *et al.*, 2006).

Skin is the body's natural barrier to infection, so the healing process will start if it is damaged. Wound healing processes are inflammation,

proliferation, and remodeling of the tissue. Those processes are considered complex in burn injuries (Mehrabani *et al.*, 2015). One of the important components in the wound healing phase is fibroblast proliferation. Fibroblast proliferation will affect the formation of collagen, which is needed as the framework of new tissue (Yuniarti and Lukiswanto, 2017).

Burn wounds can happen anytime to anyone and any animal and should be treated in the right way when it happens. Wound care for burn wounds usually uses silver sulfadiazine (SSD) cream. SSD has been used clinically as a standard treatment for burns over the past three decades and works as a topical antimicrobial agent to prevent contamination from burns (McCauley, 1994).

The silver element of SSD was shown to be highly toxic to both keratinocytes and fibroblasts. The conventional anti-infective property of SSD can not provide the moisture to boost rapid wound healing (Homann *et al.*, 2007). These conditions triggered to discover a new treatment with fewer side effects, highly bioavailable, biodegradable, bio replaceable, and better efficacy (Al-Anshori *et al.*, 2023).

The C+ showed a moderate value of fibroblast. SSD has been used as the standard treatment for burns and is well-known as a useful antibacterial agent. SSD is known to cause black marks, and the silver element is highly toxic and could decrease the wound-healing process. However, the toxicity of silver has not been an issue in burn care that has received much attention. The result of this study has shown that C+ has a better effect on wound healing than T1 gel seen from the average number of fibroblasts found.

T2 and T3 were not significantly different from the data. Both of them showed a good sign of healing based on the fibroblast number and the preview of some collagen that started to mature (Figure 1). Based on the data, the average number of fibroblasts in T3 is higher than in T2, and it is the highest of all treatments. This study was conducted for 14 days of treatment, and based on the observation of the slide of the skin, it can be seen that this wound is in the proliferative phase.

One herbal plant that contains most of the active substances mentioned above is the Madeira vine, known as Binahong in Indonesia. This plant has been growing very well since a long time ago. In society, in Java, it is trusted as a miracle plant because this plant can be used as the treatment for various diseases besides wound healing, such as diabetes mellitus, hypertension, rheumatics, typhoid fever, tuberculosis, asthma and many more (Sucita *et al.*, 2019). However, its capability is still not well documented (Astuti *et al.*, 2011). The most part that has been used in scientific experiments is leaves (Rani *et al.*, 2022).

Madeira vine leaf contains active substances such as flavonoids, saponins, tannins, and alkaloids. Flavonoid has the potential as an antioxidant, antibacterial, and vasodilator activity, while saponin works to stimulate the formation of collagen by increasing the number of fibroblasts and also works as an antiseptic that can terminate or prevent the growth of microorganisms in the wound to avoid an infection (Cahya *et al.*, 2020; Lesmana *et al.*, 2023). Tannin and alkaloids have antioxidants and antimicrobial properties that prevent and keep the wound area from being contaminated, keeping the wound area from being damaged by free radicals and inhibiting the growth of pathogenic bacteria in the wound (Menke *et al.*, 2007).

Three phases in the wound healing process overlap but are also well-defined: inflammatory, proliferative, and remodeling (Enoch *et al.*, 2006). The inflammatory phase usually occurs for three days but burn wounds may suffer from the effect of the acute influx of inflammatory mediators and growth factors for a prolonged time. Burn wound management would involve reducing the extent of the inflammatory response to acute injury and regulating fibroblast and myofibroblast activity. The activity would reduce contracture without affecting wound healing and the strength of wound recovery period (Evers *et al.*, 2010).

The second phase is the proliferative phase which occurs from the third day until the third week. The final phase of the wound healing process is remodeling, which might last from six months to one year (Church *et al.*, 2006). The

proliferation phase is characterized by fibroblast migration, angiogenesis, synthesis, and deposition of fragments of ECM proteins such as collagen tissue and granulation tissue (Enoch *et al.*, 2006). Fibroblasts produce the new ECM to support cell ingrowth using collagen as the building block, thus making it the dominant cell of this phase. The remodeling phase involves collagen remodeling and scar tissue formation. Proliferative to remodeling phase are overlapping, which could make a large number of fibroblasts and some parts with almost-mature collagen seen in one field of view.

It can be seen that re-revitalization has been formed in all treatments. From the color and space between collagen in C-, it can be seen that the collagen is mature, the fibroblast is hard to find, and the number of fibroblasts is the lowest among the five treatments. In C+, the collagen is immature, and the number of fibroblasts is in third place among other treatments. In T1, the collagen is also immature, and the number of fibroblasts is in fourth place among other treatments. Collagen of T2 and T3 were starting to mature, and fibroblasts were easy to find. However, T2 has a lower number of fibroblasts than T3, and it made T3 the treatment group with the highest number of fibroblasts (Figure 1).

Madeira vine and Turmeric have been known to be used as traditional medicine to treat different kinds of diseases. This study showed that both of them also greatly affect the wound-healing process, especially in burn wounds. This is caused by the substances in them. Madeira vine leaf is known to have a high flavonoid compound that works as an antioxidant and antibacterial, saponin, tannin, and oleanolic acid. Flavonoid has direct roles as an antibiotic function and broad spectrum targets during wound healing (Hanafiah *et al.*, 2016).

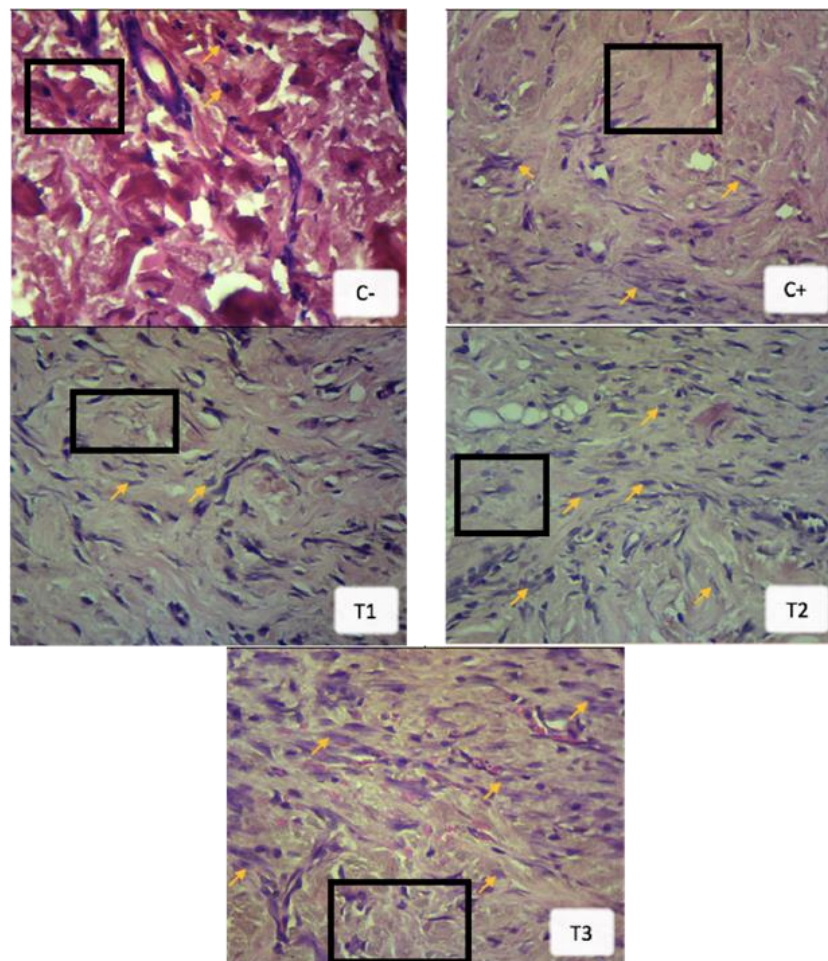
Saponin works as an anti-inflammatory and antimicrobial, such as antibacterial and anti-viral (Tagousop *et al.*, 2018). Saponin can speed up the wound-healing process by influencing fibroblast proliferation to stimulate collagen formation (Menke *et al.*, 2007). Tannin works as an antioxidant and antimicrobial and also functions as an astringent that can cause skin pores to shrink



**Table 1.** Fibroblast calculation in all treatment groups

Treatment	Fibroblast (Mean ± SD)
C-	11.44 <sup>a</sup> ± 1.84
C+	35.72 <sup>c</sup> ± 2.81
T1	27.56 <sup>b</sup> ± 3.73
T2	41.76 <sup>cd</sup> ± 6.18
T3	47.40 <sup>d</sup> ± 7.42

Different superscripts showed significant differences between treatments ( $p < 0.05$ ).



**Figure 1.** Histological change of rat skin in each treatments (HE, 400x magnification). (→) fibroblast cells; (black rectangle) collagen formation.

and stop exudates and mild bleeding, causing a wound to close and preventing bleeding on the wound (Ashok and Upadhyaya, 2012). The leaves also have oleanolic acid content, which has anti-inflammatory properties that could reduce pain in the burn.

On the other hand, Turmeric rhizomes have Curcumin as their principal ingredient, which is anti-inflammatory, antispasmodic, antimicrobial, anticancer, antioxidant, etc. Curcumin is also known to stimulate the production of TGF-β1,

which works in fibroblast proliferation in the wound healing process (Mani *et al.*, 2002; Shidu *et al.*, 1998).

The benefits of the MVLTR gel were not only producing good conditions for wound healing but there is also the possibility of accelerating the process of wound healing. Based on this study, it was known that T3 is the most effective treatment and optimal concentration. This study observes the wound healing process on one of its factors which was the fibroblast. The

results of this study also showed that MVLTR gel could potentially substitute SSD treatment as a treatment for burns because the MVLTR gel has similar results, especially in deep second-degree burns.

### CONCLUSION

Based on this study, it can be concluded that Madeira vine leaf extract combined with Turmeric rhizomes extract gel as a topical ointment for deep second-degree skin burns in rats can increase the number of fibroblasts with the highest result at 5% concentration.

### ACKNOWLEDGEMENTS

This study was supported by the Faculty of Veterinary Medicine, Universitas Airlangga.

### AUTHORS' CONTRIBUTIONS

WMY: Conceptualization and drafted the manuscript. MAMH, SWT, and ISY: Treated the animal laboratory. SAS and TVW: Performed sample evaluation. BSL: Validation, supervision, and formal analysis. SAS and WMY: Performed the statistical analysis and the preparation of table and figure. All authors have read, reviewed, and approved the final manuscript.

### COMPETING INTERESTS

The authors declare that they have no competing interests.

### REFERENCES

- Al-Anshori, A. A., Putri, A. N., Ismi, A. N., Suhud, M. K., Plumeriastuti, H., & Maslachah, L. (2023). Efficacy of Transdermal Delivery Nano Ethosomal Gel from Ashitaba Leaves on In-vivo Burn Wound Healing in Albino Rats. *Jurnal Medik Veteriner*, 6(2), 145–154.
- Anand, P., Kunnumakkara, A. B., Newman, R. A., & Aggarwal, B. B. (2007). Bioavailability of curcumin: problems and promises. *Molecular Pharmaceutics*, 4(6), 807–818.
- Ashok, P. K., & Upadhyaya, K. (2012). Tannins are astringent. *Journal of Pharmacognosy and Phytochemistry*, 1(3), 45–50.
- Astuti, S. M., Mimi, S. A. M., Retno, A. B. M., & Risch, A. (2011). Determination of saponin compound from *Andera cordifolia* (Ten.) Steenis plant (Binahong) to potential treatment for several diseases. *Journal of Agricultural Science*, 3(4), 224–232.
- Bewick, V., Cheek, L., & Ball, J. (2004). Statistics review 9: one-way analysis of variance. *Critical Care*, 8(2), 130–136.
- Cahya, R. W., Yudaniayanti, I. S., Wibawati, P. A., Yunita, M. N., Triakoso, N., & Saputro, A. L. (2020). The Effect of Sukun Leaf (*Artocarpus altilis*) Extract on Collagen Density of Excision Wound Healing in Albino Rats (*Rattus norvegicus*). *Jurnal Medik Veteriner*, 3(1), 25–30.
- Church, D., Elsayed, S., Reid, O., Winston, B., & Lindsay, R. (2006). Burn wound infections. *Clinical Microbiology Reviews*, 19(2), 403–434.
- Enoch, S., Grey, J. E., & Harding, K. G. (2006). Recent advances and emerging treatments. *BMJ: British Medical Journal*, 332(7547), 962–965.
- Evers, L. H., Bhavsar, D., & Mailänder, P. (2010). The biology of burn injury. *Experimental Dermatology*, 19(9), 777–783.
- Hanafiah, O. A., Hanafiah, D. S., Bayu, E. S., Abidin, T., Ilyas, S., Nainggolan, M., & Syamsudin, E. (2016). Quantity differences of secondary metabolites (saponina, tannins, and flavonoids) from binahong plant extract (*Anredera cordifolia* (Ten.) steenis) treated and untreated with colchicines that play a

- role in wound healing. *World Journal of Dentistry*, 8(9), 296–299
- Hewlings, S. J., & Kalman, D. S. (2017). Curcumin: a review of its effects on human health. *Foods*, 6(10), 92.
- Homann, H. H., Rosbach, O., Moll, W., Vogt, P. M., Germann, G., Hopp, M., Langer-Brauburger, B., Reimer, K., & Steinau, H. U. (2007). A liposome hydrogel with polyvinylpyrrolidone iodine in the local treatment of partial-thickness burn wounds. *Annals of Plastic Surgery*, 59(4), 423–427.
- Jeschke, M. G., van Baar, M. E., Choudhry, M. A., Chung, K. K., Gibran, N. S., & Logsetty, S. (2020). Burn injury. *Nature Reviews Disease Primers*, 6(1), 11.
- Karimi, M., Parsaei, P., Asadi, S. Y., Ezzati, S., Boroujeni, R. K., Zamiri, A., & Rafieian-Kopaei, M. (2013). Effects of *Camellia sinensis* ethanolic extract on histometric and histopathological healing process of burn wound in rat. *Middle-East Journal of Scientific Research*, 13(1), 14–19.
- Lesmana, M. A., Amri, I. A., Cahyanissa, A. R., Geoputri, K. M., Anisa, A. K., & Hardian, A. B. (2023). Efficacy of Oregano Extract Ointment on Fibroblast Cells and Epidermis in Albino Rats with Excisional Wound Model. *Jurnal Medik Veteriner*, 6(2), 262–270.
- Li, X., Chen, S., Zhang, B., Li, M., Diao, K., Zhang, Z., Li, J., Xu, Y., Wang, X., & Chen, H. (2012). In situ injectable nano-composite hydrogel composed of curcumin, N,O-carboxymethyl chitosan and oxidized alginate for wound healing application. *International Journal of Pharmaceutics*, 437(1–2), 110–119.
- Mani, H., Sidhu, G. S., Kumari, R., Gaddipati, J. P., Seth, P., & Maheshwari, R. K. (2002). Curcumin differentially regulates TGF-beta1, its receptors and nitric oxide synthase during impaired wound healing. *Biofactors*, 16(1–2), 29–43.
- McCauley, R. L., Li, Y. Y., Chopra, V., Herndon, D. N., & Robson, M. C. (1994). Cytoprotection of human dermal fibroblasts against silver sulfadiazine using recombinant growth factors. *Journal of Surgical Research*, 56(4), 378–384.
- Mehrabani, D., Farjam, M., Geramizadeh, B., Tanideh, N., Amini, M., & Panjehshahin, M. R. (2015). The healing effect of curcumin on burn wounds in rat. *World Journal of Plastic Surgery*, 4(1), 29–35.
- Menke, N. B., Ward, K. R., Witten, T. M., Bonchev, D. G., & Diegelmann, R. F. (2007). Impaired wound healing. *Clinics In Dermatology*, 25(1), 19–25.
- Prastika, D. D., Setiawan, B., Saputro, A. L., Yudaniayanti, I. S., Wibawati, P. A., & Fikri, F. (2020). Effect of Shrimp Chitosan Topically on Collagen Density as Excision Wound Healing Parameter in Albino Rats. *Jurnal Medik Veteriner*, 3(1), 101–107.
- Rani, C. A. M., Safira, A., Suryadiningrat, M., Fikri, F., Wardhana, D. K., & Purnama, M. T. E. (2022). Characterization of Tilapia collagen-loaded chitosan nanofibers synthesized by electrospinning method for wound dressing. *In IOP Conference Series: Earth and Environmental Science*, 1036(1), 012034.
- Sasidharan, S., Nilawaty, R., Xavier, R., Latha, L. Y., & Amala, R. (2010). Wound healing potential of *Elaeis guineensis Jacq* leaves in an infected albino rat model. *Molecules*, 15(5), 3186–3199.
- Sidhu, G. S., Singh, A. K., Thaloor, D., Banaudha, K. K., Patnaik, G. K., Srimal, R. C., & Maheshwari, R. K. (1998). Enhancement of wound healing by curcumin

- in animals. *Wound Repair and Regeneration*, 6(2), 167–177.
- Sucita, R. E., Hamid, I. S., Fikri, F., & Purnama, M. T. E. (2019). Secang Wood Ethanol Extract (*Caesalpinia sappan L.*) Topically Effective on Collagen Density During Wound Healing in Albino Rats. *Jurnal Medik Veteriner*, 2(2), 119–126.
- Tagousop, C. N., Tamokou, J. D., Kengne, I. C., Ngnokam, D., & Voutquenne-Nazabadioko, L. (2018). Antimicrobial activities of saponins from *Melanthera elliptica* and their synergistic effects with antibiotics against pathogenic phenotypes. *Chemistry Central Journal*, 12(1), 97.
- Thangapazham, R. L., Sharad, S., & Maheshwari, R. K. (2013). Skin regenerative potentials of curcumin. *Biofactors*, 39(1), 141–149.
- Tiwari, V. K. (2012). Burn wound: How it differs from other wounds? *Indian Journal of Plastic Surgery*, 45(2), 364–373.
- Xu, X. Y., Meng, X., Li, S., Gan, R. Y., Li, Y., & Li, H. B. (2018). Bioactivity, health benefits, and related molecular mechanisms of curcumin: current progress, challenges, and perspectives. *Nutrients*, 10(10), 1553.
- Yuniarti, W., M., & Lukiswanto, B. S. (2017). Effects of herbal ointment containing the leaf extracts of Madeira vine (*Anredera cordifolia (Ten.) Steenis*) for burn wound healing process on albino rats. *Veterinary World*, 10(7), 808–813.
- Zandieh, S., Hopf, R., Redl, H., & Schlag, M., G. (2003). The effect of ketamine/xylazine anesthesia on sensory and motor evoked potentials in the rat. *Spinal Cord*, 41(1), 16–22.

\*\*\*