

*Research Article***Differences of Bone Regeneration Using Bovine Hydroxyapatite and Bovine Hydroxyapatite with Freeze-Dried Platelet Rich Plasma Allograft in Bone Defect of Femoral White Rabbit**Mouli Edward<sup>1</sup> , Henry Dominica<sup>1</sup> , Ferdiansyah Mahyudin<sup>1</sup> , Fedik Abdul Rantam<sup>2</sup> <sup>1</sup>Department of Orthopedic and Traumatology, Faculty of Medicine, Universitas Airlangga/ Dr. Soetomo General Hospital, Surabaya, Indonesia<sup>2</sup>Department of Veterinary Microbiology, Faculty of Veterinary Medicine, Universitas Airlangga, Surabaya, Indonesia

Correspondence should be addressed to Ferdiansyah Mahyudin, Department of Orthopedic and Traumatology, Faculty of Medicine, Universitas Airlangga/ Dr. Soetomo General Hospital, Jl. Mayjend Prof. Dr. Moestopo 6-8, Surabaya 60286, Indonesia. e-mail: ferdiansyah@fk.unair.ac.id

**ABSTRACT**

**Background:** Hydroxyapatite is a bone graft that has osteoconductive properties for bone defects treatment. Platelet-rich plasma (PRP) has a capability of providing many bioactive molecules in physiological proportions. Hydroxyapatite given freeze-dried PRP is expected to create a graft that can strengthen the matrix while promoting osteoinduction. This study compares the effects of regeneration on the bone between bovine hydroxyapatite (BHA) and bovine hydroxyapatite with freeze-dried platelet-rich plasma (FD-PRP) as a bone graft in bone defect of the femoral white rabbit.

**Methods:** The 12 equal New Zealand white rabbits aged 6-9 months are divided into two groups. Bone defects were made in the lower femoral meta-diaphysis with a diameter of 2.5 mm. The defects were filled with BHA with FD-PRP allograft in the treatment group and BHA in the control group. Both groups will be sacrificed in the third and sixth weeks, then evaluated histologically for microvascular structure, osteoblasts, woven bone, type-I collagen, osteocalcin, alkaline phosphatase, and immunoglobulin G.

**Results:** During the evaluation in week 3 and 6, microvascular structure, osteoblast, and type-I collagen decreased in both groups with insignificant differences ( $p > 0.05$ ). Woven bone, osteocalcin, and immunoglobulin G increased in the treatment group but was not significant ( $p > 0.05$ ). Alkaline phosphatase increased higher in the treatment group, with a considerable difference in the sixth week ( $p = 0.008$ ).

**Conclusion:** The elevation in the production of woven bone, osteocalcin, and alkaline phosphatase at the third and sixth-week evaluations highlight the possibility that administering BHA given FD-PRP may have contributed to the healing of bone defects.

Keywords: Alkaline Phosphatase; Bone Graft; Bovine Hydroxyapatite; Freeze-Dried Platelet-Rich Plasma; Human and Medicine

**INTRODUCTION**

Bone defects due to trauma, tumors, congenital abnormalities, degeneration, and other illnesses are significant orthopedics problems. These conditions can cause non-union or delayed

healing events in 5 percent of all fractures and 20 percent of fractures with large force.<sup>1-3</sup> Management of these bone defects is a challenge and requires relatively high costs. One treatment that is often done is giving a bone graft. Around 4 million operations are

carried out using bone grafting or bone substitutes worldwide every year.<sup>1,4,5</sup>

Based on the source, a bone graft can be divided into three types: autogenous bone graft obtained from the patient's bones, allograft originating from other human donors, and the last xenograft originating from other species. The autogenous bone graft is the most ideal because it comes from oneself to minimize rejection from the patient's own body.<sup>6,7</sup> However, its disadvantages include pain at the donor site. They can cause local complications such as hematoma, fracture, and limited availability.<sup>6,8</sup> The second graft, the allograft, can be used instead of an autogenous bone graft and is now widely used. But in its application, allograft can increase the possibility of disease transmission, rejection reaction, non-union host-graft junction, graft resorption, fracture from allograft, and donor limitations.<sup>9,10</sup> Xenograft has the same function as allograft appears to be used as therapy, but it is feared that there will be many risks and complications caused by differences in the species.<sup>8,11,12</sup>

A new synthetic graft has been developed to deal with the issue. Several bioactive materials have been widely used as bone substitutes such as hydroxyapatite, bioglass, tricalcium phosphate, and  $\beta$ -wollastonite in the MgO-CaO-SiO<sub>2</sub> matrix.<sup>10</sup> The most commonly used bone-graft substitute is hydroxyapatite (HA) in granular and porous structural forms.<sup>1</sup> The unique property of HA material is its similarity to the bone mineral phase, causing osteoconductive ability and

biocompatibility is very good.<sup>13,14</sup> To improve their osteogenic potential, HA can be combined with other materials to resemble the mineral components and natural micro-bone structure. One of them by utilizing the advantages of the growth factor. Numerous growth factors, such as bone morphogenetic proteins (BMPs), platelet-derived growth factor (PDGF), transforming growth factor- $\beta$  (TGF- $\beta$ ), and insulin-like growth factors (IGF), have a stimulating effect on bone defect healing.<sup>15-17</sup>

Platelet-rich plasma (PRP) is defined as blood derivatives, where platelet concentrations are above the baseline level, contains a number of these growth factors [PDGF, TGF- $\beta$ 1, TGF- $\beta$ 2, IGF, epidermal growth factor (EGF), and epithelial cell growth factor (ECGF)] in its physiological proportions.<sup>18</sup> The osteogenic potential of PRP has been demonstrated by several in vitro studies, such as the addition of PRP in culture media that promotes proliferation. PRP can also increase cell chemokinesis and chemotaxis by reorganizing the cytoskeleton and accelerating cell migration, thereby affecting osteoblast mobility.<sup>19</sup>

PRP is generally isolated and applied on-site during surgery; however, it is time and labor-intensive, and it can be challenging to prepare adequate amounts. Yuya et al. suggest that freshly isolated PRP can be stored without functional loss by freeze-drying.<sup>20</sup> Based on Trio et al.'s research, it was found that the allogeneic freeze-dried PRP does not cause an inflammatory response compared to fresh PRP, so it is relatively safe to use.<sup>21</sup>



To our knowledge, there is little data on the effect of PRP on the healing of bone defects. We focused on bone-graft bovine hydroxyapatite with freeze-fried Platelet Rich Plasma (FD-PRP) allograft. We hypothesized that this composite graft could alter the microvascular structure, osteoblasts, woven bone, type-I collagen, osteocalcin, and alkaline phosphatase in bone regeneration without causing an inflammatory response from immunoglobulin G. In this study, we examined these *in vivo* properties for the purpose to determine bone regeneration in the administration of this composite graft to fill long bone defects.

## MATERIALS AND METHODS

### Research variable

This study uses experimental animals involving three variables: Independent variables; the type of graft used is bovine hydroxyapatite only. Control variable; rabbit breed, sex, age, weight, and health status. Dependent variable; microvascular structure, osteoblast, woven bone, levels of collagen type I (COL I), osteocalcin (OC), alkaline phosphatase (ALP), and immunoglobulin G histologically. The experimental animals used were New Zealand white rabbits, male gender, age 6 to 9 months, healthy without abnormality, weight 2.500 to 3.000 grams.

Examination of microvascular structure, osteoblast, and woven bone area carried out with hematoxylin-eosin staining

was assessed quantitatively by counting the microvascular structure and osteoblasts as the location of new bone formed. Collagen Type-1 (COL1), examined by immunohistochemical methods using *Monoclonal Collagen Type I alpha Antibody Mouse* (NB600-450-0.022ml; novusbio), then measured the thickness of type 1 collagen fibers using a calibrated micrometer. Inspections were carried out on all fields of view. Osteocalcin (OC) was examined using an immunohistochemical method using *Mouse Monoclonal anti-Osteocalcin antibody* (ABIN199514; antibodies-online GmbH) counted the number of osteoblast cells that were positive cells divided by total osteoblasts in the entire field of view. Alkaline phosphatase (ALP) was examined by an immunohistochemical method using *Mouse Monoclonal to Alkaline Phosphatase, Non-Specific Tissue* (TRA-2-49 / 6E; ab17973; Abcam), then counted the number of osteoblasts that were positive cells divided by total osteoblasts in the entire field of view. Immunoglobulin G (IgG) was examined by immunohistochemical methods using *Monoclonal Mouse [2A9] Anti-Rabbit IgG Heavy Chain* (ab99702; Abcam), then counted the number of osteoblast cells that were positive cells divided by total osteoblasts in the entire field of view. All of the experimental procedures were approved by the *Animal Care and Use Committee* (ACUC) Faculty of Veterinary Medicine, Universitas Airlangga, Surabaya - Indonesia (No: 2.KE.169.09.2018).



### **Synthesis hydroxyapatite from bovine bones (Bovine Hydroxyapatite – BHA)**

Bovine bone is cleaned chemically first then followed by the furnacing process to 1.000 °C so that all the bone's organic content evaporates. This process is carried out using the *Nabertherm P320 (Mb1)* furnace machine 30-3.000 °C.

BHA characterization was carried out to see the similarity of BHA's microstructure and composition compared to human bones. Characterization was carried out with a *JEOL JSM-T100 Scanning Microscope* to see porosity and microstructure and XRD (X-ray Diffractometer) *Bruker AXS Diffractometer* to see the hydroxyapatite composition.

### **PRP implantation to BHA**

Animal blood sampling is done through the same rabbit ear vein up to 12 cc and then transferred in a 15 ml falcon tube and centrifuged at 4.000 rpm for 10 minutes. The plasma obtained from the centrifugation was moved in another 15 ml falcon tube and centrifuged at 4.000 rpm for 10 minutes. The supernatant is removed, and the remaining  $\pm 1$  ml of PRP accumulates under the tube. The obtained PRP is dripped on the BHA block and then frozen for 24 hours at -83°C. BHA that has been soaked in PRP is processed by freeze-drying for 48 hours, then packaged and sterilized using gamma rays.

### **BHA and BHA-PRP implantation on experimental animals**

The procedure is carried out as follows. Rabbits are anesthetized first with the injection of *Ketamine* 20 mg/kg body weight intramuscularly and *Xylazine* 3 mg/kg body weight intramuscularly, then the hairs on the rear extremities are shaved. The incision is carried out layer by layer until it reaches the femur bone, then drilling in meta-diaphysis with a diameter of 2.5 mm and 2 mm deep (until it penetrates the medulla). In the treatment group, BHA-PRP composite graft was implanted, whereas in the control group was given BHA graft only. The surgical wound is sutured and dressed. The experimental animals during the study were put free to move in the cage.

### **Histopathological examination for microvascular structure, osteoblast, and woven bone**

Research specimens are derived from femur bone, cut proximal and distal with a graft located in the middle. Before conducting the examination, the process carried out consists of decalcification by immersing the research specimen in a saturated EDTA solution with a volume of 50 times the material. If there are air bubbles, it means the decalcification process is going well. The decalcification solution must be replaced every day for the process to run well. If the air bubbles are no longer visible, then the hard material may have become soft.



After the decalcification process is complete, continue with the processing of the ingredients. First, dehydration is done to withdraw water gradually using 10% formalin then 76% alcohol. Then purification is done to get a transparent specimen and replace the alcohol solution in the specimen using xylol. After finishing, the impregnation is done to equate the specimen with embedding material. Then the specimen is immersed in liquid paraffin for 4 hours. The next process is embedding to facilitate the stabbing with the microtome. This process is done by immersing the liquid paraffin specimen until the paraffin hardens. After the blending process is complete, the specimen is sliced with a microtome longitudinally, and then staining with hematoxylin-eosin (HE) is performed. Two experts carried out a histopathological examination.

#### **Immunohistochemical examination for Collagen Type-1, Osteocalcin, Alkaline Phosphatase, and Immunoglobulin G**

Examination using Mouse Monoclonal Collagen Type I alpha Antibody for type-I collagen, Mouse Monoclonal anti-Osteocalcin Antibody for osteocalcin, Mouse Monoclonal to Alkaline Phosphatase, Non-Specific Tissue for alkaline phosphatase, and Monoclonal Mouse [2A9] Anti-Rabbit IgG Heavy Chain (Mouse) HRP) for immunoglobulin G. Previously deparaffination was performed on histological preparations using xylol, absolute alcohol, 96% alcohol, and 70% alcohol. They

were then washed using PBS 2 times each for 3 minutes. Then do the incubation with a citrate buffer of 10 mM pH 6 in a microwave oven, then cool for approximately 20 minutes. Then washed again with PBS and incubation with trypsin 0.025% about 15 minutes at 37°C. Washing also was done with PBS and incubation with 3% H<sub>2</sub>O<sub>2</sub> for 10 minutes then washed again with PBS. After that, monoclonal antibodies will be used (COL-I / OC / ALP / IgG) for 30 minutes to 1 hour, then washed again with PBS and incubated with a secondary antibody for 30 minutes. Wash with PBS and incubated with streptavidin-HRP for 30 minutes. Washed with PBS and incubated with CAB-Chromogen (1:50) for 10 minutes. Washing again with PBS and Aquadest, then incubated with hematoxylin for 10 minutes. Finally washed with running water until it turns blue and then aerated until it dries and ends with the mounting entelen process. A histopathological examination was carried out by two experts.

#### **Statistical analysis**

Data analysis was performed with SPSS for Windows 15.0 (SPSS Inc., Chicago, IL, USA). Mean values and standard deviations were calculated. Differences between the two groups of the dependent variables were checked in the Paired T-Test or Wilcoxon test. Differences between two observation time in the same group of the dependent variables were checked in Independent T-Test or Mann-Whitney test. P



values  $<0.05$  were considered significant. All tests were two-tailed.

## RESULTS

In this study, 12 rabbits were used, divided into two groups (control and treatment groups), each with six animals. In the treatment group, bone defects were filled with bovine hydroxyapatite (BHA) with allograft freeze-dried Platelet Rich Plasma (FD-PRP). In the control group, bone defects were filled with BHA. Graft implantation was performed in both rear extremities to obtain a total of 24 samples.

From Figure 1(A), there is no statistically significant difference in the mean number of microvascular structures between groups in the third week ( $p = 0.412$ ; Independent T-Test) and the sixth week ( $p = 0.268$ ; Mann-Whitney). The microvascular structure was higher in the control group and the treatment group in the third week and decreased in the sixth week with the BHA group's highest number. The decrease in the number of microvascular structures in both groups was not statistically significant ( $p = 0.300$ ; Paired T-Test) ( $p = 0.343$ ; Wilcoxon).

From Figure 1(B), there is no statistically significant difference in the mean number of osteoblasts between groups in the third week ( $p = 0.903$ ; Independent T-Test) and sixth week ( $p = 0.776$ ; Independent T-Test). The number of osteoblasts was higher in the control and treatment groups in the third week and decreased in the sixth week with the highest

number found in the control group. The decrease in the number of osteoblasts in both groups was not statistically significant ( $p = 0.229$ ; Paired T-Test) ( $p = 0.318$ ; Paired T-Test).

From Figure 1(C), there is no statistically significant difference in the mean area of woven bone between groups in the third week ( $p = 0.973$ ; Independent T-Test) and sixth week ( $p = 0.947$ ; Independent T-Test). It is found that the woven bone area is lower in the control group and the treatment group in the third week and has increased in the sixth week with the highest number found in the control group. The increased woven bone area in both groups was not statistically significant ( $p = 0.102$ ; Paired T-Test) ( $p = 0.976$ ; Paired T-Test).

From Figure 1(D), there is no statistically significant difference in the mean number of Collagen Type-I between groups in the third week ( $p = 0.421$ ; Independent T-Test) and sixth week ( $p = 0.523$ ; Independent T-Test). It is found that the number of Collagen Type-I was higher in the control group and treatment group in the third week and decreased in the sixth week with the highest number found in the treatment group. The decrease in the number of Collagen Type-I in both groups was not statistically significant ( $p = 0.733$ ; Paired T-Test) ( $p = 0.940$ ; Paired T-Test).

From Figure 1(E), there is no statistically significant difference in the mean number of osteocalcin between groups in the third week ( $p = 0.140$ ; Mann-Whitney) and the



sixth week ( $p = 0.370$ ; Independent T-Test). It was found that the number of osteocalcins was higher in the control group and treatment group in the third week and increased in the sixth week with the highest number found in the treatment group. The increase in the number of osteocalcins in both groups was not statistically significant ( $p = 0.649$ ; Paired T-Test) ( $p = 0.327$ ; Paired T-Test).

Figure 1(F) shows no statistically significant difference in the mean number of alkaline phosphatase between groups in the third week ( $p = 0.628$ ; Mann-Whitney). There was a statistically significant difference in the mean number of alkali phosphatase between groups in the sixth week ( $p = 0.008$ ; Independent T-Test). It is found that the amount of alkali phosphatase is lower in the control group and the treatment group in the third week and has increased in the sixth week with the highest number found in the treatment group. The increase in the amount of alkali phosphatase in both groups was not statistically significant ( $p = 0.662$ ; Paired T-Test) ( $p = 0.075$ ; Wilcoxon).

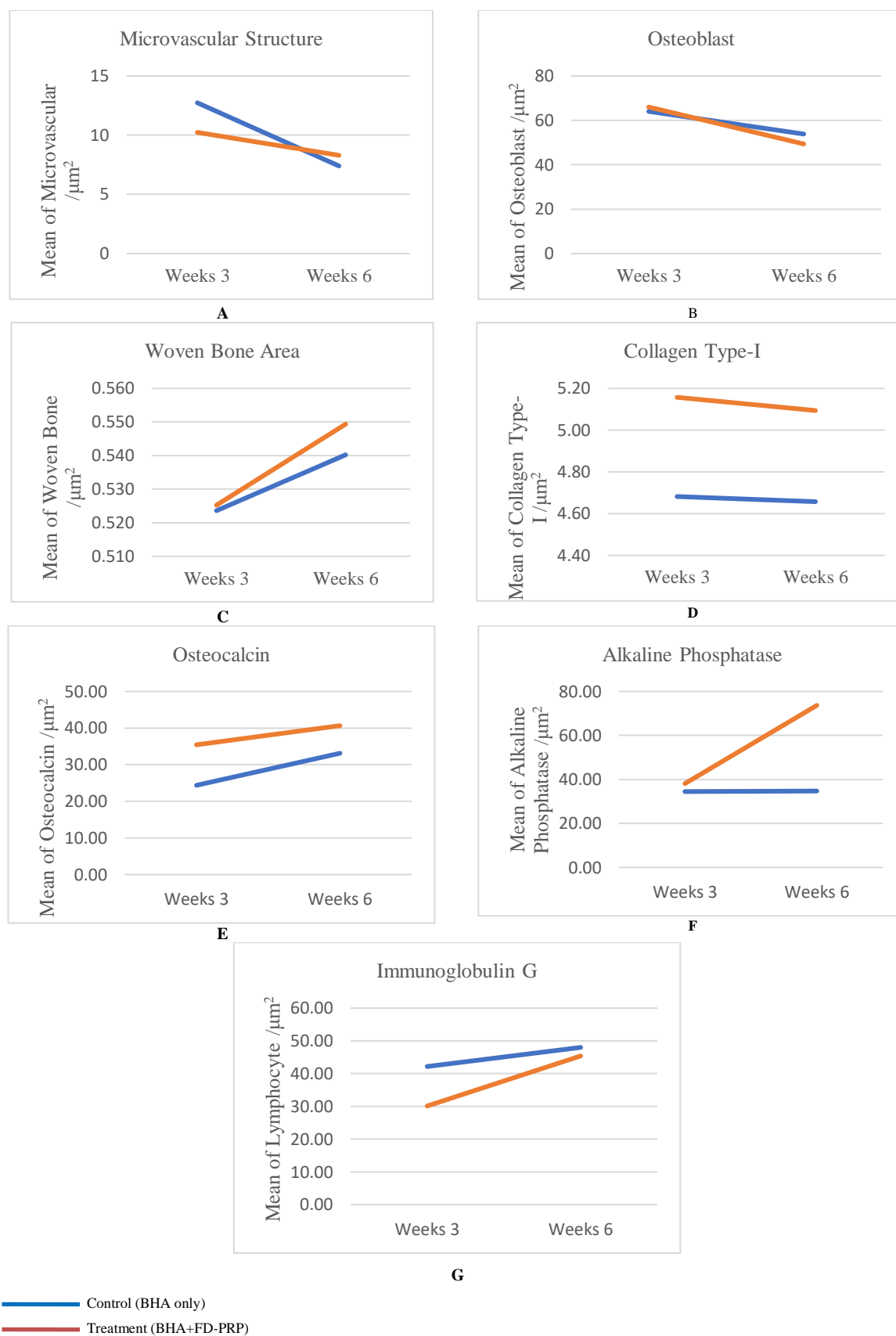
From Figure 1(G), there was no statistically significant difference in the mean number of immunoglobulin G between groups in the third week ( $p = 0.075$ ; Independent T-Test) and sixth week ( $p = 0.409$ ; Mann-Whitney). The

number of immunoglobulin G was lower in the control and treatment groups during the third week and increased in the sixth week with the highest number found in the control group. The increase in the number of immunoglobulin G in both groups was not statistically significant ( $p = 0.500$ ; Wilcoxon) ( $p = 0.066$ ; Paired T-Test).

In the third week, as shown in Figure 2, osteoblasts are seen in large numbers (orange arrows). Microvascular structure (blue arrow) and woven bone (green arrow) have formed quite broadly. In the sixth week, fibrous tissue and woven bone appear to be broader, as shown in Figure 3.

As shown in Figure 4, the collagen fibers' picture around the osteoblast is brown (indicated by a marker). The thickness of the collagen is measured by a calibrated micrometer. In Figure 5, images of osteoblasts that produce osteocalcin will turn brown (red arrows), and those that do not produce osteocalcin will turn purple (light blue arrows). In Figure 6, images of osteoblasts that produce alkaline phosphatase will turn brown (red arrows). Figure 7 shows pictures of the lymphocyte that produce it (red arrows) and those that do not (light blue arrows). As shown in Figure 8 and Figure 9, that show osteoblasts (orange arrows)





**Figure 1.** Graphs are comparing total microvascular structure (A), osteoblasts (B), woven bone area (C) collagen type-I (D), osteocalcin (E), alkaline phosphatase (F), and immunoglobulin-G (G) per micrometer<sup>2</sup> ( $\mu\text{m}^2$ ) of the field of view between control (BHA only; blue line) and treatment groups (BHA + FD-PRP; line red) at the third and sixth-week evaluation.



**Table 1.** Comparison between control (BHA only) and treatment groups (BHA+PRP) at the third and sixth-week evaluation.

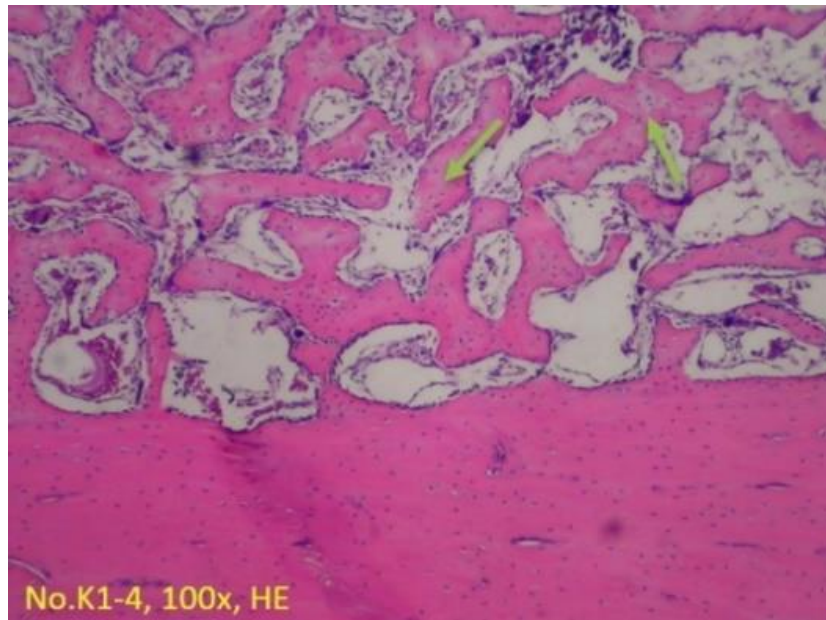
	Week	BHA	BHA+PRP	p
<b>Microvascular Structure</b>	Week 3	12,67 ± 6,65	10,17 ± 1,94	0,412
	Week 6	7,83 ± 4,11	8,33 ± 3,20	0,268
	p	0,300	0,343	
<b>Osteoblast</b>	Week 3	64,33 ± 24,41	65,83 ± 16,42	0,903
	Week 6	52,17 ± 16,43	40,33 ± 34,01	0,776
	p	0,229	0,318	
<b>Woven Bone Area</b>	Week 3	0,52 ± 0,09	0,52 ± 0,05	0,973
	Week 6	0,54 ± 0,08	0,55 ± 0,28	0,947
	p	0,102	0,976	
<b>Collagen Type-I</b>	Week 3	4,68 ± 1,17	5,16 ± 0,73	0,421
	Week 6	4,65 ± 0,69	5,09 ± 1,3	0,523
	p	0,733	0,940	
<b>Osteocalcin</b>	Week 3	24,39 ± 16,31	35,44 ± 4,21	0,140
	Week 6	33,13 ± 13,09	40,67 ± 12,51	0,370
	p	0,649	0,327	
<b>Alkaline Phosphatase</b>	Week 3	34,50 ± 7,10	38,11 ± 22,62	0,628
	Week 6	34,73 ± 7,03	73,67 ± 24,83	0,008
	p	0,662	0,075	
<b>Immunoglobulin G</b>	Week 3	42,17 ± 11,48	30,11 ± 9,61	0,075
	Week 6	48,00 ± 4,22	53,39 ± 11,15	0,409
	p	0,500	0,066	

tissue and woven bone (green arrows) appear to be broader than the third week.

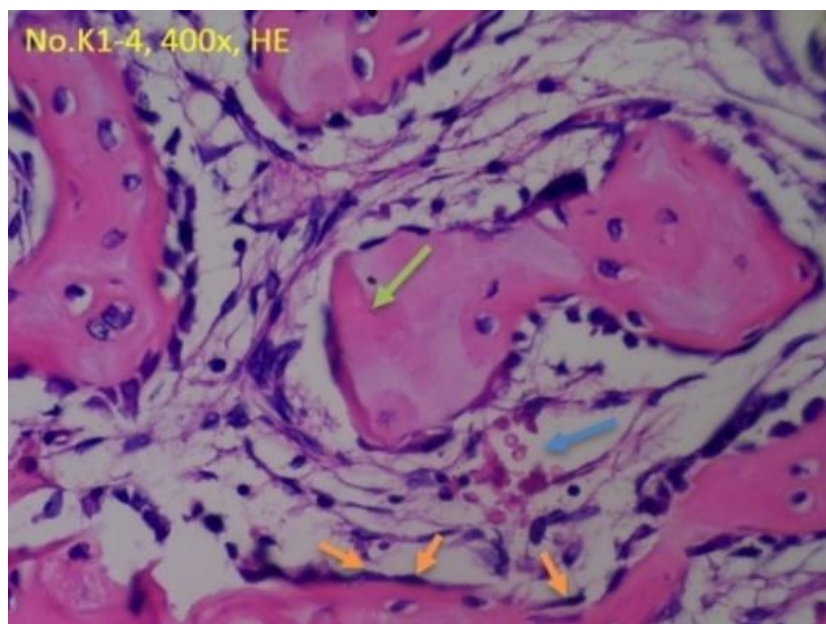
As shown in Figure 10, the collagen fibers' picture around the osteoblast is brown (indicated by a marker). In Figure 11, images of osteoblasts that produce osteocalcin will turn

brown (red arrows). In Figure 12, images of osteoblasts that produce osteocalcin will turn brown (red arrows). Figure 13 shows pictures of the lymphocyte that produce immunoglobulin G (red arrows), and those that do not produce it will turn purple (light blue arrows).



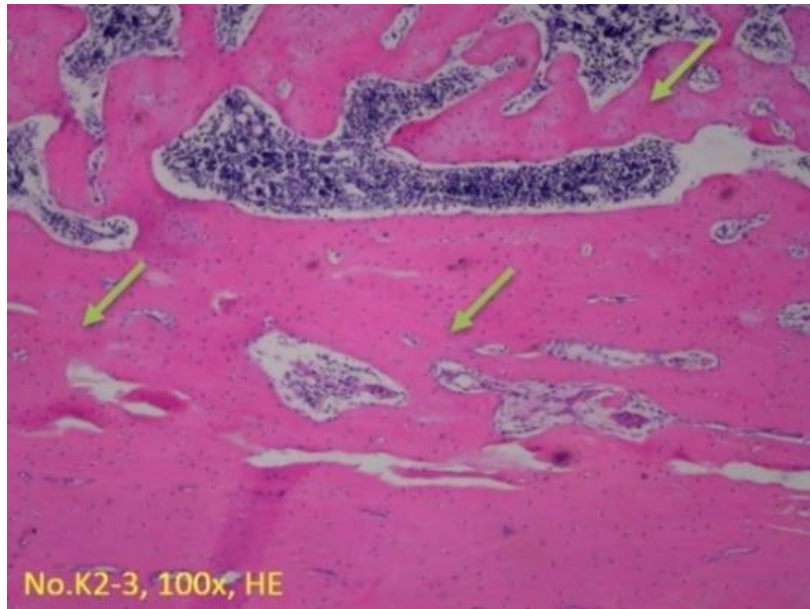


(a1)

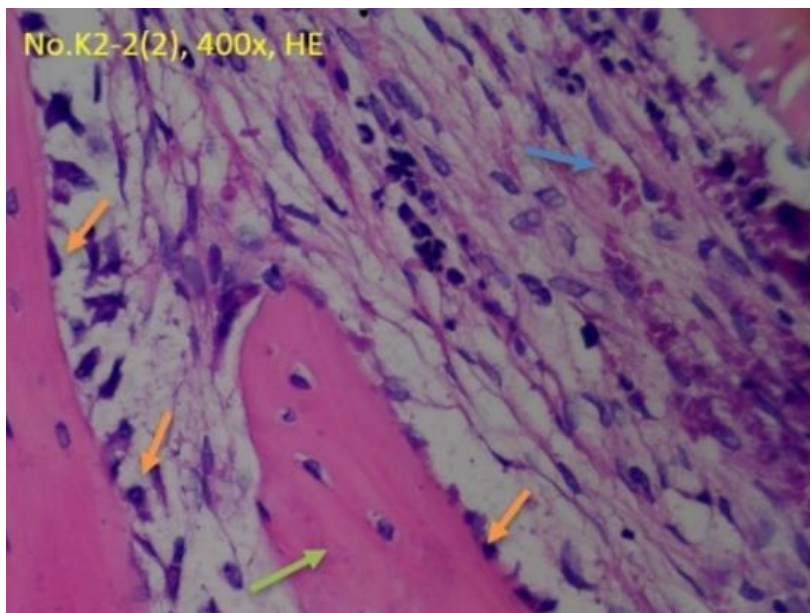


(a2)

**Figure 2.** Histology images of the control group at the third (a1-2).

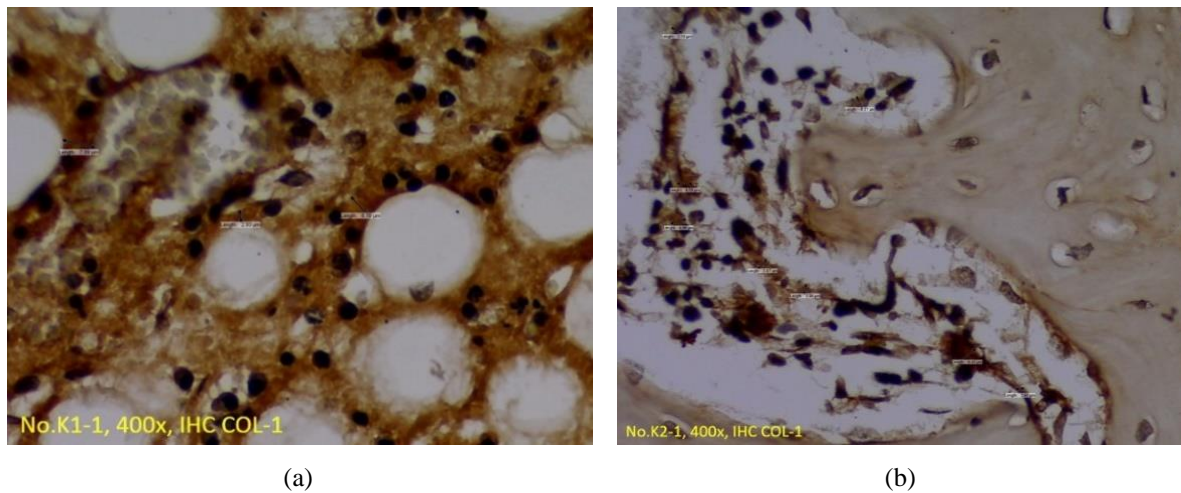


(b1)

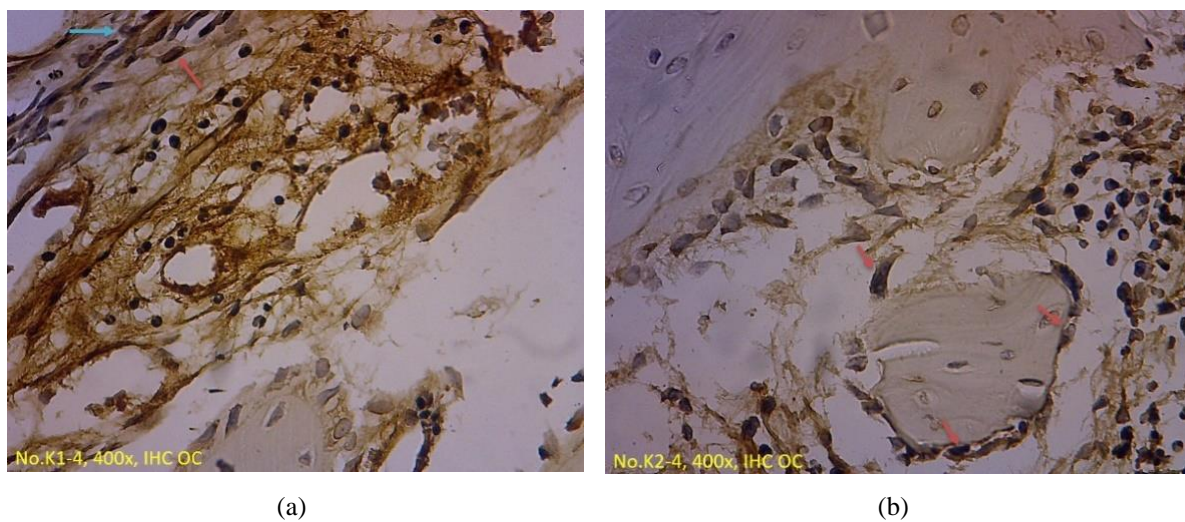


(b2)

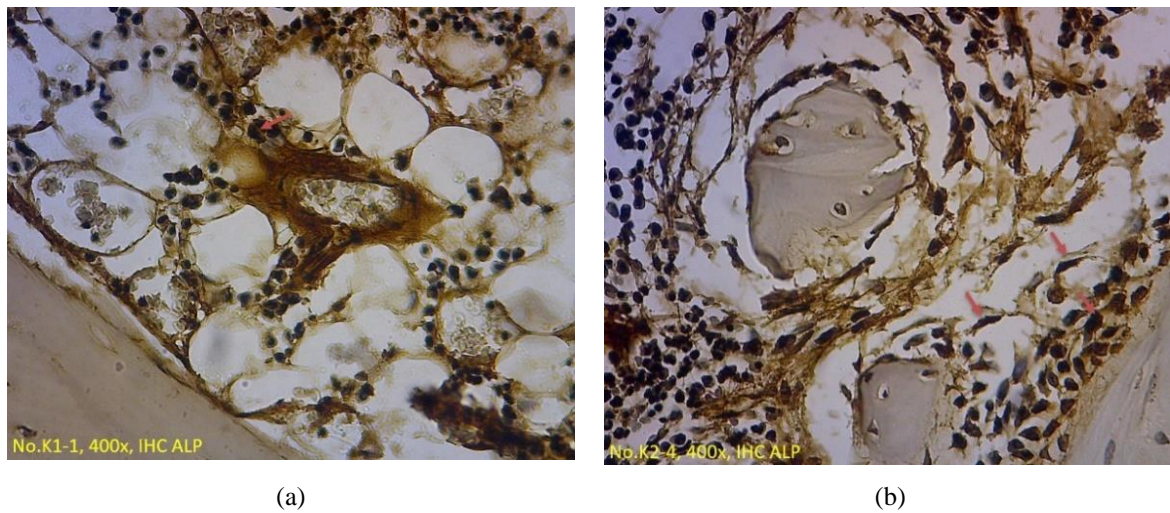
**Figure 3.** Sixth-week evaluations (b1-2) with hematoxylin-eosin (HE) staining.



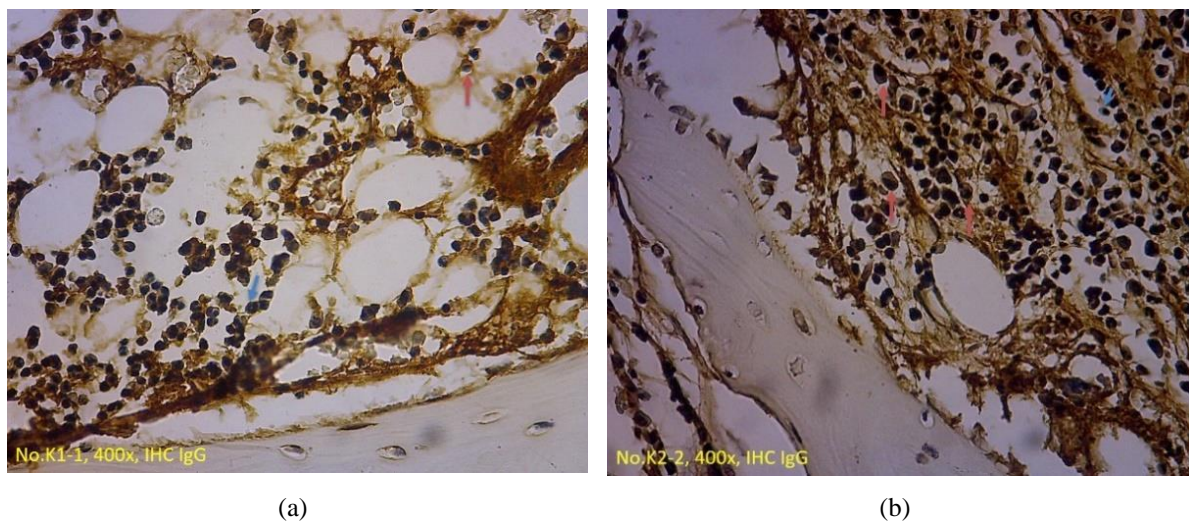
**Figure 4.** Histology images of the control group at the third (a) and sixth week (b) evaluations with immunohistochemical staining for Collagen Type-I



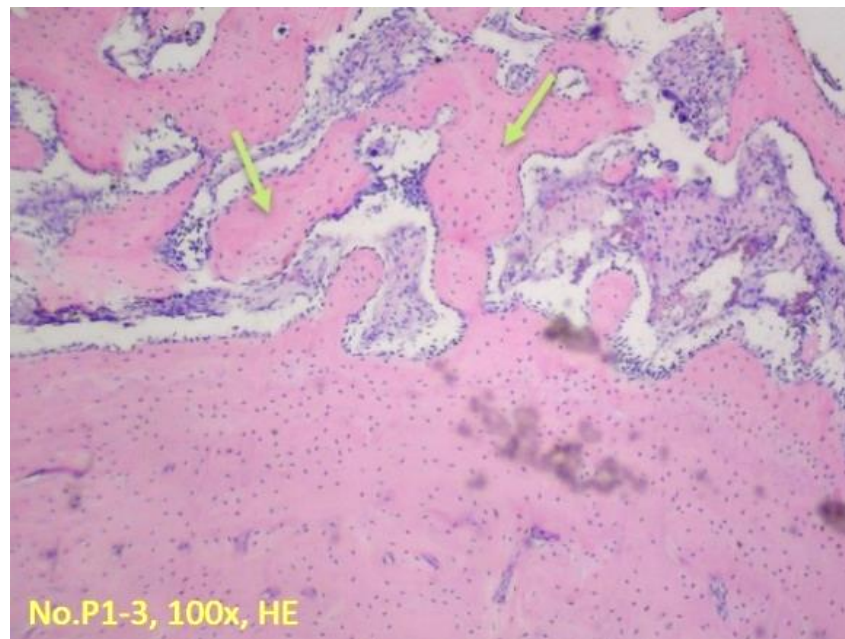
**Figure 5.** Histology images of the control group at the third (a) and sixth week (b) evaluations with immunohistochemical staining for osteocalcin



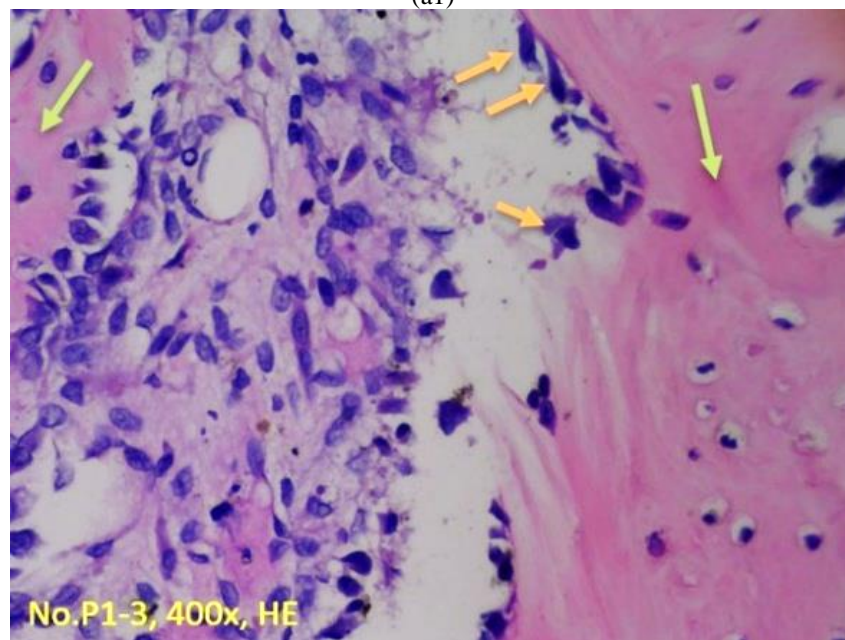
**Figure 6.** Histology images of the control group at the third (a) and sixth week (b) evaluations with immunohistochemical staining for alkaline phosphatase.



**Figure 7.** Histology images of the control group at the third (a) and sixth week (b) evaluations with immunohistochemical staining for Immunoglobulin G.

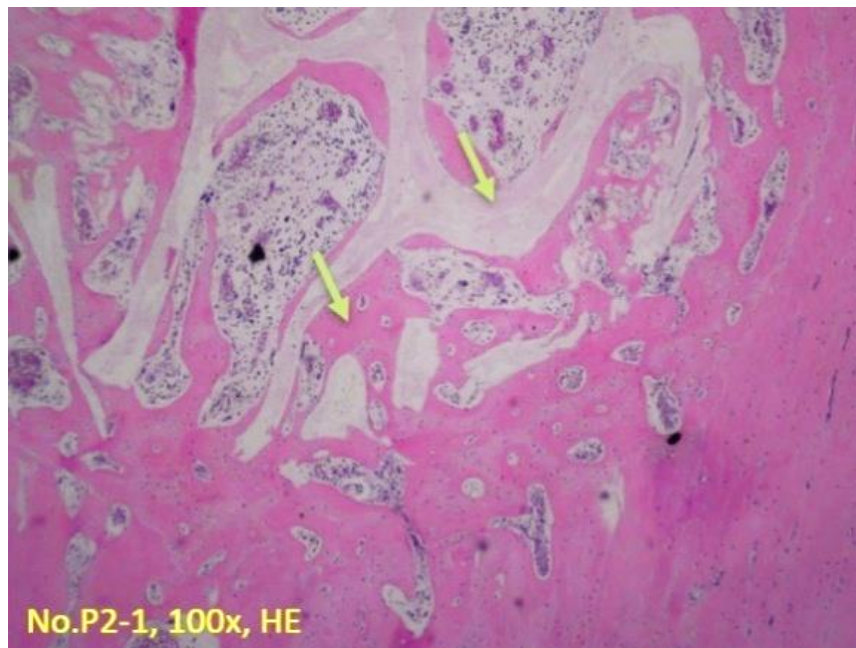


(a1)

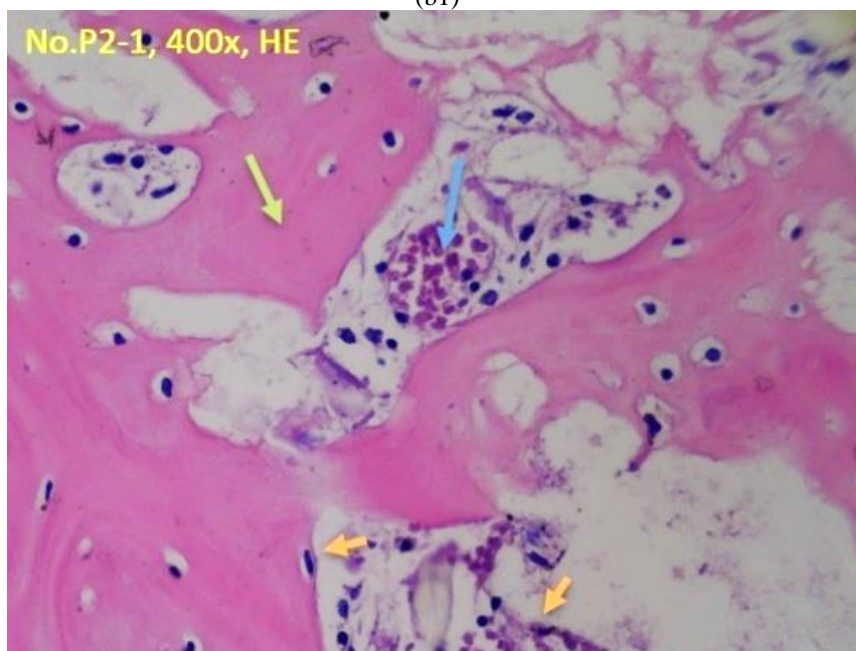


(a2)

**Figure 8.** Histology images of the treatment group at the third (a1-2)

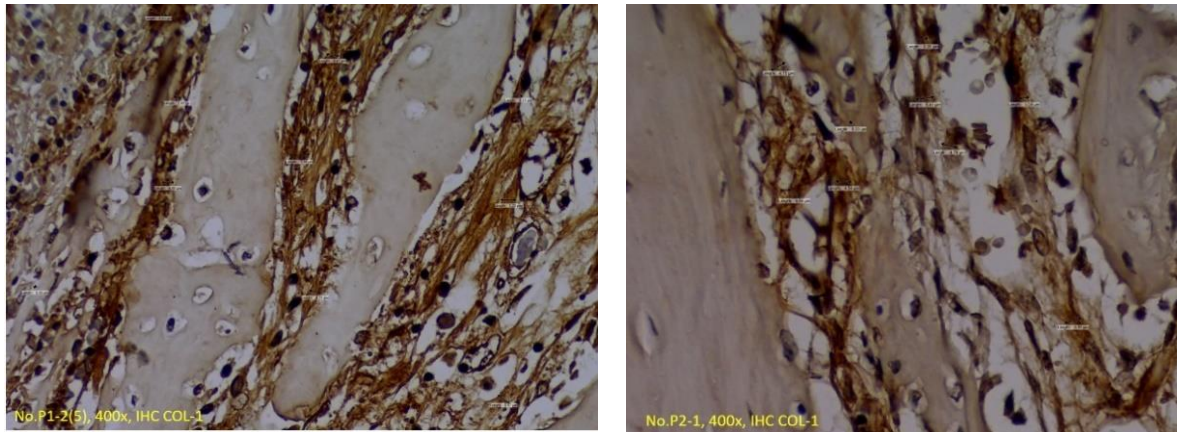


(b1)



(b2)

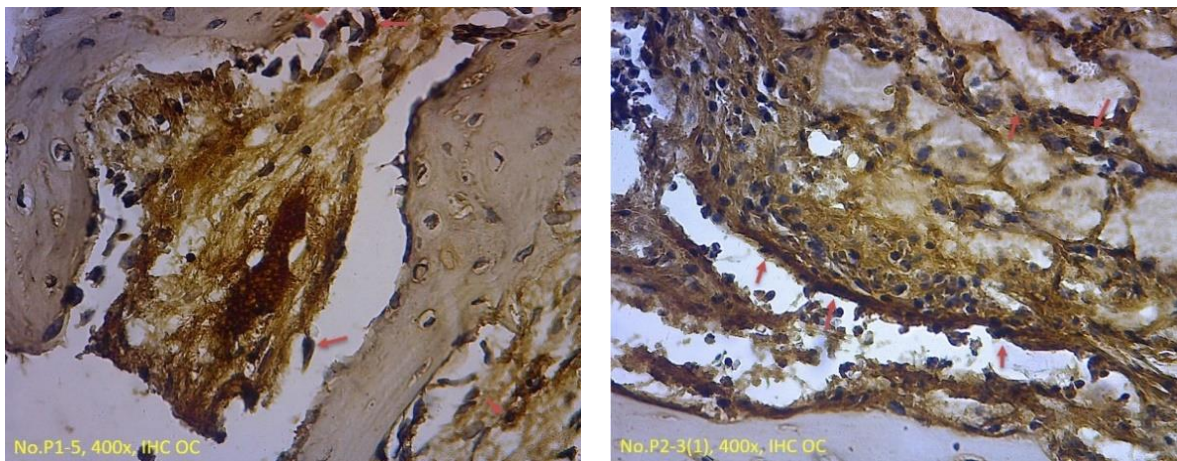
**Figure 9.** Sixth-week evaluations (b1-2) with hematoxylin-eosin (HE) staining.



(a)

(b)

**Figure 10.** Histology images of the treatment group at the third (a) and sixth week (b) evaluations with immunohistochemical staining for *Collagen Type-I*

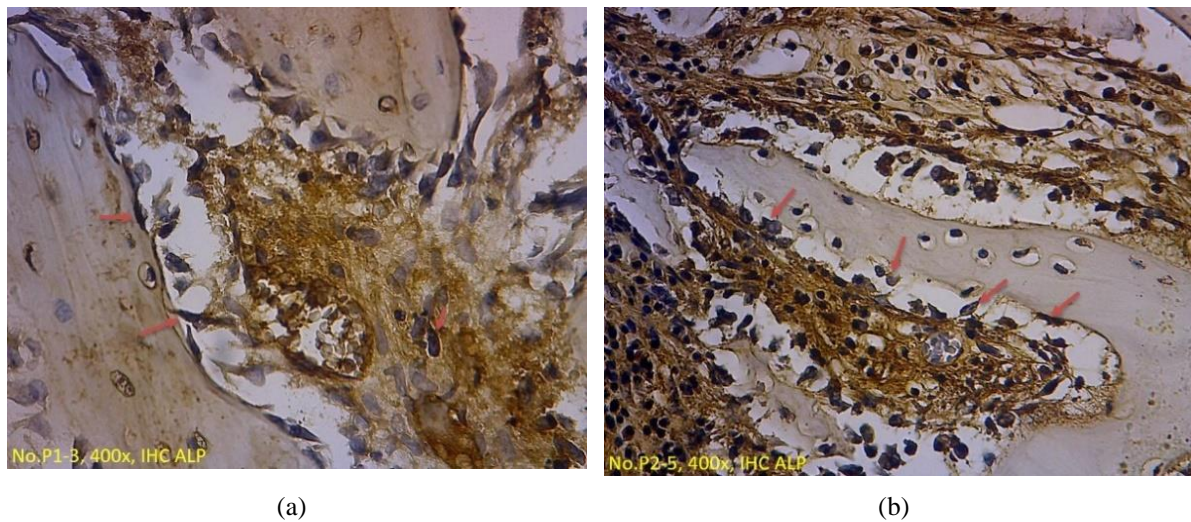


(a)

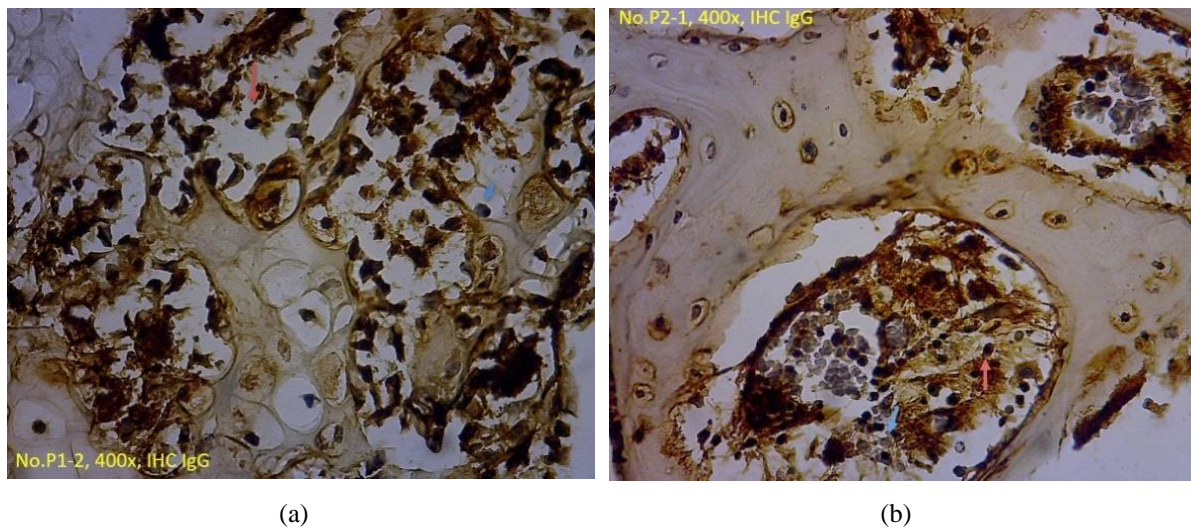
(b)

**Figure 11.** Histology images of the control group at the third (a) and sixth week (b) evaluations with immunohistochemical staining for *osteocalcin*.





**Figure 12.** Histology images of the treatment group at the third (a) and sixth week (b) evaluations with immunohistochemical staining for alkaline phosphatase.



**Figure 13.** Histology images of the control group at the third (a) and sixth week (b) evaluations with immunohistochemical staining for Immunoglobulin G.

## DISCUSSION

In the third week of microvascular structure evaluation, the number of microvascular structures in the control group was more than the treatment group, although it was not significant. At the sixth-week evaluation, there was a non-significant decrease in microvascular structure in both groups. Based on studies conducted by Winet, it is mentioned that

vascular invasion occurs on the 15th day or between the second and third weeks of the human periosteum.<sup>20</sup> One important step in using a bone graft is the formation of angiogenesis as quickly as possible and taking place during the long-term ossification process. Angiogenesis that occurs as early as possible is not expected to happen in a short time but needs to be maintained in the long run. PRP is thought to be able to maintain the angiogenesis process

that occurs quickly. Besides, microvascular formation in the treatment group should occur as early as possible because PRP contains Vascular Growth Factor (VGF), Vascular endothelial growth factor (VEGF), which has angiogenic factors that can accelerate and expand the formation of new bone in broad bone defects.<sup>21</sup>

In the third week of osteoblast evaluation, the number of osteoblasts in the treatment group was higher than the control group, although it was not significant. During the sixth-week evaluation, there was no significant decrease in the number of osteoblasts in both groups, as followed by Jensen's previous studies, where osteoblast density increased on day 21 by administering PRP.<sup>22</sup> It is due to the role of FGF, PDGF, IGF, TGF- $\beta$ , which play a role in the process of osteoblast proliferation and differentiation.<sup>23</sup>

In the third week of the evaluation of woven bone, the treatment group area was wider than the control group, although it was not significant. In the sixth-week evaluation, we found that the expansion of woven bone in both groups was not significant.

In the third week of Collagen Type-I evaluation, the amount of Collagen Type-I formed in the treatment group was more significant than in the control group even though the difference was not significant. In the sixth-week evaluation, there was a non-significant decrease in the number of Collagen Type-I in both groups, where the number in the

treatment group was still higher than in the control group.

In the third week of Osteocalcin evaluation, the treatment group's number of osteocalcin was greater than in the control group, although it was not significant. In the sixth-week evaluation, there was an insignificant increase in the production of osteocalcin in both groups. The amount of osteocalcin in the treatment group was still higher than in the control group. Osteocalcin has an essential role in the regulation of the hydroxyapatite crystals formation (called mineralization). Therefore, osteocalcin can only be detected in the advanced reparative phase where callus mineralization has begun to form.<sup>14</sup> Based on other studies, there was an increase in osteocalcin above-average values in response to normal fracture healing 42 days after fracture trauma.<sup>24</sup> Osteoblasts form osteocalcin. In this study, there was a decrease in the number of osteoblasts from the third week to the sixth week, but the number of osteocalcin increased, especially in the treatment group when compared with the control group. It can occur due to increased osteoblast activity in producing osteocalcin.<sup>25</sup> TGF- $\beta$ , which is in the PRP, has an essential role in osteoblasts' activity in osteocalcin formation.

In the third week of the evaluation of alkaline phosphatase, the amount formed in the treatment group was greater than in the control group, although it was not significant. In the sixth-week evaluation, there was an increase in alkaline phosphatase in both groups, but a



significant increase was found in the BHA group with PRP alone. It is consistent with previous literature, which states an increase in serum Bone Alkaline Phosphatase (BALP) in normal bone healing responses. However, other similar research studies found that the increase in BALP was not significant.<sup>26,27</sup> Noteworthy is the activity of osteoblasts, which may be related to the production of alkaline phosphatase. The amount of alkaline phosphatase formed was greater than the control group in the treatment group, although it was not significant.

In the third week of the immunoglobulin G evaluation, the control group amount was greater than in the treatment group, although it was not significant. In the sixth-week evaluation, there was an insignificant increase in immunoglobulin G in both groups. The number of immunoglobulin G in the control group was still higher than the treatment group. Insignificant differences between these groups indicate that immunological reactions still exist due to the allograft (PRP) and xenograft (BHA) materials used in this study. Previous literature stated that the immunological response occurred higher in xenograft than the allograft group.<sup>28</sup> Immunological reactions can be minimized with good processing techniques. Previous literature also states that the immunological reactions arising from hydroxyapatite material can be ignored.<sup>29,30</sup>

The limitation of this study is that evaluation is only carried out through histological examination. It is necessary to have another examination method, for example,

evaluation by using imaging (X-Ray, CT-SCAN, etc.). Further research is needed to determine the relationship between osteocalcin and alkaline phosphatase related to the administration of freeze-dried PRP in bone grafts. It is also necessary to do other research to determine the content of growth factor in bone graft with freeze-dried PRP after the storage process.

## CONCLUSION

A provision of PRP in the bone healing process with bone graft provides an opportunity for success in bone healing due to trauma. The area of woven bone, osteocalcin, and alkaline phosphatase has increased in third and sixth-week evaluations even though osteoblasts have decreased. Allegations that an increase in osteoblast activity impact the increase in the area of woven bone formed and the production of osteocalcin and alkaline phosphatase.

## REFERENCES

1. Brydone AS, Meek D, MacLaine S. Bone grafting, orthopaedic biomaterials, and the clinical need for bone engineering. *Proc Inst Mech Eng Part H J Eng Med.* 2010;224(12):1329–43.
2. Bowland P, Ingham E, Jennings L, Fisher J. Review of the biomechanics and biotribology of osteochondral grafts used for surgical interventions in the knee. *Proc Inst Mech Eng Part H J Eng Med.* 2015 Nov 24;229(12):879–88.
3. Jones JR, Lin S, Yue S, Lee PD, Hanna J V, Smith ME, et al. Bioactive glass scaffolds for bone regeneration and their hierarchical characterisation. *Proc Inst Mech Eng Part H J Eng Med.* 2010 29;



- 224(12): 1373–87.
4. Turnbull G, Clarke J, Picard F, Riches P, Jia L, Han F, Li B, Shu W. 3D bioactive composite scaffolds for bone tissue engineering. *Bioactive materials*. 2018 Sep 1;3(3):278-314.
  5. Henkel J, Woodruff MA, Epari DR, Steck R, Glatt V, Dickinson IC, et al. Bone regeneration based on tissue engineering conceptions—a 21st century perspective. *Bone Res*. 2013; 1(1): 216–48.
  6. Nandi SK, Roy S, Mukherjee P, Kundu B, De DK, Basu D. Orthopaedic applications of bone graft & graft substitutes: A review. *Indian J Med Res*. 2010; 132(7): 15–30.
  7. Myeroff C, Archdeacon M. Autogenous bone graft: Donor sites and techniques. *J Bone Jt Surg - Ser A*. 2011; 93(23): 2227–36.
  8. Gleeson JP, Plunkett NA, O'Brien FJ. Addition of hydroxyapatite improves stiffness, interconnectivity and osteogenic potential of a highly porous collagen-based scaffold for bone tissue regeneration. *Eur Cell Mater*. 2010; 20(218): 30.
  9. Ngoc N. Basic Knowledge of Bone Grafting; 2012.
  10. Venkatesan J, Kim S-K. Nano-hydroxyapatite composite biomaterials for bone tissue engineering - A review. *J Biomed Nanotechnol*. 2014; 10(10): 3124–40.
  11. Hung NN. Basic knowledge of bone grafting. *Zorzi A Bone Grafting Croat InTech, Chapters*. 2012; 11–38.
  12. Platt JL, Cascalho M, Piedrahita JA. Xenotransplantation: Progress Along Paths Uncertain from Models to Application. *ILAR J*. 2018; 59(3): 286–308.
  13. Rivera-Muñoz EM. Hydroxyapatite-based materials: synthesis and characterization. *Biomedical Engineering-Frontiers and Challenges*. 2011 Aug 1:75-98.
  14. Mahyudin F, Rantam FA. Regenerasi pada Massive Bone Defect dengan Bovine Hydroxyapatite sebagai Scaffold Mesenchymal Stem Cell. *J Biosains Pascasarj*. 2011; 13(3): 179–95.
  15. Lubkowska A, Dolegowska B, Banfi G. Growth factor content in PRP and their applicability in medicine. *J Biol Regul Homeost Agents*. 2012 Apr 1;26(2 Suppl 1):3S-22S..
  16. L Sinclair K, Mafi P, Mafi R. The use of growth factors and mesenchymal stem cells in orthopaedics: in particular, their use in fractures and non-unions: a systematic review. *Curr Stem Cell Res Ther*. 2017; 12(4): 312–25.
  17. Qiao Z, Greven J, Horst K, Pfeifer R, Kobbe P, Pape H-C, et al. Fracture healing and the underexposed role of extracellular vesicle-based cross talk. *Shock Inj Inflammation, Sepsis Lab Clin Approaches*. 2018; 49(5): 486–96.
  18. Kloping YP, Desnantyo AT, Rehatta NM. The effects of Platelet-Rich-Plasma (PRP) injection on ligament injury. *Bali Med J*. 2016; 5(1): 36–42.
  19. Kasten P, Vogel J, Geiger F, Niemeyer P, Luginbühl R, Szalay K. The effect of platelet-rich plasma on healing in critical-size long-bone defects. *Biomaterials*. 2008; 29(29): 3983–92.
  20. Nakatani Y, Agata H, Sumita Y, Koga T, Asahina I. Efficacy of freeze-dried platelet-rich plasma in bone engineering. *Arch Oral Biol*. 2017; 73: 172–8.
  21. Rachmawati T, Astuti SP. The Effect of Allogenic Freeze Dried Platelet- Rich Plasma in Immunological Responses of Rabbits. *J Stem Cell Res Tissue Eng*. 2017; 1(1): 325–7.
  22. Jensen SS, Terheyden H. Bone augmentation procedures in localized defects in the alveolar ridge: clinical results with different bone grafts and bone-substitute materials. In: *Database of Abstracts of Reviews of Effects (DARE): Quality-Assessed Reviews*. Centre for Reviews and Dissemination (UK); 2009.
  23. Devescovi V, Leonardi E, Ciapetti G, Cenni E. Growth factors in bone repair. *Chir Organi Mov*. 2008; 92(3): 161–8.
  24. Herrmann M, Klitscher D, Georg T, Frank J, Marzi I, Herrmann W. Different kinetics of bone markers in normal and delayed fracture healing of long bones. *Clin Chem*. 2002; 48(12): 2263–6.
  25. Wesseling-Perry K, Salusky IB. Chronic kidney disease: mineral and bone disorder in children. In: *Seminars in nephrology*. Elsevier; 2013. p. 169–79.
  26. Marchelli D, Piodi LP, Corradini C, Parravicini L, Verdoia C, Ulivieri FM. Increased serum OPG in atrophic nonunion shaft fractures. *J Orthop*



- Traumatol. 2009; 10(2): 55–8.
27. Moghaddam A, Müller U, Roth HJ, Wentzensen A, Grützner PA, Zimmermann G. TRACP 5b and CTX as osteological markers of delayed fracture healing. *Injury*. 2011; 42(8): 758–64.
  28. Jacobsen G, Easter D. Allograft vs. xenograft: Practical considerations for biologic scaffolds. *Musculoskelet Transpl Found*; 2008.
  29. Dumitrescu AL. Bone grafts and bone graft substitutes in periodontal therapy. In: *Chemicals in surgical periodontal therapy*; 2011, p. 73-144.
  30. Bairo F. Biomaterials and implants for orbital floor repair. *Acta biomaterialia*. 2011 Sep 1;7(9):3248-66.

