

*Case Report***Fixation of A Closed Displaced Midshaft Clavicle Fracture by Intramedullary K-wire: A Case Report**Devuandre Naziat¹ , David Haryadi¹ ¹Department of Orthopaedic and Traumatology, Palembang BARI General Hospital, Palembang, IndonesiaCorrespondence should be addressed to Devuandre Naziat, Department of Orthopaedic and Traumatology, Palembang BARI General Hospital, Jl. Panca Usaha No. 1, Palembang 30254, Indonesia. e-mail: devuandren@gmail.com**ABSTRACT**

Background: Fractures of the clavicle record for practically 50% of all injuries in the shoulder girdle. In recent years, the treatment paradigm for clavicle fractures has shifted from nonoperative treatment toward operative treatment, especially in fractures with significant displacement or shortening.

Case Report: A 16 years old female presented to the emergency room with an injury on her right shoulder after a motorcycle accident. The radiograph showed a displaced midshaft clavicle fracture, classified as Robinson 2B1. Operative measures were performed using intramedullary K-Wire.

Discussion: There is no universally agreed gold standard for clavicle fracture fixation. The majority of midshaft clavicle fractures with a displaced fragment can be successfully repaired without surgery. On the other hand, conservative therapy of Robinson type 2B clavicle fracture has been linked to a higher rate of nonunion and a decrease in strength and endurance of the shoulder. In this patient, on the two-week follow-up after wire removal surgery, the patient regained full shoulder range of motion without any limitation on activities of daily living with a minimal post-operative scar.

Conclusion: We recommend that intramedullary fixation using K-wires is a useful technique in displaced midshaft clavicle fracture as it is effective, has a good cosmetic outcome, and is well-suited for the BPJS era as it had the low-cost burden.

Keywords: Clavicle fractures; K-wires; Intramedullary fixation; Traffic accident

INTRODUCTION

Fractures of the clavicle address around 5-10% of all fractures and record for practically 50% of all injuries in the shoulder girdle. Middle third part of the clavicle is the most widely recognized area to sustain the fracture, with 85% of clavicle fractured in this portion.¹ Fractures of the clavicle are frequently the consequences of a vicious collision or a high-speed injury such as a traffic incident or sports-related trauma.²

In recent years, the treatment paradigm for clavicle fractures has shifted from nonoperative treatment toward operative treatment. It is particularly true in regards to markedly shortened or displaced types of fractures. Some reports stated a 0% nonunion rate between 200 fractured clavicles treated operatively compared to nearly 15% in those treated nonoperatively.² Nonunion rates were greater in several kinds of research than previously reported.^{1,3}

Concerning the fact that the problem of nonunion is even greater than previously known, proper assessment and treatment of clavicle fracture are becoming more essential. Finding cost-effective operative methods in this kind of fracture also becomes more imperative, especially in the BPJS (Indonesian Universal Healthcare) era.

In this report, we describe the case of an adolescent female who sustained a closed displaced midshaft clavicle fracture, treated with an intramedullary K-Wire. The procedure was carried out by a board-certified orthopaedic surgeon with seven years of experience in the field.

CASE REPORT

A 16 years old female presented to the emergency room with the chief complaint of pain, swelling, and deformity on her right shoulder after a motorcycle accident. She sustained the injury approximately 1 hour earlier when she fell from her motorcycle and had her right shoulder thrown directly into the road. A deformity on her right shoulder was evident along with swelling, local tenderness, limited active and passive range of motion, with no open wound.

The hand through her shoulder was fully sensate with a palpable radial nerve. Her vital signs were normal. The radiograph showed a fully displaced midshaft clavicle fracture, classified as Robinson 2B1 (Figure 1). After counseling the patient regarding her condition and the planned surgery, the decision was made

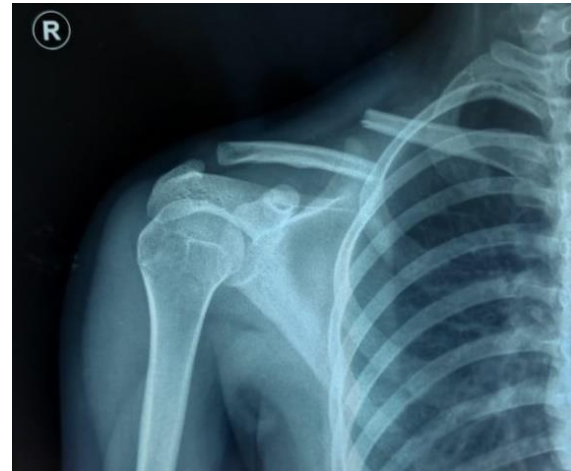


Figure 1. Radiograph of the clavicle at presentation.

to attempt open reduction and internal fixation using Kirschner Wires (K-Wires).

Under general anesthesia, the patient was positioned supine on the operating table, with a hump in the back between the scapulae. The clavicle, sternum, and anterior shoulder area were then prepped and draped in a sterile fashion, with the patient's head turned to the opposite side of the operation side. A 2 cm incision was made above the clavicle's posterolateral corner, 2 cm medial to the acromioclavicular joint. The supraclavicular nerves were carefully protected.

A knife and curette were used to remove a small quantity of soft tissue and periosteum from the fracture border as soon as the fracture location was revealed. With Weber clamps, the medial fragment was then gripped and carefully lifted. The medullary cavity of the medial fragment of the fractured clavicle was then bored by using a drill with a 2.5 millimeters bit pointed anteromedially until it reached 2-3 cm medial to the fracture line. It will serve as a guiding canal that will make drilling the medial fragment of the fractured clavicle easier for later.



After gently elevating the lateral fragment using Weber clamps, a 2.5 millimeters diamond-tipped K-Wire on both ends was bored into the intramedullary canal of the lateral fragment until the wire pierced both the cortex of the posterolateral part of the clavicle and the posterolateral skin of the shoulder. The wire was dragged out from the lateral side of the skin that has been just pierced by using a power drill until the medial tip of the wire is level with the fracture border of a lateral fragment. The fracture reduction was then performed using forceps, and the wire was then bored into the medial fracture fragment.

The wire should be bored into the medial fragment at maximum speed, gently and carefully, as it will go through the passage of the guiding canal of the medial fracture fragment that has just been made before. The wire was bored until it went through the anteromedial cortex of the medial fragment, 2-3 cm medial to the fracture site so that it would be enough for anti-rotational fixation. Approximately two weeks following surgery, the patient was placed in an arm sling until the pain subsided. After that, the patient was advised to engage in light, non-weight-bearing activities daily. For the first six weeks, the patients were not allowed to drive, do heavy weights lifting, or abduct their arm over shoulder height. The patients next underwent pendulum exercises and hand, wrist, and elbow exercises after six weeks.

After 12 weeks of fixation, the wire was removed when clinical and radiographic evidence of fracture union was found (Figure 2A). The tiny incision was made just over the posterolateral part of the clavicle, with the wire

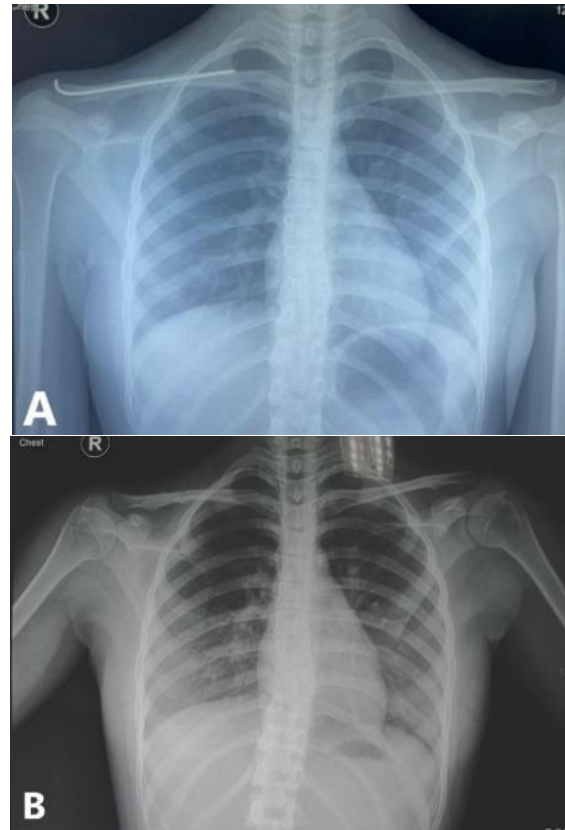


Figure 2. (A) Radiograph of the clavicle before the wire removal as it confirms fracture union and (B) Radiograph after the procedure as it confirms wire removal.

palpated and removed after that. A second radiograph was taken to confirm the hardware's removal and the clavicle's stability (Figure 2B).

On the two-week follow-up after the wire removal surgery, the patient regained full shoulder range of motion without any limitation on activities of daily living, with a DASH score of 6.7 (Figure 3A). The patient had also satisfied with the cosmetic aspect of the surgery, as it produces minimal post-operative scar (Figure 3B).



Figure 3. (A) The patient regained full shoulder range of motion on the two-week follow-up after the wire removal surgery with (B) Minimal post-operative scar.

DISCUSSION

There is no universally agreed gold standard for clavicle fracture fixation. The majority of midshaft clavicle fractures with a displaced fragment can be successfully repaired without surgery. On the other hand, conservative therapy of Robinson type 2B clavicle fracture

has been linked to a higher rate of nonunion and a decrease in strength and endurance of the shoulder.^{4,5}

Multiple studies have found nonunion and malunion rates as high as 15.1% in patients treated conservatively. Pain also contributes to up to 31% of the dissatisfaction rate among these patients. Subsequent operations are also more likely due to neurological complications, cosmetic outcomes, shortening, or malunion.⁶⁻⁸ Furthermore, displaced midshaft clavicle fracture was 18.5 times more frequent to cause non or delayed union than undisplaced fracture.¹ As a result, there are clinical indications in which Robinson type 2B clavicle fracture treated operatively can provide better results due to fewer complications than conservative treatment.^{6,9}

However, the reasons for performing intramedullary clavicle fixation by using K-wires in the present case were: (1) Implants used in intramedullary clavicle fixations should have a thin enough diameter to pass through the narrowest part of the clavicle, which is located in the midshaft part of the clavicle medullary cavity and also has enough flexibility to adjust to anatomical variations that may differ among patients. K-Wires' flexibility and small diameter make them ideal for intramedullary clavicle location for displaced midshaft clavicle fracture fixation, as they adhere to the clavicle's complicated three-dimensional anatomical variations.¹⁰ Moreover, in this case, firm fixation of the K-Wires on the anteromedial cortex is also done to function as an anti-rotational fixation; (2) Intramedullary clavicle fixations can take advantage from the good



cosmetic outcome of a smaller scar, reduced implant soft tissue irritation, preservation of surrounding soft tissue, and minimal periosteal stripping;⁸ (3) K-wires are a cost-effective option for clavicle fracture treatment. Although K-Wire fixation requires a second treatment more frequently than plate fixation, K-Wire fixation has a substantially lower economic burden than other fixation procedures.¹¹⁻¹⁴

Compared to fixation using plates, clavicle fracture fixation with intramedullary devices reportedly results in shorter operating room time, comparable time to union, fewer complications, less usage of narcotics, and less symptomatic hardware.^{10,15-17}

CONCLUSION

Due to the increasing evidence of higher nonunion and malunion rates in patients with clavicle fracture treated non-operatively, there is also an increasing need for operative treatment in patients with these fractures. We suggest that intramedullary fixation by using K-wires as a useful technique in displaced midshaft clavicle fracture. In the present case, it is effective, has a good cosmetic outcome, and is well-suited for the BPJS era as it had a low-cost burden.

REFERENCES

- Groh GI. *Clavicle Injuries: A Case-Based Guide to Diagnosis and Treatment*. Springer; 2017.
- McKee RC, Whelan DB, Schemitsch EH, McKee MD. Operative versus nonoperative care of displaced midshaft clavicular fractures: a meta-analysis of randomized clinical trials. *J Bone Joint Surg Am*. 2012; 94: 675-84.
- McKnight B, Heckmann N, Hill JR, Pannell WC, Mostofi A, Omid R, et al. Surgical management of midshaft clavicle nonunions is associated with a higher rate of short-term complications compared with acute fractures. *J Shoulder Elb Surg*. 2016; 25: 1412-7.
- Fritz EM, van der Meijden OA, Hussain ZB, Pogorzelski J, Millett PJ. Intramedullary fixation of midshaft clavicle fractures. *J Orthop Trauma*. 2017; 31: S42-4.
- Hussain N, Sermer C, Prusick PJ, Banfield L, Atrey A, Bhandari M. Intramedullary nailing versus plate fixation for the treatment displaced midshaft clavicular fractures: a systematic review and meta-analysis. *Sci Rep*. 2016; 6: 1-12.
- Barlow T, Beazley J, Barlow D. A systematic review of plate versus intramedullary fixation in the treatment of midshaft clavicle fractures. *Scott Med J*. 2013; 58: 163-7.
- Wang XH, Guo WJ, Li AB, Cheng GJ, Lei T, Zhao YM. Operative versus nonoperative treatment for displaced midshaft clavicle fractures: a meta-analysis based on current evidence. *Clinics*. 2015; 70: 584-92.
- Ban I, Nowak J, Virtanen K, Troelsen A. Overtreatment of displaced midshaft clavicle fractures: A survey of hospitals in Sweden, Denmark, and Finland. *Acta Orthop*. 2016; 87: 541-5.
- Narsaria N, Singh AK, Arun GR, Seth RR. Surgical fixation of displaced midshaft clavicle fractures: elastic intramedullary nailing versus precontoured plating. *J Orthop Traumatol*. 2014; 15: 165-71.
- Bakota B, Chan G, Staresinic M, Rajput V, Phadnis J, Korac Z. Safe intramedullary fixation of displaced midshaft clavicle fractures with 2.5 mm Kirschner wires—technique description and a two-part versus multifragmentary fracture fixation outcome comparison. *Injury*. 2017; 48: S27-S33.
- Hanselman AE, Murphy TR, Bal GK, McDonough EB. Operative cost comparison: plating versus intramedullary fixation for clavicle fractures. *Orthopedics*. 2016; 39: e877-82.
- Althausen PL, Shannon S, Lu M, O'Mara TJ, Bray TJ. Clinical and financial comparison of operative and nonoperative treatment of displaced clavicle fractures. *J*



- shoulder Elb Sur. 2013; 22: 608–11.
13. Melean PA, Zuniga A, Marsalli M, Fritis NA, Cook ER, Zilleruelo M, et al. Surgical treatment of displaced middle-third clavicular fractures: a prospective, randomized trial in a working compensation population. *J shoulder Elb Surg.* 2015; 24: 587–92.
 14. Walton B, Meijer K, Melancon K, Hartman M. A cost analysis of internal fixation versus nonoperative treatment in adult midshaft clavicle fractures using multiple randomized controlled trials. *J Orthop Trauma.* 2015; 29: 173–80.
 15. Houwert RM, Wijdicks FJ, Steins Bisschop C, Verleisdonk EJ, Kruyt M. Plate fixation versus intramedullary fixation for displaced mid-shaft clavicle fractures: a systematic review. *Int Orthop.* 2012; 36: 579–85.
 16. Van der Meijden OA, Houwert RM, Hulsmans M, Wijdicks FJ, Dijkgraaf MG, Meylaerts SA, et al. Operative treatment of dislocated midshaft clavicular fractures: Plate or intramedullary nail fixation?: A randomized controlled trial. *JBJS.* 2015; 97: 613–9.
 17. Andrade-Silva FB, Kojima KE, Joeris A, Silva JS, Mattar Jr R. Single, superiorly placed reconstruction plate compared with flexible intramedullary nailing for midshaft clavicular fractures: a prospective, randomized controlled trial. *JBJS.* 2015; 97: 620–6.

