

## Case Report

# Vacuum-Assisted Closure and Muscle Flap as An Alternative Modality for Infected Wound after ORIF of Tibial Fracture: Case Report

OK Ilham Abdullah Irsyam<sup>1</sup> , Saraswati Hastika<sup>2</sup>, Hendra Hendra<sup>1</sup> , Andrew Budiarta Budisantoso<sup>1</sup> ,  
Tesar Akbar Nugraha<sup>1</sup> 

<sup>1</sup>Department of Orthopaedic and Traumatology, Faculty of Medicine, Universitas Sumatera Utara, Medan, Indonesia

<sup>2</sup>Department of Plastic Reconstructive and Aesthetic Surgery, Faculty of Medicine, Universitas Airlangga, Surabaya, Indonesia

Correspondence should be addressed to OK Ilham Abdullah Irsyam, Department of Orthopaedic and Traumatology, Faculty of Medicine, Universitas Sumatera Utara, Jl. Dr. Mansyur No.5, Padang Bulan, Medan, Indonesia. e-mail: ilham.irsyam@usu.ac.id

## ABSTRACT

**Background:** The blood supply of a bone can be decreased due to the use of an implant, leading to wound-bed bacterial colonization and the development of the SSI. The principle of vacuum-assisted closure (VAC) is to use a negative pressure environment in the wound to promote increased wound healing. The case shows that VAC application and muscle flap therapy provide the definitive healing of infected wounds after ORIF.

**Case Report:** A 45 years-old male presented with a close comminuted proximal third right tibia fracture and tense skin. The fracture was openly reduced and internally fixated with plate fixation and a skin flap on the fracture area. Still, the wound could not be closed due to difficulty covering the wound, so a counter incision was made. After four days, the patient developed necrosis in the post-operation wound and subsequently underwent debridement and muscle flap with VAC application.

**Discussion:** SSI can be treated by applying of appropriate antibiotic and surgical procedures. In this case, the infection was treated using third-generation cephalosporin antibiotic, debridement, dissection, and re-elevation of gastrocnemius muscle flap covering the exposed plate area in inferior, split skin graft above the muscle flap and VAC above skin graft with 75 mmHg pressure.

**Conclusion:** Debridement with muscle flap and application of VAC in the deep infected wound of open reduction and internal fixation was found to be successful methods in minimizing complications and obtaining an optimal outcome. This finding was associated with accompanying morbidities or a good wound healing process.

Keywords: Vacuum-assisted closure; Muscle flap; Tibia fracture; Surgical site infection; Human and medicine

## INTRODUCTION

Tibial fractures are treated with surgery and are at risk of serious infections. Previous studies have suggested that infections following internal fixation were higher in emerging countries, as operating rooms are often not fully sterile and may contain microbes that can cause infection.<sup>1</sup> The incidence of infection was 1.6% in closed fracture and associated with the low serum albumin concentration, older age, obesity, smoking, diabetes mellitus, and ischemia secondary to vascular disease or irradiation. Surgical risk factors include prolonged procedures and

inadequacies in either the surgical scrub or the antiseptic preparation of the skin.<sup>1</sup> The goals of treatment are a pain-free function of the lower limb. Whether these can be best met with surgery or closed treatment depends on the injury's particular circumstances.<sup>2</sup> Blood flow may be reduced because of an implant and can interfere with wound healing. These are liable for bacterial colonization on the wound bed and can cause severe infections.<sup>3</sup>

A closed fracture can be treated both by closed or open procedures. Common potential complications after open reduction and internal fixation (ORIF) are post-surgical infection, non-

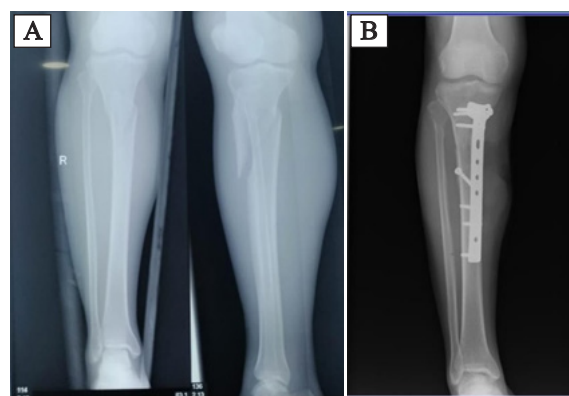
union, malrotation, pain, compartment syndrome, and nerve injury. Early infection complicating ORIF of a limb fracture is often a challenge for both the surgeon and the patient.<sup>4</sup> Cleaning the wound through irrigation and debridement was the first line of treatment in treating a deep infection after surgical ORIF. It decreases the bacterial load and infection to support fracture healing.<sup>5</sup> The incidence for the most common organisms found were aerobic gram-positive and aerobic gram-negative bacteria, 69.2% and 15.4%, respectively. The most commonly isolated organism was *Staphylococcus aureus* (84.6%). The majority of the infections were treated with antibiotics only (53.8%) or with antibiotics and surgery (38.5%). Cephalosporin was the most commonly used antibiotic. The literature's typical length of prophylactic antibiotic use for tibia fractures ranges from 1–5 days.<sup>1</sup>

Skin grafts can be applied in various conditions, such as traumatic wounds, defects after tumor resection, burn reconstruction, scar contracture release, etc. The clinical outcome of skin grafting depends on a variety of factors. The second most common cause of graft loss is infection. Henderson et al. reported a 15% graft failure rate due to infection.<sup>6</sup> One soft-tissue restoration procedure for the knee is the gastrocnemius flap. The medial gastrocnemius flap is a popular procedure for covering a variety of abnormalities. When full-thickness defects have exposed tendon, bone, or implant, or when full-thickness surgical incisions cannot be closed under proper tension, such as when a draining sinus has been debrided, medial gastrocnemius flap coverage is preferred. A flaw in the medial or anterior aspect of the knee that extends to the distal region. The medial gastrocnemius flap is particularly successful for treating soft tissue deficiency across the medial or anterior portion of the knee, at or distal to the inferior pole of the patella (e.g., over the tibial tuberosity or patellar tendon. Local rotating muscle flaps generally have positive outcomes, especially in complex skeletal and soft tissue restoration.<sup>7</sup>

Negative pressure wound therapy (NPWT) may be used to assist wound coverage in accelerating granulation formation and removing the exudate in osteosynthesis-associated infection (OAI).<sup>8</sup> VAC is one of the methods used to support wound healing. It is based on the principle that the wound's negative pressure improves the environment for wound healing.<sup>9</sup> NPWT usage aims to decrease tissue edema, enhance local blood circulation, limit or prevent infection, improve flap rates, and potentially decrease the overall need for flaps.<sup>3</sup> This case report evaluates the complex treatment and outcome of an infected wound following ORIF of a closed tibial fracture in a 45-year-old male patient treated with antibiotic therapy, VAC, and muscle flap.

## CASE REPORT

A 45-year-old male had a motor vehicle accident, being crushed by a motorcycle from the opposite side before admission, passed out (+) ± 10-15 minutes, bleeding from the nose (+). On physical examination, he was *compos mentis*, light reflex (+), blood pressure 130/72 mmHg, pulse 65x/minute, respiratory rate 22x / minute. There were deformity and extreme edema on the right leg in the localized examination, with limited range of motion. Dorsal pedis arterial pulse was palpable. We diagnosed the patient with a closed fracture on the right tibia Tscherne classification Grade I/II. On radiographic examination (Figure 1), he had a complete closed fracture on 1/3 proximal

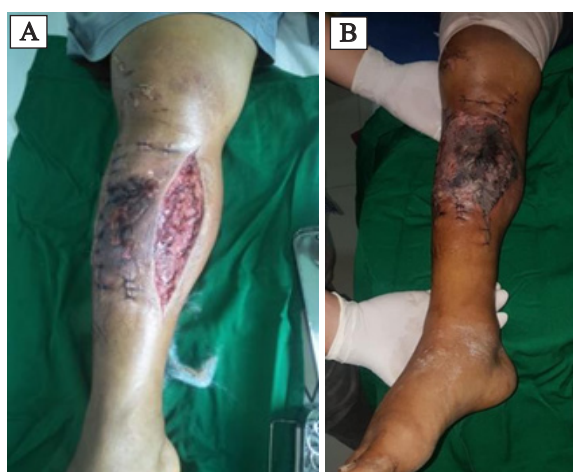

**Figure 1.** Radiographic examination of the fracture (A) and after open reduction and internal fixation (B)



right tibia with distal fragment displacement to posteromedial. There is a suspicious fracture on the proximal right fibula. On the operation, it was observed that there was a closed comminuted fracture of the tibia with butterfly fragment and tense skin. There was also high injury of the muscle of the anterior compartment.

The patient was then surgically treated with open reduction and internal fixation with T-plate 8 holes and six screws on the right lower leg. A counter incision was made on the medial side due to the difficulty of closing the wound. Four days later, the surgical wound was necrotic on the anterior aspect of the leg between the two incisions (Figure 2 A & B). The laboratory examination was obtained and showed leukocytosis with neutrophilia. He underwent debridement, medial gastrocnemius muscle flap, and split-thickness skin grafting. During surgery, there were nonviable tissue and pus on the wound. The pus and tissue culture were obtained. A broad-spectrum antibiotic, ceftriaxone 2 gr, was used as empiric treatment. The microbiology report then showed *Klebsiella pneumoniae* infection. Based on the sensitivity test that shows the microbiology is sensitive to Levofloxacin. Therefore, the antibiotic was changed into Levofloxacin 500 mg/12 hours intravenously. The patient was discharged five days after surgery with

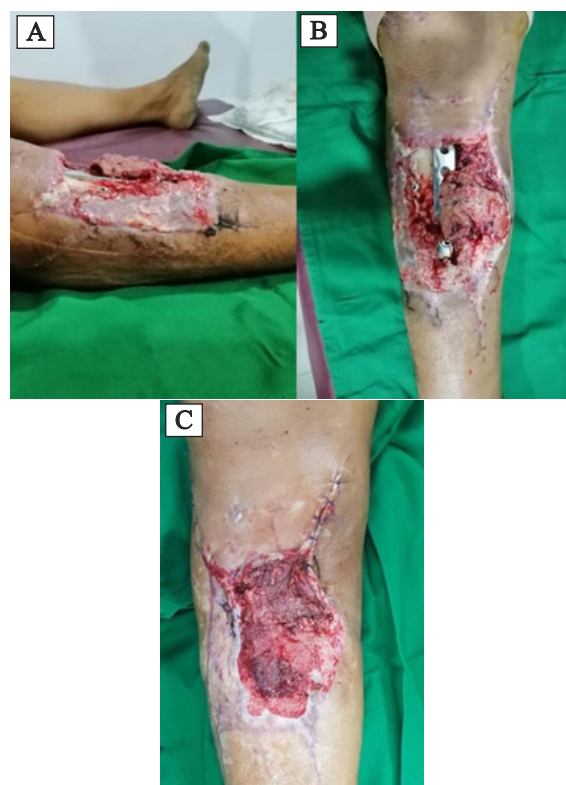

**Figure 2.** Clinical view. (A) After open reduction and internal fixation. The wound was found at the surgical incision at the proximal medial of the leg, and the size was found approximately 5x5 cm with muscle as the base of the wound. (B) 4 days after open reduction and internal fixation, there was a necrosis of the surgical wound.

non-weight bearing and moist wound dressing until the flap healed.

Within one month, the patient lacked compliance and did not control the wound according to the schedule. The patient came again with an open wound, pus in the right lower leg, granulation, bone, or plate seen in the wound area in the next month. The flap was viable but atrophied with pus discharge. There was no osteomyelitis or septic implant loosening (Figure 3A & B). Levofloxacin 500 mg/12 jam was given intravenously along with an analgesic.

After two weeks, the condition was not getting better, so the patient underwent surgical debridement. The wound was found with approximately 5 x 5 cm with bone as the base of the wound. Dissection and re-elevation of medial gastrocnemius muscle flap were done to cover the exposed plate area in the inferior. A split skin graft (donor from the right femur in anterior) was applied above the muscle flap. There was no intervention to the bone plate fixation because it was stable and loosening. There was

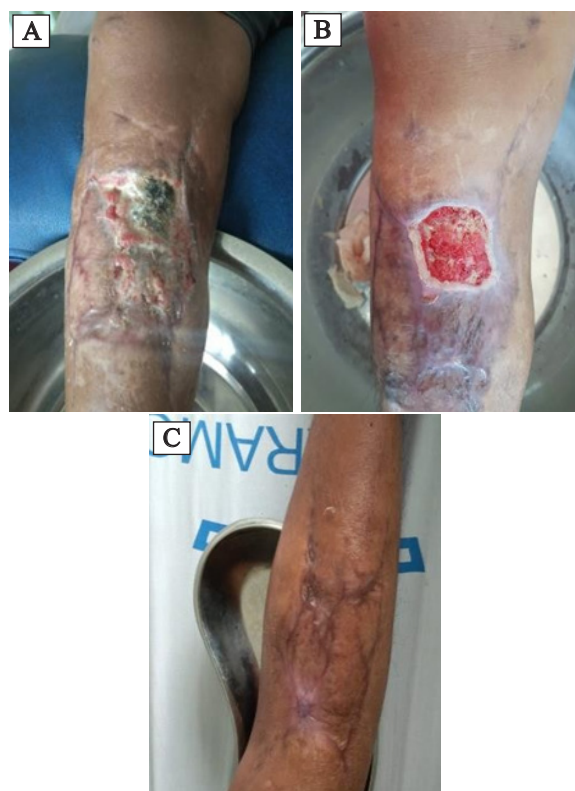

**Figure 3.** (A&B) Open wound with bone and plate were exposed. (C) Clinical picture after the second debridement, gastrocnemius flap, and skin grafting.



only one loose screw, and it had been removed. Vacuum-assisted closure (VAC) above skin graft with 75 mmHg pressure was intermittently applied in the hospital for two weeks. The pressure was set to 75 mmHg to keep skin graft viability.<sup>10</sup> The patient was given Levofloxacin for 14 days until the clinical and laboratory results were improved. After no sign of infection clinically and a decrease in the leukocyte count, the VAC was removed, and the patient was discharged two weeks post-operation. There was a granulation without pus and no bone or plate exposed on the wound. In the healing process, there is a slough appearance of the superior part of the flap (Figure 3C). The patient was given cefixime 200 mg twice daily for seven days at home.

One month after the operation, the inferior part of the wound was healed first, and two weeks later, the patient came again with granulation on the superior part of the wound (Figure 4A & B). Four months after the last operation, the wound had fully healed, and the patient could fully weight-bear. We found that the wound's infection was handled well



**Figure 4.** Wound healing at (A) One month, (B) One month, and two weeks, and (C) Four months after the operation.

during this case and did not interfere with the fracture's plate fixation and bone healing (Figure 4C).

## DISCUSSION

This case presented a patient with gene Xpert biopsy an infected wound after the ORIF of closed tibial fracture. Fractures of the tibial shaft are the most common long bone fracture.<sup>11</sup> The most common bacteria was *S.aureus*, followed by *Pseudomonas*, *S.epidermidis*, *Enterobacteriaceae*, or *Enterococcus* species. The bacterial spectrum corresponded with the incidence in the literature. Operative time and open fractures are independent predictors of postoperative infections.<sup>12</sup> Cephalosporin was the most commonly used antibiotic; in this case, we used third-generation cephalosporin, ceftriaxone, as antibiotic therapy for this patient. The bone stabilizing method was widely variable across studies. Some authors reported temporary external fixation, followed by a plate or an intramedullary device. As in this case, internal fixation was done with T-plate 8 holes and six screws on the right tibia. A similar case was reported by Karbalaeikhani et al., with a tibial fracture case. The hardware plate performed open reduction and internal fixation of the tibia fracture. A few days after the operation, soft tissue necrosis was seen at the incision site, and the implanted hardware was exposed. We decided to cover the exposed hardware by the medial head of the gastrocnemius muscle flap. After five days, the tie-over of the grafted muscle flap was removed. Complete healing of the exposed area and exposed hardware occurred without any complication.<sup>13</sup> In this case, the fracture was stabilized with open reduction and internal fixation with T-plate 8 holes and six screws on the right cruris. Due to difficulty covering the wound, a counter incision was made on the medial side.

Local circulation can be compromised by using an internal implant, which can further contribute to producing an area liable to infection. The second most common cause of graft loss is an infection, with hematoma formation being the most



common. The wound may have poor local circulation, or the surface contamination may have been too significant to allow graft survival. Technical errors such as applying the graft dermis side in the superficial will result in complete graft loss. Using excess pressure, stretching the graft too tightly, or handling the graft in other traumatic ways may lead to partial or complete graft failure.<sup>7</sup> These might be the problem that caused the necrosis of the post-operation wound in this case. Four days later, the patient underwent debridement with prophylaxis antibiotic, gastrocnemius muscle flap, and split skin grafting due to the necrotic wound. Gastrocnemius muscular flaps, particularly the medial head, showed an excellent result. It has some benefits: it is a reliable flap, even in the older patients; its vascular anatomy is consistent; the excellent caliber of the pedicle; and its dissection is rather easier to be done.<sup>14</sup>

Due to lack of compliance a month later, the patient came again with an open wound, pus in the right cruris, granulation, bone, or plate seen in the wound area. He was treated with cephalosporin antibiotic injection, debridement, dissection, and re-elevation of gastrocnemius muscle flap covering the exposed plate area in the inferior. He split skin graft (donor from the right femur in anterior) applied above the muscle flap. Vacuum-assisted closure (VAC) above skin graft with 75 mmHg pressure for two weeks in the hospital. NPWT had been reported to be a suitable method in managing wound infection after hip replacement surgery. Another study had also reported the use of VAC to treat deep wound infection after spinal instrumentation surgery. An excellent outcome had been reported, but it was only from an observation from two patients. Another study, which was observed with more detail at infection after hip arthroplasty, found infection resolution in 26 from 28 patients, with the mean duration of treatment of 9 days (3 – 16 days) with the mean follow-up of 3 years. A study by Lehner et al. showed that NPWT produced showed a cure rate of more than 80% with retention of the implants in infections, both acute

and chronic.<sup>15</sup>

Some prefer negative pressure wound therapy to treat infected wounds because negative pressure wound therapy has been reported to increase granulation tissue formation, enhance local blood flow, and decrease the bacterial burden and infection rates, among other metrics.<sup>3</sup> VAC had been proven to remove interstitial fluid from wounds, increase wound vascularization, and decrease the bacterial load. It could also benefit other diseases such as chronic open wounds, common problems with spinal cord injury, postoperative spinal surgical infections, and diabetic ulcer cases. It is a safe and reliable method to manage. It is safe to manage infected wounds, open fracture wounds, related soft tissue complications, and acute soft tissue lacerations. As a result, the outcomes in all studies and cases were satisfactory. In addition, VAC devices were also indicated for severe traumatic and dehisced wounds. VAC usage in the infection after trauma was also referred to because of its significantly effective antimicrobial feature.<sup>8</sup>

## CONCLUSION

Vacuum-assisted closure (VAC) in infected wounds after open reduction and internal fixation seems suitable for reducing complications and achieving the best result. In this case, staged treatment from open reduction and internal fixation with plate and screws, followed by gastrocnemius muscle flap and split skin grafting. At last, the infection was treated with vacuum-assisted closure. Our treatment results were satisfactory in the last stage. These results may be based on accompanying morbidities or good wound healing. We found that infection of the wound was handled well during this case and did not interfere with the fracture's plate fixation and bone healing. However, we think that treatment protocol, including vacuum-assisted closure, is a reliable method, especially to avoid complications resulting from an infected wound of open reduction or any chronic open wound.



## REFERENCES

1. Doshi P, Gopalan H, Sprague S, Pradhan C, Kulkarni S, Bhandari M. Incidence of infection following internal fixation of open and closed tibia fractures in India (INFINITI): a multi-centre observational cohort study. *BMC Musculoskelet Disord.* 2017;18:156.
2. Swart E, Lasceski C, Latario L, Jo J, Nguyen U-SDT. Modern treatment of tibial shaft fractures: Is there a role today for closed treatment? *Injury.* 2021;52:1522–8.
3. Schlatterer DR, Hirschfeld AG, Webb LX. Negative pressure wound therapy in grade IIIB tibial fractures: fewer infections and fewer flap procedures? *Clin Orthop Relat Res.* 2015;473:1802–11.
4. Bonneville P. Operative treatment of early infection after internal fixation of limb fractures (exclusive of severe open fractures). *Orthop Traumatol Surg Res.* 2017;103:S67–73.
5. Bhandari M, Jeray KJ, Petrisor BA, Deveraux PJ, Heels-Ansdell D, Schemitsch EH, et al. A Trial of Wound Irrigation in the Initial Management of Open Fracture Wounds. *N Engl J Med.* 2015;373:2629–41.
6. Nsaful KO, Paintsil AB, Dakubo JCB, Nsaful J, Appiah-Labi K, Nartey E. An Evaluation of Bacterial Infection of Split Thickness Skin Grafts: At the Korle Bu Teaching Hospital. *Lap Lambert Academic Publishing;* 2020;9(1):259-65.
7. Tetreault MW, Della Valle CJ, Hellman MD, et al. Medial gastrocnemius flap in the course of treatment for an infection at the site of a total knee arthroplasty. *JBJS Essent Surg Tech.* 2017;7(2):e14.
8. Fang C, Wong T-M, To KKW, Yong SSY, Lau TW, Leung F. Infection after fracture osteosynthesis—Part II: Treatment. *J Orthop Surg.* 2017;25(1):1–11.
9. Ploumis A, Mpourazanis G, Martzivanou C, Mpourazanis P, Theodorou A. The role of vacuum assisted closure in patients with pressure ulcer and spinal cord injury: a systematic review. *World J Plast Surg.* 2019;8:279.
10. Jiang Z-Y, Yu X-T, Liao X-C, Liu M-Z, Fu Z-H, Min D-H, Guo G-H. Negative-pressure wound therapy in skin grafts: A systematic review and meta-analysis of randomized controlled trials. *Burns.* 2021;47:747–55.
11. Raducha JE, Swarup I, Schachne JM, Cruz A, Fabricant, P. Tibial Shaft Fractures in Children and Adolescents. *JBJS Rev.* 2019;7(2):e4.
12. Henkelmann R, Frosch K-H, Glaab R, Lill H, Schoepp C, Seybold D et al. Infection following fractures of the proximal tibia—a systematic review of incidence and outcome. *BMC Musculoskelet Disord.* 2017;18:1–8.
13. Karbalaiekhani A, Dehkhoda S, Saremi H. Gastrocnemius Muscle Flap and Its Application in Lower Extremity Reconstruction. *Ann Mil Heal Sci Res.* 2015;13:154-6.
14. Le Nen D, Hu W, Liot M, Moineau G, Gerard R. Gastrocnemius medial flaps. *Interact Surg.* 2007;2:118–27.
15. Norris R, Chapman AWP, Krikler S, Krkovic M. A novel technique for the treatment of infected metalwork in orthopaedic patients using skin closure over irrigated negative pressure wound therapy dressings. *Ann R Coll Surg Engl.* 2013;95:118–24.

