

LITERATURE REVIEW

The Role of Bronchoscopy in Hemoptysis

Sakina*, Irmu Syafa'ah

Department of Pulmonology and Respiratory Medicine, Faculty of Medicine, Universitas Airlangga/Dr. Soetomo General Hospital, Surabaya, Indonesia.

ARTICLE INFO

Article history:

Received 5 May 2020

Received in revised form 26 May 2020

Accepted 27 May 2020

Available online 30 May 2020

Keywords:

Bronchoscopy,
Hemoptysis,
Bleeding.

ABSTRACT

Massive hemoptysis is a medical emergency that requires intensive treatment with appropriate therapy. The underlying causes of hemoptysis are airway disease, parenchymal disease, and vascular disease. An appropriate diagnostic modality is needed in handling hemoptysis, one of which is by bronchoscopy. Bronchoscopy can identify whether bleeding is still active and see the condition of the patient's respiratory tract. Apart from being a diagnostic tool, bronchoscopy is also used as one of the therapeutic methods to stop bleeding. Initial bronchoscopy should be performed on massive hemoptysis after the patient is stable and the other side of the lung that is not the source of bleeding has been protected. After the source of bleeding is seen, several therapies can be done.

INTRODUCTION

Hemoptysis or coughing up blood is a health problem that has the potential to cause death since it is difficult to predict its severity and clinical development.^{1, 2} Hemoptysis in the large amount (massive) is included into medical emergencies that requires intensive treatment with appropriate therapy. Aside from its ability to disrupt hemodynamic stability due to large blood loss, massive hemoptysis can also interfere the gas exchange in alveoli and cause complications in asphyxia.^{2, 3} Although the incidence of massive hemoptysis is only 5-15% of the total cases, this must always be regarded as a life-threatening case that requires effective handling and management.^{2, 4}

The etiology of hemoptysis known today is very diverse, not only infections and lung disorders, but also neoplasms, cardiovascular abnormalities, and haematological disorders or systemic diseases. The four most common causes of hemoptysis are bronchiectasis, tuberculosis, lung cancer, and fungal infections. The difference in the etiology of hemoptysis related to geographical location is mainly influenced by the high incidence of tuberculosis in a country.^{3, 5, 6}

Bronchoscopy is the main diagnostic method for hemoptysis. Bronchoscopy can identify whether bleeding is still active and tell the condition of the patient's respiratory tract and can be done to control bleeding in patients.⁷ Therefore, it is necessary to know when we should do bronchoscopy in hemoptysis patients.

Definition of Hemoptysis

Hemoptysis comes from the Greek word *haima* which means blood and *ptysis* which means spit out. According to Dorland medical dictionary, hemoptysis or coughing up blood is the expectoration of blood or bloody mucus from the respiratory tract.⁸ Hemoptysis is massive if the amount of blood is between 100 ml to 1000 ml/24 hours. Some other literature uses the terms of major hemoptysis (≥ 200 ml/24 hours), severe hemoptysis (≥ 150 ml/12 hours and > 400 ml/24 hours), and exsanguinating hemoptysis (total ≥ 1000 ml or ≥ 150 ml/hour) to explain large amounts of bleeding.^{2, 3, 9} Massive hemoptysis requires immediate treatment because it can interfere the gas exchange in the lungs and can disrupt the patient's hemodynamic stability, that can be life threatening if not treated properly. The volume of fluid that can be contained in the airway is 100-200 ml. Therefore, hemoptysis can be said to be non-massive if the bleeding is less than 200 ml.^{4, 9}

Anatomy of the Pulmonary Vascular

Pulmonary blood circulation comes from two circulatory systems, namely pulmonary circulation and bronchial circulation. The source of bleeding of the hemoptysis can come from both of the circulatory systems. The source of bleeding of the massive hemoptysis generally comes from the bronchial circulation (90%) compared to the pulmonary circulation (5%).^{2, 10, 11} Bronchial arteries drain blood into the trachea, bronchi, esophagus, posterior

*Correspondence: hi.sakina.mail@gmail.com



mediastinum, and pulmonary arterial vasa vasorum. Patients with pulmonary abnormalities generally have systemic collateral vessels in the nonbronchial system, so it is necessary to take into account the involvement of these collateral vessels, especially during embolization procedure.¹²

Some nonbronchial systemic variations are the source of bleeding of the hemoptysis, especially in post embolization patients and patients with pulmonary disease involving the pleura. One-third of the patients who are supplied by nonbronchial arteries have the hemoptysis. Pathologically these vessels originate from the intercostal arteries, subclavian and axillary arteries, internal mammary arteries, phrenic arteries, and left gastric arteries.¹³

Etiology of Hemoptysis

The underlying causes of hemoptysis can be mainly divided into three, namely airway disease, parenchymal disease, and vascular disease. Bleeding from small blood vessels is usually focal or alveolar diffuse, can be caused by immunological diseases, vasculitis, cardiovascular, and coagulation disorders. Bleeding from large blood vessels is usually caused by infection, cardiovascular, congenital, neoplasm, and vasculitis.^{3, 14, 15} All causes of hemoptysis can potentially turn into massive hemoptysis.^{16, 17}

Pathophysiology of Hemoptysis

Every process that occurs in the lungs will result in hypervascularization of branches of the bronchial arteries that plays the role in providing nutrition to the lung tissue when pulmonary artery failure occurs in carrying out its functions for gas exchange.³ The capillary anastomosis complex is located between the pulmonary arteries and the systemic bronchial arteries. When pulmonary circulation is disrupted (for example due to thromboembolic disease, vasculitis abnormalities, or hypoxic vasoconstriction), bronchial supply will slowly increase, causing an increase in flow in the anastomotic vessels. Blood vessels become hypertrophied with thin walls and tend to tear into the alveoli and bronchi, such as bronchiectasis, chronic bronchitis, tuberculosis, fungal infections of the lung, and lung abscesses. In neoplasm, the release of angiogenic growth factors triggers neovascularization and changes in pulmonary arteries, with involvement of collateral systemic vessels. The newly formed collateral blood vessels are very fragile and can rupture into the respiratory tract.^{11, 12, 18, 19}

Diagnosis of Hemoptysis

The diagnosis of the causes of hemoptysis can be made through history taking, physical examination, and supporting examinations such as sputum examination, radiologic testing, bronchoscopy, and bronchography. An appropriate diagnostic modality is needed in

handling hemoptysis, one of which is by bronchoscopy. Bronchoscopy is mainly performed in conditions of massive hemoptysis. The flow of diagnosis and management of massive hemoptysis can be seen in Figure 1.^{3, 7}

The patient's history taking is mainly aim to distinguish upper respiratory tract bleeding from hematemesis based on the symptoms, visible blood, and concomitant diseases in the patient. Physical examinations performed are vital signs examination, examining the nose, mouth, posterior pharynx and larynx including laryngoscopy. Examination of the neck, chest, heart, and lungs to look for possible causes of hemoptysis.^{7, 14, 20}

Investigations that can support the diagnosis of hemoptysis, namely, blood tests to evaluate hemoglobin and physiological hemostasis. In addition, many other examinations that can be done to diagnose hemoptysis include radiology, bronchoscopy, bacteriology, mycology, and serology. Radiological examination includes posteroanterior (PA) and lateral chest X-ray, computerized tomography, bronchography and arteriography.^{5, 7}

Bronchoscopy in Hemoptysis

Although there are no established criteria for bronchoscopy, some indications are widely accepted:¹⁸

a. Diagnostic

- Evaluation of symptoms (e.g. hemoptysis, local wheezing, unexplained cough)
- Evaluation of endobronchial disease (tumors, foreign bodies, strictures, fistulas, mucosal plugs, thermal, injuries)
- Evaluation of abnormal thoracic radiographs (pulmonary mass, focal or diffuse pulmonary infiltrates, pulmonary atelectasis)
- Evaluation of mediastinal and hilar lymph nodes by endobronchial ultrasound
- Staging of lung cancer

b. Therapy/intervention:

- Removal of foreign matter
- Intubation
- Endobronchial laser

Bronchoscopy can identify whether bleeding is still active and see the condition of the patient's respiratory tract. Bronchoscopy used is rigid or flexible. Rigid bronchoscopy is usually more stable and can maintain patency of the airways, but flexible bronchoscopy can be performed bedside as in patients treated in the Intensive Care Unit (ICU).⁷ The success of bronchoscopy in determining the location of bleeding depends on the severity of hemoptysis. Songara, *et al.* suggested bronchoscopy in all hemoptysis patients with normal or abnormal chest X-ray. Bronchoscopy in the case of hemoptysis can identify bronchogenic carcinoma cases of 4% to 22%.^{14, 21}

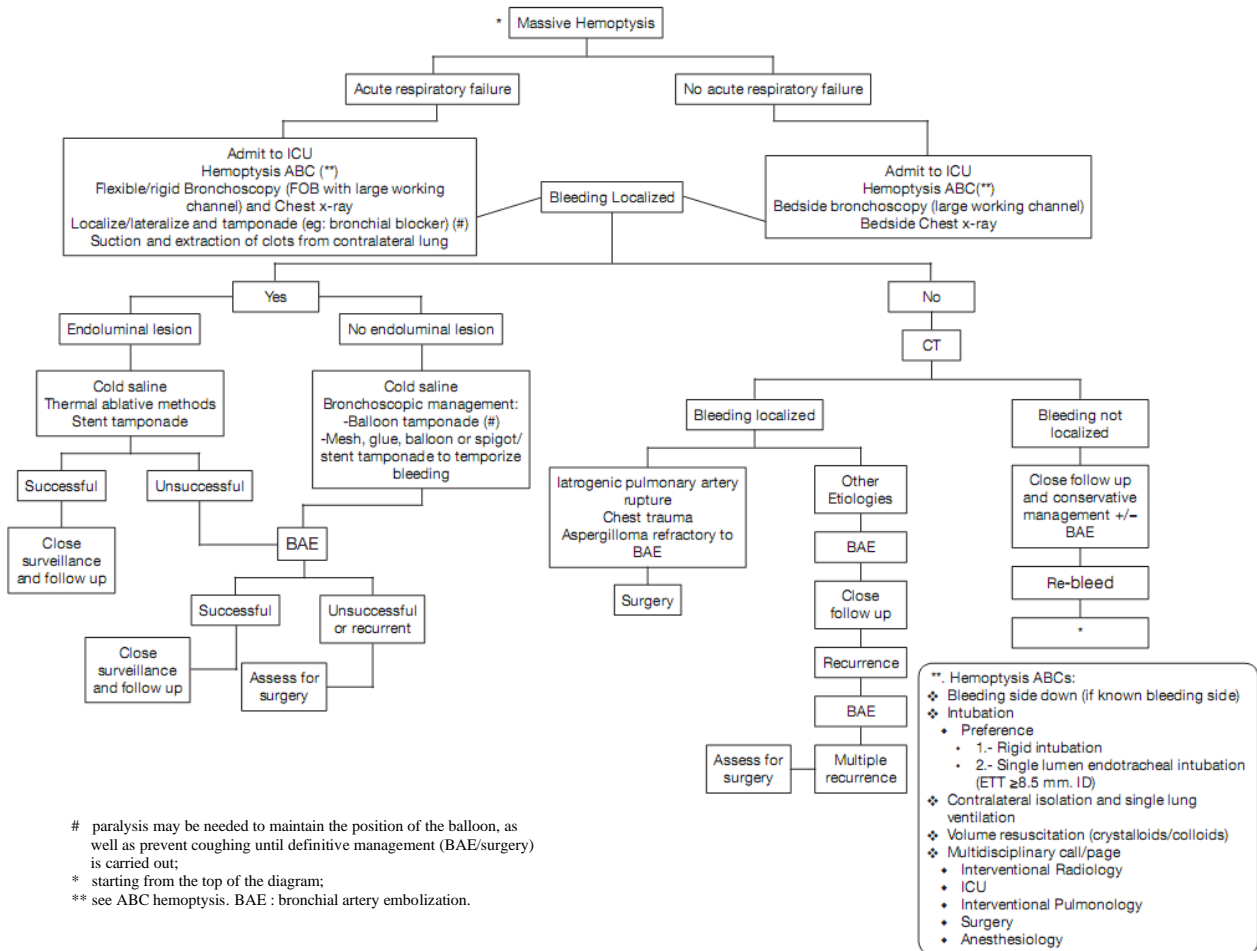


Figure 1. Diagram for a systematic approach to management of massive hemoptysis.¹⁰

Flexible bronchoscopy is more accurate in identifying the location of bleeding when bleeding is still active, with 86% success rate and has been widely used. One survey conducted by the American College of Chest Physicians (ACCP) showed in cases of respiratory emergencies, 79% of respondents preferred the use of flexible bronchoscopy through the endotracheal tube. In another survey, only 8% of respondents chose rigid bronchoscopy.^{10, 14} With bronchoscopy, in patients with endobronchial lesions tissue can be taken for examination such as culture.³

Apart from being a diagnostic tool, bronchoscopy is also used as one of the therapeutic methods to stop bleeding. The main goal is to localize the source of bleeding and if possible to control bleeding with topical or endobronchial tamponade.²² Rigid bronchoscopy is the procedure of choice for life-threatening hemoptysis, with blood expectoration >600 ml in 48 hours or 400 ml in 24 hours. This type of bronchoscopy is chosen because it can maintain airway patency and has a stronger sucking ability. This type of rigid bronchoscopy can only be done in the operating room under general anesthesia or sedation. But unfortunately, rigid bronchoscopy can only view to the depth of the major bronchi, while the lesions that are more peripheral and the upper lung lobes cannot be seen. Flexible

bronchoscopy can see bronchus 5 and 6. After the source of bleeding is seen, several therapies can be done.^{5, 14, 22}

Control of bleeding can be done in several ways, namely:^{3, 14, 17}

1. Saline solution
Using a cold saline solution with a temperature of 4°C and a volume of around 300-750 ml. This cold saline fluid can stop bleeding in patients with massive hemoptysis so that patients do not need surgery.
2. Epinephrine
Control of bleeding can also be done by administering epinephrine with a dilution of 1:1000.
3. Thrombin or thrombin-fibrinogen combination
A good response has been reported to intrapulmonary treatment with factor VII recombinant which is instilled through the bronchoscope channel in cases of diffuse alveolar bleeding.
4. Hemostatic topical
Oxidized regenerated cellulose (ORC) has water-soluble properties that are insoluble in cellulose which are known for hemostasis and wound healing properties.

5. Biocompatible glue
Endobronchial n-butyl cyanoacrylate glue is a biocompatible product that is adhesive and hardens when in contact with moisture.
6. Endobronchial stents
7. Endobronchial embolization using spigot silicon
After the bleeding segment has been identified, the spigot is grasped with biopsy forceps that have been inserted through a flexible bronchoscope. The spigot is then positioned to block the segmental airways where the bleeding originated.
8. Laser photocoagulation
9. Argon plasma coagulation
Argon plasma can be used to conduct electric current that is inserted through flexible bronchoscopy into airway lesions. This electric current will then turn into heat energy when in contact with the tumor and make the surface clot.
10. Endobronchial valves
Endobronchial valves are developed for the reduction of the lung volume in patients with severe emphysematous pulmonary hyperinflation.

Lung isolation to protect the healthy lungs can be done by several techniques, one of which is double lumen tube (DLT) (Figure 2). DLT consists of two single lumens that are bound together, with the longer lumen being positioned in the main bronchial shaft, while the shorter lumen is positioned in the trachea to ventilate the other lung. Two main advantages of DLT are that it allows lung ventilation and positioning without the need to identify the origin of bleeding. The main disadvantages of DLT include technical difficulties in the exact position and small size of the two lumens which do not allow the passage of therapeutic bronchoscope. Another technique is bronchial blocker (BB) (Figure 3). The main advantages of BB are that they can be used to isolate the lobes and to explore the source of distal bleeding.¹⁷

Endobronchial tamponade can also use a Fogarty balloon or a pulmonary artery catheter. Meanwhile, according to Radchenko, *et al.*, there are several types of tamponades including mesh, glue, ballon, spigot or stent tamponade. Successful tamponade and isolation of the bleeding site in patients with massive hemoptysis have been achieved recently by placing two stents in the airways.^{2, 10, 14, 22}

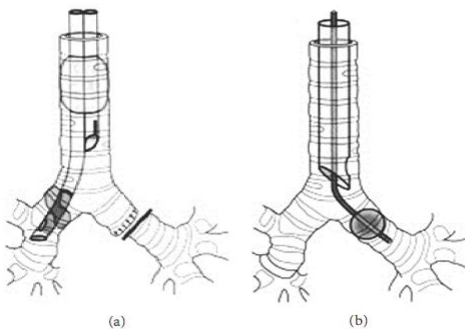


Figure 2. (a) Double-lumen tube (b) Endobronchial blockers in the left main bronchi.¹⁷

In a study conducted by Maryam, *et al.*, it showed that chest CT (computed tomography) is the best modality for finding malignancy in patients with hemoptysis. Bronchoscopy should be used after CT for direct tissue sampling.²³

CT may be comparable to bronchoscopy to identify bleeding sites (70% vs 73% each), but the literature states that CT is more efficient than bronchoscopy in identifying the cause of bleeding (77% vs 8%). Radchenko, *et al.* in his study stated that abnormalities can be found by 50% on chest CT scans with normal bronchoscopy results.¹⁰

Management of massive hemoptysis can also use cryoprobe. Cryoprobe creates a low temperature, the cooling process will flow from the high pressure to the low pressure. This will freeze the object or network that is in that section. There is a case report using cryoextraction techniques using cryoprobe and flexible bronchoscopy for blood clots in large bronchi. The case report concluded that bronchoscopy with cryoextraction is a simple and safe method for removing endobronchial blood clots to avoid invasive procedures such as rigid bronchoscopy.²⁴ Researches also stated that the use of cryotherapy and argon plasma coagulation are equally safe and effective for patients with endobronchial obstruction.

Initial bronchoscopy should be performed on massive hemoptysis after the patient is stable and the other side of the lung that is not the source of bleeding has been protected. The initial priority is the assessment of the need for intubation or mechanical ventilation, and the hemodynamic stability of the patient (Figure 1). Airway control can be achieved by flexible bronchoscopy through a large endotracheal tube or through a rigid bronchoscope. Rigid bronchoscopy is also a safe and effective way to secure the airway, because it allows ventilation and oxygenation.¹⁴

Complications of Bronchoscopy

Bronchoscopy is a very safe procedure, especially if done by trained experts with a mortality rate of no more than 0.1% and complications only occur in 8.1% of patients. Bronchoscopy can cause mucosal irritation and recurrent bleeding. Death can occur due to

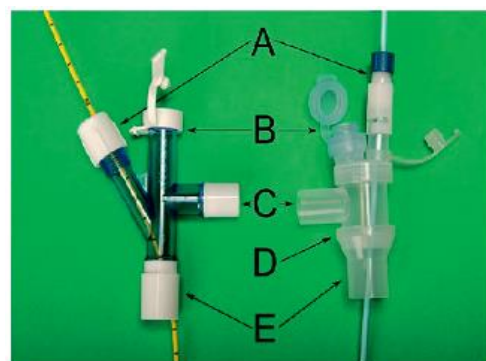


Figure 3. Endobronchial blockers (A) BB, (B) bronchoscopic ports, (C) ventilator ports, (D) three-way adapter connectors for endotracheal tubes, and (E) connected to endotracheal tubes.¹⁰

too much premedication, apnea due to bleeding, laryngeal or bronchial spasm, and cardiac arrest due to acute myocardial infarction.⁹ Other complications that can occur but are not fatal include fever (1.2-2.4%), pneumonia (0.6-6%), vasovagal reaction (2.4%), spasm of the larynx and bronchi (0.1-0.4%), arrhythmias (0.9-4%), pneumothorax (4% after transbronchial biopsy), anesthetic-related problems (0.1%), and aphonia (0.1%).²² Fever can occur in 24% of post-bronchoscopic patients and can be caused by inflammatory cytokines so it is not always an indication of infection. The incidence of transoral post-bronchoscopic bacteremia is 0.7%.^{3, 22}

Bronchoscopic contraindications must always be taken into consideration of the advantages and clinical consequences of these actions. Several factors determine, in addition to the clinical condition and prognosis of the patient, as well as technical difficulties and the skills and experience of the doctor who will perform the bronchoscopy. The relative contraindications of bronchoscopy include severe respiratory disorders where the bronchoscopy to be performed is non-therapeutic, inability to maintain a patent airway and severe cardiovascular instability, coagulopathy in patients undergoing biopsy, and poor general condition.^{14, 22}

Patients with kidney failure, blood coagulation disorders, infectious infections such as active tuberculosis, and patients who are very uncooperative, before bronchoscopy is done, it should be considered that the benefits outweigh the risks of complications. Patients with unstable respiratory status require intubation and installation of a mechanical ventilator before bronchoscopy.^{3, 22}

The most common complication is a decrease in oxygen saturation due to the decrease in tidal volume. In a study by Lindholm, *et al.* it was found that the disruption of gas exchange will decrease and slowly return to normal after bronchoscopy, and the value of PaO₂ can be reduced by 40% if during bronchoscopy, the suctioning is done. Desaturation in the form of a decrease in SpO₂ <90% is found in 20% of patients undergoing bronchoscopy at the ICU.²¹ No literature has been found to explain the specific complications that can occur in hemoptysis patients undergoing bronchoscopic procedures.

SUMMARY

The causes of hemoptysis can be broadly divided into three, namely airway disease, parenchymal disease, and vascular disease. Pathophysiology depends on the underlying disease. The diagnosis of the cause of hemoptysis is made by history taking, physical and supportive examination such as laboratory examinations, bronchoscopy, chest X-ray, computerized tomography, bronchography, and arteriography. Initial bronchoscopy should be performed on massive hemoptysis after the patient is stable and the other side of the lung that is not the source of bleeding has been protected. Aside from being a diagnostic tool, bronchoscopy is also used as a therapeutic method to stop bleeding by localizing the source of bleeding and if possible, control bleeding with topical or endobronchial tamponade.

REFERENCES

1. Koesoemoprodjo W, Meliana RY, Amin M, et al. *Buku Ajar Ilmu Penyakit Paru*. Airlangga University Press, 2019.
2. Sakr L and Dutau H. Massive Hemoptysis: An Update on the Role of Bronchoscopy in Diagnosis and Management. *Respiration; International Review of Thoracic Diseases*. 2010; 80: 38-58.
3. Yulisar RN and Kamelia T. Diagnosis dan Tata Laksana Terkini Hemoptisis. *Indonesian Journal of Chest Critical and Emergency Medicine*. 2016; 3: 57-66.
4. Irfa I, Medison I and Iryani D. Gambaran Kejadian Hemoptisis pada Pasien di Bangsal Paru RSUP Dr. M. Djamil Padang Periode Januari 2011 – Desember 2012. *Jurnal Kesehatan Andalas*. 2014; 3.
5. Ittrich H, Bockhorn M, Klose H and Simon M. The Diagnosis and Treatment of Hemoptysis. *Deutsches Arzteblatt International*. 2017; 114: 371-81.
6. Mbata G and Ewelike I. Management of Haemoptysis after Cure of Pulmonary Tuberculosis. *African Journal of Respiratory Medicine*. 2013; 8: 22-4.
7. Cordovilla R, Bollo de Miguel E, Nuñez Ares A, Cosano Povedano FJ, Herráez Ortega I and Jiménez Merchán R. Diagnosis and Treatment of Hemoptysis. *Archivos de Bronconeumología (English Edition)*. 2016; 52: 368-77.
8. *Kamus Kedokteran Dorland, Edisi 31*. EGC, 2010.
9. Gaude GS. Hemoptysis in Children. *Indian Pediatrics*. 2010; 47: 245-54.
10. Radchenko C, Alraiyes AH and Shojaee S. A Systematic Approach to the Management of Massive Hemoptysis. *Journal of Thoracic Disease*. 2017; 9: S1069-s86.
11. R D, Singh N and Gupta R. Management Issues in Haemoptysis: More Questions than Answers. *The Indian Journal of Chest Diseases & Allied Sciences*. 2014; 55: 237-8.
12. Dabo H, Gomes R, Marinho A, Madureira M, Paquete J and Morgado P. Bronchial Artery Embolisation in Management of Hemoptysis--A Retrospective Analysis in a Tertiary University Hospital. *Revista Portuguesa de Pneumologia*. 2016; 22: 34-8.
13. Larici AR, Franchi P, Occhipinti M, et al. Diagnosis and Management of Hemoptysis. *Diagnostic and Interventional Radiology (Ankara, Turkey)*. 2014; 20: 299-309.
14. Folch E. Assessment of Haemoptysis. *British Medical Journal*. 2018; 1-54.
15. Yang S, Mai Z, Zheng X and Qiu Y. Etiology and an Integrated Management of Severe Hemoptysis Due to Pulmonary Tuberculosis. *Journal of Tuberculosis Research*. 2015; 03: 11-8.
16. Abdulmalak C, Cottenet J, Beltramo G, et al. Haemoptysis in Adults: A 5-Year Study Using the French Nationwide Hospital Administrative Database. *The European Respiratory Journal*. 2015; 46: 503-11.
17. Gagnon S, Quigley N, Dutau H, Delage A and Fortin M. Approach to Hemoptysis in the Modern Era. *Can Respir J*. 2017; 2017: 1565030-.
18. Songara A, Mukherjee R, Shikha S, Solanki A, Joshi T and Patel D. To Assess the Role Fiberoptic Bronchoscopy in the Evaluation of Hemoptysis. *International Journal of Research in Medical Sciences*. 2016.
19. Noe GD, Jaffe SM and Molan MP. CT and CT Angiography in Massive Haemoptysis with Emphasis on Pre-embolization Assessment. *Clinical Radiology*. 2011; 66: 869-75.
20. Earwood JS and Thompson TD. Hemoptysis: Evaluation and Management. *American Family Physician*. 2015; 91: 243-9.

-
21. Mulyadi. Bronkoskopi Serat Optik pada Saluran Nafas Bawah. *Jurnal Kedokteran Syiah Kuala*. 2011; 11: 28-33.
22. Fatrullah SP, Iswati Y, Prasenohadi and Rasmin M. Bronkoskopi di Unit Perawatan Intensif. *Jurnal Respirologi Indonesia*. 2014; 34: 167-73.
23. Ganaie MB. *Should Bronchoscopy be Performed in All Patients with Hemoptysis and a Normal CT Chest*. 2014.
24. Sehgal IS, Dhooria S, Agarwal R and Behera D. Use of a Flexible Cryoprobe for Removal of Tracheobronchial Blood Clots. *Respiratory Care*. 2015; 60: e128-31.