

TABLE OF CONTENTS

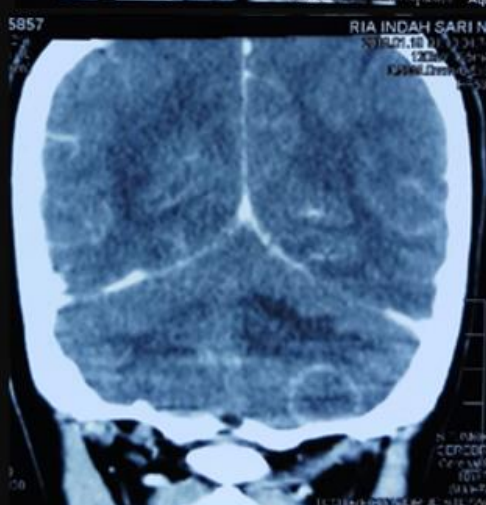
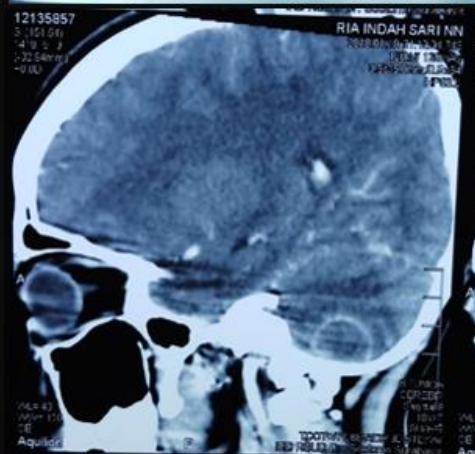
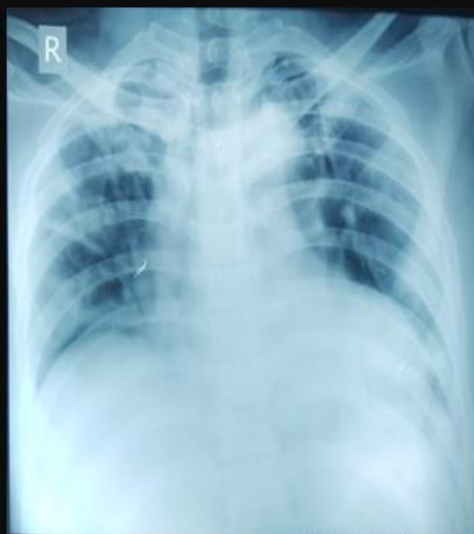Correlation of Epidermal Fibroblast Growth Factor and Clinical Improvement of Asthma in Children after Zinc Supplementation

The First Case of Covid-19 in South Kalimantan

Cerebellar Tuberculoma in a Patient with Lung Tuberculosis New Case: A Case Report

Work Lung Disease Due to Rice Dust

Management of Cough



EDITORIAL TEAM

Volume 6 No. 2 2020

Editor in Chief

*Winariani Koesoemoprodjo, dr., Sp.P(K), MARS, FCCP, Universitas
Airlangga, Indonesia*

Reviewers

Prof. Dr. Muhammad Amin, dr., Sp.P(K), Universitas Airlangga, Indonesia

Arief Bakhtiar, dr., Sp.P(K), FAPSR, Universitas Airlangga, Indonesia

Irmis Syafa'ah, dr., Sp.P, FAPSR, Universitas Airlangga, Indonesia

Dr. Daniel Maranatha, dr., Sp.P(K), Universitas Airlangga, Indonesia

Farah Fatmawati, dr., Sp.P, FAPSR, Universitas Airlangga, Indonesia

Wiwin Is Effendi, dr., Sp.P, FAPSR, Universitas Airlangga, Indonesia

Section Editor

*Isnin Anang Marhana, dr., Sp.P(K), FCCP, FISR, FAPSR,
Universitas Airlangga, Indonesia*

*Alfian Nur Rosyid, dr., Sp.P., FAPSR., FCCP, Universitas
Airlangga, Indonesia*

Managing Editor

*Laila Maulida Hidayah, S.KM., Universitas Airlangga,
Indonesia*

TABLE OF CONTENTS

| ORIGINAL ARTICLE | Pages |
|--|--------------|
| Correlation of Epidermal Fibroblast Growth Factor and Clinical Improvement of Asthma in Children after Zinc Supplementation <i>Retno Asih Setyoningrum, Anang Endaryanto, I Dewa Gede Ugrasena</i> | 61-66 |
| CASE REPORT | |
| The First Case of COVID-19 in South Kalimantan <i>Muhammad Nor, Haryati Haryati</i> | 67-74 |
| Cerebellar Tuberculoma in a Patient with Lung Tuberculosis New Case: A Case Report <i>Gemilang Khusnurrokhman, Tutik Kusmiati</i> | 75-78 |
| REVIEW ARTICLE | |
| Work Lung Disease Due to Rice Dust <i>Ariani Permatasari, Reagen Irwan Kolibu</i> | 79-84 |
| Management of Cough <i>Arief Bakhtiar, Putri Mega Juwita</i> | 85-96 |