

## CASE REPORT

# Challenging Treatment of Drug-Resistant Tuberculosis during Pregnancy: A Case Report

Ni Luh Putu Eka Arisanti<sup>1\*</sup> , Ni Putu Ayu Widiyanti<sup>1</sup> , Ni Wayan Candrawati<sup>1</sup> , Ida Ayu Jasminarti Dwi Kusumawardani<sup>1</sup> , Ida Bagus Ngurah Rai<sup>1</sup>, Made Ary Sarasmita<sup>2</sup> 

<sup>1</sup>Department of Pulmonology and Respiratory Medicine, Udayana University/Sanglah General Hospital, Denpasar, Indonesia.

<sup>2</sup>Department of Clinical Pharmacy, School of Pharmacy, Taipei Medical University, Taipei, Taiwan.

ARTICLE INFO	ABSTRACT
<p><i>Article history:</i> Received 15 June 2022 Received in revised form 19 September 2022 Accepted 26 September 2022 Available online 30 September 2022</p> <hr/> <p><i>Keywords:</i> Anti-tuberculosis drug, MDR TB, Pregnancy, Tuberculosis, Teratogenicity.</p>	<p><b>Introduction:</b> Globally, drug-resistant tuberculosis (TB) still has a high number of cases. Pregnant women are one of the high-risk populations for TB infection, especially multidrug resistance (MDR)/Rifampicin resistance (RR) TB. Physiological differences in pregnant women and the safety of the fetus make drug resistance TB treatment challenging.</p> <p><b>Case:</b> A 20-year-old woman was 22 weeks pregnant while undergoing the third month of the late phase for short-regimen. Thus, Kanamycin was one of her early phase treatment combinations during the first trimester of pregnancy. After we consulted with other departments, especially the obstetric department, we decided not to change her regimen. Her chief complaint before treatment was cough with white sputum and fluctuated shortness of breath for two months. The patient only experienced minor side effects in the early treatment phase. The patient was cured of MDR TB on 8 October 2020 at 34 weeks of gestation. Her baby was born on 10 November 2020 at 37 weeks without congenital abnormality. Observation for her baby continued by the pediatric department. The last follow-up of her baby in the middle of 2022 found no abnormality in the child's growth and development.</p> <p><b>Conclusion:</b> Drug-resistant TB therapy in pregnant women requires the collaboration of a multidisciplinary team to consider the benefits and risks of the therapy based on gestational age and disease severity.</p>

## INTRODUCTION

Globally, drug-resistant tuberculosis (TB) still has a high number of cases. Based on data from the World Health Organization (WHO) in 2020, 4.1% of TB cases in the world are multidrug resistance (MDR)/Rifampicin resistance (RR) TB cases. Its prevalence is also increasing in people with a history of previous TB treatment. India, China, and Russia have the highest MDR/RR TB cases in the world. In 2017, Indonesia had an average of 0-2.9% prevalence of MDR TB cases.<sup>1,2</sup> Pregnant women are one of the high-risk populations for TB infection, especially MDR/RR TB.<sup>3,4</sup>

MDR/RR TB treatment in pregnant women has yet to have specific guidelines.<sup>5</sup> Those related to the double-hand side have the potential to be teratogenic, less effective, and more dangerous than the first line, while on the other hand, suboptimal therapy can have harmful effects on both mother and fetus.<sup>6</sup> Various case reports reported MDR/RR TB cases in pregnant women, especially for its treatment options and outcomes. Each had different characteristics with different treatment options and outcomes. A case series report in Lima, Peru, involving 38 pregnant women with MDR TB showed

\*Corresponding author: eka.arisanti@unud.ac.id



the patient cure rate was 61%, with a death rate of 13%. Those case reports also found that four pregnancies experienced spontaneous abortion; three babies were born with low birth weight (LBW), one baby was born prematurely, and one baby experienced fetal distress.<sup>7</sup> Another case report reported two cases of MDR TB in pregnant women with different combinations of therapy and side effects. This illustrates that a suitable therapeutic option is very important for effectiveness, especially teratogenicity in the fetus.<sup>8</sup>

This case reported one case of MDR TB in a pregnant woman. It is hoped that this case report can provide an overview of treatment options and outcomes for TB infection in pregnant women.

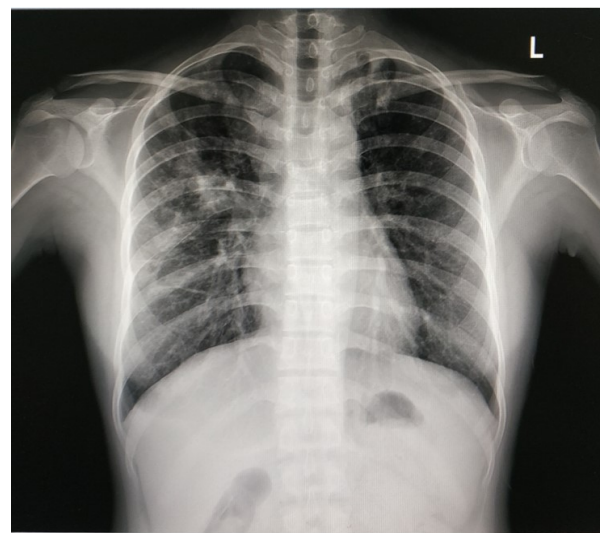
## CASE

A 20-year-old woman came to Polyclinic with a chief complaint of cough with white sputum for two months. The phlegm was sometimes green. Shortness of breath fluctuated for about two months. Chest pain and hematemesis were denied. Fever was felt in the last one month, accompanied by a weight loss of 2 kg within one month. The patient also had a lump on the right neck in the past one year, and it had worsened in one month. Night sweating was felt for one month. There was no contact history with TB patients.

On palpation of the neck, there were multiple enlargements of the right submandibular glands, with hyperemic skin tone, measuring approximately 2 cm in diameter. Lung physical examination found rhonchi on the apex of the right and left lungs. On chest radiograph, there was a consolidation of the right and left lung apex (Figure 1). Furthermore, sputum gen x-pert examination detected low MTB and Rifampicin resistance. The patient was then prepared to receive second-line anti-tuberculosis drug therapy and diagnosed with drug-resistant TB. We did not perform Line Probe Assay (LPA) and Drug Sensitivity Test (DST) because of technical problems. Thus, we decided to start drug-resistant TB treatment and observed the patient's clinical condition to know the effectiveness of the treatment.

The patient received the 2019 Indonesian short regimen protocol with the combination of Kanamycin (Km), Moxifloxacin (Mfx), Ethionamide (Eto), High Dose Isoniazid, Clofazimine (Cfz), Ethambutol (E), and Pyrazinamide (Z)/5 Mfx-Cfz-EZ. ECG evaluation, ENT examination, ophthalmology examination, and laboratory tests were performed before starting the treatment. ECG, ENT, and ophthalmology examinations were normal. Laboratory examination results were mild anemia (9.98 g/dl), negative for HIV, and negative for pregnancy test (Table 1).

TB therapy began on 13 January 2020 (Figure 2). Dosages of initial phase treatment were Km 750 mg Intramuscular, Mfx 600 mg orally, Eto 500 mg orally, High dose Isoniazid 600 mg orally, Cfz 100 mg orally, E 800 mg orally, and Z 1500 mg orally. Treatment evaluation of the early phase was performed every month. There were increasing uric acid levels in the first month of evaluation, but after being treated with Allopurinol and diet, the value was normal in the next evaluation (Table 1). Evaluation of the Acid Fast Bacilli (AFB) examination and sputum culture in the initial phase was performed every month and every two months in the late phase.



**Figure 1.** Patient chest X-ray at first visit

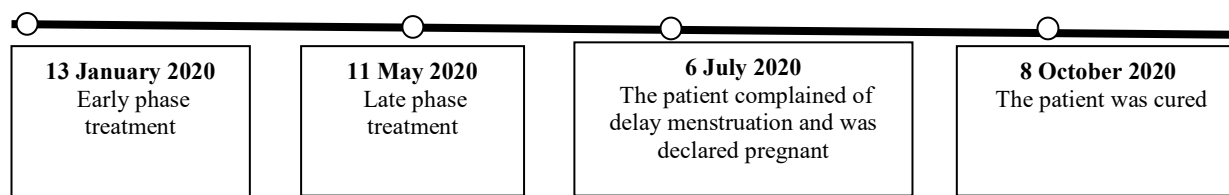


Figure 2. The patient's treatment timeline

Table 1. Pre-treatment examination and laboratory evaluation during treatment

Parameter	Baseline	1 <sup>st</sup> month	2 <sup>nd</sup> month	3 <sup>rd</sup> month	4 <sup>th</sup> month	Unit
Leukocyte	11.04	13.41	15.93	12.34	18.92	10 <sup>3</sup> /uL
Ne#	6.51	8.58	9.05	6.94	13.55	10 <sup>3</sup> /uL
Ly#	2.96	2.18	3.13	2.21	2.61	10 <sup>3</sup> /uL
Hemoglobin	9.98	10.92	10.02	9.11	10.29	g/dl
Hematocrit	32.91	37.64	33.41	30.90	35.70	%
Thrombocyte	602.1	436.7	511.20	383.90	486.80	10 <sup>3</sup> /uL
TSH	3.23					IU/ml
Free T4	1.58					ng/dl
SGOT	21.9					U/L
SGPT	10.90					U/L
Alkali phosphatase	99					U/L
Random blood glucose	77					mg/dl
Ureum	7.30	6.40	5.50	6.50	11.30	mg/dl
Creatinine	0.61	0.70	0.53	0.52	0.69	mg/dl
Uric Acid	4.5	9.1	5.4	3.1	3.9	mg/dl
Kalium	4.03	3.41	3.09	2.92	4.12	mmol/L
Natrium	136	135	134	131	135	mmol/L
Chloride	98.4					
Magnesium	2.15					
HIV	Negative					
Pregnancy Test	Negative					

The patient underwent early phase treatment for four months and continued by late phase on 11 May 2020 for five months with the combination of Mfx 600 mg orally, Cfs 100 mg orally, E 800 mg orally, and Z 1500 mg. In the third month of the treatment, the patient complained that she had not had menstruation for four months. After an examination by an obstetrician, it was found that the patient was 22 weeks pregnant and late-phase treatment was continued with regular monitoring from the obstetrician. On 8 October 2020, the patient completed the short-term drug-resistant TB treatment regimen with a negative smear and sputum culture. The patient gave birth on 10 November 2020 at 37 weeks without congenital abnormality. The pediatric department continued the observation of the baby, and there was no growth and development abnormality reported up to one year old. At the last follow-up, in the middle of 2022, the patient's child showed normal development, especially speaking ability. Although there was no specific examination for hearing loss, normal speaking ability, good focus, and concentration while

communicating in a two-year-old can be a good sign for normal hearing function. The patient was informed about the publication of her case, and she agreed by signing informed consent.

## DISCUSSION

The patient in this case came to the hospital for the first time with chief complaints of productive cough for two months, shortness of breath, weight loss, night sweating, and tenderness lump in the right neck. Clinical symptoms of TB in pregnant women are similar to those in general patients.<sup>9,10</sup> Physical examination revealed multiple right submandibular lymphadenopathy and rhonchi at the right and left lung apex. Chest radiograph showed consolidation of the right and left lung apex. Physical examination in patients with drug-resistant TB can vary according to the location of infection and severity of lung damage. In this patient, multiple lymphadenopathies of the right submandibular lymph

node were found and suspected to be due to TB lymphadenitis. Chest radiograph showed a typical feature of TB.<sup>11</sup> Mild anemia in this patient could be caused by chronic diseases like TB. A study at Hasan Sadikin Hospital in Bandung found that the prevalence of anemia in adult pulmonary TB patients was 63.62%, which was dominated by mild microcytic hypochromic anemia.<sup>12</sup> In the literature review and meta-analysis article, the prevalence of anemia in adult TB patients was 61.53% and dominated by mild anemia (35.67%).<sup>13</sup>

Based on clinical manifestation and supporting examinations, the patient was suspected of being infected with TB, and a Gen-Xpert sputum examination was performed detecting medium MTB and Rifampicin resistance. The patient was given short-regimen treatment. Administration treatment was performed after an LPA and matched patient criteria for a short regimen. At the beginning of the treatment, the patient met the criteria for a short-regimen treatment.<sup>5</sup> We could not do LPA and DST for the patient because of technical problems. Therefore, we only diagnosed the patient as drug-resistant TB or Rifampicin-resistant TB. Based on discussion and evaluation, we decided to start the treatment with a drug-resistant TB regimen without LPA and DST results to prevent more severe symptoms while monitoring the subjective and objective clinical presentation of the patient. Due to a good therapeutic response, we continued the regimen. We frequently did not do a pregnancy test because there was no recommendation for frequent screening by pregnancy test in drug resistance TB guidelines in Indonesia unless there is an indication.<sup>5</sup>

In the 7<sup>th</sup> month of the treatment, the patient was declared pregnant while undergoing a short regimen with a combination of Mfx 600 mg orally, Cfs 100 mg orally, E 800 mg orally, and Z 1500 mg orally. After re-evaluation and consultation with the obstetrician, the patient was given information about the risk and benefits of the treatment and decided to continue her treatment regimen. Re-evaluation means evaluating the patient's clinical condition, including therapeutic response from the regimen. The severity of the disease and history of side effects are also important to decide the therapy. Consultation with the obstetrician was performed to know the age of the pregnancy, the condition of the fetus, and to collaborate on monitoring the patient during the

therapy. The age of the pregnancy and fetal condition are two factors that contribute to decision-making.

Things related to drug-resistant TB treatment in pregnant women are like a double-edged sword. On the one side, second-line TB drugs are potentially teratogenic, less effective, and more dangerous than first-line drugs, while on the other side, suboptimal therapy can have harmful effects.<sup>14,15</sup> Most second-line TB drugs have category C for pregnant women, except for aminoglycosides which are category D.<sup>6,16</sup> Ethambutol is one of the second-line drugs in category B. Most of them have side effects if used at the organogenesis stage or trimester one of the pregnancy.<sup>17,18</sup> We had to decide when to begin the treatment with the best drug combination regimen, which had more potential but was less toxic in each pregnancy. In this patient, we decided to continue the treatment such as Mfx 600 mg orally, Cfs 100 mg orally, E 800 mg orally, and Z 1500 mg because the patient, while declared pregnant in her second trimester, which is teratogenicity of TB treatment, was low after organogenesis stage or first trimester. Furthermore, evaluation from the obstetric department reported good condition of the fetus. After discussing with the patient the risk and benefits of the treatment, the patient decided to continue the treatment. Consulting with a neonatologist is also important to discuss the further risk of the side effects and the preparation after giving birth. Therefore, drug-resistant TB therapy in pregnant women requires the collaboration of a multidisciplinary team such as obstetricians, neonatologists, pulmonologists, and public health experts.<sup>6,15</sup>

Several articles reported cases of drug-resistant TB in pregnant women, the treatment options, and the outcomes. One article reported four cases of MDR TB in patients who were declared pregnant while undergoing therapy. The first case was a 24-year-old woman in the second trimester of pregnancy while undergoing 36 months of the individual treatment regimen with a combination of Amikacin, Ethionamide, Ciprofloxacin, Cycloserine, PAS, Clofazimine, and Amoxicillin-Clavulanic Acid. There was no change in the treatment regimen or complications during the pregnancy. The baby was born healthy, but the mother failed to be treated and died after a right upper lobe lobectomy. In the second case, the patient was in the second trimester of pregnancy

while undergoing 16 months of MDR TB treatment with the combination of INH, Rifampin, Ciprofloxacin, Ethionamide, Cycloserine, and Amoxicillin-Clavulanic Acid. During pregnancy, the doctor decided to decrease the dose of Cycloserine and stopped Ethionamide. The outcome was no complications in the pregnancy, the baby was born healthy, and the mother was cured.<sup>10</sup>

In the third case, the patient was in the second trimester of pregnancy while undergoing the first month of MDR TB treatment with a regimen combination of Capreomycin, Ofloxacin, Ethionamide, Cycloserine, PAS, Clofazimine, Amoxicillin-Clavulanic Acid. The therapy was postponed for one week and then changed according to the results of DST to a combination of Capreomycin, INH, Ethionamide, Ofloxacin, Ethionamide, Cycloserine, and PAS. It was found that there were no complications in the pregnancy, the baby was born healthy, and the mother was confirmed to be healthy. In the fourth case, the patient was declared pregnant during the 9<sup>th</sup> month of MDR TB treatment with the regimen combination of Capreomycin, Pyrazinamide, Ciprofloxacin, Protionamide, Cycloserine, and Amoxicillin-Clavulanic Acid. Subsequently, the treatment was postponed for three weeks, and the therapy was continued with a combination of Pyrazinamide, Ciprofloxacin, Cycloserine, and Amoxicillin-Clavulanic Acid regimens. There were no pregnancy complications, the baby was born healthy, and the mother got a negative culture result in the 16<sup>th</sup> month of treatment.<sup>19</sup>

A case report regarding MDR TB in pregnant women involved a 32-year-old woman with MDR TB and type 2 DM, declared pregnant in the first trimester while undergoing 3<sup>rd</sup>-month follow-up TB treatment with Cycloserine, Ethambutol, Levofloxacin, and Ethionamide regimens with the outcome that there was no evidence of transmission of TB infection from the mother to the baby. The mother was healthy and was cured one month after giving birth, but it was reported that the patient's baby had palatoschisis associated with uncontrolled type 2 DM during the pregnancy.<sup>20</sup>

An article in Indonesia reported two cases of MDR TB in pregnant women. Both cases were diagnosed with MDR TB in the third trimester of pregnancy. The first patient received a combination therapy of Ethionamide, Cycloserine, Levofloxacin, Pyrazinamide, and Ethambutol. The second patient received a combination therapy of Ethionamide, Cycloserine,

Levofloxacin, and Pyridoxine. The baby from the first case was born with LBW (2,350 gr), 36 weeks at birth, and without congenital abnormalities. The baby from the second case was born with a body weight of 2,600 grams, 36 weeks at birth, and without congenital abnormalities. A study by Palacios, *et al.* (2009) about MDR TB therapy in pregnant women in Peru showed that most patients recovered and gave birth to healthy babies without congenital abnormalities. In the study, pregnant women received a standard combination regimen of at least five effective drugs, including quinolone and parenteral drugs (Streptomycin, Kanamycin, Capreomycin, and Amikacin). The parenteral drugs were continued for at least six months after culture conversion.<sup>8</sup>

The patient was cured and finished the treatment after undergoing second-line TB treatment for nine months with a negative result for AFB sputum examination and sputum culture. During the treatment, the patient only experienced mild side effects in the form of nausea and vomiting in the early phase of the treatment, which could overlap with symptoms of emesis in pregnancy. Laboratory evaluation during the treatment was found to be within normal limits. Evaluation of the treatment in the patient was performed by looking at clinical, AFB results, culture results, and laboratory tests like complete blood, liver function, kidney function, and electrolytes. Based on 2019 drug-resistant TB treatment guidelines, evaluation of the treatment with a short-term regimen consists of 1) clinical and physical examination performed every month; 2) AFB examination performed every month in the early phase and every two months in the late phase; 3) sputum culture performed every month in the early phase and every two months in late phase; 4) ECG examination performed every month; and 5) evaluation of kidney function and electrolytes performed every month in the early phase.<sup>5</sup>

There are various side effects or adverse events that can arise during drug-resistant TB treatment.<sup>5</sup> Each second-line TB drug conveys a different risk of side effects. Ethionamide, PAS, Pyrazinamide, Ethambutol, and Levofloxacin have a risk of side effects such as nausea and vomiting. Vertigo can be caused by Aminoglycosides and Ethionamide drugs.<sup>21,22</sup> Other side effects include visual disturbances, impaired liver function, psychotic disorders, hypothyroidism, and seizures.<sup>22</sup>

Hearing loss can be caused by the Aminoglycoside group.<sup>22,23</sup> Aminoglycosides have a narrow therapeutic index. Thus, long-term use requires monitoring serum levels to prevent dose-dependent ototoxicity. While treating MDR-TB with Kanamycin, hearing loss can occur anytime, but its severity depends on the duration and dose. Hearing loss is sensorineural, predominantly bilateral, and starts from high frequencies to develop into lower conversational-level frequencies. Pathogenesis of hearing loss begins with the penetration of aminoglycosides in the inner ear fluid from the organ of Corti and sensory hair cells, then reacts with heavy metal ions to form highly reactive free radicals that destroy stereocilia sensory hair cells. However, the risk of ototoxicity only occurs in 25%-60% of MDR TB patients receiving Aminoglycoside therapy. A case report in Ethiopia reported an MDR-TB patient with Kanamycin as a combination therapy regimen. In that case, the patient had bilateral hearing loss and vertigo at two and half months of the therapy.<sup>24</sup> It is different from this case report, on the basic examination of this patient, there were no abnormalities in the audiometric examination. During monitoring, there were no symptoms of hearing loss.

Evidence for the teratogenicity of Kanamycin in the fetus is still limited. Kanamycin at a dose of 200 mg/kg per day given to pregnant genuine pigs produces harmful histomorphologic effects on the fetus, especially on the organ of Corti. Kanamycin has been documented to cross the placental barrier.<sup>25</sup> There was also evidence that the teratogenicity of Kanamycin increases with increasing trimesters. Raphael, *et al.* showed that histopathologically, ototoxicity of Kanamycin generally occurs when administered in late trimester mothers. This can be explained by the mechanism of increased placental permeability and rapid maturation of cochlear function in the last trimester of pregnancy. Whereas in the first trimester, the epithelial tissue of the cochlear duct has not yet differentiated and permeability of the placenta is still low. In the second trimester, the organ of the Corti has not yet reached functional maturity, and metabolic activity has not occurred. In this case, the previous mechanism could explain the possible absence of teratogenicity in the patient's fetus. A case report by Jones reported a pregnant woman who received Kanamycin and experienced total deafness. Nevertheless, at three years old, her child did not experience any abnormalities.<sup>26</sup>

Based on the mentioned articles, we can understand that the outcome of TB treatment in pregnant women, especially drug-resistant TB, depends on various factors. There were factors from the mother, such as a history of comorbidity and disease severity, pregnancy factor, and medication factor. Comorbidity history is very important, and consultation with other appropriate departments should be performed. Uncontrolled comorbidity like DM can be related to the prognosis of the mother and the fetus. Disease severity is also related to regimen combination and prognosis. Therefore, a multidisciplinary approach is important. Pulmonologists have to discuss with other departments such as Obstetrics and Gynecology to know the age of the pregnancy, the fetus's condition, and planning to begin the treatment and monitoring during the treatment. Consultation with a neonatologist is also important to know the probability of side effects. Thus, we can prepare and inform the patient.

The medication timeline of the mother is important to prepare for monitoring the fetus after birth. The age of pregnancy and fetus condition are very important for deciding combination treatment. The risk of bacterial spreading, especially in the patient's environment, must also be assessed by a public health expert to support good treatment outcomes. The side effects of each TB drug are important to know by doctors and the patient. The earlier the finding of side effects, the better prognosis will be. Thus, information about side effects to the patient and intensive monitoring of side effects of TB medication to the mother and the fetus will help us to prevent severe side effects and ensure a better outcome for the fetus and a good outcome of disease treatment.

This case report showed us more about problems we can encounter in treating pregnant women with drug-resistant TB, how to resolve the problems, and figure out the outcomes. The limitation of this case was that we did not do LPA and DST because of technical problems. Thus, we could not know the specific type of resistance in this patient. Furthermore, a case series in the future will be good to make a comparison.

## CONCLUSION

Drug resistance therapy in pregnant women must consider various factors and involve multidisciplinary collaboration to determine the appropriate combination of therapy based on gestational age and disease severity.

### Consent

Written informed consent was obtained from the patient.

### Acknowledgments

We would like to thank the patient who consented their case for a scientific report.

### Conflict of Interest

The authors declared there is no conflict of interest.

### Funding

This study does not receive any funding.

### Authors' Contributions

Writing the manuscript, collecting patient data: NLPEK, NPAW, AJDK. Reviewing and revising: NLPEK, NWC, IAJDK, IBNR, MAS. All authors contributed and approved the final version.

### REFERENCES

- World Health Organization (WHO). *Surveillance of Drug-Resistant TB*. Geneva, <https://www.who.int/teams/global-tuberculosis-programme/diagnosis-treatment/treatment-of-drug-resistant-tb/surveillance-of-drug-resistant-tb> (2020, accessed October 14, 2020).
- Widiasari NPA, Kusumawardani IAJD, Rai IBN. Descriptive Study: Level of Communities Knowledge and Perception about Tuberculosis (TB) in Denpasar, Bali. *Respiratory Science* 2020; 1: 1–14.
- Jonsson J, Kühlmann-Berenzon S, Berggren I, *et al*. Increased Risk of Active Tuberculosis during Pregnancy and Postpartum: A Register-Based Cohort Study in Sweden. *Eur Respir J* 2019; 1901886.
- Kraus TA, Engel SM, Sperling RS, *et al*. Characterizing the Pregnancy Immune Phenotype: Results of the Viral Immunity and Pregnancy (VIP) Study. *J Clin Immunol* 2012; 32: 300–311.
- Kementerian Kesehatan Republik Indonesia. *Panduan Pelayanan Tuberculosis Resisten Obat untuk Fasilitas Pelayanan Kesehatan*. Jakarta, 2019.
- Rohilla M, Joshi B, Jain V, *et al*. Multidrug-Resistant Tuberculosis during Pregnancy: Two Case Reports and Review of the Literature. *Case Rep Obstet Gynecol* 2016; 2016: 1–4.
- Palacios E, Dallman R, Muñoz M, *et al*. Drug-Resistant Tuberculosis and Pregnancy: Treatment Outcomes of 38 Cases in Lima, Peru. *Clin Infect Dis* 2009; 48: 1413–1419.
- Yusuf D, Lisnawati Y. Luaran Bayi dari Ibu dengan Tuberculosis Resistan Multi Obat. *Journal of the Indonesian Medical Association*; 69. Epub ahead of print October 2, 2019.
- Direktorat Jenderal Pencegahan dan Pengendalian Penyakit. *Pelatihan Penanggulangan Tuberculosis Bagi Petugas Kesehatan di Fasilitas Kesehatan Tingkat Pertama dan Fasilitas Kesehatan Rujukan Tingkat Lanjutan*. Jakarta, 2018.
- Loto O, Ibraheem A. Tuberculosis in Pregnancy: A Review. *J Pregnancy* 2012; 2012: 379271.
- al Ubaidi BA. The Radiological Diagnosis of Pulmonary Tuberculosis (TB) in Primary Care. *J Fam Med Dis Prev*; 4. Epub ahead of print January 1, 2018.
- Adzani M, Dalimoenthe NZ, Wijaya I. Profile of Anemia on Lung Tuberculosis at Dr. Hasan Sadikin General Hospital and Community Lung Health Center Bandung. *Althea Medical Journal* 2016; 3: 137–140.
- Barzegari S, Afshari M, Movahednia M, *et al*. Prevalence of Anemia among Patients with Tuberculosis: A Systematic Review and Meta-Analysis. *Indian J Tuberc* 2019; 66: 299–307.
- Ormerod P. Tuberculosis in Pregnancy and the Puerperium. *Thorax* 2001; 56: 494.
- Nahid P, Dorman SE, Alipanah N, *et al*. Official American Thoracic Society/Centers for Disease Control and Prevention/Infectious Diseases Society of America Clinical Practice Guidelines: Treatment of Drug-Susceptible Tuberculosis. *Clin Infect Dis* 2016; 63: e147–e195.
- Bothamley G. Drug Treatment for Tuberculosis during Pregnancy: Safety Considerations. *Drug Saf*; 24.
- Stephanie P, Evelin W, Reinhard M, *et al*. Observational Cohort Study of Pregnancy Outcome after First-Trimester Exposure to Fluoroquinolones. *Antimicrob Agents Chemother* 2014; 58: 4392–4398.
- Drobac PC, del Castillo H, Sweetland A, *et al*. Treatment of Multidrug-Resistant Tuberculosis during Pregnancy: Long-Term Follow-Up of 6 Children with Intrauterine Exposure to Second-Line Agents. *Clin Infect Dis* 2005; 40: 1689–1692.
- Shin S, Guerra D, Rich M, *et al*. Treatment of Multidrug-Resistant Tuberculosis during Pregnancy: A Report of 7 Cases. *Clin Infect Dis* 2003; 36: 996–1003.
- Alaga A, Fairous M, Razul M. MDR TB Treatment of An Expectant Mother – A Case Report. *J Lung Health Dis*; 4. Epub ahead of print March 13, 2020.
- Park WS, Kang HY, Kim SJ. Notified Tuberculosis Status in Korea. *Public Health Weekly Report* 2015; 9: 342–345.
- Yang T-W, Park HO, Jang H, *et al*. Side Effects Associated with the Treatment of Multidrug-Resistant Tuberculosis at a Tuberculosis Referral Hospital in South Korea: A Retrospective Study. *Medicine* 2017; 96: e7482.

- 
23. Amber A, S CG, Min KO, *et al.* Adverse Effects and Choice between the Injectable Agents Amikacin and Capreomycin in Multidrug-Resistant Tuberculosis. *Antimicrob Agents Chemother* 2017; 61: e02586-16.
  24. Mantefardo B, Sisay G. Case Report: Kanamycin Ototoxicity and MDR-TB Treatment Regimen. *Int Med Case Rep J* 2021; 14: 815.
  25. Holdiness MR. Teratology of the Antituberculosis Drugs. *Early Hum Dev* 1987; 15: 61–74.
  26. Raphael Y, Fein A, Nebel L. Transplacental Kanamycin Ototoxicity in the Guinea Pig. *Arch Otorhinolaryngol* 1983; 238: 45–51.