

## CASE REPORT

# Swine Flu (Influenza A, H1N1pdm2009) Infection on an Elderly Patient with Chronic Obstructive Pulmonary Disease (COPD): A Case Report

Anak Agung Bagus Bramardipa<sup>1</sup> , Anak Agung Gde Upeksha<sup>2</sup> 

<sup>1</sup>Internship Doctor, Department of Pulmonology and Respiratory Medicine, Bali Mandara Hospital, Denpasar, Indonesia.

<sup>2</sup>Department of Pulmonology and Respiratory Medicine, Bali Mandara Hospital, Denpasar, Indonesia.

ARTICLE INFO	ABSTRACT
<p><i>Article history:</i> Received 15 December 2022 Received in revised form 2 May 2023 Accepted 26 May 2023 Available online 31 May 2023</p> <p><i>Keywords:</i> Infectious disease, Oseltamivir, Swine flu.</p> <p><i>Cite this as:</i> Bramardipa AAB and Upeksha AAG. Swine Flu (Influenza A, H1N1pdm2009) Infection on an Elderly Patient with Chronic Obstructive Pulmonary Disease (COPD): A Case Report. <i>J Respi</i> 2023; 9: 136-140.</p>	<p><b>Introduction:</b> Influenza is among the most common causes of respiratory illness worldwide. In April 2009, a novel H1N1 virus of swine origin was spreading among individuals, and within days became a pandemic called H1N1pdm2009. Years after the pandemic, H1N1pdm2009 is now a typical seasonal flu that manifests as flu-like symptoms, just like other influenza. Swine flu is a self-limiting disease that does not need necessary antiviral treatment unless it displays moderate presentation or in an individual with comorbidities.</p> <p><b>Case:</b> A 71-year-old man came to the emergency room with a chief complaint of shortness of breath. Symptoms started with common flu one week before admission and worsened before the admission date. In the emergency room, the patient looked lethargic, had tachypnea, and had low saturation. His oxygen saturation was 88% on room air and 99% using a non-rebreathing mask of 8 liters per minute. Ronchi was heard on both sides of the lungs. He has regular visits for his chronic obstructive pulmonary disease (COPD). Multiple investigations included thorax imaging, complete blood count, and naso-oropharynx polymerase chain reaction (PCR). Swab results indicated an influenza-A H1N1pdm2009 infection with no COVID-19 co-infection. During hospitalization, the patient received a 75 mg dose of oseltamivir twice a day and other supportive treatment. The patient was discharged after five days of oseltamivir therapy with improved conditions.</p> <p><b>Conclusion:</b> Swine flu manifestation is similar to another influenza. However, this virus can show moderate or severe presentation in patients with comorbidities. Oseltamivir administration was given for five days and helped improve the patient's condition.</p>

## INTRODUCTION

In 2009, a new variant of influenza causing cases of respiratory problems emerged and spread quickly worldwide. Later, the World Health Organization (WHO) declared this condition as a global pandemic. This virus was later identified as Influenza A (H1N1pdm09), a triple-reassortant virus from avian, human, and swine flu viruses.<sup>1-3</sup> There were around 150,000-575,000 people who died from this H1N1pdm09 virus in the first year of this pandemic, according to Centers for Disease Control and Prevention (CDC).<sup>4,5</sup>

H1N1pdm09 is transmitted through the airways by contact with aerosol. This disease is a self-limiting disease lasting for around seven days. However, patients with chronic lung disease or pregnant women are vulnerable to severe complications and may need hospitalization if severe symptoms are found.<sup>5,6</sup> Unlike the typical seasonal influenza, swine flu H1N1pdm09-related deaths were primarily found in younger people,<sup>7</sup> as the elderly had been exposed to the previous type of H1N1 and developed immunity. Hence, they were less affected, while younger individuals had little or no prior immunity. However, if this virus infects the elderly, the outcome will likely be bad as they are vulnerable.<sup>1,4,8,9</sup>

\*Corresponding author: [bramardipa@gmail.com](mailto:bramardipa@gmail.com)

Jurnal Respirasi (Journal of Respiratory), p-ISSN: 2407-0831; e-ISSN: 2621-8372.

Accredited No. 200/M/KPT/2020; Available at <https://e-journal.unair.ac.id/JR>. DOI: [10.20473/jr.v9-i2.2023.136-140](https://doi.org/10.20473/jr.v9-i2.2023.136-140)



This work is licensed under a Creative Commons Attribution-Share Alike 4.0 International License.

## CASE

A 71-year-old man came to the emergency room accompanied by his family with a chief complaint of shortness of breath. Around one week before the admission, the patient had a cough and runny nose that worsened daily, followed by fever and loss of appetite.

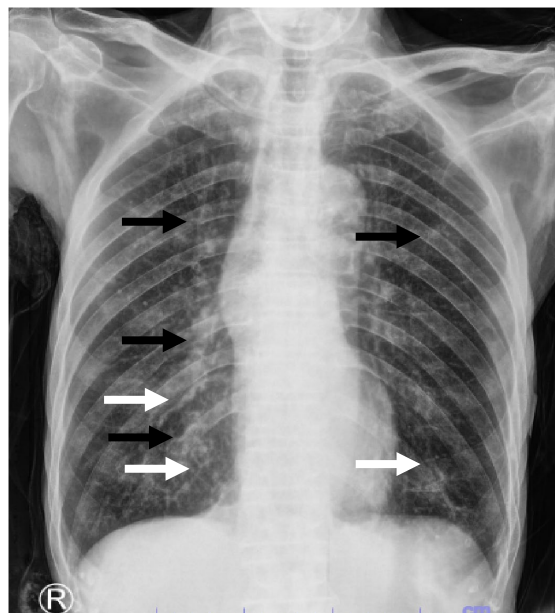
In the emergency room, the symptoms persisted, and the patient started to feel shortness of breath with a respiratory rate of around 26 times per minute. Oxygen saturation was 88%. The patient used a 10 lpm non-rebreathing mask to keep the saturation at 99%. His blood pressure was 108/64 mmHg, with a pulse rate around 94 bpm. In general, the patient looked lethargic. From auscultation, rhonchi were heard on both lungs.

The patient worked as a farmer with daily activities mainly on his farm and mostly contacted with his family. No animals, such as birds, chickens, or pigs, were kept in the house. He was an active smoker who smoked up to four cigarettes daily from his 20s to his 65s. Alcohol history was denied. In the past, the patient had routine visits to a pulmonologist due to chronic obstructive pulmonary disease (COPD) and routinely used his corticosteroid-beta agonist inhaler. Seven months ago, he had to be hospitalized due to COVID-19. History of allergy was denied. No other families showed similar symptoms except his wife, who possessed a productive cough and mild dyspnea with no fever.

Several examinations were planned, including polymerase chain reaction (PCR) swabs for respiratory pathogens panel checks, complete blood tests, and thorax roentgen. Influenza A H1N1pdm2009 was detected from a PCR swab. The thorax roentgen showed increased bronchovascular markings, consolidation, hyperaerated lung, and aortic atherosclerosis (Figure 1). There were no significant abnormalities in the complete blood count result, where the white blood cell was  $6.54 \times 10^3/\mu\text{L}$ , hemoglobin was 13.3 g/dL, and platelets were  $363 \times 10^3/\mu$ .

The patient was then admitted to a non-COVID-19 isolation room and given oseltamivir 75 mg twice a day for five days as a therapy along with other supportive treatments, such as intra vena (IV) fluids and oxygens, and procedures, such as nebulizations (as needed) if the patient felt shortness of breath. The administration of oseltamivir was planned for five days following the guideline's recommendation. Two days before the hospitalization, the patient's condition was improving. No shortness of breath or cough and fever were felt. However, his oxygen saturation remained unstable and still depended on oxygen supplementation. On the fourth day of hospitalization, the oxygen flow was tapered down, and the patient showed no respiratory problems or desaturation. The patient was

discharged on the seventh day of hospitalization with 98% oxygen saturation in room air and other vital signs within normal limits.



**Figure 1.** Patient's thorax roentgen. An increase and thickening in bronchovascular marking (black arrow), consolidation sign (white arrow), and slightly flattened diaphragm as in hyperaerated lung were found from the thorax roentgen.

## DISCUSSION

The patient came to the emergency room with symptoms of influenza-like illness (ILI), shortness of breath, cough, fever, and runny nose. During the COVID-19 pandemic, all individuals showing ILI symptoms are classified as suspected cases of COVID-19 and are eligible for PCR tests to confirm the diagnosis.<sup>10,11</sup> The chest X-ray showed an increased bronchovascular mark and consolidation, further strengthening the COVID-19 suspicion. However, from the respiratory pathogens panel checks result, which was the PCR swab that the patient's family chose, no SARS-CoV-2 was detected. Instead, Influenza A H1N1pdm2009 was found.

Swine flu (H1N1pdm09) is caused by the influenza A virus of the orthomyxoviridae family. This virus results from a triple-reassortant virus from avian, human, and swine flu viruses that mingle and swap their genetic material in pigs and has become a human pathogen.<sup>2,3,12</sup> The manifestations of swine flu are similar to other influenza viruses, which include fever, cough, pain in the throat, and breathlessness. Other manifestations, such as the rise in respiratory rate and hypoxia, may be found where the white blood cell (WBC) count is commonly in a normal range.<sup>11</sup> PCR was used to confirm the diagnosis of swine flu, where the optimal specimen for adults could be obtained from a nasopharyngeal swab.<sup>12</sup>

An influenza virus displays antigenic diversity by 1) antigenic shift due to Ha and Na mutation in which they produce a new antigenic variant; Hemagglutinin (Ha) and Neuraminidase (Na) are proteins that play an important role in avoiding immune response, the results of mutation are later able to avoid pre-existing host defense; 2) antigenic shift that gained after reassortment of genes segment between two or more viruses in the same host and resulting in a new variant.<sup>12,13</sup> When a new variant of the influenza virus is created, it will spread quickly to the public as the herd community has yet to be formed.<sup>3</sup> Swine flu H1N1pdm09 has become a seasonal virus and circulates publicly.<sup>14,15</sup>

The pathogenesis of H1N1pdm09 starts in the columnar epithelial cells of the respiratory tract. This virus will replicate along the epithelial cells of the respiratory tract. After they invade the epithelial cells, replication occurs, producing virions and toxins. The release of infectious budding will attract the inflammation process, which destroys epithelium cells.<sup>3,16</sup>

Swine flu has a low mortality rate. Death usually occurs because bacterial co-infection causes severe pneumonia and acute respiratory distress syndrome.<sup>3,17,18</sup> Secondary bacterial infections are mostly found and developed later in vulnerable patients. Infection with the swine flu virus will disrupt the integrity of the respiratory tract. Viral infection also weakens the immune system causing individuals to be vulnerable to bacterial infection.<sup>19</sup> Chronically ill people are more susceptible to the swine flu.<sup>5</sup> In this instance, the patient had an underlying medical condition in his history of routine visits to a pulmonologist due to COPD. The COPD history matched the thorax roentgen result, which displayed a hyperaerated lung.

COPD is a progressive inflammatory lung disease that causes a limitation in the airflow. COPD patients face an immune dysfunction that weakens their alveolar macrophages, mucociliary clearance, T-cells, and antiviral molecules production, such as sIgA and IFN- $\beta$ , and these problems lead patients to a condition in which they are vulnerable to many viral and bacterial infections.<sup>20,21</sup>

In this case, the patient suffered from a swine flu viral infection. As the inflammation grows progressively in COPD patients, corticosteroids are helpful to decrease the destructive effect of inflammation and mitigate the process by downregulating mast cells, neutrophils, macrophages, T-cells, and other inflammatory cytokines activities. However, the beneficial effects of corticosteroids could lead to a higher susceptibility to respiratory infections.<sup>22</sup> COPD and its therapy could lead individuals to a higher risk of respiratory disease. Therefore, physicians should continually educate COPD patients to be extra cautious

about their condition to avoid further worsening conditions.

The patient was hospitalized in a non-COVID-19 isolation room and received oseltamivir for five-day treatment. The managements of swine flu consist of medicamentosa and non-medicamentosa (Table 1).<sup>23,24</sup> For mild cases, supportive therapy is enough with no antiviral prescription. Antiviral treatment is not necessary for healthy individuals because this infection is a self-limiting disease, but in a severely ill patient or patient with comorbidities, neuraminidase inhibitors, such as oseltamivir, are the first line of influenza A and B treatment. The drugs work by competitively inhibiting neuraminidase on the virus surface and preventing the new virus from being released from infected cells. Neuraminidase inhibitor reduces the duration of illness by 30% if given within 36 hours of symptoms.<sup>13</sup>

The dosage of oseltamivir (Table 1) was 75 mg and given twice daily for five days. It is recommended to be delivered within 36-48 hours of onset.<sup>3,5,24</sup> Some side effects of oseltamivir, even though they are barely found, include nausea, vomiting, and vertigo.<sup>14</sup> The patient received 75 mg twice daily for five days, along with other supportive therapies, and showed improvement on the second day of the oseltamivir treatment. The symptoms started to vanish on the fourth day.

**Table 1.** Brief strategy for swine flu management<sup>24</sup>

Medicamentosa
Oseltamivir within 48 hours of onset
Supportive and symptomatic therapy
Antibiotics (if needed)
Non-medicamentosa
Nutrition therapy
Rest

**Table 2.** Oseltamivir recommendation dose<sup>24</sup>

Oseltamivir	
Oseltamivir is prescribed for one year for older hospitalized patients or individuals with a high risk of complications. For individuals $\geq 14$ years old, the recommended dose is 75 mg twice daily for five days. For infants older than one year,	
<15 kg	30 mg twice a day for five days
15–23 kg	45 mg twice a day for five days
24–40 kg	60 mg twice a day for five days
>40 kg	75 mg twice a day for five days

The most effective influenza prevention method is vaccination, especially in vulnerable populations. Individuals with chronic disease are at risk of suffering from swine flu.<sup>10,25</sup> CDC recommends yearly flu vaccination as the first and most crucial step in protecting against the flu. The protection provided by flu vaccination is essential to protect against an H3N2 virus, an influenza B virus, and 2009 H1N1.<sup>26,27</sup>

## CONCLUSION

This report discussed about a swine flu (H1N1pdm2009) infection in an elderly patient with COPD as an underlying disease. Even though this virus epidemiologically displays as mild, infection of swine flu in elderly with comorbidities should be considered. PCR swab is needed in order to establish the diagnosis to detect the virus. Once the diagnosis is established, oseltamivir administration is given for five days following the therapeutics guidelines recommendation.

## Consent

Written informed consent was obtained from the patient's daughter.

## Acknowledgments

None declared.

## Conflict of Interest

The authors declared there is no conflict of interest.

## Funding

This study did not receive any funding.

## Authors' Contributions

Initiating the case report: AABB. Drafting and making manuscript: AABB and AAGU. All authors contributed and approved the final version of the manuscript.

## REFERENCES

- Carvalho FS, Mendes BA, Villafuerte LKM, *et al.* Aspectos Clínicos dos Casos Confirmados de Influenza A (H1N1) Pdm09 por Região Durante a Pandemia No Brasil: Datasus. *Práticas e Cuid Rev Saúde Coletiva* 2021; 2: e12007.
- Guo F, Yang J, Pan J, *et al.* Origin and Evolution of H1N1/pdm2009: A Codon Usage Perspective. *Front Microbiol* 2020; 11: 1615.
- Ohanu M, Olusina DB, Eni A, *et al.* Influenza A viruses: Current Perspectives on Swine Flu Virus. *Int J Med Heal Dev* 2019; 24: 55.
- Juvet LK, Robertson AH, Laake I, *et al.* Safety of Influenza A H1N1pdm09 Vaccines: An Overview of Systematic Reviews. *Frontiers in Immunology*; 12, <https://www.frontiersin.org/articles/10.3389/fimmu.2021.740048> (2021).
- Himani, Anand A, Barwal A, *et al.* A Review Article on Swine Flu. *Indian J Forensic Community Med* 2020; 7: 109–116.
- Singh BP. Swine Flu: Common Disease with a Rare Complication: A Rare Complication of H1N1 Pneumonia. *Community Acquir Infect*; 6, <https://www.hksmp.com/journals/cai/article/view/177> (2020).
- Konda KC, Handattu K, Bhat Y R, *et al.* Spectrum of H1N1 Influenza Infection in Indian Children: A Tertiary Centre Experience. *Sri Lanka J Child Heal.* Epub ahead of print 2019.
- Kyaw Win SM, Saito R, Win NC, *et al.* Epidemic of Influenza A(H1N1)pdm09 Analyzed by Full Genome Sequences and the First Case of Oseltamivir-Resistant Strain in Myanmar 2017. *PLoS One* 2020; 15: e0229601.
- Kain T, Fowler R. Preparing Intensive Care for the Next Pandemic Influenza. *Crit Care* 2019; 23: 337.
- Verma M, Bhansali S, Kumar A. Time Trend of Swine Flu at a Tertiary Care Centre of Western Rajasthan: A Decadal Analysis. *Natl J Community Med* 2021; 12: 88–91.
- Kshatriya RM, Khara N V, Ganjiwale J, *et al.* Lessons Learnt from the Indian H1N1 (Swine Flu) Epidemic: Predictors of Outcome based on Epidemiological and Clinical Profile. *J Fam Med Prim Care* 2018; 7: 1506–1509.
- Mansoor S, Maqbool I. Swine Flu a Seasonal Pandemic, Symptoms, Diagnostics and Prevention. *Rev Res Med Microbiol*; 30, [https://journals.lww.com/revmedmicrobiol/Fulltext/2019/10000/Swine\\_flu\\_a\\_seasonal\\_pandemic\\_symptoms,.2.aspx](https://journals.lww.com/revmedmicrobiol/Fulltext/2019/10000/Swine_flu_a_seasonal_pandemic_symptoms,.2.aspx) (2019).
- Lampejo T. Influenza and Antiviral Resistance: An Overview. *Eur J Clin Microbiol Infect Dis* 2020; 39: 1201–1208.
- Gupta MK, Agrawal A, S K, *et al.* Resistance of Oseltamivir: A Major Problem for Swine Flu Treatment. *World J Pharm Res* 2020; 9: 338–354.
- Patterson B, Marks M, Martinez-Garcia G, *et al.* A Novel Cohorting and Isolation Strategy for Suspected COVID-19 Cases during a Pandemic. *J Hosp Infect* 2020; 105: 632–637.
- Perhimpunan Dokter Paru Indonesia (PDPI). *Pedoman Tatalaksana COVID-19*. 4th ed. Jakarta: Perhimpunan Dokter Paru Indonesia (PDPI), 2022.
- Nogales A, Martinez-Sobrido L, Chiem K, *et al.* Functional Evolution of the 2009 Pandemic H1N1 Influenza Virus NS1 and PA in Humans. *J Virol*; 92. Epub ahead of print October 2018.
- Adeola OA, Olugasa BO, Emikpe BO. Molecular Detection of Influenza A(H1N1)pdm09 Viruses with M Genes from Human Pandemic Strains among Nigerian Pigs, 2013-2015: Implications and Associated Risk Factors. *Epidemiol Infect* 2017; 145: 3345–3360.
- Dhakad PK, Singh M. A Review on Swine Flu Infection and Strategies for Its Treatment in Future. *J Anal Pharm Res* 2020; 9: 5–9.
- Gounder AP, Boon ACM. Influenza Pathogenesis: The Effect of Host Factors on Severity of Disease. *J Immunol* 2019; 202: 341–350.
- MacIntyre CR, Chughtai AA, Barnes M, *et al.* The Role of Pneumonia and Secondary Bacterial Infection in Fatal and Serious Outcomes of Pandemic Influenza a(H1N1)pdm09. *BMC Infect Dis* 2018; 18: 637.
- Olloquequi J. COVID-19 Susceptibility in Chronic Obstructive Pulmonary Disease. *Eur J Clin Invest* 2020; 50: e13382.
- Munjaj S, Munjal S, Gao J, *et al.* Exploring Potential COPD Immunosuppression Pathways

- Causing Increased Susceptibility for MAC Infections among COPD Patients. *Clin Pract* 2021; 11: 619–630.
24. (PDPI) PDPI. *Panduan Umum Praktis Klinis Penyakit Paru dan Pernapasan*. Jakarta: Perhimpunan Dokter Paru Indonesia (PDPI), 2021.
  25. Retamal M, Abed Y, Rhéaume C, *et al.* In Vitro and In Vivo Evidence of a Potential A(H1N1)pdm09 Antigenic Drift Mediated by Escape Mutations in the Haemagglutinin Sa Antigenic Site. *J Gen Virol* 2017; 98: 1224–1231.
  26. Smetana J, Chlibek R, Shaw J, *et al.* Influenza Vaccination in the Elderly. *Hum Vaccin Immunother* 2018; 14: 540–549.
  27. (CDC) C for DC and P. Summary of the 2017-2018 Influenza Season. *Influenza (Flu)*, [https://www.cdc.gov/flu/about/season/flu-season-2017-2018.htm?fbclid=IwAR04qA1an2fqMMLvn1qJCQOHp8IKUoxxPVFpoOkSXj\\_jiUPkLSCXeYsdCkk](https://www.cdc.gov/flu/about/season/flu-season-2017-2018.htm?fbclid=IwAR04qA1an2fqMMLvn1qJCQOHp8IKUoxxPVFpoOkSXj_jiUPkLSCXeYsdCkk) (2017).