

## *SUCCESSFUL PHARYNGOPLASTY AFTER LE FORT I ADVANCEMENT IN A SEVERELY NEGLECTED CLEFT LIP AND PALATE PATIENT*

Timotius Hansen Arista<sup>a</sup>, Magda Rosalina Hutagalung<sup>b\*</sup> 

<sup>a</sup>Department of Plastic Reconstructive and Aesthetic Surgery, Faculty of Medicine, Universitas Airlangga, Surabaya, Indonesia

<sup>b</sup>Australian Craniofacial Unit, Adelaide, South Australia, Australia

### ARTICLE INFO

**Keywords:** Pharyngoplasty, le fort, neglected cleft lip, palate, good health and well-being

#### \*Corresponding author:

Magda Rosalina Hutagalung  
Email:  
[magda.rosalina@fk.unair.ac.id](mailto:magda.rosalina@fk.unair.ac.id)

#### History:

Received: February 20, 2019  
Revised: May 7, 2019  
Accepted: May 20, 2019  
Published: June 1, 2019

#### JRE : Jurnal Rekonstruksi dan

**Estetik**  
e-ISSN:2774-6062; p-ISSN: 2301-7937  
DOI: 10.20473/jre.v4i1. 24351

#### Open access :

*Creative Commons Attribution-  
ShareAlike 4.0 International License  
(CC-BY-SA)*

#### Available at:

<https://e-journal.unair.ac.id/JRE/>

**How to cite:** Arista, T.H, & Hutagalung, M.R. SUCCESSFUL PHARYNGOPLASTY AFTER LE FORT I ADVANCEMENT IN A SEVERELY NEGLECTED CLEFT LIP AND PALATE PATIENT. Jurnal Rekonstruksi Dan Estetik, 2019. 4(1): 30-33

### ABSTRACT

**Introduction:** When indicated, velopharyngeal insufficiency (VPI) is treated with pharyngoplasty with consideration of patient's age. Several studies have evaluated the relationship between age at surgery and speech outcome. The best results regarding reduction of open nasality were obtained when surgeries were performed around age of 5 to 6 years and operative complications were also less frequent in the younger age group than in older patients. Pre-operative assessment such as nasopharyngoscopy and/or videofluoroscopy gives surgeons a chance to estimate flap dimension to correct the defect causing the VPI. Moreover, velopharyngoplasty proceeded with speech therapy yields better recovery.

**Case Illustration:** A seriously neglected case of cleft lip and palate was reported. A 24 years old female underwent two palatorrhaphy at age 13 and 14 years old, which were far beyond the recommended age of 10 -12 months. The resulting hypernasality was further worsened by absence of speech therapy which should have been followed from age 1-4 years old. On presentation, this patient requested to have immediate orthognatic surgery to repair his severe type 3 facial profile and malocclusion, a procedure which he underwent worsening the VPI. We decided to surgically correct the VPI.

**Discussion:** Nasoendoscopic assessment revealed he had an antero-posterior velopharyngeal closure problem which indicated a pharyngoplasty using a superiorly- based pharyngeal flap. Three months post-operatively his speech was re-evaluated by a speech therapist and nasoendoscopically. Despite imperfectness, significant improvement was achieved.

**Conclusions:** Pharyngoplasty could still be reliable to a certain extent as a correction treatment of VPI in a seriously neglected case. A posterior pharyngeal flap helped this patient to recover significant speech capacity.

### Highlights:

1. In a seriously neglected case, pharyngoplasty to a certain extent as a correction treatment of VPI was reliable.
2. A posterior pharyngeal flap was successful to recover significant speech capacity.

### INTRODUCTION

Velopharyngeal sphincter is a structure consisted of muscle on anterior, lateral, and posterior wall separated between nasopharyngeal and oropharyngeal have a role in ability to speaking and swallowing. Velopharyngeal

dysfunction (VPD) is a functional problem from velopharyngeal sphincter induce hyper nasal voice and nasal regurgitation while speaking.<sup>1</sup> This problem may affect psychosocial from patient such as lack of confident and more introvert.<sup>2</sup> Children with cleft lip and palate (CLP) has limited

maxilla growth that need a correction. Primary cause of this deformity are effect from short cleft palate and soft palate.<sup>3</sup> According to classification, velopharyngeal dysfunction is caused by deformity from neuromuscular or velopharyngeal tissue deficit. Moreover, velopharyngeal dysfunction can caused by sequel on cleft lip and palate patient after do a maxillary advancement with ratio between 0-84%.<sup>4</sup> Pre-operative nasopharyngoscopy or video fluoroscopy give a chance for surgeon to adjust flap dimensions according to model and width of closure on pharyngeal valve.<sup>4</sup>

In addition to speech therapy with the therapist, velopharyngoplasty surgery remains a success of 92%.<sup>3</sup> Surgery techniques that often used in correcting velopharyngeal dysfunction are posterior pharyngeal flap, sphincter pharyngoplasty, and furlow double opposing z-palatoplasty.<sup>1,5</sup> Besides affecting way of speaking on velopharyngeal dysfunction patient, this condition provides a social stigma such a lack of confident.<sup>2</sup> This case report aims to improve knowledge about velopharyngeal dysfunction on cleft lip and palate patient, and a management to improve ability to talk from the patient.

### CASE ILLUSTRATION

#### Clinical Finding

We reported a twenty four years old female came to Plastic and Reconstructive outpatient clinic with nasal voice complaint and poor ability to talk. The patient has been married and completing her bachelor degree. Patient with lack of speech and scrannel voice from last operation with labioplasty and palatoplasty for cleft lip and palate (CLP/LASHSAL) done overseas, the condition getting worse after orthognathic surgery (Bilateral Sagittal Split Osteotomy Mandibular Set-Back + Le Fort I Advancement Surgery) to control type III malocclusion. The patient hasn't get

a referral to do a speech therapy.

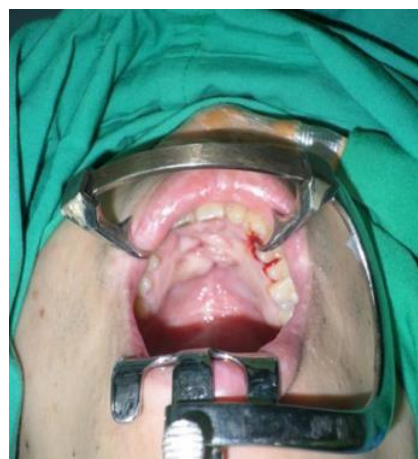

Figure 1. A Fistulae From Palate

#### Diagnostic Finding

We did endoscopy to evaluate deformity from velopharyngeal sphincter size and location, and followed by a plastic surgeon and speech therapist. The result are found a fistulae and nasal air leakage.

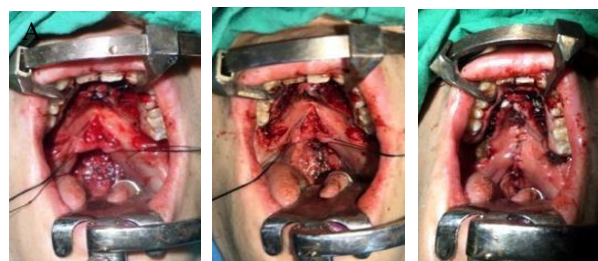


Figure. 2 (A-B). Posterior incision pharyngeal flap with superior pedicle; (C). Fistula repaired and suture palate region with double layer technique

#### Operative Prosedure

Velopharyngeal incompetence diagnosed by finding a problem on antero-posterior velopharyngeal movement and decided to do a pharyngeal flap; A problem fistulae on palatum anterior decided to do re- palathoplasty surgery with technique as follow; 1) Repaired fistula with double layer technique and suture by silk 4.0 (Figure 2C) ; 2) Posterior pharyngeal flap with superior pedicle (Figure 2A); 3) Suture palate region with silk 4.0 (Figure 2B).

Oral analgesia was prescribed after surgery and no complication of scar after surgery. We also prescribed antibiotics and corticosteroid to decrease swelling after surgery. The result from nasoendoscopy re-examination after 4 month pharyngoplasty consist of; 1) Pharyngeal Flap is intact 2) Velopharyngeal movement become better 3) Fistulae covered well.

## DISCUSSION

Velopharynx is a complex structure that delimits mouth and nasal cavity. Dysfunction to this structure may cause air leaking from mouth to nasal cavity, causing nasopharynx regurgitation and decreased ability to speak normally. In some cases it is found that velopharyngeal dysfunction also have effect in patient's social life in their interaction with other people. In this case, the patient had surgical history of two palatoplasty on 13-14 years age in Singapore and China. This is contrast between cleft and left palate treatment that should be speech evaluated by speech therapist. From cleft lip and palate management, speech therapy is scheduled for patient after palatoplasty on 1-4 years of age. Plastic Reconstructive and Aesthetic Surgery Department of Surabaya established palatoplasty protocol for age of 10-12 month, and pharyngoplasty in 4 years of age. It may improve success rate on velopharyngeal insufficient correction. Rong-min Baek said if pharyngoplasty do after 6 years age can make 90% successfully, if do it for 20 year age the successful rate just 60% - 70 %. From above can make an analysis that obstacle factor about this case is a neglected case that make a treatment for velopharyngeal insufficient didn't perfect.

This patient has historical surgery, midface advancement because hypoplasia maxilla with distance 9mm and mandibular setback for 4mm. This orthogenetic surgery has disadvantage of longer velopharynx

and increased number of velopharyngeal insufficient with distance more than 11 mm. From the history taking, physical examination, and nasoendoscopy we found that the patient has a velopharynx closing problem on antero-posterior and we did posterior pharyngeal flap.

We also found an anterior oronasal fistulae that decrease quality of speech on this patient. We did a re-palatoplasty to correct the fistulae. Three months after surgery, the patient was evaluated by speech therapist. The quality of speech was getting better, especially in letter 'S' pronunciation, fluid doesn't come out of the nose, and a good malocclusion.

## CONCLUSION

A neglected case affecting the result of surgical procedure which have been chosen for the patient. The posterior pharyngeal flap performed in this patient can only help restoring the quality of patient's voice, as midface advancement were done, that made the velopharynx lengthening and decreasing the patient ability to speak.

Management of action in velopharyngeal dysfunction is surgery based on history taking, physical examination, and diagnostic examination such as nasoendoscopy to established the diagnosis and determine appropriate technique for this case. Following multidisciplinary management and multistage action for cleft lip and palate which is adjusted to patient's age and it's procedure might give maximum success rate and the incident of velopharyngeal insufficient can be avoided.

## ACKNOWLEDGMENT

The authors would thanks to Department of Plastic Reconstructive and Aesthetic Surgery, Faculty of Medicine, Universitas Airlangga, Surabaya, Indonesia.

### **CONFLICT OF INTEREST**

There is no conflict of interest in this study.

### **FUNDING DISCLOSURE**

None.

### **AUTHORS CONTRIBUTION**

Authors contributed to the wrote, study design, finding the literature, methodology.

### **REFERENCES**

1. Sullivan SR, Eileen M. "Pharyngeal Flap Outcomes in Nonsyndromic Children with Repaired Cleft Palate and Velopharyngeal Insufficiency." *Plastic and Reconstructive Surgery*. 2010.125 (1): 290-8.
2. Raol N, Hartnick CJ. "Anatomy and Physiology of Velopharyngeal Closure and Insufficiency." *Adv Otorhinolaryngol*. 2015.76: 1-6.
3. Bois E, Celerier C. " Velopharyngeal insufficiency managed by autologous fat grafting in patients with aberrant courses of internal carotid arteries." *International Journal of Pediatric Otorhinolaryngology*. 2017. (96): 135-39.
4. Dentino K, Marrinan E. 2016. "Pharyngeal Flap is Effective Treatment for Post Maxillary Advancement Velopharyngeal Insufficiency in Patients with Repaired Cleft Lip and Palate." *Journal of Oral and Maxillofacial Surgery*.
5. Berkowitz, S. 2006. *Cleft lip and palate: diagnosis and management*. 2<sup>nd</sup> Edition. Springer.