



A CASE REPORT: UNILATERAL COMPLETE CLEFT LIP RECONSTRUCTION USING THE MODIFICATION MILLARD TECHNIQUE

Rr. Theodora Ratih Labdagati Iswara^a, Muhammad Aulia Ul Hakim^{b*}

^aMedical Doctor, Intern of Plastic Reconstructive and Aesthetic Surgery Department, Sultan Agung Islamic Hospital, Semarang, Central Java, Indonesia

^bDepartement of Surgery, Sultan Agung Islamic Hospital, Semarang, Central Java, Indonesia

ARTICLE INFO

Keywords: Cleft lip and palate, craniomaxillofacial, labioplasty, medicine, Millard, reconstruction

***Corresponding author:**
Muhammad Aulia Ul Hakim
Email address:
dr.ul.hakim@gmail.com

History:
Received: March 3, 2023
Revised: May 25, 2023
Accepted: May 30, 2023
Published: June 1, 2023

JRE : Jurnal Rekonstruksi dan Estetik
e-ISSN:2774-6062; p-ISSN: 2301-7937
DOI: 10.20473/jre.v8i1.43868
Open access :
Creative Commons Attribution-ShareAlike 4.0 International License (CC-BY-SA)
Available at:
<https://e-journal.unair.ac.id/JRE/>

How to cite: Iswara RTRL & Hakim MAU. CASE REPORT: UNILATERAL COMPLETE CLEFT LIP RECONSTRUCTION USING THE MODIFICATION MILLARD TECHNIQUE. Jurnal Rekonstruksi dan Estetik.2023; 8(1): 14-20.

ABSTRACT

Introduction: With 1 in 700 live births worldwide, cleft lip with or without cleft palate is the most prevalent congenital craniomaxillofacial birth condition. More people have a unilateral cleft lip than a bilateral cleft lip. Except for vision, it can influence morphology and nearly all facial functions. The purpose of this study is to give an overview and learn more about the management of lip repair using the modified Millard approach, which can prevent straight-line closure and vermilion notching.

Case Illustration: We present a case of a 4-month-old male who underwent a modified Millard procedure and had a unilateral full cleft lip. The findings revealed no vermilion notch, acceptable columellar and alar lengths, symmetrical Cupid's bow, lip height, lip width, and philtrum angle.

Discussion: The modified Millard technique, including the Tennison triangular flap, improves the repair of cleft lips by preventing vermilion notching and reducing scar complications. It also addresses concerns related to lip tissue compromise and nostril deformities. Scar thinning techniques and separate nosography contribute to enhanced aesthetics and optimal healing. These modifications aim to achieve improved appearance and functionality in cleft lip repairs.

Conclusion: The modified Millard technique can be considered a viable option for treating unilateral cleft lip due to its ability to create a balanced Cupid's bow, maintain appropriate lip height and width, and achieve satisfactory aesthetic results in the nasal area without vermilion notching.

Highlights:

1. The modified Millard technique, including the Tennison triangular flap, is effective in preventing vermilion notching and reducing scar complications in cleft lip repairs.
2. The technique addresses concerns related to compromised lip tissue and nostril deformities, leading to improved appearance and functionality.
3. Scar thinning techniques and separate nosography contribute to enhanced aesthetics and optimal healing in cleft lip repairs.

INTRODUCTION

Cleft lip and palate (CLP) is the most common congenital craniomaxillofacial birth defect with 1 in 700 live births in the world. Cleft lip and palate are intricate conditions with a combination of various risk factors and are known to have a prevalence of 0.2% in Indonesia¹. It is the second most prevalent congenital defect in the country². The non-union of the top lip and roof of the mouth is known as cleft lip and palate, and it can happen when congenital abnormalities develop significantly in both shape and severity³.

A unilateral cleft is more common than a bilateral cleft lip⁴. There are various etiologies of this disease, including ethnic, racial, geographic, and socioeconomic factors, and smoking habits^{5,6}. Bilateral clefts are twice as challenging as unilateral clefts, and the outcomes are only slightly better. There are a variety of techniques for treating bilateral clefts with various timings for each surgery, 1 or 2 stages, and diverse associated procedures like rhinoplasty. However, due to symmetry issues, a short columella, or a wide nasolabial angle, the outcomes of bilateral cleft surgery may be modest. To enhance treatment protocols, it is critical to evaluate treatment results⁴. Techniques that are often used to repair unilateral cleft lip are Millard and Tennison. However, both of these techniques have advantages and disadvantages depending on the patient variation, measurement of the cleft, and time of evaluation. In recent times, numerous surgeons have been devising different approaches to effectively repair complete unilateral cleft lips, aiming to achieve improved outcomes in the surgical results^{7,8}.

The purpose of surgical correction for a unilateral cleft lip is to enhance both the functional and aesthetic aspects of the lip while ensuring proper anatomical reconstruction. Performing cleft palate repair between the ages of 10 to 12 months is recommended. This timeline allows for the maturation of postoperative scar tissue, which softens over time and contributes to optimal speech outcomes. Delaying cleft palate repair

beyond this timeframe may elevate the risk of speech function disorders⁹. Asymmetrical upper lip with a natural-looking philtral column length on either side characterizes the ideal outcome. To conceal the scar, the scar must reflect the opposite side, not extend past the philtral column, and not have vermilion notching^{10,11}. This study aims to provide an overview and learn more about the management of lip repair with the modified Millard technique to get a better result.

CASE ILLUSTRATION

A 4-month-old male comes to the Plastic Surgery Department with his parents and complains of a cleft lip on the left side up to the nostrils since birth. There's no family history of cleft lip or cleft palate. Before and during pregnancy, the patient's mother did not consume drugs that could interfere with the process of fetal formation.

A physical examination of the patient found a complete cleft lip on the left side and there's no cleft palate (Figure 1). A thorough examination was carried out for the preparation of general anesthesia including routine blood tests (hemoglobin, erythrocytes, leukocytes, platelets, Bt, Ct), and chest X-rays. The results are within normal limits. The patient is also examined to ensure that he is free from other congenital diseases.

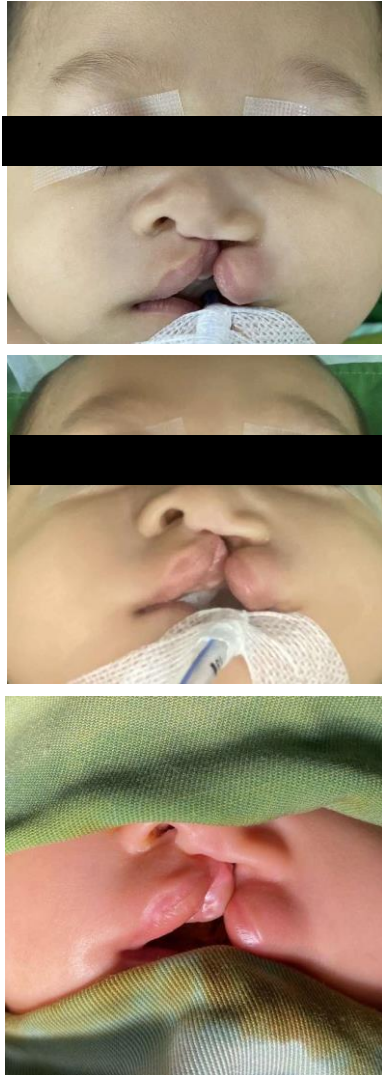

Figure 1. Pre- reconstruction surgery.

On preoperative examination, the patient is confirmed to have fulfilled the rule over ten (age: 12 weeks; weight: 6.5 kgs; Hb: 12.4 g/dL). The surgery was performed under general anesthesia. Reconstruction begins by disinfecting the area to be operated on and drawing an incision design on the patient's lips. The design used is Millard's design which is modified by providing a triangle on the side of the lip slit to make a flap. Then an incision is made according to the design and undermining is carried out to separate the tissue so that it can be rotated and sutured according to anatomical shape appropriately. The triangular flap from the lateral side is tucked into the corner on the medial side of the fissure just above the

vermilion border, across the philtral neck to the apex of the cupid (Figure 2).

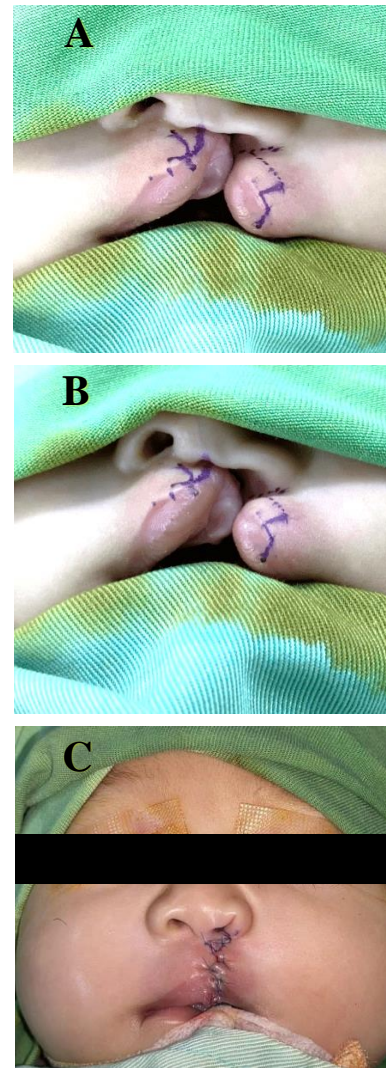


Figure 2. (A, B) Modification of Millard's design; (C) Post-reconstruction result.

Evaluation one month after reconstruction, the results showed that there was no vermilion notch, lip height, lip width, or philtrum angle, and Cupid's bow appeared symmetrical, and acceptable columellar and alar lengths (Figure 3).

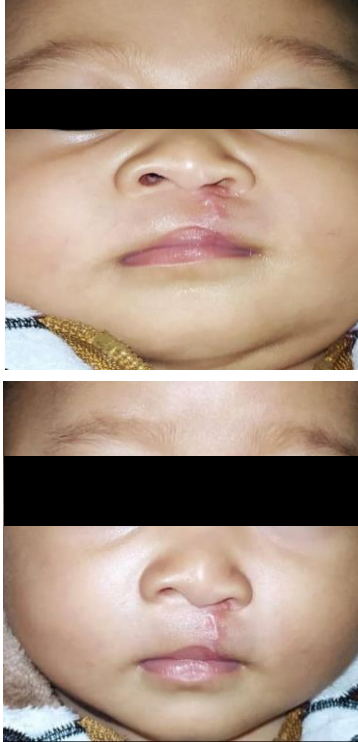

Figure 3. Evaluation one-month post-reconstruction surgery

DISCUSSIONS

Bilateral cleft lip occurs less frequently than unilateral clefts. Surgeons are trying to determine the best way to handle it as a result of this. Since it can create a natural philtral column, the rotation-advancement technique described by Millard remains one of the most used repair techniques for cleft lip restoration. However, the majority of surgeons utilize a modified version of the rotation-advancement flap^{12,13}.

The triangular flap procedure has a wide range of applications and can be used to repair clefts of all sizes, from little to very large. Tennison's triangular flap, however, has been criticized since the lower triangle encroaches on the philtral region and is hence unsightly¹⁴.

In this case, we use a modified Millard design with Tennison (Figure 4) because, besides being expected to fill the deficiencies of each technique, basically they have the same geometric principles even though the results are different (Figure 5). Geometric analysis is necessary for cheiloplasty

design. Sufficient descent of the peak points of Cupid's bow near the cleft edge is the most important requisite in cheiloplasty. Existing incision designs are based on geometric principles, taking into account factors affecting the rotation of the apex on the cleft side. However, surgeons are always more concerned with the length of the incision than the location of key points such as the top edge of the incision. This is one reason why only skilled surgeons can successfully treat many types of deformities. According to Bing Shi, a successful cheiloplasty method must adhere to a design that follows geometrical principles and can, to the maximum extent possible, restore and rebuild natural anatomical components¹⁵.

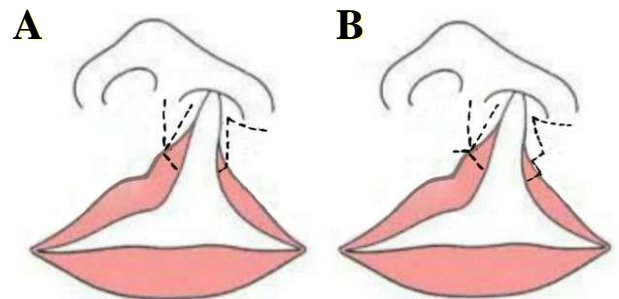


Figure 4. (A) Classic Millard's technique; (B) Modification Millard's technique.

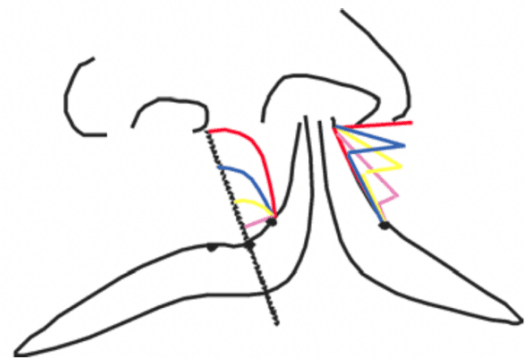


Figure 5. Geometric lines of Classic Millard's technique (red line) and Tennison's technique (purple line)¹⁵

In this case, the technique choice has the purpose to restore the lip function with an acceptable appearance. The good result must be symmetrical lips, look natural, and a faint scar. This modification Millard technique is expected to be able to avoid straight-line closure and vermilion notching. As a result, there's no vermilion notch, got a symmetrical lip length, Cupid's bow, and acceptable columellar and alar lengths.

Vermilion notching develops in repaired lips as a consequence of the inadequate rotation of the medial lip segment, lack of most muscle in the vermilion, and scar contracture along the cutaneous or mucosal aspect of the lip. The Tennison triangular flap from the lateral side that tucked into a corner on the medial side of the fissure just above the vermilion border, across the philtral neck to the apex cupid can add length on the shortest side of the lips and avoid the vermilion notch^{7,14}. Due to research by Alkebsi et al. showing that patients who received the modified rotation advancement technique had better aesthetic results, the surgeons modified the Millard technique to address the drawbacks of the classical technique and to achieve better results than the classical method¹⁶.

The Classic Millard technique often results in straight line scars and vermilion notches. The Tennison technique's scars are zig-zag lines that have a minimal propensity for hypertrophy and are easily camouflaged. The Tennison technique does have one limitation: it tends to produce lips that are overly lengthy vertically because a scar forms on the philtrum in its lower third¹⁷. Scar thinning can be overcome by applying silicone gel with light massage in the direction of the stitches on the wound.

The disadvantages of the Classic Millard technique are that if the lateral lip segment has a shorter vertical height, the method may occasionally compromise the mucosa and lip tissue, as this technique requires significant undermining and may result in a small nostril. Therefore, in this modified Millard technique, the two points of closure along the nostril floor are designed so that when they are brought together

the nasal deformity is corrected. From these two points, corresponding lines are dropped to the cleft Cupid's bow peak medially and to the base of the triangular flap laterally^{18,19,20}.

There is no definite benchmark for doing nosography. Some centers perform nosography at the same time as chirography, but we chose to delay nosography in this patient with the consideration that apart from not interfering with function, the nose is also a center for facial growth, so we will do nosography in stages after the post chirography wound heals properly to get better results.

This case provides a concise and comprehensive overview of cleft lip as a common congenital birth defect. It covers various aspects, such as scar appearance, vermilion notching, lip length, and nasal deformity correction. The importance of surgical repair in improving both the functional and aesthetic aspects of the lip. It effectively introduces the modified Millard technique as a method to avoid straight-line closure and vermilion notching, which can lead to symmetrical and natural-looking results. The decision to delay nosography to ensure proper healing reflects a thoughtful approach to achieving optimal results.

CONCLUSION

The modified Millard technique offers a potential solution for addressing unilateral cleft lip by ensuring a leveled Cupid's bow, maintaining lip height and width, and achieving satisfactory aesthetic results in the nasal area. Additionally, this technique effectively avoids vermilion notching, resulting in improved outcomes for patients. The Millard technique, a modification of the

traditional approach, can be considered a viable option for managing unilateral cleft lip. This technique addresses several important aspects of aesthetic outcomes, such as leveling the Cupid's bow while preserving lip height and width. Additionally, the Millard technique has shown satisfactory nasal outcomes aesthetically, and it effectively avoids vermilion notching, a common concern in cleft lip repair. Overall, the Millard technique offers a comprehensive approach to unilateral cleft lip management, combining favorable cosmetic results with functional considerations.

ACKNOWLEDGMENTS

We thank the Medical Doctor, Intern of Plastic Reconstructive and Aesthetic Surgery Department and Department of Surgery, Sultan Agung Islamic Hospital, Semarang, Central Java, Indonesia, and also our patient and their families who gave us their consent to report their cases in our paper.

CONFLICT OF INTEREST

The authors have no conflict of interest to declare in this article.

FUNDING DISCLOSURE

This research has no financial interest or affiliation concerning material.

AUTHOR CONTRIBUTION

RTRLI was conceptual the manuscript, MAUH was written, revise, conceptual, and data analysis collection

REFERENCES

1. Moegni K, Suryadinata K, Sisca F. Analyzing Parental Age to Determine Types of Cleft in Hayandra Peduli Foundation Patient, Indonesia. *J Profesi Med J Kedokt dan Kesehatan*; 14. Epub ahead of print 26 May 2021. DOI: 10.33533/jpm.v14i2.2244.
2. Khamila N, Agus Nurwiadh A & PF. Characteristic of Cleft Lip and Palate at Cleft Center of Padjadjaran University Dental Hospital: 2 Years Retrospective Study. *J Pendidik Tambusai* 2022; 6: 1058–1064.
3. Huqh MZU, Abdullah JY, Wong LS, et al. Clinical Applications of Artificial Intelligence and Machine Learning in Children with Cleft Lip and Palate-A Systematic Review. *Int J Environ Res Public Health*; 19. Epub ahead of print August 2022. DOI: 10.3390/ijerph191710860.
4. Aljancic L, Rougier G, Neiva-Vaz C, et al. Millard's modified technique in the reconstruction of bilateral cleft lip: Objective and subjective assessment. *J Stomatol oral Maxillofac Surg* 2022; 123: 532–537.
5. Yılmaz HN, Özbilen EÖ, Üstün T. The Prevalence of Cleft Lip and Palate Patients: A Single-Center Experience for 17 Years. *Turkish J Orthod* 2019; 32: 139–144.
6. Auslander A, McKean-Cowdin R, Brindopke F, et al. The role of smoke from cooking indoors over an open flame and parental smoking on the risk of cleft lip and palate: A case- control study in 7 low-resource countries. *J Glob Health*; 10. Epub ahead of print 14 August 2020. DOI: 10.7189/jogh.10.020410.
7. F GA& J. Perbandingan Estetika Post Labioplasty Unilateral antara Teknik Millard dengan Teknik Tennison. *UMI Med J* 2022; 7: 1–9.
8. Zaleckas L, Linkevičienė L, Olekas J, et al. The comparison of different surgical techniques used for repair of complete unilateral cleft lip.



- Medicina (Kaunas)* 2011; 47: 85–90.
9. Ningrum LP, Saputro ID & ZL. Correlation of Parents' Profile of Children with Late Cleft Repair in Surabaya Cleft Lip and Palate Centre *Jurnal Rekonstruksi dan Estetik*. 2020.5(1): 18–23
 10. ElMaghraby MF, Ghozlan NA, Ashry MH, et al. Comparative study between fisher anatomical subunit approximation technique and millard rotation- advancement technique in unilateral cleft lip repair. *Alexandria J Med* 2021; 57: 92–102.
 11. Adetayo AM, Adetayo MO, Adeyemo WL, et al. Unilateral cleft lip: evaluation and comparison of treatment outcome with two surgical techniques based on qualitative (subject/guardian and professional) assessment. *J Korean Assoc Oral Maxillofac Surg* 2019; 45: 141–151.
 12. Knežević P, Grgurević L, Uglešić V, et al. Modified Millard's technique in operations for unilateral cleft lip. *J Plast Surg Hand Surg* 2012; 46: 326–329.
 13. Han K, Park J, Lee S, et al. Personal technique for definite repair of complete unilateral cleft lip: modified Millard technique. *Arch craniofacial Surg* 2018; 19: 3–12.
 14. RK S. Triangular flap technique for unilateral cleft lip deformity. *J Cleft Lip Palate Craniofac Anomal* 2021; 8: 163–8.
 15. Shi Bing & Sommerlad Brian. *Cleft Lip and Palate Primary Repair*. Zhejiang University Press: Springer, 2013.
 16. Alkebsi K, Li C, Aonan X, et al. Cupid's Bow Leveling and Preservation of Lip Height and Width: A Modified rotation- advancement Technique. *Plast Reconstr Surg*. Epub ahead of print January 2023. DOI:10.1097/PRS.000000000010229.
 17. Adetayo AM, James O, Adeyemo WL, et al. Unilateral cleft lip repair: a comparison of treatment outcome with two surgical techniques using quantitative (anthropometry) assessment. *J Korean Assoc Oral Maxillofac Surg* 2018; 44: 3–11.
 18. Elayah SA, Sakran KA, Alkebsi K, et al. Primary unilateral incomplete cleft lip repair by a modified rotational advancement technique. *J Stomatol Oral Maxillofac Surg* 2023; 124: 101325.
 19. Tse R. Unilateral cleft lip: principles and practice of surgical management. *Semin Plast Surg* 2012; 26: 145–155.
 20. Dunitz MR & M. *Cleft Lip and Palate Primary Repair*. The Lip an. CRC Press: Taylor & Francis Group, 2000.