


A META-ANALYSIS: THE UTILIZATION OF NEGATIVE PRESSURE WOUND THERAPY IN DIABETIC FOOT ULCERS

Ni Putu Gita Raditya Sanjiwani^a  I Putu Krisna Murti

Faculty of Medicine, Udayana University, Prima Medika Hospital, Denpasar, Indonesia

ARTICLE INFO

Keywords: Negative pressure wound therapy, diabetes, diabetic foot treatment, quality-adjusted life year, mortality

***Corresponding author:**

Ni Putu Gita Raditya Sanjiwani
Email address:

Sanjiwani60@gmail.com

History:

Received: September 5, 2023

Revised: October 27, 2023

Accepted: November 15, 2023

Published: December 1, 2023

JRE : Jurnal Rekonstruksi dan Estetik

e-ISSN:2774-6062; p-ISSN: 2301-7937

DOI: 10.20473/jre.8i2.50290

Open access :

Creative Commons Attribution-ShareAlike 4.0 International License (CC-BY-SA)

Available at:

<https://e-journal.unair.ac.id/JRE/>

How to cite: Sanjiwani, N.P.G.R., & Murti, I.P.K. META-ANALYSIS: THE UTILIZATION OF NEGATIVE PRESSURE WOUND THERAPY IN DIABETIC FOOT ULCERS. Jurnal Rekonstruksi Dan Estetik,2023. 8(2):106-116.

ABSTRACT

Introduction: Diabetes mellitus has a global prevalence and significant consequence known as diabetic foot ulcers. Negative pressure wound therapy (NPWT) is a modern therapeutic strategy for managing diabetic foot ulcers. The primary objective of this study is to assess the efficacy and safety by doing a thorough literature review and performing a meta-analysis.

Methods: The search platforms chosen for this study were PubMed, Embase, and Cochrane Library databases with years of publication between 2013 and 2022. The analysis was conducted using the software RevMan 5.4 and R statistical software.

Results: In the present investigation, a total of 291 articles were first subjected to screening. The analysis ultimately included nine relevant literatures after the screening process. The selected literature encompassed a collective sample size of 890 patients. The random effect model used in the analysis revealed a statistically significant discrepancy in the healing rate that had negative pressure wound therapy (NPWT) intervention with the healing rate analysis shows OR 0.77 [0.65, 0.90] $p=0.0$, and other outcome analysis shows no statistically significant result, adverse event incident OR 0.01 CI [0.00 to 0.04], $p=0.23$, and amputation rate was OR 0.01 CI [0.00 to 0.02] $p=0.81$.

Conclusions: This research has provided evidence of the effectiveness of negative pressure wound therapy (NPWT) as a potential approach for accelerating the wound healing process. However, when utilizing this innovative approach, it is imperative to guarantee meticulous regulation and modification of the negative pressure value to mitigate any potential risk of bleeding in the wound.

Highlights :

1. Diabetes mellitus has a global prevalence of more than 500 million individuals, and it is associated with a significant consequence known as diabetic foot ulcers (DFUs).
2. Diabetic foot is a commonly observed complication of diabetes mellitus, characterized by the development of non-healing ulcers, which can have a substantial negative impact on the overall well-being of those affected.
3. Negative pressure wound therapy (NPWT) effectively eliminates necrotic tissue and wound secretions, stimulates the production of granulation tissue, mitigates bacterial infection, and expedites the process of wound healing.

INTRODUCTION

Diabetes mellitus has a global prevalence of more than 500 million individuals. In the year 2019, diabetes was the primary reason for 1.5 million fatalities, and 48% of all diabetes-related deaths took place prior to individuals reaching the age of 70 years. It is associated with a significant consequence known as diabetic foot ulcers or DFUs. DFUs exhibit a significant degree of chronicity and morbidity, frequently presenting with complications such as infections that can progress to osteomyelitis and necessitate amputations. Comorbidities are associated with a decline in immune function and the ability to repair wounds.^{1,2}

The five-year survival rate for amputations connected to diabetes is 40%, which exceeds the mortality rate observed in numerous cancer cases. Diabetic foot is a prevalent complication of diabetes mellitus that arises from elevated blood glucose levels. This condition manifests as peripheral nerve and vascular impairments, leading to dry and irritated skin on the foot. Ultimately, this can progress to the formation of non-healing ulcers, significantly diminishing the quality of life for affected individuals. The application of novel medical treatments has resulted in the progressive incorporation of diverse approaches in wound therapy, driven by the fundamental principles of biochemistry and cytology.³⁻⁹

Negative pressure wound therapy (NPWT) is a therapeutic technique that can be utilized to manage superficial wounds and promote the removal of exudate from deep wounds. The intervention can efficiently remove necrotic tissue and wound fluids, promote granulation tissue formation, reduce bacterial infection, and accelerate the wound healing process.¹⁰ Negative Pressure Wound Therapy (NPWT) is a mechanical device consisting of a tube connected to a suction apparatus. The present technique induces a sub-atmospheric pressure gradient between the site of injury and the surrounding

environment, thereby promoting the elimination of exudate and accelerating the wound-healing process.¹¹

The previous case report has investigated NPWT successfully as a wound healing treatment for diabetic foot. Negative Pressure Wound Therapy (NPWT) has proven to be a highly effective treatment for improving skin survival and accelerating wound healing across various wound types. NPWT's mechanisms are diverse, with a biological role that includes macro-deformation, micro-deformation, fluid removal, wound contraction promotion, and the creation of a warm, moist, and enclosed wound environment. It also supports angiogenesis, granulation tissue growth, and inhibits bacterial growth. These advantages result in reduced dressing change frequency, minimized wound exposure, lower infection risk, optimal conditions for subsequent skin transplantation, and an increased success rate for skin graft procedures.¹²

The author intends to conduct a systematic review and meta-analysis to further explore aspects related to wound healing rate, the rate of amputations, and the occurrence of adverse events following the application of NPWT for diabetic foot ulcers.

METHODS

The search platforms chosen for this investigation were Embase, Pubmed, and the Cochrane Library databases. The search keywords utilized were "negative pressure wound therapy" OR "vacuum-assisted closure therapy," OR "diabetes" OR "diabetic foot," OR "chronic wound" OR "morbidity" OR "Quality-adjusted life year."

The inclusion criteria in the study were as follows: (a) The study employed a randomized controlled trial (RCT) design, with a publication period spanning from 2013 to 2022. (b) The participants were diagnosed with DF. (c) The study was conducted and reported in the English language. (d) The patient had a medical procedure known as negative pressure

debridement, which is also commonly referred to as vacuum negative pressure therapy. (e) The study assessed many indicators, including wound healing rate, incidence of adverse responses, and amputation rate. The criteria for exclusion were as follows: (a) Studies conducted in languages other than English. (b) Studies with a sample size of less than 10 participants. (c) Foot trauma not caused by diabetes. (d) Studies that do not include outcome measures or have incomplete data.

The researchers conducted a systematic search of databases, resulting in the identification of relevant publications that were subsequently compiled by two scholars. Duplicate articles were eliminated, and an initial screening phase involved the assessment of titles and abstracts of the publications. Subsequently, a more thorough review of the complete texts was performed, and the papers were categorized based on predetermined criteria for inclusion or exclusion. In cases where the researchers did not reach a consensus during the screening phase, an impartial third party was consulted to assist in resolving any disagreements. The dataset comprised a wide range of parameters obtained through extensive text analysis, including factors such as authorship, publication date, the number of patients who received the intervention, gender distribution, levels of glycosylated hemoglobin, duration of the intervention, age, body mass index (BMI), location and size of the ulcers, and the duration of follow-up. The data underwent a transformation process to make it more suitable for subsequent synthesis. For instance, metrics that were initially expressed as a proportion of the entire body of literature were converted into specific patient counts.

The synthesis was conducted using RevMan version 5.4 and R statistical software. The statistical measures employed for reporting continuous variables were the weighted mean difference (WMD) and the 95% confidence interval (CI). Binary

variables, on the other hand, were reported using the odds ratio (OR) and the 95% CI. The statistical data was displayed using a forest plot, with a significance level of $\alpha=0.05$. The examination of literature heterogeneity was conducted using I² analysis and Q calibration. The heterogeneity in the data was indicated by an I² value greater than 25% or a significant P value. The random effects model analysis was employed when heterogeneity was seen among studies.

On the other hand, in situations where there was an absence of heterogeneity. In order to address the potential presence of variability in the literature, a sensitivity analysis was performed utilizing the exclusion strategy. This involved carefully excluding each study one by one.

RESULTS

The current study encompassed an initial assessment of 291 publications and subsequently underwent a sequence of procedures, which included confirming duplication, conducting primary screening, and re-screening. Ultimately, seven papers were deemed suitable for inclusion in the research, with a combined sample size of 890 participants. The screening process is visually represented in Figure 1.

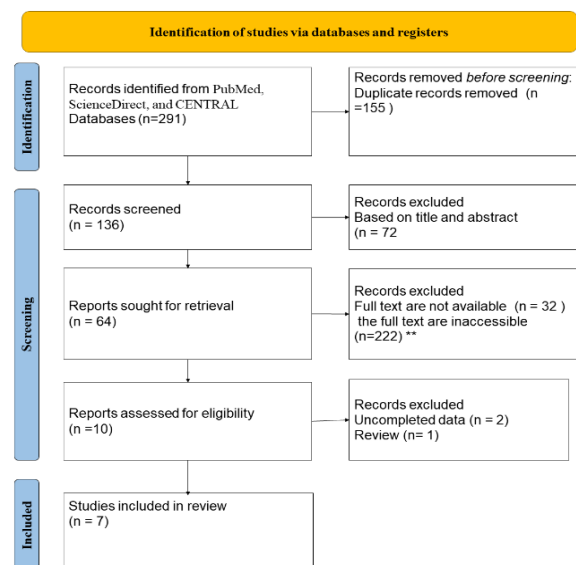


Figure 1. PRISMA Flow Chart



The critical characteristics of the seven randomized controlled trials (RCTs) in this study are succinctly summarized in Table 1. The participants' age span ranged from 50 to 69 years. The duration of the interventions varied from one week to 56 days. Furthermore, the observation period's duration exhibited variability, with a minimum of two weeks and a maximum of six months. The tabulated data can be found in Table 1.

Table 1. Characteristics of Study

Author and Year of Publication	Country	Population	Type and Duration of Intervention	Follow Up Time
Borys et al. (2018) ¹³	Poland	75	NPWT and 9 days	Six months
Chiang et al. ¹⁴ (2017)	New Zealand	22	NPWT and 14 days	Six months
James et al. (2019) ¹⁵	India	54	NPWT and N/A	N/A
Lone et al. (2014) ¹⁶	India	56	NPWT and 8 weeks	Two months
Seidel et al. (2020) ¹⁷	Germany	345	NPWT and 16 weeks	Six months
Vaidhya et al. (2015) ¹⁸	India	60	Eight days	N/A
Sajid et al (2015) ¹⁹	Pakistan	278	NPWT and 1 week	2 weeks

*N/A : Not Available

Table 1 conducted in various countries, offer valuable insights into the application of Negative Pressure Wound Therapy (NPWT) for the treatment of diabetic foot ulcers. Notably, these studies exhibit diversity in the duration of NPWT intervention and the follow-up periods, contributing to a comprehensive understanding of its effectiveness across different populations and settings.

This study focused on the investigation of a meta-analysis conducted in multiple nations. Two of the studies took place in Europe, with one conducted in Poland and the other in Germany. Three research investigations were carried out in India, while one study was performed in Pakistan, and an additional study was undertaken in New Zealand. The main treatment intervention applied to the participants in

this study was Negative Pressure Wound Treatment (NPWT). In each of the research studies, the control group received standard wound care, which included regular topical dressing, traditional wound dressing, and SWMC.

Wound Healing Rate

After completing a comprehensive review of the available literature, it was discovered that four studies have provided data on the markers of wound healing rate displayed by the participants. The existing body of research provides evidence of statistical heterogeneity, as evidenced by an odds ratio (OR) of 0.77 95% (CI) [0.65, 0.90], $p=0.01$, and an I^2 value of 73%, which means the result shows the statistically significant of NPWT treatment for DFUs. The results suggest that the patient had a positive impact on wound healing after the utilization of NPWT.

Incidence of Adverse Events

Two investigations have successfully identified the variables that exhibit associations with the incidence rate of adverse patient events. The conducted studies did not exhibit substantial statistical heterogeneity, as indicated by an I^2 value of 0% and a P-value of 0.23. The results obtained from the comprehensive analysis using a random effect model (odds ratio [OR] = 0.01, 95% [CI]: 0.00 to 0.04), $p=0.23$. The result shows no statistical significance of NPWT in reducing incident adverse events.

Amputation Rate

To gather data on patient amputation rates, a set of four studies was conducted. The analysis revealed no statistically significant heterogeneity among the studies included in the research. The findings indicate that there is no statistically significant reduction in the amputation rate with the use of NPWT (Odds Ratio [OR] = 0.01, 95% Confidence Interval [CI]: 0.00 to 0.02, $p = 0.81$).

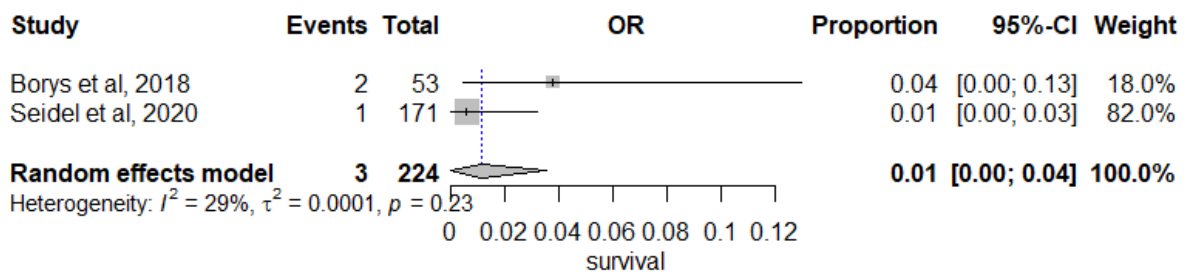


Figure 2. Adverse Event After Intervention

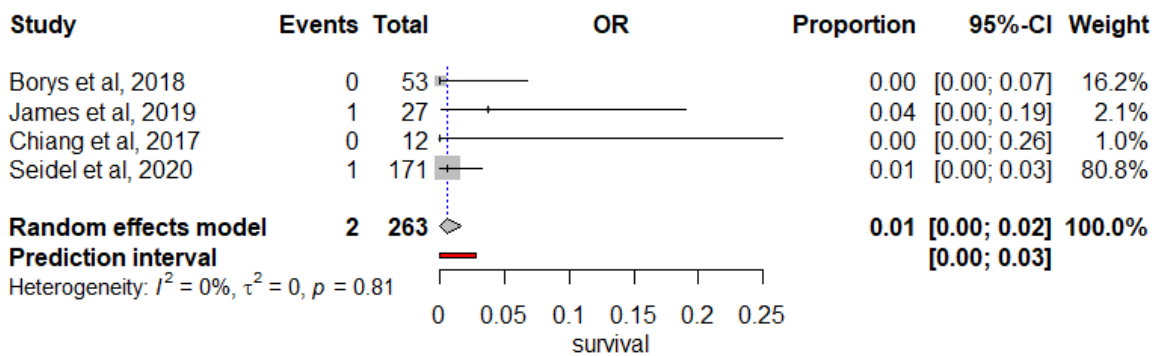


Figure 3. Amputation of Extremities

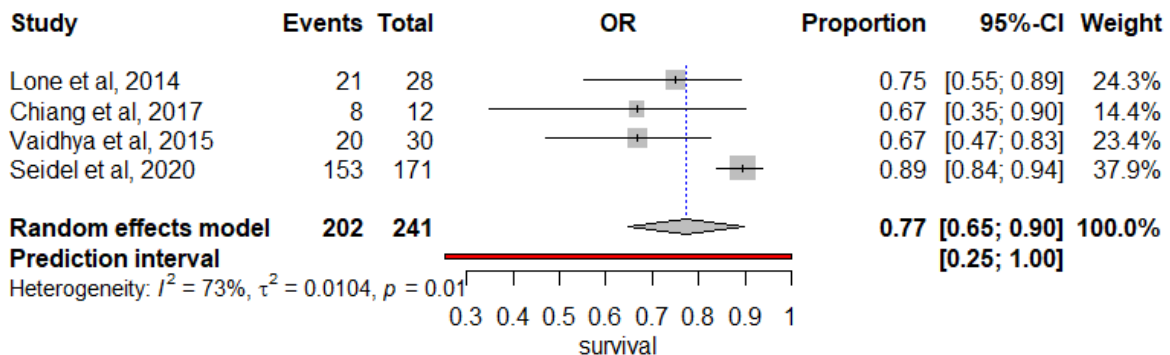


Figure 4. Wound Healing Rate

DISCUSSION

A diabetic foot ulcer (DFU) stands as a prevalent complication stemming from inadequately managed diabetes mellitus. Diabetic foot ulcers impact millions of people globally annually, leading to heightened risks of amputation and mortality. The societal consequences of diabetic foot problems are substantial, affecting individuals with disabilities, leading to hospital admissions, and incurring substantial healthcare expenses.

While, The psychological impact of diabetic foot issues can be profound. It often results in emotional distress, anxiety, and depression for individuals dealing with these complications. The fear of amputation, pain, and the challenges of managing the condition can take a toll on a person's mental well-being. Additionally, the lifestyle changes required to manage diabetic foot problems, such as restricted mobility and potential dependency on others for care, can lead to feelings of frustration and a reduced

quality of life. The psychological impact of diabetic foot issues should not be underestimated, and addressing the emotional well-being of individuals is an important aspect of their overall care. Although substantial endeavors have been made, the quest for an efficient remedy to facilitate DFU healing continues to be a prominent clinical challenge, representing a significant issue within the realm of chronic wound management.²⁰⁻²³

In patients diagnosed with diabetes, elevated blood glucose levels give rise to atypical cell proliferation, impairment of vascular endothelial cells, alterations in the micro-environment, and an inflammatory reaction within the peripheral nerves and blood vessels. Several factors are crucial in the complex healing process of diabetic foot ulcers (DFU).^{24, 20}

The primary approaches for treating diabetic foot ulcers involve surgical removal of damaged tissue, alleviating pressure on weight-bearing areas, addressing lower extremity ischemia and foot infections, and promptly referring patients to multidisciplinary care, constituting the initial treatment protocols.²⁰

Diabetic Foot Ulcer (DFU) is considered one of the most concerning complications of type 2 diabetes mellitus. DFU is a condition affecting the feet of diabetic individuals and is characterized by sensory, motor, autonomic neuropathy, as well as macrovascular and microvascular issues. Several factors contribute to the development of DFU, including elevated blood sugar levels, neuropathy, joint limitations, and deformities. The diagnostic process for DFU typically starts with a medical history, which includes details about previous ulcers, amputations, injuries, and the patient's diabetes history. Physical examination involves assessing vascular health, neurological and musculoskeletal function, as well as evaluating the presence of any infections. Effective management of DFU often requires a multidisciplinary approach.²⁵

Diabetic foot ulcers are a prevalent and perilous manifestation of diabetes, arising from a combination of causes, including repetitive stress, inadequate glucose management, and neuropathy. Associated immunological deficits are known to result in the swift development of deep-tissue infections via the formation of skin ulcers. The diagnostic process encompasses clinical assessment, culture and sensitivity testing, radiography, and imaging techniques. The comprehensive management of diabetic foot ulcers (DFU) encompasses many interventions, such as antibiotic therapy, surgical debridement, meticulous wound care, and metabolic optimization.^{26,27}

Muscle flaps are commonly used to reconstruct infected wounds due to their ability to enhance vascular perfusion and fill empty spaces. However, The utilization of muscle flaps to address large diabetic foot ulcers (DFUs) presents challenges in individuals with limited blood circulation in their lower limbs.²⁸ Complications of diabetic foot ulcer commonly connected with muscle flaps include hematoma formation, wound dehiscence, flap loss seroma development, fat necrosis, scarring, and delayed healing, rendering them less preferable in specific scenarios.²⁹ The conventional method for managing foot wounds often entails the utilization of moist-to-dry dressings and the implementation of skin grafts. Nevertheless, This method has certain disadvantages, including a prolonged healing period, an elevated risk of infections, heightened levels of discomfort, and difficulties in promoting the optimal formation of granulation tissue when tendons, bones, or implants are exposed.³⁰ Certain surgeons may opt for extracting extensor tendons and employ methods such as negative pressure wound therapy (NPWT) or moist dressings to facilitate the formation of granulation tissue, which might result in enduring impairment and deformation of the foot.^{30,31}

Negative pressure wound therapy (NPWT) is a therapeutic approach that utilizes differential internal and exterior pressures to promote the removal of deeply buried necrotic tissue and wound fluids. This strategy has been shown to successfully reduce the occurrence of wound infection and promote a favorable moist wound environment, hence facilitating wound healing.³² However, the signs presented regarding the repercussions of this phenomenon in clinical practice demonstrate a significant degree of variability.³³

In the previous study, it was stated that Negative Pressure Wound Therapy (NPWT) outperforms traditional methods in the treatment of diabetic foot ulcers. NPWT not only reduces the time to rehospitalization but also lowers the risk of amputation or surgical removal of the diabetic foot. Despite the higher costs associated with NPWT, the approach proves to be cost-effective. It is essential to emphasize the importance of employing proper therapy techniques and selecting patients judiciously.³⁴

Another study provided an explanation that NPWT has brought about a significant transformation in the management of challenging and persistent wounds. It also serves as an adjunct therapy for preparing wounds before surgical procedures like skin grafts and flap surgery, contributing to improved wound healing rates. This chapter provides a comprehensive overview of the NPWT device's composition, mechanism of action, application techniques, advantages, suitable use cases, restrictions, potential side effects, and innovative developments.³⁵

However, it's important to note that while NPWT is a valuable tool for wound healing, it may pose challenges in treating wounds with inadequate tissue oxygenation, such as diabetic foot ulcers. NPWT can reduce tissue oxygenation in wound areas due to the external compression applied by the foam and tubing. The foot, being

particularly sensitive to ischemia, and considering that diabetes often coincides with atherosclerosis, caution is necessary when applying NPWT to diabetic foot ulcers to minimize compression pressure.³⁵

The result of this study shows the positive impact of NPWT as a promising intervention to promote the healing rate for chronic wounds such as diabetic foot ulcers with (OR) of 0.77 95% (CI) [0.65, 0.90], $p=0.01$. This result was supported by research from Liu et al.³⁶ who conducted a meta-analysis that identified 11 randomized controlled trials (RCTs) and included 1044 patients. Moreover, a significant proportion of these articles exhibited a deficiency in giving full explanations of the randomized techniques and processes. Specifically, only three studies included specific information addressing allocation concealment. The present study included nine randomized controlled trial (RCT) articles published within the past decade, which specifically examined the application of negative pressure wound therapy (NPWT).³⁷ In the realm of wound care, conventional methodologies have involved the implementation of various dressings to facilitate and accelerate the wound healing process. However, it is imperative to recognize that these dressings tend to adhere to the wound's scab, perhaps causing harm to the formation of granulation tissue during dressing replacement. Consequently, there exists a potential for impeding the overall progress of wound healing. Numerous studies have provided evidence supporting the efficacy of Negative Pressure Wound Therapy (NPWT) in enhancing the wound microenvironment, modulating microvascular hemodynamics, mitigating wound infections, and facilitating the regeneration of endothelial cells.³⁸ The findings of this meta-analysis revealed that the most commonly seen adverse effects during treatment were wound edema, bleeding, pain, and infection.

The results of this study suggest that the utilization of NPWT did not lead to a

greater prevalence of unfavorable consequences. However, it is imperative to highlight that no statistically significant difference was seen between the two treatment regimens. The current study did not incorporate a statistical analysis of the negative pressure value employed in the Negative Pressure Wound Therapy (NPWT) approach. Numerous studies have provided evidence regarding the importance of maintaining a negative pressure range of 50-200 mmHg to manage excessive bleeding and effectively promote optimal wound healing. Moreover, accurate identification and management of infections in cases of diabetic foot infection, along with the administration of suitable antibiotic therapy, are of utmost importance.³⁹ It is critical to prioritize the optimization of blood glucose levels as a key factor in improving wound healing and reducing the harmful effects on cellular immunity, thereby lowering susceptibility to infections.⁴⁰

The study provides detailed information on the challenges and complications associated with DFUs, the diagnostic process, and various treatment methods, with a specific focus on NPWT. The study the need for further research, particularly in exploring the impact of NPWT on gene expression in diabetic patients, which can be considered a novel area of investigation. The article hints at a novel aspect by suggesting that NPWT may impact gene expression in individuals with diabetes. This potential influence on gene expression could open up new avenues for research into the underlying mechanisms of NPWT in wound healing. Future research could delve into optimizing the application of NPWT in terms of negative pressure levels. Future research could explore whether tailoring NPWT parameters to individual patient characteristics could enhance its effectiveness and to explore emerging or innovative therapeutic approaches for diabetic foot ulcers.

The limited number of studies to analyze has a possible impact on this meta-analysis's result, resulting in a potential bias. In order to conduct a thorough analysis of the effectiveness of Negative Pressure Wound Therapy (NPWT), additional samples are necessary. Additionally, a recent study has shown evidence that negative pressure wound therapy (NPWT) can impact gene expression alterations in persons diagnosed with diabetes. This discovery implies that exploring the influence of NPWT on gene expression holds potential as a fruitful area of investigation for future research within the discipline. Further research is needed to confirm this finding.

CONCLUSION

This meta-analysis aims to assess the effectiveness and safety of negative pressure wound therapy (NPWT) in managing diabetic foot ulcers (DFUs). The result of our analysis shows that NPWT has a significant effect on the healing rate. These findings of our study indicate that the application of NPWT is a viable strategy for expediting the process of wound healing in diabetic foot ulcers. NPWT can be a promising intervention for patients with diabetic foot ulcers to reduce morbidity. Nevertheless, it is imperative to meticulously manage and adjust the negative pressure value to mitigate any potential risk of bleeding in the wound. To confirm these findings, further research is needed.

ACKNOWLEDGMENTS

The authors would like to extend our sincere acknowledgments to Prima Medika Hospital in Denpasar, Indonesia, for their invaluable support and contributions in conducting this study

CONFLICT OF INTEREST

The authors assert that there are no conflicts of interest about the publishing of this study.

FUNDING DISCLOSURE

None.

AUTHOR CONTRIBUTION

NPGRS and IPKM designed the study. The manuscript was originally composed by the authors NPGRS and IPKM. Moreover, the author conducted a thorough examination and provided their endorsement for the definitive iteration of the document.

REFERENCES

- Zaitseva EL et al. The study of influence of different methods of local treatment on wound healing in patients with diabetic foot ulcers. *Ann Russ Acad Med Sci*; 71.
- WHO. Diabetes, <https://www.who.int/news-room/fact-sheets/detail/diabetes> (2023).
- Uğurlar M et al. Comparison of two different vacuum-assisted closure (VAC) treatments of multiple chronic diabetic foot wounds in the same extremity. *Foot Ankle Surg* 2017; 23: 173–8.
- Saluja S., et al. Foot ulceration and its association with mortality in diabetes mellitus: A meta-analysis. *Diabet Med* 2020; 37: 211–218.
- Brownrigg JRW, et al. Influence of foot ulceration on cause-specific mortality in patients with diabetes mellitus. *J Vasc Surg* 2014; 60: 982–986.e3.
- Chammas NK, et al. Increased Mortality in Diabetic Foot Ulcer Patients: The Significance of Ulcer Type. *J Diabetes Res* 2016; 2016: 1–7.
- Jupiter DC, et al. The impact of foot ulceration and amputation on mortality in diabetic patients. I: From ulceration to death, a systematic review. *Int Wound J* 2016; 13: 892–903.
- Walsh JW, et al. Association of diabetic foot ulcer and death in a population-based cohort from the United Kingdom. *Diabet Med* 2016; 33: 1493–1498.
- Brennan MB, et al. Diabetic foot ulcer severity predicts mortality among veterans with type 2 diabetes. *J Diabetes Complications* 2017; 31: 556–561.
- Hasan MY, Teo R NA. Negative-pressure wound therapy for management of diabetic foot wounds: a review of the mechanism of action, clinical applications, and recent developments. *Diabet Foot Ankle* 2015; 6: 27618.
- Wynn M FS. The efficacy of negative pressure wound therapy for diabetic foot ulcers: A systematised review. *J Tissue Viability* 2019; 28: 152–60.
- Mo, J., et al. Autologous wound margin point columnar full-thickness skin grafting combined with negative pressure wound therapy improves wound healing in refractory diabetic foot ulcers. *Int Wound J* 2023; 20: 1506–1516.
- Borys S et al. Negative-pressure wound therapy for management of chronic neuropathic noninfected diabetic foot ulcerations—short-term efficacy and long-term outcomes. *Endocrine* 2018; 62: 611–616.
- N, Chiang N et al. Effects of topical negative pressure therapy on tissue oxygenation and wound healing in vascular foot wounds. *J Vasc Surg* 2017; 66: 564–571.
- SM J et al. Comparison of Vacuum Assisted Closure Therapy and Conventional Dressing on Wound Healing in Patients with Diabetic Foot Ulcer: A Randomized Controlled Trial. *Niger J Surg* 2019; 25: 14–20.
- Lone AM, et al. Vacuum-assisted closure versus conventional dressings in the management of diabetic foot ulcers: a prospective case–control study. *Diabet Foot Ankle* 2014; 5: 23345.
- Seidel D, et al. Negative pressure wound therapy compared with standard moist wound care on diabetic foot ulcers in real-life clinical practice: results of the German DiaFu-RCT. *BMJ Open* 2020; 10: e026345.
- Vaidhya N, Panchal A AM. A new cost-

- effective method of NPWT in diabetic foot wound. *Indian J Surg* 2015; 77: 525–529.
19. Shukr I AM. Comparison of negative pressure wound therapy using vacuum-assisted closure with advanced moist wound therapy in the treatment of diabetic foot ulcers. *J Coll Physicians Surg Pak* 2015; 25: 789–793.
 20. Armstrong, D. G., et al. Diabetic foot ulcers: a review. *JAMA* 2023; 330: 62–75.
 21. Bandyk DF. The Diabetic Foot: Pathophysiology, Evaluation, and Treatment. *Semin Vasc Surg* 2018; 31: 43–48.
 22. Tran, H.Q et al. Recent Advances in Functional Wound Dressings. *Adv Wound Care*.
 23. Mrozikiewicz-Rakowska B, et al. Allogenic Adipose-Derived Stem Cells in Diabetic Foot Ulcer Treatment: Clinical Effectiveness, Safety, Survival in the Wound Site, and Proteomic Impact. *Int J Mol Sci* 2023; 24: 1472.
 24. Shu X. et al. Efficiency of stem cell based therapy in the treatment of diabetic foot ulcer: a meta-analysis. *Endocr J* 2018; 65: 403–413.
 25. Decroli E. *Diagnostic of Diabetic Foot Ulcer*. Unand/RSUP Dr. M. Djamil Padang, 2011.
 26. Frykberg RG, et al. A multinational, multicenter, randomized, double-blinded, placebo-controlled trial to evaluate the efficacy of cyclical topical wound oxygen (TWO2) therapy in the treatment of chronic diabetic foot ulcers: the TWO2 study. *Diabetes Care* 2020; 43: 616–624.
 27. Everett E MN. Update on management of diabetic foot ulcers. *Ann N Y Acad Sci* 2018; 1411: 153–165.
 28. Saha S. Hybrid Regenerative Therapy for Successful Reconstruction of an Infected Traumatized Diabetic Foot Wound. *Plast Reconstr Surgery–Global Open* 2023; 11: e5213.
 29. Huang YY, et al. Survival and associated risk factors in patients with diabetes and amputations caused by infectious foot gangrene. *J Foot Ankle Res* 2018; 11: 1–7.
 30. Saha S. Minimally Invasive Successful Reconstruction of a Severely Traumatized Upper Extremity Using Platelet-Rich Plasma and Tissue Scaffold: A Case Report. *Surg J* 2022; 8: e28-33.
 31. Lipsky BA, et al. Guidelines on the diagnosis and treatment of foot infection in persons with diabetes (IWGDF 2019 update). *Diabetes Metab Res Rev* 2020; 36: e3280.
 32. Normandin S, et al. Negative pressure wound therapy: mechanism of action and clinical applications. *InSeminars Plast Surg* 2021; 35: 164–170.
 33. Grecu AF, et al. Platelet-rich fibrin and its emerging therapeutic benefits for musculoskeletal injury treatment. *Medicina (B Aires)* 2019; 55: 141.
 34. Bogucka, Julia et al. The effectiveness of negative pressure wound therapy compared to the traditional method in the treatment of diabetic foot. *J Educ Heal Sport* 2023; 16: 25–31.
 35. Han S-K. Negative-Pressure Wound Therapy (NPWT). Innovations and Advances in Wound Healing. *Springer Nat Singapore* 2023; 257–273.
 36. Liu S, et al. Evaluation of negative-pressure wound therapy for patients with diabetic foot ulcers: systematic review and meta-analysis. *Ther Clin Risk Manag* 2017; 533–544.
 37. Raposio E, et al. Adipose-derived Stem Cells Added to Platelet-rich Plasma for Chronic Skin Ulcer Therapy. *Wounds a Compend Clin Res Pract* 2016; 28: 126–131.
 38. Lerman B, et al. The SNaP™ wound care system: a case series using a novel ultraportable negative pressure wound therapy device for the treatment of diabetic lower extremity wounds.
 39. Zhang J, et al. Effectiveness and safety of negative-pressure wound therapy for

diabetic foot ulcers: a meta-analysis.
Plast Reconstr Surg 2014; 134: 141–151.
40. Ji S, et al. Consensus on the application

of negative pressure wound therapy of
diabetic foot wounds. *Burn Trauma*
2021; 9: tkab018.