

COMPARISON OF INFLAMMATORY RESPONSE BETWEEN PLATELET RICH PLASMA 20% AND AUTOLOGOUS SERUM 20% IN EXPERIMENTALLY-INDUCED CORNEAL ALKALI BURN

**Amelia Safitri Ramadhani^{1*}, Ismi Zuhria², Alphania Rahniayu³, Endang Retnowati⁴,
Windhu Purnomo⁵**

¹Faculty of Medical, Universitas Airlangga

²Faculty of Medical, Department of Ophthalmology, Universitas Airlangga

³Faculty of Medical, Universitas Airlangga

⁴Faculty of Medical, Universitas Airlangga

⁵Faculty of Medical, Universitas Airlangga

* Corresponding author: ameliasramadhani08@gmail.com

ABSTRACT

Objective to compare the inflammatory response between platelet rich plasma 20% and autologous serum 20% on cornea after sodium hydroxide exposure. Methods a true experimental study with two groups post-test design. A total of 18 rabbits were used in this study and allocated into two groups. After collecting intravenous blood samples from both group, platelet rich plasma 20% and autologous serum 20%, respectively, were obtained by centrifugation and dilution. Alkali burns were inflicted on the central cornea of each rabbit's right eye by applying a round filter paper, 7.0 mm in diameter, soaked in 1N NaOH for 60 s. Clinical outcome of the inflammation were observed everyday for seven days. On the seventh day, corneal tissue was collected for histopathological examination to evaluate amount of PMN neutrophils that infiltrate the central cornea. All data were statistically analyzed for difference between the study groups. Results statistical analysis shows statistically difference in clinical inflammatory feature of conjunctival hyperemia at day 3 until day 7, in which the group that received PRP 20% got lower conjunctival hyperemia grading compared to the group that received AS 20%. Other clinical features, corneal opacity and epithelial defect, shows no statistically difference between two groups. Histopathological examination shows lower amount of PMN neutrophil infiltration to the central cornea on PRP group, compared to AS group. Conclusio Platelet-rich plasma 20% eyedrop can be used as one of adjuvant therapies

and has better control of inflammatory response towards alkaline injury of the cornea during acute phase.

Keyword : alkali injury, corneal alkali burn, autologous serum, platelet rich plasma

INTRODUCTION

Chemical trauma to the eye is an eye emergency that requires immediate and intensive management to reduce the risk of developing severe complications and loss of vision. Slow epithelialization processes, persistent ulcers, corneal perforation, and angiogenesis are the most common complications and are the result of inflammatory processes, neovascularization, and corneal conjunctivalization (Baradaran-Rafii et al. 2017; Ke et al. 2015; Saud et al. 2012; Zhao et al. 2009).

Chemical trauma most often occurs between the ages of 20 and 40 years, especially in factory or chemical industry employees. As many as 20% of cases of chemical trauma result in significant visual and cosmetic impairment. Inflammation is an important factor affecting the course of disease due to chemical trauma (Eslani et al. 2014; Kaur, Sinha, dan Sharma 2014; Saud et al. 2012; Ventocilla 2017).

Autologous serum (AS) and platelet-rich plasma (PRP) trigger epithelialization because they contain various growth factors such as epidermal growth factor (EGF), vitamin A, fibroblast growth factor (FGF), fibronectin, nerve growth factor (NGF), substance P,

antiproteases like α 2-macroglobulin, and mucin expression.

In the last decade, several studies have reported that the use of platelet-rich plasma (PRP) is a new therapeutic modality in various medical fields, including ophthalmology. A study by Khaksar et al showed a significantly lower inflammatory reaction in the eyes of rabbits exposed to alkaline trauma and treated with subconjunctival PRP. Tanidir et al examined the effect of subconjunctival PRP injection on healing of the corneal epithelium, and obtained better healing results, in the form of more stable fibroblast migration, faster epithelial regeneration, and less inflammation in the PRP-treated group compared to the control group. Bashkaran et al investigated the anti-inflammatory effect of Tualang honey on alkaline chemical trauma of the cornea of rabbits with the result that there were no significant differences in clinical inflammation signs or histopathological examination of PMN leukocyte cell infiltration between the group treated with Tualang honey and the group treated with conventional therapy. (Gunay et al. 2015; Khaksar et al. 2013; Oh et al. 2012; Tanidir et al. 2010).

METHODS

This study is a true experimental study with a two-group post test design in experimental animals to compare the inflammatory response between 20% platelet-rich plasma therapy and 20% autologous serum on the cornea after NaOH exposure.

The population of this study were eyeballs of adult New Zealand white rabbits (*Oryctolagus cuniculus*), male sex, 9-12 months old, 2.5-3.5 kg body weight, healthy condition and no abnormalities in both eyes.

The facilities used in this study included rabbit cages containing 1 rabbit each, with optimal room temperature, adequate ventilation and good nutrition (food and drink). All rabbits get food and drink in equal portions.

RESULTS

In the first group, 20% PRP eye drops were prepared, while in the second group, 20% AS eye drops were prepared (table 1). The right eye of each experimental animal in both groups was then exposed to an alkaline compound, namely 1N NaOH solution, for 60 seconds, and received 20% PRP eye drop therapy for the first

Prior to the study, the rabbits underwent an anterior segment examination using a handheld slitlamp and a fluorescein test. Blood sampling was carried out on experimental rabbits in each group. The experimental rabbits in each treatment group were anesthetized using ketamine hydrochloride i.m. 5% (30 mg/kg) before administration of local anesthetic in the form of 1% proparacaine hydrochloride eye drops. Clinical evaluation of the rabbit's right eye was carried out with a handheld slitlamp on days 1 to 7 after exposure to NaOH. The variables used in the clinical assessment were the degree of corneal inflammation (based on conjunctival hyperemia, corneal edema, and corneal epithelial defects).

group, and 20% US eye drop therapy for the second group.

In the first group, 20% PRP was prepared for each experimental animal, and the total volume of 20% PRP eye drops was 8 mL. Whereas in the second group, 20% AS was prepared for each experimental animal, and the total volume of 20% AS eye drops was 16 mL.

Kelompok Perlakuan	Jumlah	Persentase (%)
<i>Platelet-Rich Plasma</i> 20%	9	50
<i>Autologous Serum</i> 20%	9	50
Total	18	100

Table 1. Distribution of research subject groups

Assessment of clinical signs of inflammation was carried out based on a study conducted by Bashkaran et al in 2011, with the distribution of inflammation degrees as follows: normal if there is no conjunctival hyperemia, corneal opacities, or epithelial defects; mild if mild/sectoral dilation of the conjunctival blood vessels is found, details of the iris are still visible, epithelial defects $< \frac{1}{4}$ surface of the cornea; moderate if there is

diffuse dilation of the conjunctival blood vessels, iris details are not visible, epithelial defects $\frac{1}{4}$ to $\frac{1}{2}$ surface of the cornea; and severe if there is significant dilation of the conjunctival blood vessels, no pupils are visible, epithelial defects $> \frac{1}{2}$ of the corneal surface. Representative images as well as statistical analysis of the comparative clinical signs of inflammation in the two groups are shown in Figure 1, Figure 2, and Table 2.

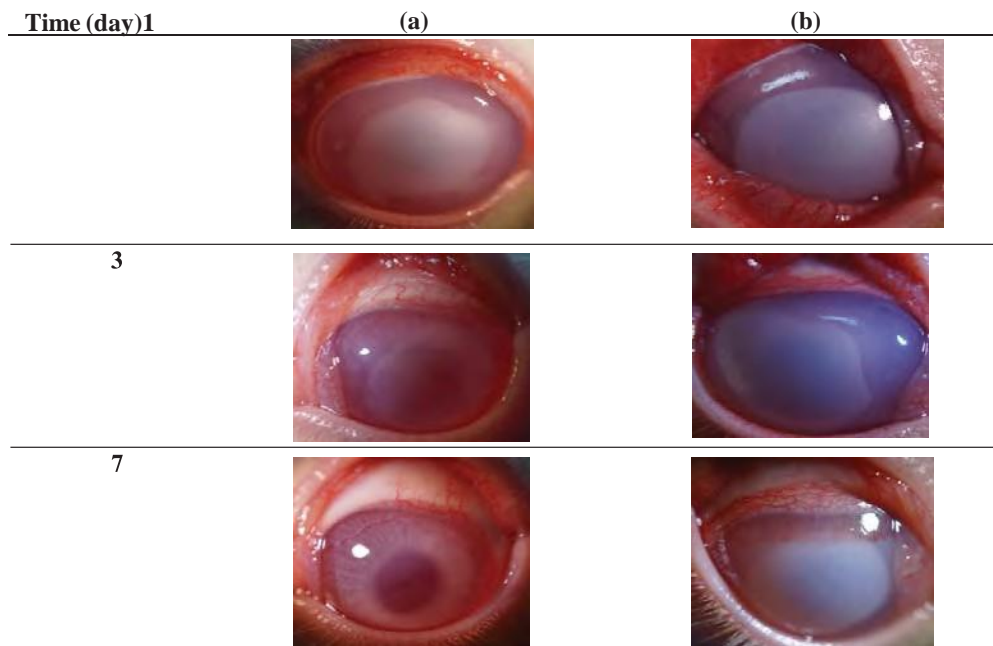


Figure 5.1 Evaluation of clinical signs of inflammation in the form of conjunctival hyperemia and corneal cloudiness after exposure to 1N NaOH with 20% PRP and 20% AS eye drop therapy. The group treated with 20% PRP eyedrops (a) showed a better degree of clinical inflammation than the 20% AS eyedropped group (b).

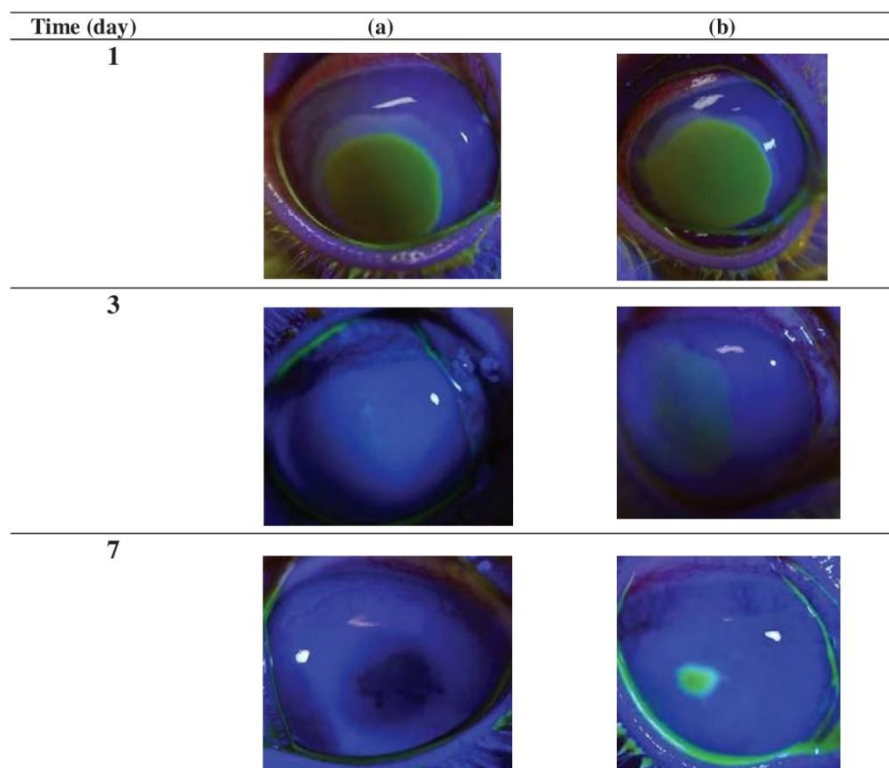


Figure 2 Evaluation of clinical signs of inflammation in the form of defects in the corneal epithelium after exposure to 1N NaOH with PRP 20% (a) and AS 20% (b) eye drop therapy. The group with 20% PRP eyedrops (a) showed a smaller area of epithelial defects than the 20% US eyedrops group (b).

Hiperem i Konjung - tiva (harike-)	PRP 20% n=9				AS 20% n=9				P value
	N	R	S	B	N	R	S	B	
1	0	0	1	8	0	0	0	9	0,317
2	0	1	1	7	0	0	0	9	0,146
3	0	2	4	3	0	0	2	7	0,047
4	1	3	4	1	0	1	1	7	0,010
5	1	4	4	0	0	1	6	2	0,027
6	1	6	2	0	0	1	8	0	0,006
7	1	7	1	0	0	2	7	0	0,005

Table 2 Results of evaluation of clinical signs of inflammation (conjunctival hyperemia) day 1 to. 7th with N = normal, R = mild, S = moderate, B = severe. SMann-Whitney test, significant if $p < 0.05$.

Table 2 shows the results of observations of clinical signs of inflammation in the form of conjunctival hyperemia. There was a significant difference in the PRP 20%

and AS 20% treatment groups on days 3, 4, 5, 6, and 7. Meanwhile, on days 1 and 2, differences were not statistically significant.

Kekeruha nKornea (hari ke-)	PRP 20% n=9				AS 20% n=9				P value
	N	R	S	B	N	R	S	B	
1	0	0	2	7	0	0	0	9	0,145
2	0	1	2	6	0	0	0	9	0,066
3	0	3	2	4	0	0	1	8	0,039
4	1	2	4	2	0	1	1	7	0,031
5	1	2	4	2	0	1	3	5	0,120
6	1	2	4	2	0	1	3	5	0,120
7	2	2	4	1	0	2	3	4	0,105

Table 3 Results of evaluation of clinical signs of inflammation (corneal opacities) from day 1 to. 7th with N = normal, R = mild, S = moderate, B = severe. Mann-Whitney test, significant if $p < 0.05$.

Table 5.3 shows the results of observations of clinical signs of inflammation in the form of corneal opacities. There was a significant difference between the PRP 20%

and AS 20% treatment groups on day 3 and day 4. Whereas on day 1, 2, 5, 6, 7 the differences were not statistically significant.

Luas Defek Epitel (hari ke-)	PRP 20% n=9				AS 20% n=9				P value
	N	R	S	B	N	R	S	B	
1	0	0	9	0	0	0	9	0	1,000
2	0	9	0	0	0	9	0	0	1,000
3	0	9	0	0	0	9	0	0	1,000
4	0	9	0	0	0	9	0	0	1,000
5	1	8	0	0	0	9	0	0	0,317
6	1	8	0	0	0	9	0	0	0,317
7	1	8	0	0	0	9	0	0	0,317

Table 4 Observation results of clinical signs of inflammation (area of epithelial defect) day 1 to. 7th with N = normal, R = mild, S = moderate, B = severe. Mann-Whitney test, significant if $p < 0.05$.

Table 4 shows the results of observations of clinical signs of inflammation in the form of extensive corneal epithelial defects. There was no statistically significant difference between the two groups, from day 1 to day 7.

After being sacrificed and enucleated, the cornea of each experimental animal was taken and histopathological analysis was carried out. The corneal tissue was fixed in

10% normal buffered formalin solution, then embedded in a paraffin block. Corneal tissue was then cut centrally with a thickness of 5 μm and stained with hematoxylin eosin. Figure 5.3 shows representative images of histopathological examination regarding the number of neutrophil PMN inflammatory cell infiltration in the group treated with 20% PRP and 20% AS.

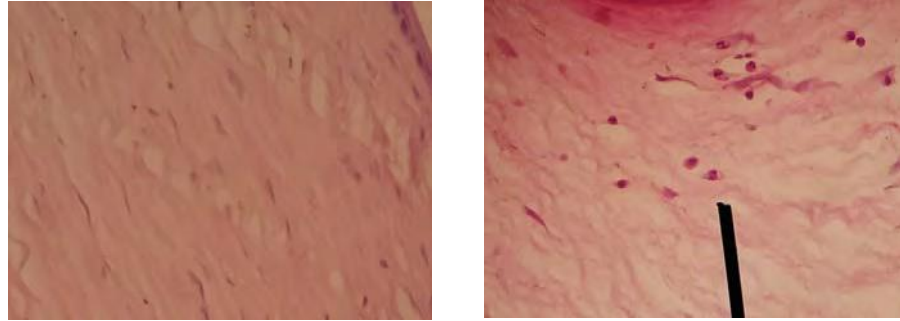


Figure 5.3 Representative histopathological comparison of neutrophil PMN inflammatory cell infiltration in the central cornea. After staining with hematoxylin eosin, there was more neutrophil PMN inflammatory cell infiltration in the group with 20% AS eye drop treatment (b) compared to the 20% PRP eye drop treatment group (a).

Table 5 presents the number of neutrophil PMN inflammatory cell infiltration in the central cornea after treatment in both groups. Based on statistical analysis, there was a significant difference ($p < 0.005$), in which

the number of neutrophil PMN inflammatory cell infiltration in the group that received PRP eye drop therapy was 20% less (mean 6.5) compared to the AS therapy group 20% (mean 12, 5).

DISCUSSION

Alkaline chemical trauma is the type of trauma that has the most serious impact on the anterior segment of the eyeball. Slow progressing epithelialization, persistent ulcers, corneal perforation and angiogenesis are the main complications and result from inflammation, neovascularization and conjunctivalization of the cornea, which can threaten the patient's vision.

Blood derivatives have the potential to stimulate tissue healing rates. Growth factors play an important role in epithelial integrity. Blood derivatives contain growth factors, cytokines, and other signaling molecules that are important in the process of cell turnover in epithelial and stromal tissues in the process of

healing corneal wounds. These molecules are also able to reduce inflammation due to epithelial damage and have antimicrobial effects (Anitua et al. 2015; Freire et al. 2014).

Platelets are one of the main cells that contain proteins and growth factors that participate in homeostasis, tissue regeneration, immune response, and wound healing. In the ophthalmic field, Geerling et al reported that platelets influence the migration and differentiation of corneal epithelial cells and stimulate cell growth in in vitro cell culture. The main role of PRP is obtained from PDGF which is the first growth factor that appears in wounds to increase the number of repaired cells, stimulate angiogenesis, support the

growth of new blood vessels and activated macrophages.

Preparation of PRP eye drops in this study was carried out by taking 10 mL of blood from the auricular vein from a tube containing 0.5 mL of citrate dextrose (ACD) anticoagulant. The blood sample obtained was then centrifuged for 10 minutes at 3500 rpm to produce 2 fractions: the red fraction at the bottom contains erythrocytes, and the reddish yellow fraction above contains plasma components. The top layer, called the buffy coat, is rich in platelets and leukocytes. Plasma and buffy coat (BC) were then transferred to a new, sterile centrifugation tube. Then, the plasma and buffy coat were centrifuged again at 3500 rpm for 10 minutes,

so that 2 visible layers were obtained. The top 2/3 layer is referred to as PPP and discarded, and the bottom 1/3, as much as 1.5 mL, is PRP (Utomo et al. 2017).

Next, the first low-strength centrifugation (200-600g) was carried out and 3 layers were produced. The top layer and superficial BC were transferred to another sterile tube without anticoagulant, then a second centrifugation was carried out at a higher speed (700-2300g). After the second step, soft pellets (erythrocytes-platelets) were formed at the bottom of the tube. The upper two thirds of the volume (PPP) is discarded, while the lower 1/3 (5 mL plasma) is carefully homogenized to make PRP (Piccin et al., 2017).

BIBLIOGRAPHY

- Anitua, E., F. Muruzabal, A. Tayebba, A. Riestra, VL Perez, J. Merayo-Loves, dan G. Orive. 2015. “). Autologous Serum and Plasma Rich in Growth Factors in Ophthalmology: Preclinical and Clinical Studies.” *Acta Ophthalmology* 93:605–14.
- Baradaran-Rafii, A., M. Eslani, Z. Haq, E. Shirzadeh, MJ Huvard, dan AR Djalilian. 2017. “Current and Upcoming Therapies for Ocular Surface Chemical Injuries.” *The Ocular Surface* 15, n:48–64.
- Eslani, M., N. Andollo, J. Etxebarria, R. Hernaez-Moya, JA Duran, dan MC Morales. 2014. “The Ocular Surface Chemical Burns.” *Journal of Ophthalmology* 2014:1–9.
- Freire, V., N. Andollo, J. Etxebarria, R. Hernaez-Moya, JA Duran, dan MC Morales. 2014. “The Ocular Surface Chemical Burns.” *Journal of Ophthalmology* 33:614–20.
- Gunay, C., A. Sagliyan, S. Yilmaz, FM Kandemir, MC Han, M. Ozkaraca, dan K. Kulualp. 2015. “Evaluation of Autologous Serum Eyedrops for the Treatment of Experimentally Induced Corneal Alkali Burns.” *Revue Med Vet* 166 No. 3:-:63–71.
- Kaur, M., R. Sinha, dan N. Sharma. 2014. “Acute Chemical Injuries, Ocular Emergency.” 19 No. 9:41–45.
- Ke, Y., Y. Wu, X. Cui, X. Liu, M. Yu, C. Yang, dan X. Li. 2015. “Polysaccharide Hydrogel Combined with Mesenchymal Stem Cells Promotes the Healing of Corneal Alkali

- Burn in Rats.” *PLOS One* 10, n:1–16.
- Khaksar, E., SJ Aldavood, GR Abedi, R. Sedaghat, O. Nekoui, dan M. Zamaniahmadmahmudi. 2013. “The Effect of Sub-conjunctival Platelet-Rich Plasma in Combination with Topical Acetylcysteine on Corneal Alkali Burn Ulcer in Rabbits.” *Comparative Clinical Pathology* 22:107–22.
- Oh, HJ, JY Jang, Z. Li, SH Park, dan KC Yoon. 2012. “Effects of Umbilical Cord Serum Eye Drops in a Mouse Model of Ocular Chemical Burn.” *Current Eye Research* 37, n:1084–90.
- Saud, EE, HV Morales, LGC Marculino, JAP Gomes, S. Allodi, dan NCO Miguel. 2012. “Clinical and Histopathological Outcomes of Subconjunctival Triamcinolone Injection for the Treatment of Acute Ocular Alkali Burn in Rabbits.” *Cornea* 31, n:181–87.
- Tanidir, ST, N. Yuksel, O. Altintas, DK Yilidiz, E. Sener, dan Y. Caglar. 2010. “The Effect of Subconjunctival Platelet-Rich Plasma on Corneal Epithelial Wound Healing.” *Cornea* 29:664–69.
- Utomo, DN, Purwati, T. Damayanti, dan HW Nanang. 2017. “The Effect of Platelet Rich Plasma (PRP) in Anterior Cruciate Ligament (ACL) Reconstruction Surgery.” *Journal of Biomimetics, Biomaterials, and Biomedical Engineering* 30:97 – 102.
- Ventocilla, M. 2017. “Ophthalmologic Approach to Chemical Burns.” *Medscape*.
- Zhao, B., A. Ma, FL Martin, dan NJ Fullwood. 2009. “An Investigation Into Corneal Alkali Burns Using an Organ Culture Model.” *Cornea* 28, n:541–46.