

**COMPARISON IN CORNEAL COLLAGEN STRUCTURE BETWEEN 20%  
PLATELET RICH PLASMA AND 20% AUTOLOGOUS SERUM  
THERAPY POST NATRIUM HIDROKSIDA EXPOSURE  
(Experimental study on *Oryctolagus Cuniculus*)**

**Marisca<sup>1\*</sup>, Nila Kurniasari<sup>2</sup>, Endang Retnowati<sup>3</sup>, Windhu Purnomo<sup>4</sup>**

<sup>1</sup>Faculty of Medical, Universitas Airlangga

<sup>2</sup>Department of Anatomical Pathology, Universitas Airlangga

<sup>3</sup> Faculty of Medical, Universitas Airlangga

<sup>4</sup> Faculty of Public Health, Universitas Airlangga

\*Corresponding author: marisca802@gmail.com

**ABSTRACT**

Objective to compare therapy response between 20% PRP and AS 20% on cornea post sodium hydroxide exposure on collagen structure. Methods this is a true experimental study with post test only design on 18 New Zealand white rabbits. Sample were divided randomly to two groups, each with 9 rabbits. The right eye of each rabbit were exposed to alkali injury with 1N NaOH under general anesthesia. First group was given 20% PRP eyedrops and 20% AS for the second group. And the end of the 7 day periode, all rabbits were euthanized and enucleated to obtain histopathological data. Collagen density, collagen thickness and keratocyt cell were evaluated. The result will be analyzed, ratio scale data will be tested with independent T- test, and ordinal scaled data will be tested with Mann-Whitney test. Result The collagen density in the 20% PRP group shows 88.9% grade 2 and 44.4 % grade 2 for the 20% AS group. The collagen thickness in the 20% PRP group is 55.41 and 67.62 for the 20% AS group. The keratocyt cell count in the 20% PRP group are 54.56 and 45.47 in the 20% AS group. There is significant difference in the collagen density between 20% PRP and 20% AS treatment ( $p=0.066$ ). There is significant difference in the collagen thickness between 20% PRP and 20% AS treatment ( $p=0,224$ ). There is significant difference in the keratocyt cell count between 20% PRP and 20% AS treatment ( $p=0,227$ ). Conclusion From the statistik analysis shows that there is no significant difference in corneal collagen structure between 20% PRP and 20% AS therapy post natrium hidroxida exposure, from our study there is no significant better corneal healing parameters in post alkali chemical ocular injury with 20% PRP eyedrops compare to 20% AS eyedrops.

**Keyword : Corneal Collagen, Platelet Rich Plasma, Autologous Serum, Natrium Hidroksida**

## INTRODUCTION

Ocular chemical trauma is an emergency that requires prompt treatment, intensive evaluation, and adequate treatment. Complications that are often found are suspected because the therapy given has not been able to provide maximum results. In a recent study, the use of blood derivatives, namely Platelet Rich Plasma (PRP) and Autologous Serum (AS) were used as adjuvant therapy in chemical trauma of the alkaline ocular, but their use is still controversial, due to the lack of optimization and standardization of the preparation protocol. This is what is still a challenge in handling chemical trauma to the ocular base (Hassel & Birk., 2010; Khaskar, et al. 2011; Sigh, et al., 2013; Anitua, 2016).

Based on data from the Centers for Disease Control (CDC), in 2000 around 1 million people in the United States experienced visual impairment due to trauma. Recent studies state that there is an increased incidence of ocular chemical trauma by 7.7-18% of all existing ocular trauma. Internationally, 80% of chemical trauma is due to occupational exposure.

Conventional therapy for ocular chemical trauma so far is administration of tear replacement fluids, topical corticosteroids, topical antibiotics, and ascorbic acid based on

indications. The content of growth factors and several wound healing factors, cytokines, vitamin A, and bacteriostatic components in PRP and AS are very important in the repair and regeneration of stromal collagen tissue damaged by saponification reactions of chemical trauma to the base ocular (Tanidir., 2010; Kim, et al. al., 2012; Lekhanot, et al., 2013; Kaur, 2014; Semeraro, et al., 2014; Salman & Gundogdu., 2015).

Based on several studies, long-term use of conventional therapy can cause serious side effects, including (1) The danger of preservatives contained in tear replacement fluids can cause irritation and toxic reactions to the cornea. (2) Long-term use of corticosteroid drops can result in cataracts and increased intraocular pressure.

According to research by Anitua et al, Khaskar et al, and Salman and Gundogdu, growth factors and several proteins contained in AS are able to help the process of proliferation and migration of keratocytes (stromal fibroblasts) which can increase the production of collagen and stromal proteoglycans, resulting in an improvement in density. stromal collagen which will reduce corneal turbidity, Luo H et al, investigated the use of the amnion membrane as a graft in alkaline ocular trauma which can provide repair of stromal collagen.

## METHODS

This study is a true experimental study with a post test only design in experimental

rabbits to compare the response of 20% PRP and 20% AS in the cornea after exposure to NaOH..

The population of this study were eyeballs of adult New Zealand white rabbits (*Oryctolagus cuniculus*), male, aged 6-11 months, body weight 2.5 – 3.5 kg, healthy condition and no abnormalities in both eyes. The sample for this study was the right eyeball of an adult New Zealand white rabbit (*Oryctolagus cuniculus*), male, aged 6 – 11 months, body weight 2.5 – 3.5

## RESULTS

The results of this study were obtained based on histopathological examination with Hematoxylin Eosin and Masson's trichrome staining. Further statistical analysis was to determine differences in collagen density, collagen thickness and the number of corneal keratocyte cells. From histopathological examination, everything can be assessed and a representative examination can be carried out so that it can be properly analyzed.

The population of this study were the eyeballs of New Zealand rabbits (*Oryctolagus cuniculus*) from 9-12 months old male rabbits with a body weight of 2.5-3.0 kg as many as 18 rabbits. Observation and therapy were carried out for 7 days, and during this period each rabbit in both groups received additional therapy with

kg, healthy condition and no abnormalities in both eyes.

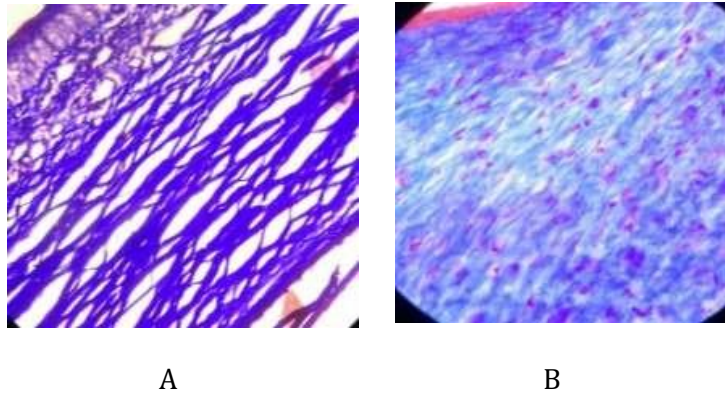
The data that has been collected is analyzed, the ratio scale data will be tested with the free sample t test, the ordinal scale data will be tested with the Mann-Whitney Difference Test. Ethical eligibility was obtained from the Ethics Commission for Basic and Clinical Science Research at the Faculty of Veterinary Medicine, Airlangga University.

antibiotic eye drops (1% levofloxacin) four times a day to prevent secondary infection.

We got the collagen density on the 7th day by taking the central part of the corneal tissue for histopathological examination. The corneal tissue was fixed using 10% normal buffered formalin solution and then embedded in a paraffin block.

After a histopathological evaluation, we found that the density of corneal collagen that received a PRP of 20% was 11.1% of rabbits included in a score of 1, 88.9% of rabbits included in a score of 2, and no collagen density was included in a score of 3.

An example of the results of an overview of corneal collagen density in both groups can be seen in Figure 1.



**Figure 1** A, Loose collagen density score, B Moderate collagen density score.

**Table 1** Table of group comparisons in percent.

Group	PRP 20%	Amount	Score Density		Total
			Loose	Currently	
			1	8	9
		% between groups	11.1%	88.9%	100.0%
Group	AS 20%	Amount	5	4	9
		% between groups	55.6%	44.4%	100.0%

Examination of the thickness of the corneal collagen was carried out after enucleation on the 7th day. The corneal tissue was stained using Masson's trichrome. After that, the thickness of

the cornea was measured using a microscope, in the central corneal area. Histopathological picture of central corneal collagen thickness is shown in **figure 3**.

**Table 2** Table of average collagen thickness

	Mean	Standard Deviation	Maximum	Minimum
PRP 20%	55.41	15.66	78.91	38.08
AS 20%	67.62	24.37	114.75	35.27

After histopathological measurements, we found that the average thickness of the corneal collagen in the group treated with 20% PRP was 55.41 micrometers (standard deviation of 15.66 micrometers), with the thickest result being 78.91 micrometers and the thinnest being 38.08 micrometers.

Examination of the number of keratocyte cells was carried out on the 7th day after exposure to NaOH and therapy. The central corneal tissue was stained with Hematoxylin eosin staining, after which the number of keratocyte cells per hpf (high power field = 400x) was counted, counted in the hot spot area in five visual fields on the

central cornea, using a light microscope (Olympus CX31) in the central corneal area.

The average number of keratocyte cells in the central corneal area of the group treated with

20% AS was 45.47 cells/hpf (standard deviation 15.86), with the highest number of cells being 74.00 cells/hpf and the least being 26.20 cells/hpf.

**Table 3** Table of the average number of keratocyte cells per hpf (high power field)

	Mean	Standard Deviation	Maximum	Minimum
PRP 20%	54.56	22.92	104.40	34.80
AS 20%	45.47	15.86	74.00	26.20

In table 1. the collagen density of the group with 20% PRP eye drop therapy was 88.1% which was a score of 2 while the collagen thickness of the group with 20% AS eye drop therapy was 44.4% which was a score of 2. After the Chi-Square test was carried out, there was a non-significant difference between the two groups, between the group that was given 20% PRP eyedrops and those that received 20% AS eyedrops ( $p < 0.066$ ).

In table 2, the mean collagen thickness of the group with 20% PRP eye drop therapy was 55.41 micrometers, while the mean collagen thickness of the group with 20% AS eye drop

therapy was 67.62 micrometers. After the free sample T test was performed, there was no significant difference between the two groups that were given 20% PRP eye drop therapy and the group that was given 20% AS eye drop therapy ( $p = 0.224$ ).

Table 3 shows the average number of keratocytes in the group with PRP eye drop therapy of 20% and the number of keratocyte cells in the group with US eye drops of 20%. After the free sample t test was carried out, there was no significant difference between the two groups where  $p = 0.500$  was obtained.

## DISCUSSION

Chemical trauma to the ocular base is a chemical trauma that can cause extensive damage to both the surface of the ocular and inside the ocular. Its management often does not give maximum results, resulting in poor repair of corneal injuries, often in the form of corneal opacities and even scars.

Trauma to the ocular base is said to be very damaging due to protein denaturation and the process of saponification of the fatty membrane which causes alkaline materials to quickly enter the eye. Corneal wound healing, especially corneal transparency due to trauma will return if the density of collagen fibers is good, where collagen regulation is regular and the spacing

between collagen fibers is regular. Light scattering can also be reduced by the presence of proteins contained in keratocytes, growth factors contained in PRP and AS will activate keratocytes during stromal repair (Hassell and Birk, 2010, Khaskar, 2011).

PRP in its preparation uses anticoagulants to obtain concentrated platelets and coagulation factors. Platelets have an important function derived from  $\alpha$ -granules in their cytoplasm, namely as a reservoir of growth factors and several proteins (acid phosphatase,  $\alpha$ -1 antitrypsin, chemotactic factor and fibronectin). Growth factors and several proteins have important functions in tissue regeneration (proliferation, migration, and cell resistance). Anitua, et al (2015), stated that the concentrations of PDGF, VEGF, EGF, FGF and TGF- $\beta$ 1 are large in PRGF than AS, can increasing proliferation and migration of stromal keratocytes, in addition to reducing TGF- $\beta$ 1 differentiation in myofibroblasts (Kim, et al., 2012; Geerling, et al., 2004; Pacini et al., 2017; Anitua, et al., 2015).

From the results of histopathological examination, it was said that the percentage of corneal collagen density that received 20% PRP eye drop therapy was 88.9% which corresponds to a score of 2, for corneal collagen that received 20% AS eye drop therapy was 44.4% grade 2. this indicates that there is a difference in collagen density between the two groups. In the treatment group with 20% PRP therapy, collagen density was found to be close to normal, namely medium density. This was possible because PRP contains

many kinds of growth factors that play a role in proliferation, migration and differentiation. Research from Hu et al, which investigated the effect of basic fibroblast growth factor (bFGF) on repair of corneal epithelial injuries in dogs, which histopathologically resulted in repair of the corneal epithelium, inflammatory cells and significantly improved the structure of collagen density (Hue et al, 2009; Damayanti et al, 2012).

From the results of histopathological examination, it was said that the percentage of corneal collagen density that received 20% PRP eye drop therapy was 88.9% which corresponds to a score of 2, for corneal collagen that received 20% AS eye drop therapy was 44.4% grade 2. this indicates that there is a difference in collagen density between the two groups. In the treatment group with 20% PRP therapy, collagen density was found to be close to normal, namely medium density. This was possible because PRP contains many kinds of growth factors that play a role in proliferation, migration and differentiation. Research from Hu et al, which investigated the effect of basic fibroblast growth factor (bFGF) on repair of corneal epithelial injuries in dogs, which histopathologically resulted in repair of the corneal epithelium, inflammatory cells and significantly improved the structure of collagen density (Hue et al, 2009; Damayanti et al, 2012).

From the results of histopathological examination, we found the average number of keratocyte cells per high powerfield (hpf). The mean number of keratocyte cells in the group with 20% PRP therapy was 54.56. The average keratocyte cell group with 20% AS therapy was

45.47 cells/hpf. From these results it can be concluded that there is a difference in the average number of keratocyte cells in five fields seen in the hot spot area (the densest area) of the central cornea, where the mean group with PRP therapy is 20% more than the group average with AS therapy 20%. . This is related to PRP which is rich in growth factors derived from platelets compared to AS. Growth factors contained in platelets including FGF, TGF- $\beta$  and PDGF are important in stimulating the proliferation and migration of stromal fibroblasts (keratocytes) on the surface of the corneal tissue (Anitua et al, 2015).

From the results of calculating the difference in collagen density, we found that there was a difference between the corneas treated with 20% PRP and those treated with 20% AS, but not statistically significant with  $p = 0.066$ . From the results of other studies, Tandir et al; where research on reepithelialization in the rabbit cornea, showed acceleration in corneal regeneration, reduced inflammation in the eye, increased repair of the structure of collagen fibers in the corneal stroma compared to the control group. Meanwhile, Khaskar et al, examined PRP therapy in combination with acetylcysteine, which resulted in statistically significant improvements in collagen fiber density.

## BIBLIOGRAPHY

Anitua E, Muruzabal F, Alcalde I, Merayo-Lloves J & Orive G, 2013. Plasma richin growth factors (PRGF-Endoret) stimulates corneal wound healing and reduces haze

From the results of calculating the difference in collagen thickness, we found that there was a difference in the thickness of the corneal collagen treated with PRP 20% and those treated with AS 20% but not statistically significant with  $p=0.224$ . From a study conducted by Ariesta 2018, it was found that the thickness of the central corneal stroma treated with 20% PRP was better than 20% AS therapy, because the stromal lamellae experienced greater edema compared to 20% PRP therapy. In our study the measurements used a computer microscope using software, while the tools used in previous studies used a graticule which was viewed manually using a light microscope.

From the results of calculating the number of keratocyte cells, we found that there was a difference in the number of coronal keratocyte cells treated with PRP 20% and the cornea treated with AS20% but the results were not statistically significant. In another study, PRP was very good at stimulating the process of proliferation and migration of keratocyte cells (corneal fibroblasts). Hasemi et al, who used platelet rich plasma in various concentrations derived from human umbilical cord and peripheral blood in cultured human skin fibroblasts in vivo. The results obtained by PRP were able to increase the growth of skin fibroblasts compared to controls.

formation after PRK surgery, *Experimental Eye Research*, Elsevier Journal, vol. 115, p.153-161.

- Damayanti SA, Yuwono B, Dwi, & Robin dwi MC, 2012. Efek Pemberian Kurkumin terhadap Peningkatan Pembentukan Kolagen pada soket gigi tikuswistar pasca pencabutan, *tesis*. p. 1-4.
- Geerling G, MacLennan S & Hartwig D, 2004. Autologous Serum Eye Drops for Ocular Surface Disorders, *Br J Ophthalmol*, vol.88, no.11, p. 1467 – 1474.
- Hassell RJ & Birk DE, 2010. The molecular basis of corneal transparency. Elsevier journal. *Experimental Eye Research* 91. p 326- 335.
- Kaur M, Sinha R & Sharma N, 2014. Acute Chemical Injuries. DOS Times. Vol 9, no 9, p.41-45.
- Khaskar E, Aldavood SJ, Abedi GR, Sedaghat R, Nekoui O & Zamani ahmadmahmudi M, 2013. The Effect of Sub-Conjunctival Platelet Rich Plasma in Combination With Topical Acetylcysteine on Corneal Alkali Burn Ulcer In Rabbits, *Comparative Clinical Pathology*, Jan, vol.22, no.1, p. 107- 112.
- Kim KM, Shin YT & Kim HY, 2012 Effect of Autologous Platelet-Rich Plasma On Persistent Corneal Epithelial Defect After Infectious Keratitis, *Jpn J Ophthalmol*, vol.56, no.6, p. 544 – 550.
- Lekhanont K, Jongkhajornpong P, Choubtum L & Chuckpaiwong V, 2013. Topical 100 % Serum Eye Drops for Treating Corneal Epithelial Defect after Ocular Surgery, *BioMed Research International*, vol, artikel ID. 521315, p.7.
- Luo HL, Lu YB, Wu T, Zhang M, Zhana Y & Jin Y, 2013. Construction of Tissue Engginered Cornea Composed of Amniotic Epithelial Cell anda Acellular Porcine Cornea for Treating Coneal alkali Burn, *Biomaterials journal*, vol 34, p.6748-6759.
- Piccin A, Di Pierro AM, Canzian L, Primerano M, Corvetta D, Negri G, Mazzoleni G, Gast G, Steurer M, Gentilini I, Eisendle K & Fontanella F, 2016. Platelet gel: a new therapeutic tool with great potential. *Blood transfuse review*. p 1-7
- Salman IA & Gundogdu C, 2010. Epithelial Healing In Experimental Corneal Alkali Wounds with Nondiluted Autologous Serum Eye Drops, *Cutan. Ocul. Toxicol.*, vol.29, p. 116 – 121.
- Semeraro F, Forbice E, Braga O, Bova A, Salvatore AD & Azzolini C, 2014. Evaluation of The Efficacy of 50 % Autologous Serum Eye Drops In Different Ocular Surface Pathologies. *BioMed Research International*, vol. 2014, artikel ID. 826970, p. 11.
- Singh P, Tyagi M, Kumar Y, Gupta K & Sharma P, 2013. Ocular Chemical Injuries and Their Management. *Oman J Ophthalmol*, vol.6, no.2, p. 83 – 86.
- Tanidir ST, Yuksel N, Altintas O, Yildiz DK, Sener E & Caglar Y, 2010. The Effect of Subconjunctival Platelet-Rich Plasma On Corneal Epithelial Wound Healing Cornea, vol.; 29, no.6, p. 664 – 669.