



HISTOMORPHOLOGICAL ENHANCEMENT OF THE VAGINAL WALL IN DEHYDROEPIANDROSTERONE-TREATED POST-OVARECTOMIZED WISTAR RATS

PERBAIKAN HISTOMORFOLOGIS DINDING VAGINA PADA TIKUS WISTAR PASCA-OVARIKTOMI YANG DIobati DENGAN DEHIDROEPIANDROSTERON

Lis Widodo Peni¹, Pilar Menara Falah^{2*}, Yudha Nurdian³

¹ Anti-Aging Post-Graduate Program, Udayana University, Indonesia

² Department of Basic Dental Sciences, Faculty of Dentistry, University of Jember, Indonesia

³ Department of Basic Medical Sciences, Faculty of Medicine, University of Jember, Indonesia

ABSTRACT

Background: Vaginal atrophy has occurred in three quarters of post-menopausal women. The exclusive source of post-menopausal sex hormones is dehydroepiandrosterone (DHEA). **Purpose:** Observe the impact of orally administered DHEA in the vagina of a rat (*Rattus norvegicus*) post-bilateral ovariectomy. **Method:** This experiment utilized 36 wistar rats aged 10 - 12 weeks with a body weight of 180 - 200 grams. The rats were randomly divided into two groups with an equal number of members. The control group was orally administered glycerin via gavage at a dose of 1 mL per day, while the treatment group received 7.2 mg of DHEA dissolved in glycerin, also administered orally via gavage at a daily dose of up to 1 mL. Both groups were maintained for 42 consecutive days. Finally, a histomorphology examination was conducted on the vaginal tissues of the sacrificed rats. **Result:** The mean of epithelial and smooth muscle thickness of the treatment group was significantly higher than that of the control group (p -value < 0.05). Besides, the number of blood vessels were also significantly higher in the treated group (p -value < 0.05). **Conclusion:** Administering DHEA orally via gavage enhances epithelial and smooth muscle tissue thickness, and augments the number of blood vessels in the vagina of wistar rats after bilateral ovariectomy.

ABSTRAK

Latar belakang: Atrofi vagina telah terjadi pada tiga perempat wanita pasca-menopause. Hormon seks pasca-menopause bersumber dari *dehydroepiandrosteron* (DHEA). **Tujuan:** Mengamati dampak DHEA yang diberikan secara oral pada histomorfologi dinding vagina tikus putih (*Rattus norvegicus*) pasca-ovarietomi bilateral. **Metode:** Percobaan ini menggunakan 36 ekor tikus wistar berumur 10 - 12 minggu dengan berat badan 180 - 200 gram. Tikus dibagi secara acak menjadi dua kelompok dengan jumlah anggota yang sama. Kelompok kontrol diberikan gliserin per sonde secara oral dengan dosis 1 mL per hari, sedangkan kelompok perlakuan menerima DHEA 7,2 mg yang dilarutkan dalam gliserin, juga diberikan secara oral hingga 1 mL per sonde tiap hari. Tata laksana pada masing-masing kelompok dilakukan selama 42 hari berturut-turut. Terakhir, dilakukan pemeriksaan histomorfologi pada jaringan vagina tikus percobaan. **Hasil:** Rerata ketebalan epitel dan otot polos kelompok perlakuan lebih tinggi secara signifikan dibandingkan kelompok kontrol (p -value $< 0,05$). Selain itu, jumlah pembuluh darah juga jauh lebih tinggi pada kelompok perlakuan (p -value $< 0,05$). **Kesimpulan:** Pemberian DHEA per sonde secara oral meningkatkan ketebalan jaringan epitel dan otot polos, serta meningkatkan jumlah pembuluh darah di vagina tikus wistar setelah ovariektomi bilateral.

Original Research Article
Penelitian

ARTICLE INFO

Received 28 February 2023
Revised 12 April 2023
Accepted 22 January 2024
Available Online 31 July 2024

Correspondence:
Pilar Menara Falah

E-mail :
Pilarmenara18@gmail.com

Keywords:
Enhancement, Dehydroepiandrosterone,
Ovariectomy, Vaginal wall

Kata kunci:
Perbaikan, Dehydroepiandrosteron,
Ovariektomi, Dinding vagina



INTRODUCTION

Menopause is defined as the aging process initiated by a decline in hormone levels (Davis *et al.*, 2015; Pangkahila, 2015). According to Naumova and Castelo-Branco (2018), about three quarters of *Post-Menopausal Women* (PMW) experience vaginal atrophy. PMW often has a syndrome that includes reduced vaginal lubrication, irritation, burning, itching, inflammation, bleeding, vaginal infections, *Urinary Tract Infections* (UTIs), dyspareunia, decreased libido, and sexual dysfunction (Portman *et al.*, 2014). Based on the results of the Real Women's Views of Treatment Options for Menopausal Vaginal Changes (REVIVE) survey in Europe, there are three significant impacts of vaginal atrophy related to partnerships: sexual satisfaction (72%), sexual spontaneity (66%), and intimacy (62%) (Nappi *et al.*, 2016).

Vaginal atrophy results in a decrease in the size of the uterus, ovaries, vaginal canal, and vulva. The components that make up the connective tissue of the vaginal wall, consisting of collagen, elastin, and smooth muscle, undergo degeneration. This degeneration causes a decrease in the structural integrity of the vagina, which includes thinning of the epithelium, reduced thickness of smooth muscle tissue, loss of rugae, and a reduced number of blood vessels, making the vagina look pale and dry. Epithelial tissue becomes brittle with submucosal petechiae. Reduced vaginal blood flow results in decreased transudation during sexual arousal and increased sensitivity to trauma and pain (Johnston *et al.*, 2004).

The dysfunction of ovaries at menopause is physiologically compensated by intracrinological mechanisms. This mechanism provides estrogen and androgens according to the needs of each cell to function normally, and the amount depends on the level of steroidogenic enzymes that are specifically expressed in each tissue (Labrie, 2015a; Labrie *et al.*, 2017b). Those enzymes responsible for steroid synthesis in classical glands are expressed in peripheral tissues, allowing for local steroid metabolism. Therefore, the intracrinological mechanism does not increase serum levels of sex steroid hormones, avoiding undesirable systemic effects, particularly the stimulation of the ovaries, uterus, and breast (Labrie *et al.*, 2017a).

Dehydroepiandrosterone (DHEA) is a unique and exclusive source of sex steroid hormones in PMW. The secretion of DHEA markedly decreases from the age of 30 years and reaches an average reduction of 60% at menopause when compared to the maximum value at the age of 30 years (Labrie, 2010). Women exhibit varying serum levels of endogenous DHEA, with 25% of them having high DHEA levels to avoid the menopausal syndrome (Labrie, 2015b; Labrie, 2015c). DHEA secretion lacks a feedback mechanism to increase its secretion if the serum level is low. Therefore, women with low DHEA

secretion rates will consistently experience sex steroid hormone deficiency with all its consequences if not treated with exogenous DHEA (Labrie and Labrie, 2013).

In a preclinical study, ovariectomy performed on rats is used as the menopausal model to study the effects of a permanent reduction in the levels of steroid hormones. In ovariectomized rats, hormonal changes similar to those in human females occur. Progesterone and estradiol levels are lower at a month than they are at a week post-ovariectomy (Moiety *et al.*, 2015). Recent data have demonstrated the presence of steroidogenic enzymes in the rodent vagina that allows local synthesis of sex steroid hormones (Santos *et al.*, 2017). Besides that, the female rat was chosen due to a gender preference in the effect of DHEA (Bloch *et al.*, 2013). Rats cannot synthesize DHEA (Weerden *et al.*, 1992), so the administration of DHEA is the exclusive source for these experimental animals. Therefore, the rat is also suitable as an animal model for DHEA intracrinology at menopause.

A preliminary comparative study was conducted on the thickness of epithelium and smooth muscle tissue, as well as the number of blood vessels on the vaginal wall, due to the oral administration of DHEA in four groups of adult albino wistar rats (*Rattus norvegicus* Berkenhout, 1769) after *Bilateral Ovariectomy* (BOVX). The selected dose for further research was determined based on the group administered with a dose of 7.2 mg/day of DHEA (Peni and Pangkahila, 2018). This chosen DHEA dose is deemed sufficient to reverse BOVX-induced vaginal atrophy. Related to the lack of data on the differences in DHEA per os against menopausal vaginal atrophy, additional research was performed to assess whether orally administered DHEA could enhance the thickness of epithelial and smooth muscle tissue, and elevate the number of blood vessels in rats' vaginas post-BOVX. Therefore, this study aims to observe the impact of orally administered DHEA on the histomorphology of the vaginal wall in bilateral white rats (*R. norvegicus*) after ovariectomy.

MATERIAL AND METHOD

The subjects of this study were 36 young female albino wistar rats (10 - 12 weeks old) sourced from the Laboratory Animal Unit, Department of Pharmacology, Medical Faculty, Udayana University, Denpasar, Indonesia. These rats were healthy and active, with an initial weight ranging from 180 - 200 g. According to the *Federer* formula, the designated sample number for each treatment group was 16 rats. Then to anticipate if there were dead samples, 10% of the samples obtained per group were added, resulting in an increase of 1.6 per group, rounded up to 2 individuals per group. The overall sample size that fits with the calculation was 36 rats.

The rats were acclimatized to the room conditions [temperature: $22 \pm 3^\circ\text{C}$, humidity: $50 \pm 20\%$, 12 hour light (not exceeding 50 lux)/12-hour dark cycles, with lights on at 07:00 AM] for 7 days before starting the experiment. The rats were individually housed and provided free access (*ad libitum*) to water and rat chow (Mazuri® Rat & Mouse Diets, St. Louis, MO, USA). The experiment was conducted following the guidelines outlined in "Use of Laboratory Animals in Biomedical Studies" (Carlsson *et al.*, 1988). All procedures performed in this study adhered to the ethical standards of the Faculty of Veterinary Medicine at Udayana University. The approval number of ethical clearance for this study was 346/KE-PH-Lis-2/1/2018.

The rats were randomly divided into two groups of 18 rats each as follows: (i) BOVX + glycerin (control group), (ii) BOVX + DHEA + glycerin (treatment group). On the first day of the experiment, the rats in both groups underwent BOVX under isoflurane-induced anesthesia. The abdominal fur was shaved, and antisepsis with a 10% povidone-iodine solution was performed before the surgery. Using an aseptic technique and under sterile conditions, a 0.5 cm pfannenstiel incision (Khajuria *et al.*, 2012) was performed with a scalpel blade number 11 to remove the ovaries and ligate the oviduct. The incision was closed in two layers by 2/0 polyglactin sutures. All rats were observed for 30 days for the wound healing process and to allow the steroid sex hormone levels to drop, creating menopausal conditions.

Treatment was initiated on day 32 of the experiment. Glycerin was administered by oral gavage to each rat (1 mL/rat/day) in the control group for 6 weeks, while 7.2 mg of DHEA was dissolved in glycerin up to 1 mL and administered by oral gavage to each rat (1 mL/rat/day) in the treatment group for 6 weeks. The selected dose of DHEA was obtained from preliminary research (Peni and Pangkahila, 2018). The DHEA used was from Zhou®, Zhou Nutrition, Utah, USA. Twenty four hours after the last dosing, overnight-fasted animals were euthanized under isoflurane anesthesia using the cervical dislocation method.

The vagina of each euthanized animal was post-fixed in 10% *Neutral Buffered Formalin* (NBF) at room temperature for 48 hours, routinely processed, and embedded in paraffin. A cross-segment of 3 mm was dissected from the central region of each vagina segment at approximately 1 cm from the ostium (2/3 posterior vagina). Four sections (5 μm thick) from the middle part of each vagina segment were cut at intervals of 15 μm and mounted on glass slides. Sections were stained with *Hematoxylin and Eosin* (H & E) for histological analysis. The histomorphological examination was carried out using a digital microscope (ZEISS Axio Imager®, Oberkochen, Germany) with 200 times magnification. Measurements were taken using the *ImageJ*® raster software (National Institute of Health, USA) by drawing a line perpendicular to the

cross-section of the widest epithelial and plain muscle tissue. The measurement results are presented in units of micrometers (μm). The area of four different vaginal sections per animal was also performed by manually counting submucosal blood vessels at an image magnification of 200x. The average number of blood vessels per high power field (200x) was calculated for each group.

Finally, the obtained data were confirmed to be normally distributed through the *Shapiro-wilk* test ($p\text{-value} > 0.05$) and homogeneity was verified by *Levene's* test ($p\text{-value} > 0.05$). Consequently, statistical significance was determined according to the *Independent samples T* test (IBM SPSS Statistics®, Germany). The data were represented as mean \pm *Standard Deviation* (SD), and a value with $p\text{-value} < 0.05$ was considered significant. To ensure unbiased results, a blind experiment was conducted.

RESULT

The results indicated that orally administered DHEA had a significant histomorphological impact on the vaginal walls of rats. As shown in Table 1, the thickness of the epithelial and smooth muscle tissues of the vaginal wall elevates significantly following DHEA treatment in BOVX rats ($p\text{-value} < 0.05$). In addition, the number of submucosal blood vessels also increases ($p\text{-value} < 0.05$). DHEA induced a 73%, 56%, and 93% increase in epithelial thickness, smooth muscle thickness, and submucosal blood vessel count, respectively, compared to control rats ($p\text{-value} < 0.001$).

As evidenced in Figure 1, the administration of DHEA exhibits its impact on improving vaginal epithelial cell thickness in rat models. The vaginal mucosa of treatment rats performed a stratified epithelium, 12 layers or more in thickness, with a superficial cornified layer and epithelial infoldings into the lamina propria. In contrast, the epithelium of control rats was reduced to a few cells, not exceeding 5 cells in depth, and very few epithelial infoldings into the lamina propria were observed.

Enhancement of vaginal smooth muscle is evident in Figure 2. Figure 2 shows that the vaginal muscle in the treatment group is well organized with a clearly defined layer. However, the muscle underwent wasting in the control group. The bundles of smooth muscle were fewer, smaller, and more condensed, and the layer could scarcely be recognized.

The impact of repairing vaginal vessels is indicated by Figure 3. Figure 3 demonstrates an increase in the count of submucosal vascular vessels, prominently visible in treatment rats. Blood vessels were easily found in the treatment group. On the contrary, vascular vessels were scarcely observed in the control group.

Table 1. Comparative test results between control and treatment rats

Group	Epithelial thickness (µm)		Smooth muscle thickness (µm)		Blood vessel count	
	Mean	SD	Mean	SD	Mean	SD
Control (n=18)	29.75539	± 8.047253	47.42761	± 9.4749	9.50	± 2.431
Treatment (n=18)	51.39794	± 8.556033	74.13567	± 11.2810	18.30	± 1.461

n = replication

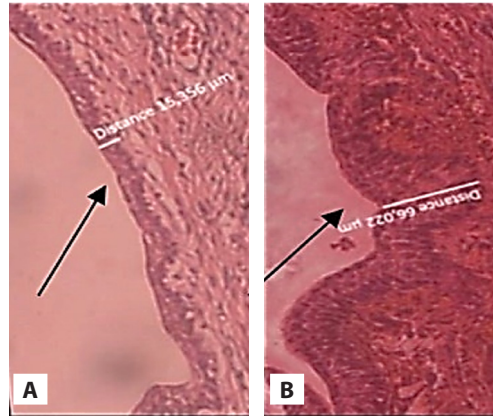


Figure 1. Histomorphological differences in epithelial thickness (Hematoxylin and Eosin (H & E) staining, 200x magnification): A = Control; B = Treatment

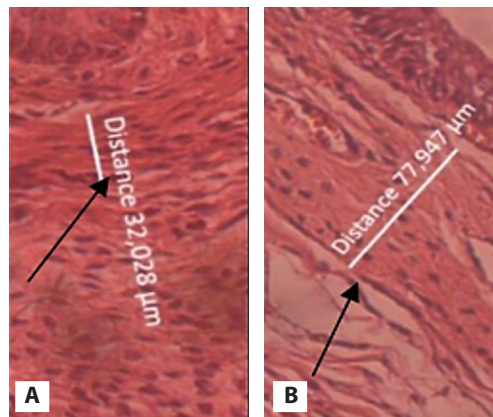


Figure 2. Histomorphological differences in smooth muscle thickness (Hematoxylin and Eosin (H & E) staining, 200x magnification): A = Control; B = Treatment

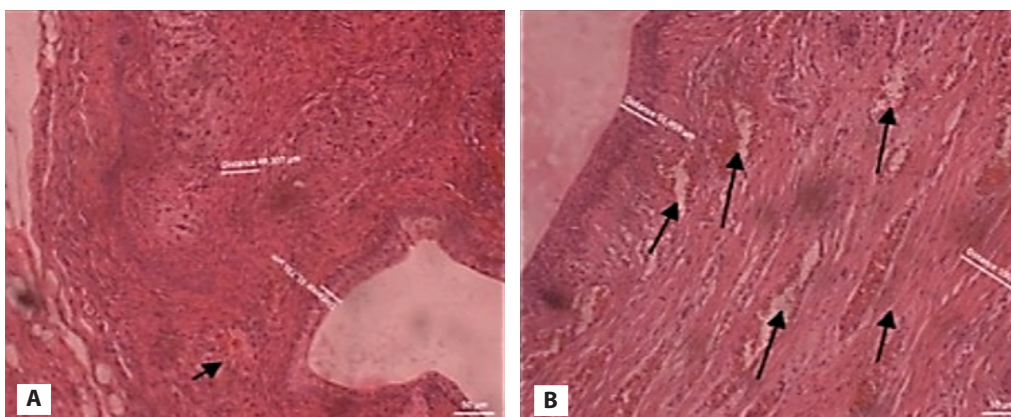


Figure 3. Histomorphological differences in blood vessel count (Hematoxylin and Eosin (H & E) staining, 200x magnification): A = Control; B = Treatment

DISCUSSION

The present study observes the differences in DHEA's ability to induce androgenic and/or estrogenic responses when given per os in sample groups of rats. The per os route of administration was used to provide evidence for the alternative usage of DHEA. The present data show that treatment with DHEA reverses the atrophic changes in the vaginal wall and results in a 73%, 56%, and 93% increase in epithelial thickness, smooth muscle thickness, and submucosal blood vessel count, respectively, in the BOVX rats. Since DHEA has no intrinsic androgenic or estrogenic activity, the histomorphological changes observed after DHEA treatment reflect its intracrine conversion into active sex steroids with estrogenic and/or androgenic actions. Previous studies by Pelletier *et al.* (2013, 2012) and Berger *et al.* (2008, 2005) have shown that DHEA administration in ovariectomized rats had stimulatory androgenic and/or estrogenic effects.

Based on the findings of this study, orally administered DHEA induced enhancements in the histomorphology of the rat vaginal wall due to sex steroids deficiency following bilateral ovariectomy. In these castrated rats, DHEA exhibited beneficial effects on the vaginal epithelium and the underlying cell layers, repairing the structural integrity of the vaginal tissue. Histomorphological examination indicated the restoration of the vaginal structural integrity in rats. The underlying mechanism is as follows: the vaginal epithelium underwent thickening with androgenic mucification, and related to the androgenic effect of DHEA. Furthermore, plain muscle bundles thickened and solidified. The thickening of the tunica muscularis is related to both the androgenic and estrogenic effects of DHEA, as well as the increased expression of progesterone receptors in the muscle layer (Labrie *et al.*, 2017b). The number of submucosal blood vessels also showed an increase, which was associated with the estrogenic effects of DHEA, directly stimulating endothelial proliferation and angiogenesis (Liu *et al.*, 2008). In addition, there is progestogenic milieu restoration that does not originate from DHEA conversion, but is associated with the inhibition of the conversion of pregnenolone to cortisol via 17-hydroxyprogesterone (Pluchino *et al.*, 2008).

DHEA is a prohormone synthesized by the adrenal glands. It undergoes metabolism to androgens (androstenedione, testosterone), followed by aromatization to estrogens (estrone, estradiol). The process is not mediated by endocrine mechanisms. Based on the concept of intracrinology, termed by Labrie (2019), this inactive prohormone enters the cells of the vagina, where it is transformed into an active hormone by intracellularly localized enzymes. Thus, the active hormone exerts its effects exclusively within the vagina cells, avoiding systemic influence as it is inactivated

within the same cells. The inactive metabolites are released into the bloodstream for elimination by the liver and kidneys. This minimizes changes in serum sex steroid levels after DHEA administration, thereby avoiding inappropriate exposure of other tissues to active sex steroids. The intracrinology mechanism of DHEA is a physiological compensation mechanism to eliminate the risk of systemic effects associated with estrogen based *Hormone Replacement Therapy* (HRT) for PMW (Jones *et al.*, 2016; Manson *et al.*, 2017, Manson *et al.*, 2013). Furthermore, it is important to note that estrogen therapy is only a partial hormonal therapy because, after menopause, not only estrogens but also androgens are deficient, a condition that can be corrected by DHEA.

Based on our knowledge, the findings of this study represent the first evidence that orally administered DHEA is effective in reversing the aging of the rat vagina. The mechanism restores and fulfills the needs of estrogen and androgens according to the needs of each cell to function normally, according to the level of steroidogenic enzymes specifically expressed *in situ* in the vagina (Labrie, 2015a; Labrie *et al.*, 2017a). Moreover, oral administration is a more convenient and alternative method to avoid adverse reactions related to vaginal ovules. The most frequently reported adverse reaction in clinical trials with vaginal DHEA was vaginal discharge, occurring in 9.9% of patients (Portman *et al.*, 2015). The ovule vehicle has the potential to irritate the vagina, and the melting process can lead to unpleasant discharge (Voelker, 2017).

Epithelialization, angiogenesis, and proliferation of smooth muscle cells in the rat vagina occurred significantly at a DHEA dose of 7.2 mg/day, indicating the adequacy of the dose used. This dosage is equivalent to a human dose of 400 mg/day, and it is considered a well-tolerated supraphysiological dose based on available data in the scientific clinical literature (Sripada *et al.*, 2013). There have been no reports of serious adverse effects associated with the use of DHEA at doses ranging from 50 mg/day to 2,250 mg/day (Tummala and Svec, 1999). A weakness of this study is that it did not use aged intact female white rats, so we could not compare the effects of DHEA-induced reverse aging on vaginal aging between intact and ovariectomized rats. In addition, we did not know exactly how much DHEA was in the study drug used in this study.

CONCLUSION

Based on the results of this study, it can be concluded that oral administration of DHEA significantly enhances vaginal epithelium and plain muscle tissue thickness, as well as significantly elevates the number of vaginal blood vessels in adult wistar rats after bilateral ovariectomy.

ACKNOWLEDGMENTS

The authors thank to Prof. Dr. dr. Wimpie Pangkahila, Sp.And., and Prof. dr. I Gusti Made Aman, Sp.FK, who facilitated this study. The authors state that there is no conflict of interest with the parties involved in this study.

REFERENCE

- Berger, L., El-Alfy, M., Labrie, F., 2008. Effects of Intravaginal Dehydroepiandrosterone on Vaginal Histomorphology, Sex Steroid Receptor Expression and Cell Proliferation in the Rat. *J Steroid Biochem Mol Biol Vol.* 109(1-2), Pp. 67-80.
- Berger, L., El-Alfy, M., Martel, C., Labrie, F., 2005. Effects of Dehydroepiandrosterone, Premarin and Acolbifene on Histomorphology and Sex Steroid Receptors in the Rat Vagina. *J Steroid Biochem Mol Biol Vol.* 96(2), Pp. 201-215.
- Bloch, M., Meiboom, H., Zaig, I., Schreiber, S., Abramov, L., 2013. The Use of Dehydroepiandrosterone in the Treatment of Hypoactive Sexual Desire Disorder: A Report of Gender Differences. *European Neuropsychopharmacology Vol.* 23(8), Pp. 910-918.
- Carlsson, H.E., Hagelin, J., Hagelin, J., 1988. Use of Laboratory Animals in Biomedical and Behavioral Research, in: *Use of Laboratory Animals in Biomedical and Behavioral Research.* National Academies Press (US).
- Davis, S.R., Lambrinoudaki, I., Lumsden, M., Mishra, G.D., Pal, L., Rees, M., Santoro, N., Simoncini, T., 2015. Menopause. *Nat Rev Dis Primers Vol.* 1(1), Pp. 1-19.
- Johnston, S.L., Farrell, S.A., Bouchard, C., Farrell, S.A., Beckerson, L.-A., Comeau, M., Johnston, S.L., Lefebvre, G., Papaioannou, A., SOGC Joint Committee-Clinical Practice Gynaecology and Urogynaecology, 2004. The Detection and Management of Vaginal Atrophy. *J Obstet Gynaecol Can Vol.* 26(5)], Pp. 503-515.
- Jones, M.E., Schoemaker, M.J., Wright, L., McFadden, E., Griffin, J., Thomas, D., Hemming, J., Wright, K., Ashworth, A., Swerdlow, A.J., 2016. Menopausal Hormone Therapy and Breast Cancer: What is the True Size of the Increased Risk? *Br J Cancer Vol.* 115(5), Pp. 607-615.
- Khajuria, D.K., Razdan, R., Mahapatra, D.R., 2012. Description of a New Method of Ovariectomy in Female Rats. *Rev Bras Reumatol Vol.* 52(3), Pp. 462-470.
- Labrie, F., 2019. Intracrinology and Menopause: The Science Describing the Cell-Specific Intracellular Formation of Estrogens and Androgens from DHEA and Their Strictly Local Action and Inactivation in Peripheral Tissues. *Menopause Vol.* 26(2), Pp. 220-224.
- Labrie, F., 2015a. Androgens in Postmenopausal Women: Their Practically Exclusive Intracrine Formation and Inactivation in Peripheral Tissues, in: Rizk, B.R.M.B., Plouffe, J., Leo (Eds.), *Androgens in Gynecological Practice.* Cambridge University Press, Cambridge, Pp. 64-73.
- Labrie, F., 2015b. Intracrinology in Action: Importance of Extragonadal Sex Steroid Biosynthesis and Inactivation in Peripheral Tissues in Both Women and Men. *J Steroid Biochem Mol Biol Vol.* 145, Pp. 131-132.
- Labrie, F., 2015c. All Sex Steroids Are Made Intracellularly in Peripheral Tissues by The Mechanisms of Intracrinology After Menopause. *J Steroid Biochem Mol Biol Vol.* 145, Pp. 133-138.
- Labrie, F., 2010. Important Source of Sex Steroids in Men and Even More in Women. *Prog Brain Res Vol.* 182, Pp. 97-148.
- Labrie, F., Bélanger, A., Pelletier, G., Martel, C., Archer, D.F., Utian, W.H., 2017a. Science of Intracrinology in Postmenopausal Women. *Menopause Vol.* 24(6), Pp. 702-712.
- Labrie, F., Labrie, C., 2013. DHEA and Intracrinology at Menopause, a Positive Choice for Evolution of the Human Species. *Climacteric Vol.* 16(2), Pp. 205-213.
- Labrie, F., Martel, C., Pelletier, G., 2017b. Is Vulvovaginal Atrophy Due to a Lack of Both Estrogens and Androgens? *Menopause Vol.* 24(4), Pp. 452-461.
- Liu, D., Iruthayanathan, M., Homan, L.L., Wang, Yiqiang, Yang, L., Wang, Yao, Dillon, J.S., 2008. Dehydroepiandrosterone Stimulates Endothelial Proliferation and Angiogenesis through Extracellular Signal-Regulated Kinase 1/2-Mediated Mechanisms. *Endocrinology Vol.* 149(3), Pp. 889-898.
- Manson, J.E., Aragaki, A.K., Rossouw, J.E., Anderson, G.L., Prentice, R.L., LaCroix, A.Z., Chlebowski, R.T., Howard, B.V., Thomson, C.A., Margolis, K.L., Lewis, C.E., Stefanick, M.L., Jackson, R.D., Johnson, K.C., Martin, L.W., Shumaker, S.A., Espeland, M.A., Wactawski-Wende, J., WHI Investigators, 2017. Menopausal Hormone Therapy and Long-term All-Cause and Cause-Specific Mortality: The Women's Health Initiative Randomized Trials. *JAMA Vol.* 318(10), Pp. 927-938.
- Manson, J.E., Chlebowski, R.T., Stefanick, M.L., Aragaki, A.K., Rossouw, J.E., Prentice, R.L., Anderson, G., Howard, B.V., Thomson, C.A., LaCroix, A.Z., Wactawski-Wende, J., Jackson, R.D., Limacher, M., Margolis, K.L., Wassertheil-Smoller, S., Beresford, S.A., Cauley, J.A., Eaton, C.B., Gass, M., Hsia, J., Johnson, K.C., Kooperberg, C., Kuller, L.H., Lewis, C.E., Liu, S., Martin, L.W., Ockene, J.K., O'Sullivan, M.J., Powell, L.H., Simon, M.S., Horn, L.V., Vitolins, M.Z., Wallace, R.B., 2013. Menopausal Hormone Therapy and Health Outcomes During the Intervention and Extended Poststopping Phases of the Women's Health Initiative Randomized Trials. *JAMA Vol.* 310(13), Pp. 1353-1368.

- Moiety, F.M., Salem, H.A., Mehanna, R.A., Abdel-Ghany, B.S., 2015. Comparative Study on Induction and Effects of Surgical Menopause in A Female Rat Model: A Prospective Case Control Study. *Int J Clin Exp Med* Vol. 8(6), Pp. 9403-9411.
- Nappi, R.E., Palacios, S., Panay, N., Particco, M., Krychman, M.L., 2016. Vulvar and Vaginal Atrophy in Four European Countries: Evidence from The European REVIVE Survey. *Climacteric* Vol. 19(2), Pp. 188-197.
- Naumova, I., Castelo-Branco, C., 2018. Current Treatment Options for Postmenopausal Vaginal Atrophy. *Int J Womens Health* Vol. 10, Pp. 387-395.
- Pangkahila, W.I., 2015. Evidence-Based Anti-Aging Medicine Hormone-Replacement Therapy, 1 st. ed. TLC Publication.
- Pelletier, G., Ouellet, J., Martel, C., Labrie, F., 2013. Androgenic Action of Dehydroepiandrosterone (DHEA) on Nerve Density in the Ovariectomized Rat Vagina. *J Sex Med* Vol. 10(8), Pp. 1908-1914.
- Pelletier, G., Ouellet, J., Martel, C., Labrie, F., 2012. Effects of Ovariectomy and Dehydroepiandrosterone (DHEA) on Vaginal Wall Thickness and Innervation. *J Sex Med* Vol. 9(10), Pp. 2525-2533.
- Peni, L.W., Pangkahila, W., 2018. DHEA Supplementation Increases Epithelial Thickness, Plain Muscle Tissue, and Adult Vaginal Blood Vessels (*Rattus norvegicus*) after Bilateral Post-Ovarectomy. *IJAAM (Indonesian Journal of Anti-Aging Medicine)*.
- Pluchino, N., Ninni, F., Stomati, M., Freschi, L., Casarosa, E., Valentino, V., Luisi, S., Genazzani, A.D., Potì, E., Genazzani, A.R., 2008. One-Year Therapy with 10 mg/Day DHEA Alone or in Combination with HRT in Postmenopausal Women: Effects on Hormonal Milieu. *Maturitas* Vol. 59(4), Pp. 93-303.
- Portman, D.J., Gass, M.L.S., Vulvovaginal Atrophy Terminology Consensus Conference Panel, 2014. Genitourinary Syndrome of Menopause: New Terminology for Vulvovaginal Atrophy from The International Society for The Study of Women's Sexual Health and The North American Menopause Society. *Maturitas* Vol. 79(3), Pp. 349-354.
- Portman, D.J., Labrie, F., Archer, D.F., Bouchard, C., Cusan, L., Girard, G., Ayotte, N., Koltun, W., Blouin, F., Young, D., Wade, A., Martel, C., Dubé, R., other participating members of VVA Prasterone Group, 2015. Lack of Effect of Intravaginal Dehydroepiandrosterone (DHEA, Prasterone) on The Endometrium in Postmenopausal Women. *Menopause* Vol. 22(12), Pp. 1289-1295.
- Santos, A.C.D., Conley, A.J., Oliveira, M.F. de, Oliveira, G.B., Viana, D.C., Neto, A.C. de A., 2017. Immunolocalization of Steroidogenic Enzymes in The Vaginal Mucous of *Galea Spixii* during the Estrous Cycle. *Reproductive Biology and Endocrinology* Vol. 15(1), Pp. 30.
- Sripada, R.K., Marx, C.E., King, A.P., Rajaram, N., Garfinkel, S.N., Abelson, J.L., Liberzon, I., 2013. DHEA Enhances Emotion Regulation Neurocircuits and Modulates Memory for Emotional Stimuli. *Neuropsychopharmacol* Vol. 38(9), Pp. 1798-1807.
- Tummala, S., Svec, F., 1999. Correlation between The Administered Dose of DHEA and Serum Levels of DHEA and DHEAS in Human Volunteers: Analysis of Published Data. *Clin Biochem* Vol. 32(5), Pp. 355-361.
- Weerden, Van W.M., Bierings, H.G., Van Steenbrugge, G.J., de Jong, F.H., Schröder, F.H., 1992. Adrenal Glands of Mouse and Rat Do Not Synthesize Androgens. *Life Sci* Vol. 50(12), Pp. 857-861.
- Voelker, R., 2017. Relief for Painful Intercourse. *JAMA* Vol. 317(1), Pp. 18.